

# Growing skull fracture with cerebrospinal fluid fistula: A rare case report and its management strategies

Saurabh Jain, Ashok Gandhi, Achal Sharma, Radhey Shyam Mittal

Department of Neurosurgery, SMS Hospital, Jaipur, Rajasthan, India

## ABSTRACT

The growing skull fracture (GSF) occurs in younger age group as a sequel of trauma. The most common site of these lesions is parietal region. Here we are presenting a case of GSF of posterior fossa with cerebrospinal fluid (CSF) fistula. As per literature, we have not found a single case of GSF in the posterior fossa with CSF fistula. The aim of this presentation is discussing the unusual presentation of GSF and its management.

**Key words:** Cerebrospinal fluid fistula, growing skull fracture, sequel of trauma

## Introduction

Growing skull fracture (GSF) is also known as leptomeningeal cyst, craniocerebral erosion, and intradiploic cyst or posttraumatic cephalocele. The GSF occurs in younger age group sequel to trauma. The most common site of these lesions is parietal region. Here we are presenting a case of GSF of posterior fossa with cerebrospinal fluid (CSF) fistula. As per literature, we have not found a single case of GSF in the posterior fossa with CSF fistula. The aim of this presentation is discussing the unusual presentation of GSF and its management.

## Case Report

Two months before 7-year-old female presented to our department with a history of injury due to fall from height. Due to injury patient suffered from fracture in midline occipital bone [Figure 1]. Now she presented with progressively enlarging swelling in the occipital and sub occipital region. The swelling is soft in consistency, globular in shape, smooth surface, transilluminant and impulse on coughing present.

Before coming to our institution parents of the patient, consulted a local practitioner who misdiagnosed the swelling as hematoma/abscess. In an attempt to aspirate the content of swelling he inserted a needle converting it to a CSF fistula. There was a visible CSF leak present on the superior part of the swelling coming drop by drop [Figure 2]. The drop size increases rapidly on crying of patient. A noncontrast computed tomography of the head suggested a hypo dense cystic swelling in the occipital and sub occipital region with underlying occipital bone fracture. The cyst was communicating with underlying posterior fossa through the fracture. The underlying occipital bone defect increased significantly over this period of time.

The diagnosis of midline posterior fossa GSF with iatrogenic CSF fistula was made. After initial blood investigations, an operative decision was planned for the patient in the emergency settings. The patient was subjected for the midline sub occipital craniectomy with duraplasty using autologous pericranial patch. Intraoperatively there was a large dural defect underlying the fracture line [Figure 3], larger than the fracture itself [Figure 4]. The dura was adhered to the underlying cerebellar tissue. The dural margins were separated from underlying cerebellar tissue. The margins were freshened, and the dura was repaired using pericranial patch in a water tight closure [Figure 5]. Postoperatively patient developed bulging of the operative site, which was subsided after conservative treatment.

## Discussion

Howship was the first person to report the GSF in 1816.<sup>[1]</sup> There are many names given to this condition since then including but not limited to a traumatic ventricular cyst, craniocerebral

### Access this article online

#### Quick Response Code:

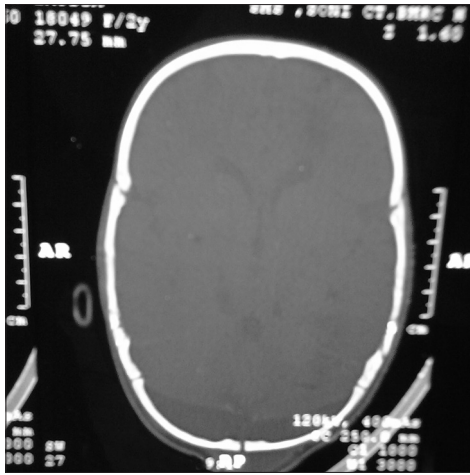


**Website:**  
www.asianjns.org

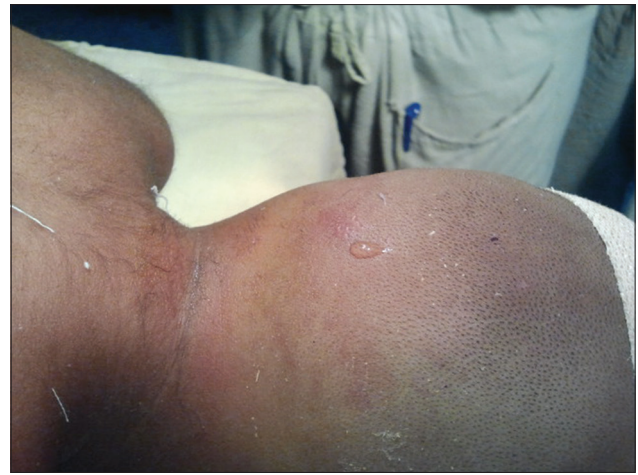**DOI:**  
10.4103/1793-5482.161182

### Address for correspondence:

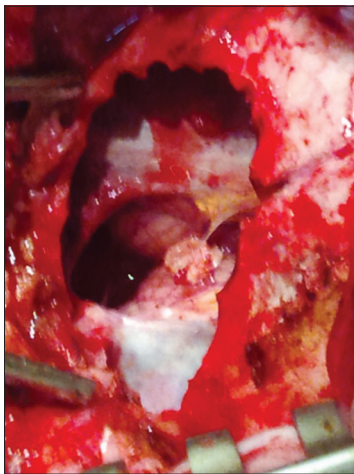
Dr. Saurabh Jain, 33, Uniara Gardens, Near Trimurti Circle, Jaipur, Rajasthan, India. E-mail: drsaurabh\_jain@rediffmail.com



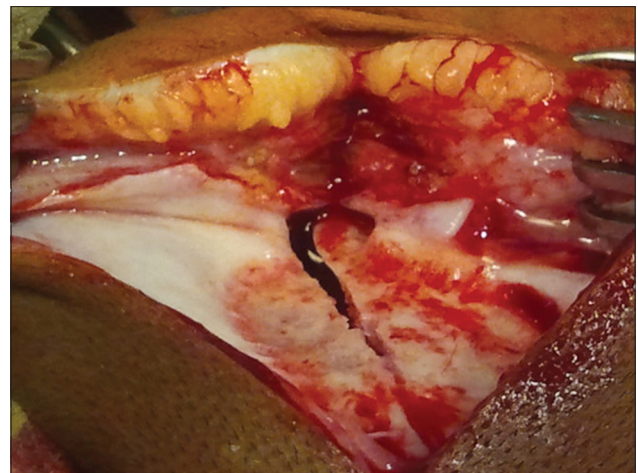
**Figure 1:** Noncontrast computed tomography scan head bone window after initial head trauma



**Figure 2:** Cerebrospinal fluid coming out through scalp



**Figure 3:** Dural margins and underlying cerebellar tissue through enlarged bone defect



**Figure 4:** Fracture occipital bone after exposure

erosion, cranial malacia, leptomeningeal cyst and the most common and popularly used GSF.<sup>[1]</sup>

The incidence of GSF is varying in different study. It is usually 0.05–1.6%. It occurs in 5–10 years of age with slight male preponderance. This is a sequel of head injury. The most common mode of trauma is fall from height. The most common region affected is parietal region. It is rarely seen in the occipital bone, may be due to extensive muscle mass.<sup>[2]</sup> Many conditions have been described for contributing to the occurrence of GSF, such as rapid brain growth and brain pulsation, raised intracranial pressure, leptomeningeal cysts, parenchymal injury and alteration of CSF flow.<sup>[3]</sup>

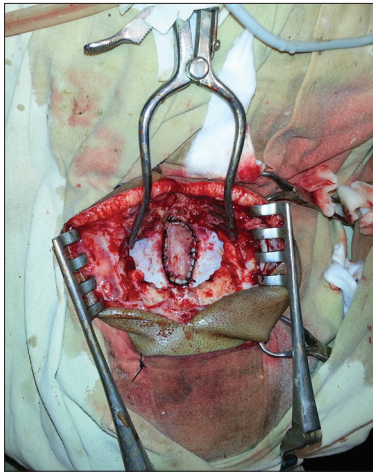
Three phases were described in pathogenesis of GSF. The first phase consists of mechanical trauma, which causes skull bone fracture with underlying dural tear. In the second phase, healing of the fracture margins is hindered by the presence of an intracranial hypertension syndrome and constant pulsation of the CSF, with invagination and entrapment of arachnoids

into a diastatic fracture. During the last phase, there is an important bone diastasis, associated with leptomeningeal herniation and elevated intracranial pressure.<sup>[4]</sup>

The osteodural defect enlarges due to leptomeningeal and brain tissue hernia through the defect, preventing apposition of bone. A progressive gliotic tissue occurs on the underlying brain tissue with a subsequent development of a porencephalic cavity.<sup>[5-8]</sup>

Noncontrast computed tomography with bone window is essential for diagnosis and planning an appropriate management.

The presence of CSF leak makes patient a potential candidate for getting a life threatening infection. Early surgery is the key to prevent this complication. Intraoperatively the dural defect is almost always bigger than the bony defect.<sup>[3,9-11]</sup> Dural margins should be explored first by bold craniectomy. Primary closure of dura should not be attempted especially in the posterior fossa as undue pressure may cause raised intracranial tension. Duraplasty using autologous material is



**Figure 5:** Dural repair using pericranial patch

recommended. Artificial patches of dura to be avoided in the settings of infection. Water tightness is checked by Valsalva maneuver. CSF is to be sent for microscopic and bacterial examination. Till then empirical broad spectrum antibiotics are to be administered.

## References

1. Robert O, Pittman T. youman's Neurological Surgery. 6<sup>th</sup> ed. Philadelphia: Elsevier; 2011. p. 2184-6.
2. Martínez-Lage JF, Martínez Pérez M, Domingo R, Poza M.

- Posttraumatic intradiploic arachnoid cyst of the posterior fossa. *Childs Nerv Syst* 1997;13:293-6.
3. Muhonen MG, Piper JG, Menezes AH. Pathogenesis and treatment of growing skull fractures. *Surg Neurol* 1995;43:367-72.
4. Drapkin AJ. Growing skull fracture: A posttraumatic neosuture. *Childs Nerv Syst* 2006;22:394-7.
5. Hayashi Y, Yamaki T, Odake G, Hashimoto Y, Ueda S. Long-term follow up of a growing skull fracture treated by dura and cranioplasty with artificial dura mater and methylmethacrylate. *Childs Nerv Syst* 1997;13:349-51.
6. Djientcheu VD, Rilliet B, Delavelle J, Argyropoulo M, Gudinchet F, de Tribolet N. Leptomeningeal cyst in newborns due to vacuum extraction: Report of two cases. *Childs Nerv Syst* 1996;12:399-403.
7. Zegers B, Jira P, Willemsen M, Grotenhuis J. The growing skull fracture, a rare complication of paediatric head injury. *Eur J Pediatr* 2003;162:556-7.
8. Ziyal IM, Aydin Y, Türkmen CS, Salas E, Kaya AR, Ozveren F. The natural history of late diagnosed or untreated growing skull fractures: Report on two cases. *Acta Neurochir (Wien)* 1998;140:651-4.
9. Ersahin Y, Gülmen V, Palali I, Mutluer S. Growing skull fractures (craniocerebral erosion). *Neurosurg Rev* 2000;23:139-44.
10. Singhal A, Steinbok P. Operative management of growing skull fractures: A technical note. *Childs Nerv Syst* 2008;24:605-7.
11. Gupta SK, Reddy NM, Khosla VK, Mathuriya SN, Shama BS, Pathak A, *et al.* Growing skull fractures: A clinical study of 41 patients. *Acta Neurochir (Wien)* 1997;139:928-32.

**How to cite this article:** Jain S, Gandhi A, Sharma A, Mittal RS. Growing skull fracture with cerebrospinal fluid fistula: A rare case report and its management strategies. *Asian J Neurosurg* 2015;10:229-31.

**Source of Support:** Nil, **Conflict of Interest:** None declared.