

## Case Report

# A Rare Case of Disseminated *Mycobacterium avium-intracellulare* Presenting as Proctitis

Chukwunonso Chime <sup>1,2</sup>, Peter Bhandari <sup>2</sup>, Masooma Niazi,<sup>3</sup> and Harish Patel <sup>1,2</sup>

<sup>1</sup>Division of Gastroenterology, BronxCare Hospital Center a Clinical Affiliate of Mt Sinai Health Systems and Academic Affiliate of Icahn School of Medicine, Bronx, NY 10457, USA

<sup>2</sup>Department of Medicine, BronxCare Hospital Center a Clinical Affiliate of Mt Sinai Health Systems and Academic Affiliate of Icahn School of Medicine, Bronx, NY 10457, USA

<sup>3</sup>Department of Pathology, BronxCare Hospital Center a Clinical Affiliate of Mt Sinai Health Systems and Academic Affiliate of Icahn School of Medicine, Bronx, NY 10457, USA

Correspondence should be addressed to Chukwunonso Chime; [cchime@bronxleb.org](mailto:cchime@bronxleb.org)

Received 10 September 2019; Accepted 27 September 2019; Published 3 December 2019

Academic Editor: Engin Altintas

Copyright © 2019 Chukwunonso Chime et al. This is an open access article distributed under the Creative Commons Attribution License, which permits unrestricted use, distribution, and reproduction in any medium, provided the original work is properly cited.

*Mycobacterium avium intracellulare* (MAI) infections are common in *Human Immuno-deficiency Virus* (HIV) positive patients. MAI infection can have localized or disseminated presentation, patients with low CD4 count presenting with disseminated infection. Fever, abdominal pain, diarrhea, and weight loss are generally the presenting symptoms of disseminated MAI. We present a rare case of a patient with HIV and low CD4 count presenting with proctitis as manifestation of disseminated MAI infection. A 25 year-old man with HIV came to the emergency room (ER) with complaints of intermittent rectal bleeding for two months. His CD4 count was less than 20 cells/ $\mu$ L. He was MSM (men having sex with men) and has receptive anal intercourse with men. His stool work-up was unrevealing for infectious etiology. Swabs for gonorrhea and chlamydia were negative. Colonoscopy revealed erythematous, congested, friable rectal mucosa with two superficial ulcers. Biopsies of the ulcer were positive for acid fast staining bacteria and the culture grew MAI. His blood culture was negative for growth of acid-fast bacteria (AFB). However, liver biopsy performed for elevated alkaline phosphatase of 958 units/L revealed noncaseating granuloma. Gastro-duodenoscopy with duodenal biopsy did not reveal any mucosal abnormality. He was managed as with disseminated MAI infection using clarithromycin, ethambutol, and rifabutin in addition to HAART therapy. Interval Colonoscopy in 20 months showed resolution of rectal ulcer. The gut is often involved in patients with disseminated MAI infection, with the duodenum being the most common site. MAI infection should be suspected as possible etiology for proctitis in HIV positive patient with low CD4 count, as proctitis, though infrequent can be the sole presentation for disseminated MAI infection in patients with HIV and low CD4 count.

## 1. Introduction

The association between *Mycobacterium avium intracellulare* (MAI) and acquired immune deficiency syndrome (AIDS) was identified in the 1980's [1]. Immune compromise status in general is a risk factor for acquiring MAI infection. The epidemic of MAI is concurrent to the AIDS epidemic [2] with a low CD4 count being a risk factor for acquiring MAI infection [3]. With advent of Highly Active Anti-Retroviral Therapy (HAART) there has been a control of MAI epidemic, however, nonadherence to HAART can decrease the CD4 count and hence increase susceptibility to MAI infection [4]. The

occurrence of MAI infection is relatively late in the course of the natural history of Human Immuno-deficiency Virus (HIV) infection [5] and with improvement in life expectancy in the era of HAART, there can be an increased frequency of MAI infections [5, 6].

MAI infection can present as a localized disease or a disseminated presentation, patients with AIDS being more prone to disseminated infection. Blood stream infection, lymph nodes, and liver infections are common in patients with disseminated MAI. Gastrointestinal manifestations are also common in patients with systemic MAI infections, the duodenum being the most common organ to be involved [7]. We present

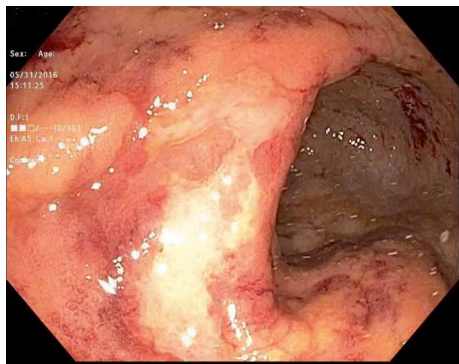


FIGURE 1: Rectal mucosal with ulcerations.

a case of a young male with AIDS presenting with proctitis and diagnosis of the disseminated MAI, successfully treated with triple combination therapy.

## 2. Case Presentation

A 25-year-old male presented to the emergency room (ER) with complaints of rectal bleeding, described as bright red blood on formed stool, for 2 months. His medical co-morbid condition includes a 7-year history of Human Immuno Deficiency Virus (HIV) infection, nonadherence to Highly Active Retroviral Therapy (HAART) with a CD4 count  $<20$  cells/ $\mu$ L and HIV viral load of 151,257 copies/mL. He is MSM (men having sex with men) and has receptive anal intercourse with men. He reported remote treatment for Genital Herpes. In the ER, his vitals were within normal limits and physical examination was unremarkable except for minimal right upper quadrant tenderness upon palpation and numerous tender perirectal ulcerations. Rectal examination revealed normal sphincter tone with empty but tender rectal vault. There was no peripheral lymphadenopathy.

Laboratory investigations showed haemoglobin of 10.4 g/dL, leukocyte count of 3.1 K cells/ $\mu$ L, platelet count of 339 K cells/ $\mu$ L, aminotransferase levels 3X ULN, total bilirubin levels of 7.0 mg/dL with conjugated bilirubin of 5.2 mg/dL, serum lactate dehydrogenase of 327 unit/L, serum gamma glutamyl transferase of 414 units/L, and alkaline phosphatase of 958 unit/L. Stool work up was negative for *Cryptosporidium*, *Cryptococcal* antigen, *Clostridium difficile*, *Cyclospora*, *Microsporidium*, and *Isospora*. No Ova and parasites isolated from stool studies. Blood cultures for regular pathogens acid-fast bacteria (AFB) were negative. Patient was admitted and colonoscopy performed to further identify the cause of rectal bleeding revealed diffusely erythematous, congested, friable rectal mucosa with two superficial ulcers (Figure 1). Biopsies were taken of the rectal mucosa as well as normal appearing proximal colon and terminal ileum. Rectal swabs were negative for chlamydia and gonorrhea. Pathology for rectal biopsy revealed AFB positive organism (Figures 2 and 3) and culture revealed growth of *Mycobacterium avium-intracellulare* (MAI) organisms. During this clinical course, he had an unremarkable upper endoscopy and was started on clarithromycin 500 mg BID, ethambutol 1200 mg QD, and rifabutin 300 mg QD in addition to HAART therapy.

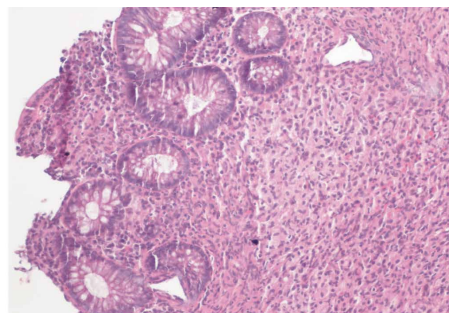


FIGURE 2: Rectal biopsy showing diffuse expansion of lamina propria with infiltration by lymphohistiocytic cells. (H and E, magnification  $\times 200$ ).

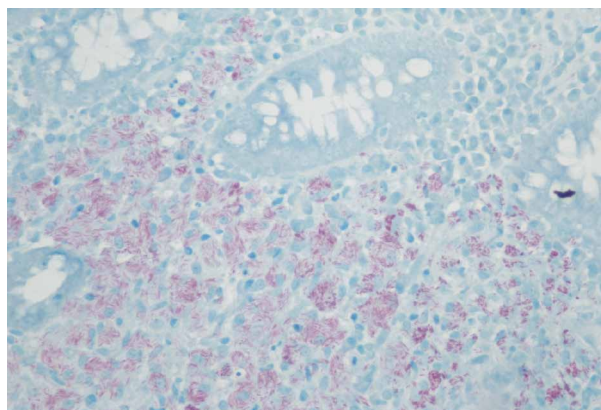


FIGURE 3: Rectal biopsy: acid fast staining showing sheets of macrophages packed with bundles of acid-fast bacilli, characteristic of *Mycobacterium avium intracellulare*. (Acid fast stain, magnification  $\times 400$ ).

Clinical presentation was highly suspected for disseminated MAI infection. Given negative blood culture, we further pursued evaluation of elevated alkaline phosphatase and performed liver biopsy. Pathology was reported to have necrotizing granulomas composed of lymphohistiocytic collections (Figure 4), highly suggestive of MAI infection. This confirmed our diagnosis of disseminated MAI. Patient was on and off the recommended regimen, flexible sigmoidoscopy after a short course of interrupted treatment again demonstrated similar initial findings in the rectum (Figure 5) but a follow up colonoscopy 20 months after diagnosis showed healing of rectal mucosa with negative biopsies for MAC. There was also a decreasing trend of alkaline phosphatase while on treatment, with last reported value of 218 unit/L.

## 3. Discussion

Nontuberculous Mycobacteria (NTM) are environmental organisms that are opportunistic in nature and under favorable conditions, cause a wide range of diseases ranging from pulmonary to disseminated infections, with the former being the most common [8]. Immune suppression is the typical predisposing factor and includes patients with HIV/AIDS, using

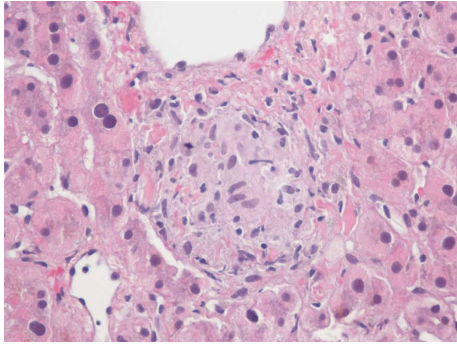


FIGURE 4: Liver biopsy with nonnecrotizing granuloma. Composed of lymphohistiocytic collections. (H and E, magnification  $\times 400$ ).

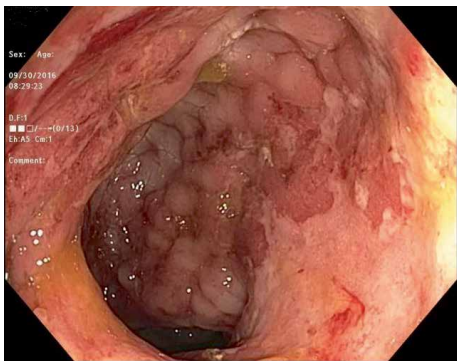


FIGURE 5: Friable rectal mucosa with edema (2 months after initiation of MAI treatment).

immunosuppressive therapy and undergoing solid organ or haematologic transplant [9]. A CD4 count below 50 cells/ $\mu$ L presents the highest risk for NTM infection and there has been suggestion of a genetic predisposition determined by human leukocyte antigen (HLA) class [10]. In the context of immune suppression, the vast majority of NTM cases are still *Mycobacterium avium complex* (MAC) but several factors lead to increased recognition of other species like *M. fortuitum*, *M. abscessus*, *M. chelonae*, and *M. haemophilium*, these include host factors and improved laboratory diagnostics [9]. In the United States, Tuberculosis (TB) has been overtaken by NTM as the predominant cause of mycobacterial lung disease [11].

Proctitis can be from infectious or noninfectious etiology. In MSM (men having sex with men) population, proctitis presents as sexually transmitted disease with gonorrhea being the most common infection [12]. MAI related proctitis is an uncommon presentation and it is not considered to be a sexually transmitted disease. Localized and disseminated disease are the two presentations of MAC in patients infected with HIV with the latter declining with increasing use of HAART [13]. Disseminated MAC present with malabsorption, rectal bleeding and loose stool when the gastrointestinal tract is involved [14], with the duodenum being the most commonly involved location in a case series [7]. In patients with advanced AIDS, MAI is one of the most common etiology of hepatic opportunistic infection [15]. It has a varied clinical manifestation ranging from granulomatous liver disease to presentation of a liver mass [16]. The increase in alkaline phosphatase

in our patient appears to arise from MAI induced granulomatous liver disease and with anti-microbial management for MAI, there was an interval decrease in alkaline phosphatase levels. Liver involvement is a sign of disseminated MAI infection. Once diagnosis of MAC is derived from liver biopsy, endoscopic work-up is usually not warranted to start anti-microbial treatment. Hence, there is literature to opine on the rates of rectal infection in conjunction with liver MAI involvement.

In general, cultures are the mainstay of diagnosis of infection with MAI. Blood cultures are preferred in disseminated cases as they are highly sensitive [13]. There is a role for stool culture in early diagnosis of patients with disseminated disease, especially in cases with confirmed gastrointestinal involvement, with sensitivity and specificity as high as 86% and 99% respectively [7, 17]. In our patient, stool culture was largely negative and did not reveal any opportunistic pathogen. Upper endoscopy and colonoscopy can aid in visual identification of any abnormalities in the mucosa and result in tissue specimens that can be stained and directly observed for acid fast bacilli present in the setting of noncaseating granuloma as was the case in our index patient. In patients with MAI colitis, erythema, friability, and ulcerations are commonly seen endoscopic findings [14], these were also noted in our patient and shown in Figures 1 and 5 above. A case of MAI presenting with severe gastrointestinal bleeding in a non HIV patient, diagnosed with colonoscopy with biopsy specimens staining positive for acid fast organisms, was described by Nguyen et al. [18].

In a nonHIV patient with extrapulmonary MAI, given that lack of consensus on the duration of treatment, a minimum duration of 6 months is usually adopted, meanwhile the pulmonary cases are tailored towards treatment for 12 months after sputum cultures have remained negative [19]. The main stay of treatment for MAI is with dual therapy comprising of ethambutol and macrolides, especially in patient with AIDS [13]. Some special circumstances that warrant a third agent include elevated mycobacterial burden, lack of antiretroviral therapy and patients with advanced immune compromise [20]. The preferred third agent is usually Rifabutin but other choices could be amikacin or fluoroquinolones like moxifloxacin and levofloxacin, these combinations are typically used for at least 12 months, preferably for minimum of 6 months after sustained CD4 count above 100 cells/ $\mu$ L [20].

Our patient was started on triple therapy, issues were encountered during his treatment course given his poor adherence. But after 20 months of therapy, he had clinical and endoscopic cure of his MAI proctitis. He is currently on treatment for the MAI, concurrent with his HAART given that his CD4 count is still not at target.

#### 4. Conclusion

Disseminated MAI with gastrointestinal involvement should always be considered as a cause of lower gastrointestinal bleeding, in patients with immune compromise. The findings, including friability, and ulcerations, are nonspecific and can be seen in other clinical entities that include but are not limited to inflammatory bowel disease and cytomegalovirus colitis,

both of which are commonly seen with immune deficiency. Biopsy with special stains helps to identify MAI as the causative organism. Treatment will depend on immune status and location, with extra pulmonary cases like our index case requiring at least 12 months of treatment. Given the correlation between this opportunistic pathogen and low CD4 count in the HIV patients, concurrent treatment with HAART is also warranted.

## Consent

Patient provided informed consent for publication of this report and the accompanying images.

## Conflicts of Interest

The authors declare that they have no conflict of interest.

## Authors' Contributions

All authors have reviewed the literature and contributed to manuscript drafting. Chukwunonso Chime and Peter Bhandari were responsible for the revision of the manuscript for important intellectual content. Masooma Niazi has reviewed patient slides and legends for the pathology figures. Harish Patel has critical reviewed manuscript and figures. All authors issued final approval for the version to be submitted.

## References

- [1] J. A. Havlik Jr., C. R. Horsburgh, B. Metchock, P. P. Williams, S. A. Fann, and S. E. Thompson, "Disseminated *Mycobacterium avium* complex infection: clinical identification and epidemiologic trends," *Journal of Infectious Diseases*, vol. 165, no. 3, pp. 577–580, 1992.
- [2] C. R. Horsburgh and R. M. Selik, "The epidemiology of disseminated nontuberculous mycobacterial infection in the acquired immunodeficiency syndrome (AIDS)," *American Review of Respiratory Disease*, vol. 139, no. 1, pp. 4–7, 1989.
- [3] J. Chiu, "Treatment of disseminated *Mycobacterium avium* complex infection in AIDS with amikacinethambutol, rifampin, and ciprofloxacin. California collaborative treatment group," *Annals of Internal Medicine*, vol. 113, no. 5, p. 358, 1990.
- [4] C. Fortin and D. Rouleau, "Cerebral *Mycobacterium avium* abscesses: late immune reconstitution syndrome in an HIV-1-infected patient receiving highly active antiretroviral therapy," *The Canadian Journal of Infectious Diseases & Medical Microbiology*, vol. 16, no. 3, pp. 187–189, 2005.
- [5] C. R. Horsburgh, "*Mycobacterium avium* complex infection in the acquired immunodeficiency syndrome," *The New England Journal of Medicine*, vol. 324, no. 19, pp. 1332–1338, 1991.
- [6] J. Hoy, A. Mijch, M. Sandland, L. Grayson, R. Lucas, and B. Dwyer, "Quadruple-drug therapy for *Mycobacterium avium-intracellulare* bacteremia in AIDS Patients," *Journal of Infectious Diseases*, vol. 161, no. 4, pp. 801–805, 1990.
- [7] J. R. Gray and L. Rabeneck, "Atypical mycobacterial infection of the gastrointestinal tract in AIDS patients," *The American Journal of Gastroenterology*, vol. 84, no. 12, pp. 1521–1524, 1989.
- [8] L. Zhang, W. M. Lin, H. Li et al., "Hepatic nontuberculous mycobacterial granulomas in patients with cancer mimicking metastases: an analysis of three cases," *Quantitative Imaging in Medicine and Surgery*, vol. 9, no. 6, pp. 1126–1131, 2019.
- [9] E. Henkle and K. L. Winthrop, "Nontuberculous mycobacteria infections in immunosuppressed hosts," *Clinics in Chest Medicine*, vol. 36, no. 1, pp. 91–99, 2015.
- [10] E. Naik, S. LeBlanc, J. Tang, L. P. Jacobson, and R. A. Kaslow, "The complexity of HLA class II (DRB1, DQB1, DM) associations with disseminated *Mycobacterium avium* complex infection among HIV-1-seropositive whites," *Journal of Acquired Immune Deficiency Syndromes*, vol. 33, no. 2, pp. 140–145, 2003.
- [11] D. R. Prevots, P. A. Shaw, D. Strickland et al., "Nontuberculous mycobacterial lung disease prevalence at four integrated health care delivery systems," *American Journal of Respiratory and Critical Care Medicine*, vol. 182, no. 7, pp. 970–976, 2010.
- [12] J. D. Klausner, R. Kohn, and C. Kent, "Etiology of clinical proctitis among men who have sex with men," *Clinical Infectious Diseases*, vol. 38, no. 2, pp. 300–302, 2004.
- [13] J. A. Gonzales Zamora and C. Milikowski, "Proctitis caused by *Mycobacterium avium-intracellulare* in an HIV-infected patient," *Diseases*, vol. 6, no. 2, p. 36, 2018.
- [14] C. Keller, S. Kirkpatrick, K. Lee, M. Paul, I. C. Hanson, and M. Gilger, "Disseminated *Mycobacterium avium* complex presenting as hematochezia in an infant with rapidly progressive acquired immunodeficiency syndrome," *The Pediatric Infectious Disease Journal*, vol. 15, no. 8, pp. 713–715, 1996.
- [15] J. C. Price and C. L. Thio, "Liver disease in the HIV-infected individual," *Clinical Gastroenterology and Hepatology*, vol. 8, no. 12, pp. 1002–1012, 2010.
- [16] M. Bonacini, "Hepatobiliary complications in patients with human immunodeficiency virus infection," *The American Journal of Medicine*, vol. 92, no. 4, pp. 404–411, 1992.
- [17] T. J. Hellyer, I. N. Brown, M. B. Taylor, B. W. Allen, and C. S. F. Easmon, "Gastro-intestinal involvement in *Mycobacterium avium-intracellulare* infection of patients with HIV," *Journal of Infection*, vol. 26, no. 1, pp. 55–66, 1993.
- [18] H. N. Nguyen, D. Frank, S. Handt et al., "Severe gastrointestinal hemorrhage due to *Mycobacterium avium* complex in a patient receiving immunosuppressive therapy," *The American Journal of Gastroenterology*, vol. 94, no. 1, pp. 232–235, 1999.
- [19] D. E. Griffith, T. Aksamit, B. A. Brown-Elliott et al., "An official ATS/IDSA statement: diagnosis, treatment, and prevention of nontuberculous mycobacterial diseases," *American Journal of Respiratory and Critical Care Medicine*, vol. 175, no. 4, pp. 367–416, 2007.
- [20] J. E. Kaplan, J. E. Kaplan, C. Benson et al., "Guidelines for prevention and treatment of opportunistic infections in HIV-infected adults and adolescents: recommendations from CDC, the national institutes of health, and the HIV medicine association of the infectious diseases society of America," *MMWR Recommendations and Reports*, vol. 58, no. RR-4, pp. 1–207, 2009, Quiz CE1-4.