

Case Series

Finger-guided Heller cardiomyotomy procedure to prevent the recurrence of esophageal achalasia in patients who are not qualified for laparoscopy: A case series



Adeodatus Yuda Handaya^{a,*}, Aditya Rifqi Fauzi^b

^a Division of Digestive Surgery, Department of Surgery, Dr. Sardjito Hospital/Faculty of Medicine, Public Health, and Nursing, Universitas Gadjah Mada/Yogyakarta, Indonesia

^b Faculty of Medicine, Public Health, and Nursing, Universitas Gadjah Mada, Yogyakarta, Indonesia

ARTICLE INFO

Article history:

Received 18 May 2018

Received in revised form 30 June 2018

Accepted 11 July 2018

Available online 25 July 2018

Keywords:

Esophageal achalasia

Finger-guided esophagocardiomyotomy

Prevention

Laparoscopy

Case series

ABSTRACT

INTRODUCTION: Achalasia is usually found in young adults with an incidence of 1 in 100,000 population. Symptoms include regurgitation, burning and substernal pain, weight loss, may also include a complete sense of fullness in the substernal region and persistent vomiting. The laparoscopy Heller cardiomyotomy and partial fundoplication have become the procedure of choice for surgical management of achalasia.

PRESENTATION OF CASE: We report 6 cases, 4 males and 2 females with chief complaints were dysphagia. All patients displayed comorbidities. We performed a finger-guided Heller cardiomyotomy. All surgeries resulted in minimal intraoperative bleeding. Patients experienced neither leakage, postoperative fistula, dysphagia, nor postoperative reflux. One month after surgery, no patient experienced recurrence of their complaints.

DISCUSSION: Since not all esophageal achalasia patients can undergo laparoscopy as the main treatment method due to some comorbidities, we did a modified technique of Finger-guided Heller cardiomyotomy to treat the patients.

CONCLUSION: Finger-guided Heller cardiomyotomy for the treatment of esophageal achalasia in patients who are not qualified for laparoscopy due to comorbid factors can be considered to be an alternative treatment because the procedure is relatively easier, has fewer complications, and can prevent the recurrence of the disease.

© 2018 The Authors. Published by Elsevier Ltd on behalf of IJS Publishing Group Ltd. This is an open access article under the CC BY-NC-ND license (<http://creativecommons.org/licenses/by-nc-nd/4.0/>).

1. Introduction

Esophageal achalasia, cardia achalasia, cardiospasm or aperistalsis esophagus involve a disorder of esophageal motility in the smooth muscle layers of the esophagus and lower esophageal sphincter (LES), making it unable to open and let food into the stomach. It is characterized by incomplete LES relaxation, increased LES tone, and lack of peristaltic movement in the esophagus in the absence of other abnormalities such as cancer or fibrosis. Achalasia patients feel the need to encourage or force the passage of food with water or drinking fluids to complete the process of swallowing. Other clinical symptoms may include a complete sense of fullness in the substernal region or obstruction and acute reflux with regurgitation [1,2]. Achalasia is reported to have an annual incidence of 1 per 100,000 population worldwide. Prevalence is

about 10.8 per 100,000 population [3,4]. Diagnosis of achalasia is based on clinical symptoms, radiologic features, esophagoscopy and manometric measurements. The nature of the therapy is only palliative because the peristaltic function of the esophagus cannot be recovered. Treatment can be done by administering high-calorie diet, medicamentosa, pneumatic dilatation and appropriate surgical procedures [5,6]. The usual clinical symptom is dysphagia. Usually, the liquid food or drinks are more difficult to swallow than solid ones. The course of the disease is usually chronic with progressive dysphagia.

The severity of dysphagia according to the British Oesophageal Surgery is divided into five levels as follows: (a) Level 0: normal; (b) Level 1: cannot swallow solid food; (c) Level 2: cannot swallow fine meat; (d) Level 3: cannot swallow soup or liquid food; (e) Level 4: cannot swallow saliva. The relative symptoms are regurgitation, burning and substernal pain, weight loss, may also include a complete sense of fullness in the substernal region or obstruction and acute reflux with regurgitation is due to food retention, and persistent vomiting.

* Corresponding author.

E-mail address: yudahandaya@ugm.ac.id (A.Y. Handaya).

We conducted a case report study with the subjects are patients from secondary and tertiary hospitals in Yogyakarta, Indonesia. The subjects are achalasia patients who are having comorbid conditions so that laparoscopy surgery cannot be undergone. Comorbid conditions that become contraindications for laparoscopy surgery are pulmonary disease, cardiovascular disease, intracranial disease, coagulopathy, pregnancy, and shock [7]. This case series is an operator experience as a digestive surgeon. This research work has been reported in line with the PROCESS criteria [11].

2. Case reports

2.1. Case 1

A 73-year old male patient was referred by a gastroenterologist for having a complaint about swallowing food and drink. The patient had an endoscopy, and the results were within normal limits, while the oesophagus-maag-duodenum (OMD) showed a feature of esophageal dilatation (megaesophagus) or a bird-beak appearance. The patient also suffered from pneumonia and was under treatment of a pulmonologist. Pneumonia is a contraindication for laparoscopy surgery. The patient underwent laparotomy with finger-guided Heller cardiomyotomy and Toupet fundoplication surgery. The length of the operation was 45 min with minimal bleeding. Eight hours post-operative the patient could drink water. After the first day, the patient could eat porridge. On the third day, the patient was allowed to go home.

2.2. Case 2

A 54-years old female patient came to the polyclinic with complaints of weight loss, frequent shortness of breath, difficulty to eat and drink, and sometimes nausea. The patient underwent esophagogastroduodenoscopy (EGD), and the result showed no tumor. In the esophagography, there was found a bird-beak feature. The patient was already given botulinum toxin injection and balloon dilatation by the gastroenterologist six times, but the complaints still persisted and patient's weight continues to fall. The recurrence and ongoing weight loss were becoming indication for Finger-guided Heller cardiomyotomy procedure Then the patient underwent the operation, and eight hours post-operative the patient could drink water. On the second day, the patient could eat porridge, then on the following day, the patient was discharged from the hospital.

2.3. Case 3

A 48-year-old male patient came to polyclinic with complaints of a distended abdomen, with difficulty to swallow food and drink. In the physical examination, spleen enlargement was found as high as the umbilicus (Schuffner grade 4). The patient underwent abdominal ultrasonography (USG), and the results showed splenomegaly. A history of malaria 10 years earlier was found in this patient. The patient also often felt shortness of breath and was treated by a cardiologist as a congestive heart failure. In an esophagography examination, a bird-beak appearance was found. Then the patient underwent abdominal CT scan, the result showed splenomegaly, and no mass was found in the esophagogastric junction. As the patient was having congestive heart failure, it becomes contraindication for laparoscopy surgery. The patient then underwent finger-guided Heller cardiomyotomy and Toupet fundoplication, and a splenectomy was also performed. Duration of the operation was 110 min, and bleeding volume was estimated 100 cc. Eight hours after surgery, the patient could drink water. On

the second day, the patient could eat porridge, and on the fifth day, the patient was discharged.

2.4. Case 4

A 64-year-old male patient came to polyclinic with complaints of difficulty to swallow food and drink. He was a post-stroke patient with weakness in the right limbs, The EGD examination showed narrowing in the esophagogastric junction, and bird-beak appearance was found. Endoscopy examination was performed and showed no tumor mass, and the scope was able to enter the duodenum. The patient suffered from pneumonia due to excessive bed rest. As the patient was diagnosed with pneumonia and intracranial disease (stroke), it becomes contraindications for laparoscopy surgery. Achalasia surgery was done with open laparotomy finger-guided Heller myotomy and Toupet fundoplication. Duration of the operation was 55 min with minimal bleeding. Eight hours postoperative the patient could drink water. On the second day, the patient could eat porridge. A joint treatment and evaluation in conjunction with a neurologist for stroke and neurologic evaluation were made. On the sixth day, the patient was discharged from the hospital.

2.5. Case 5

A 55-year-old female patient came to polyclinic with the complaints of the difficulty of swallowing, in addition to anemia and hypertension diagnosis. Esophagography was performed and the result showed esophageal dilation, a feature of the sigmoid esophagus and bird-beak appearance, with constriction of the esophagogastric junction. A differential diagnosis of tumor on the esophagogastric junction was made. To confirm it, we performed abdominal CT scan, and no tumor mass was found. Esophagogastroduodenoscopy was also performed, and the result found a narrowing of the esophagogastric junction. The scope was able to enter stomach and duodenum, and no tumor mass was found. Anemia and hypertension are physiologic contraindications for laparoscopy surgery. Then explorative laparotomy surgery, Finger-guided Heller cardiomyotomy were done, with Toupet fundoplication. Duration of the operation was 60 min with minimal bleeding volume. Eight hours postoperative the patient could drink water. On the second day, the patient could eat porridge. On the fourth day, the patient was discharged from the hospital.

2.6. Case 6

A 43-year-old male patient came to polyclinic with complaints of the difficulty of eating, drinking, and weight loss. The patient came carrying oesophagomaagduodenography (OMD) results from the previous hospital with a diagnosis of suspected achalasia with a differential diagnosis of distal esophageal carcinoma. CT scan and endoscopic examination were performed and the results were within normal limits. The patient had a history of pulmonary tuberculosis treatment. Pulmonary disease is a contraindication for laparoscopy. Laparotomy finger-guided Heller cardiomyotomy with Toupet fundoplication was performed. The duration of the operation was 45 min with minimal bleeding. The patient was evaluated 2 weeks postoperative and showed that he could eat and drink without any complaints. 6 months after surgery the patient had a weight gain of 5–10 kg.

The authors attest that full and informed consent was obtained from every single patient who have undergone medical treatment in our Hospital. The informed consent form also declared that patient data or samples will be used for educational or research purposes. This work has been registered in the a publicly accessible database and having a unique identifying number : researchregistry4073.

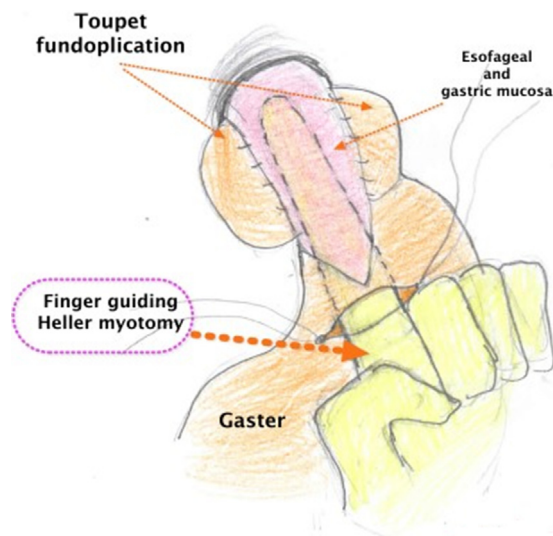


Fig. 1. Finger-guided Heller Cardiomyotomy and Toupet Fundoplication.

Finger-guided Heller Cardiomyotomy Procedure:

- 1 First, we performed surgical procedure under general anesthesia.
- 2 We made an upper midline incision.
- 3 Then we did a general exploration of the abdomen while was paying attention to the esophagogastric junction;
- 4 We mobilized the left hemiliver by dividing the triangular ligament to expose the lower esophagus;
- 5 Then, we divided the small bands between the stomach and spleen to avoid tearing of the splenic capsule and divide the peritoneum over the esophagus, then retracted the stomach downward;
- 6 We divided the gastro-hepatic ligament, phrenoesophageal ligaments and excised the esophageal fat pad and crus medial and lateral diaphragm to allow downward mobilization of the esophagogastric junction;
- 7 A 1.5 cm incision at the gastric corpus was made and then we inserted an index finger through the incision that has been made into gastric lumen, continued to esophagogastric junction, then into esophagus. We then felt the constricted (spasmodic) lumen.
- 8 With finger guiding, we divided all the circular and longitudinal muscle fibers to make the myotomy above the area of constriction until the esophageal mucosa is visible.
- 9 The myotomy incision was extended 4 cm into the esophagus and 2 cm into the gastric cardia to reduce outflow resistance.
- 10 The evaluation was done by feeling with the finger that the distal esophagus is loosened and the muscle spasm is released then we gave normal saline liquid through the nasogastric tube into the esophagus by closing the cardia area to ensure no mucosal leakage and the mucosa should have been seen bulged. The illustration of the technique is shown in Fig. 1.

3. Discussion

Achalasia is usually found in young adults, although there are cases also found in infants but is very rare in old age. It has a small incidence in children younger than 16 years, with 0.18 per 100,000 people per year, while in adults, the mean age at diagnosis is over 50 years [8]. The mean age of our cases was 56.6 ± 10.9 years (range 43–73 years old).

Treatment options for esophageal achalasia are divided into surgical and non-surgical. The non-surgical treatment using medicamentosa by giving a smooth muscle relaxant like sublingual

nitroglycerin or sublingual nifedipine can help the LES to relax and reduce the symptoms. Botulinum toxin injection intra-sphincter may also be used to relieve achalasia symptoms by inhibiting the release of acetylcholine. This technique was reported to be able to decrease dysphagia complaints in 66% patients for 6 months. Pneumatic dilatation has also been a major form of therapy for achalasia. A balloon is inflated in the esophagogastric junction (EGJ) aiming to retain the muscle fiber and make the mucosa intact. This method's efficacy was reported by 62%–90% [3,6,9].

The laparoscopy Heller cardiomyotomy and partial fundoplication have become the procedure of choice for surgical management of achalasia. The patients who underwent this procedure were admitted to hospital for 24–48 h and can return to daily activity after 2 weeks. Currently, many surgeons use the laparoscopic procedure to treat achalasia, and more than 90% cases reported successful recovery, but this procedure was contraindicated in patients who are having hiatal hernia, bleeding, pneumothorax, infectious injury, ileus, and trauma to the spleen [6].

Our operations duration was average for 62.5 ± 24.2 min (range 45–110 min). For a comparison, a single centered study by Fernandez et al. observed operation duration in laparoscopy surgery of esophageal achalasia was average for 138 min (range 67–300 min) in his 6-years-experience [10]. This was a significant operative time reduction.

Although in the current modern era, the minimally invasive surgery like laparoscopic surgery technique is growing rapidly, the surgeon should have specific knowledge regarding any preexisting contraindications in the patient. Laparoscopy contraindication can be divided into relative and absolute. Adhesions of organs to the peritoneal cavity become absolute contraindication for laparoscopy because adhesions decrease the peritoneal working space and hinder visibility. The relative contraindications were also divided into anatomic and physiologic contraindications. The relative anatomic contraindications include obesity, cirrhosis, small bowel obstruction, septic peritonitis, disseminated abdominal cancer, and aberrant anatomy, while the physiologic ones are coagulopathy, pregnancy, shock, or a disease of intracranial, pulmonary or cardiovascular [12]. All of our patients have comorbidity of cardiovascular and/or pulmonary diseases so that primary concerns were the relative contraindications to perform laparoscopic surgery on these patients.

Several complications associated with this surgical approach were observed. One of them is inadequate myotomy, and this complication is one of the most important and preventable and could lead to poor esophageal emptying and recurrent dysphagia. The challenge is creating a balance between performing adequate myotomy to relieve obstruction while minimizing the risk of gastroesophageal reflux. Another cause of recurrent dysphagia is adequate myotomy but failure to separate the muscle edges to prevent scar forming which can lead to the impaired emptying of the esophagus. Gastroesophageal reflux also could occur after myotomy, but to date, the addition of anti-reflux procedures showed a reduction of acid exposure to the esophagus. One study showed a significant decrease in reflux with the incidence of 9% of the cases using Dor fundoplication compared to 48% in myotomy alone. Another complication of myotomy was also a postoperative leakage with symptoms of fever or chest pain. CT scan is a useful diagnostic tool to see any feature of leakages such as water-fluid levels near the hiatus or air bubbles in the mediastinum [11]. Incomplete myotomy, especially on the gastric side (where myotomy is more difficult), scarring of myotomy, and too-tight anti-reflux bonds are thought to be the cause of treatment failure [8].

The purpose of this report is to present our experience in managing achalasia patients with comorbid diseases who are not qualified for laparoscopic procedure, with some technical modifications to

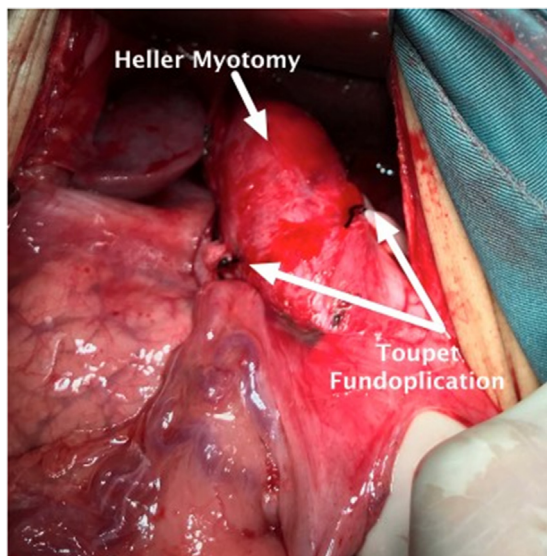


Fig. 2. Toupet fundoplication.

minimize the rate of complications. We added two steps: where finger guiding was used while we divided all the circular and longitudinal fibers to make the myotomy, and to evaluate whether the distal esophagus was loosened and the muscle spasm was released and Toupet fundoplication as seen in Fig. 2. All of our patients have their complaints relieved in postoperative follow-up without reflux symptom.

4. Conclusion

Surgery of extra-mucosa esophagocardiomyotomy by inserting the index finger towards the LES to ensure LES patency and Toupet fundoplication is an option in esophageal achalasia therapy. The periodic follow-up of postoperative patients showed safe procedure with no symptoms of recurrence and reflux. In the future, we need to do a bigger scale of research so that this technique can become a technical report.

Conflict of interest

No potential conflict of interest relevant to this article was reported.

Funding

The authors declare that this study had no funding resource.

Ethical approval

The informed consent form was declared that patient data or samples will be used for educational or research purposes. Our institutional review board also do not provide an ethical approval in the form of case report.

Open Access

This article is published Open Access at [sciencedirect.com](https://www.sciencedirect.com). It is distributed under the [IJSCR Supplemental terms and conditions](#), which permits unrestricted non commercial use, distribution, and reproduction in any medium, provided the original authors and source are credited.

Consent

Written informed consent was obtained from the patient for publication of this case report and accompanying images. A copy of the written consent is available for review by the Editor-in-Chief of this journal on request.

Author contribution

Adeodatus Yuda Handaya conceived the study. Aditya Rifqi Fauzi drafted the manuscript and critically revised the manuscript for important intellectual content. Adeodatus Yuda Handaya and Aditya Rifqi Fauzi facilitated all project-related tasks.

Registration of research studies

researchregistry4073.

Guarantor

Adeodatus Yuda Handaya is the guarantor of the study.

Acknowledgments

We thank patient family, the surgical team and the nursing staff who were involved in the surgery and patients care.

References

- [1] W. Park, M.F. Vaezi, Etiology and pathogenesis of achalasia: the current understanding, *Am. J. Gastroenterol.* 100 (2005) 1404–1414.
- [2] S.J. Spechler, D. Castell, Classification of oesophageal motility abnormalities, *Gut* 49 (2001) 145–151.
- [3] J.E. Pandolfino, A.J. Gawron, Achalasia: a systematic review, *JAMA* 313 (18) (2015) 1841–1852.
- [4] Z. Arora, P.N. Thota, M.R. Sanaka, Achalasia: current therapeutic options, *Ther. Adv. Chronic Dis.* (2016) 1–6.
- [5] P.J. Lamb, S.M. Griffin, The anatomy and physiology of the esophagus, in: J.W.L. Fielding, M.T. Hallisey (Eds.), *Upper Gastrointestinal Surgery*, Springer, 2005, pp. 1–16.
- [6] M. Vierra, L. Heller Myotomy, *Monterey County Surgical Associates*, 2018, pp. 1–5.
- [7] N.J. Buote, J.K. McClaran, Laparoscopic contraindications, complications, and conversion, in: B.A. Fransson, P.D. Mayhew (Eds.), *Small Animal Laparoscopy and Thoracoscopy*, 1st ed., John Wiley & Sons, Inc., 2015, pp. 93–101.
- [8] G.E. Boeckxstaens, G. Zaninotto, J.E. Ritcher, Achalasia [Internet], 2018, [http://dx.doi.org/10.1016/S0140-6736\(13\)60651-0](http://dx.doi.org/10.1016/S0140-6736(13)60651-0), Available from:.
- [9] S.K. Chuah, P.I. Hsu, K.L. Wu, D.C. Wu, W.C. Tai, C.S. Changchien, 2011 update on esophageal achalasia, *World J. Gastroenterol.* 18 (14) (2012).
- [10] A.F. Fernandez, M.A. Martinez, J. Ruiz, R. Torres, B. Faife, J.R. Torres, et al., Six years of experience in laparoscopic surgery of esophageal achalasia, *Surg. Endosc.* 17 (2003) 153–156.
- [11] A.E. Luckey, S.R. DeMeester, Complications of achalasia surgery, *Thorac. Surg. Clin.* 16 (2006) 95–98.
- [12] R.A. Agha, A.J. Fowler, S. Rammohan, I. Barai, D.P. Orgill, PROCESS Group, The PROCESS statement: preferred reporting of case series in surgery, *Int. J. Surg.* 36 (Pt. A) (2016) 319–323.