

Trauma and reconstruction

Calcified retained intrauterine device in the setting of a vesicovaginal fistula



Jillian R. Scambia^{a,*}, Lindsay Lombardo^{a,b}, Mark A. Wille^a, Patricia Vidal^a, Courtney M.P. Hollowell^a, Traci P. Beck^a

^a Division of Urology, John H. Stroger, Jr. Hospital of Cook County, Chicago, IL, USA

^b Division of Urologic Surgery, Saint Louis University School of Medicine, Saint Louis, MO, USA

ARTICLE INFO

Article history:

Received 10 January 2018

Accepted 21 January 2018

Available online 31 January 2018

Keywords:

Vesicovaginal fistula

Intrauterine device

Transabdominal fistula repair

Vaginal foreign bodies

1. Introduction

A patient with a complicated medical history including: pelvic malignancy, acute vaginal bleeding, chronic incontinence, pelvic external radiation therapy, and a history of an intrauterine device (IUD), presents for a challenging diagnosis. A detailed physical exam, imaging, cystoscopy and vaginostomy were all important tools to evaluate and treat the patient's conditions.

1.1. Case presentation

A 64-year-old female was admitted from the emergency department after experiencing profuse vaginal bleeding while on anticoagulation for atrial fibrillation. She had previously experienced intermittent vaginal spotting. Her medical history was also significant for cervical cancer treated with external beam radiation therapy, breast cancer treated with lumpectomy, hypertension, urinary incontinence, and chronic urinary tract infections. The cervical cancer was treated 17 years prior to presentation and

believed to be in remission. Her only other known gynecological treatment was remote placement of IUD and she reported that it was removed prior to her radiation therapy.

Physical exam was benign except for the pelvic exam that revealed blood in the vaginal canal, and a stricture 2 cm from the introitus, which was approximately 1 cm in diameter. A five centimeter solid mass was appreciated on bimanual exam. There was a small protruding extension of the solid mass on palpation of the center of the vaginal stricture.

Computed tomography (CT) abdomen and pelvis was performed with and without contrast. An irregular, enhancing mass seen along the posterior left urinary bladder wall concerning for local extension of the patient's known primary carcinoma. Diffuse, enhancing mass-like thickening of the posterior wall of the urinary bladder measuring 4.4 cm × 2.8 cm was noted (Fig. 1). The bladder wall demonstrated thickening with mild perivesicular fat stranding and there were small pockets of intraluminal air in the nondependent portion of the bladder as well. Radiopaque material within the lower uterine segment and cervix was also identified (Fig. 2). Additionally, there was mild right hydronephrosis and moderate renal cortical scarring.

The physical exam and imaging alone did not reveal the etiology of the solid mass and the patient was taken to the operating room (OR) by gynecology to perform a more thorough vaginal exam, which exposed a fused and shortened vagina consistent with radiation treatment. At the top of the vagina, a fistula with urine leakage was noted, and it appeared that a plastic cannula emerged through the fistula. At this point, urology was consulted and performed cystoscopy revealing a large vesicovaginal fistula (VVF). Vaginostomy was also performed and an object was identified in the vaginal canal consistent in appearance with a calcified string of an IUD. The left ureteral orifice was identified and a retrograde pyelogram was performed and revealed no hydronephrosis, extravasation or filling defects. Methylene blue was administered and the right ureteral orifice could not be identified. The mass identified on CT was correlated during cystoscopy as inflamed tissue around the fistula tract. This tissue was biopsied and pathology identified squamous mucosa with acute and chronic inflammation, parakeratosis, hyperkeratosis and a stromal fragment with dilated

* Corresponding author. John H. Stroger, Jr. Hospital of Cook County 1900 W. Polk Street, Suite 465 Chicago, IL 60612, USA.

E-mail address: jscambia@cookcountyhhs.org (J.R. Scambia).

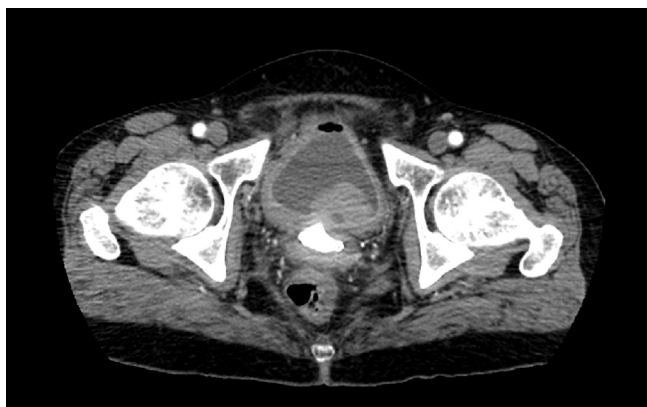


Fig. 1. CT, transverse section, showing both the irregular enhancing bladder mass and radiopaque material in the vaginal canal.

vessels and few adherent benign epithelial cells.

The patient returned to the OR during this admission and after gentle digital dilation of the vaginal stricture polyp forceps were introduced. This allowed the calcified mass to be broken and then removed in pieces from the vaginal canal. Within the calcified mass was a Lippes Loop IUD (Fig. 3).

Shortly after discharge the patient went to the OR with urology for transabdominal VVF repair and right ureteral reimplantation with psoas hitch. She had an uneventful post-operative course and after two years of outpatient follow up, patient continues to report resolution of vaginal bleeding and urinary incontinence.

2. Discussion

The Lippes Loop was the most widely prescribed IUD in 1962

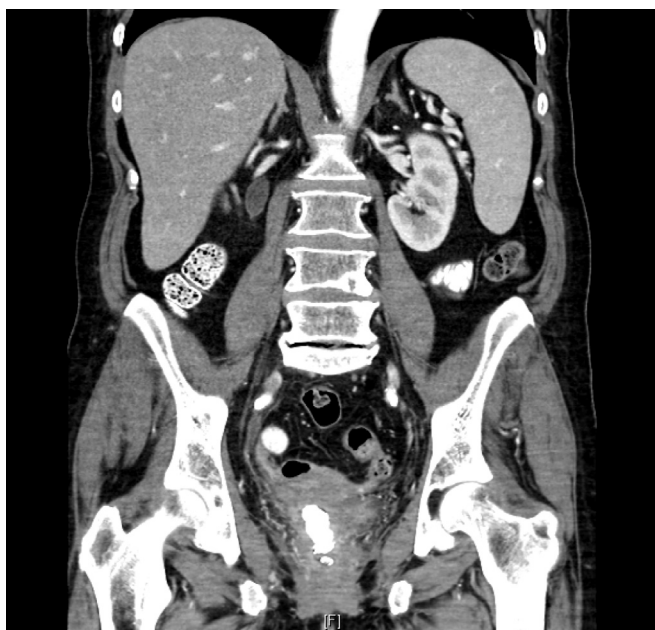

Fig. 2. CT, coronal section, showing linear radiopaque material in the vaginal canal with a smaller distal extension.

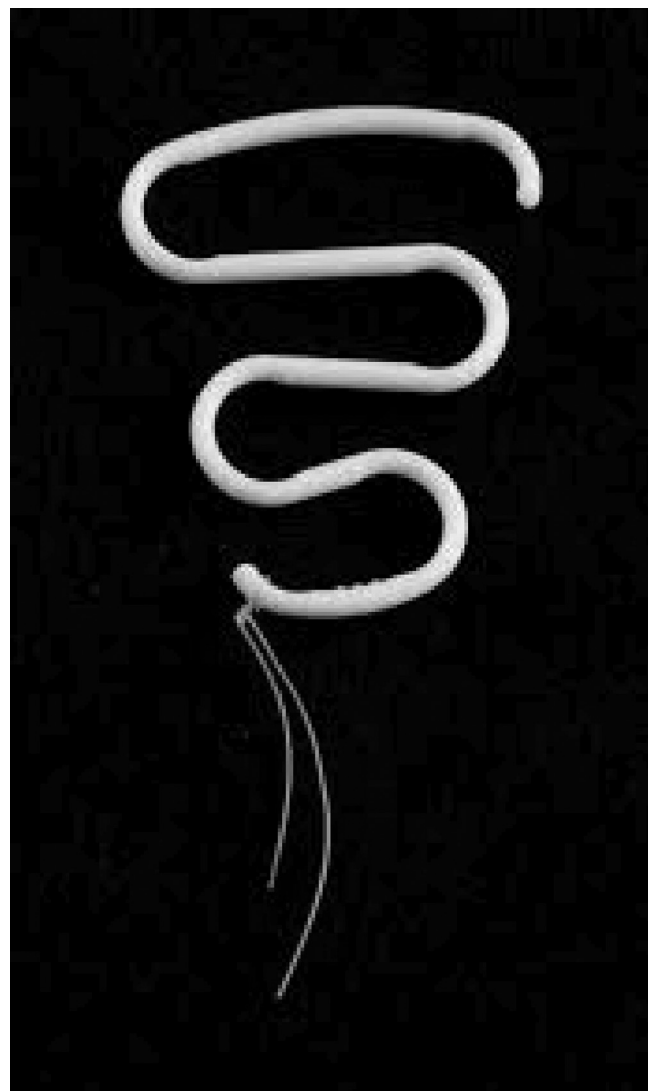


Fig. 3. Lippes loop intrauterine device.

when it began distribution.¹ Since that time, inert IUDs are no longer utilized in the United States and newer devices have replaced them. Perforation of an IUD is exceedingly rare, occurring in approximately 1 out of 1000 insertions, and fewer than 10% are expelled, generally in the first year after placement.² Currently there is no consensus for the safe length of use of inert IUD under normal circumstances, but it is generally advised to remove the device one-year post menopause.¹ Risks of neglecting an IUD include migration, infection, and calcification.

This patient has a very complicated medical history with three factors that may have contributed to the formation of VVF: radiation therapy, malignancy, and foreign body, which are all known causes of fistula. However, considering the irregular mass in the bladder and the fact that the patient was told the IUD was removed 17 years early, making the diagnosis was difficult.

External beam radiation therapy to the pelvis certainly played a role in the decreased integrity of the pelvic tissue and contributed to the unfortunate series of complications. Vaginal stenosis is present in as many as 62% of women following pelvic radiation therapy.³ This patient's vaginal stenosis had a less than 1 cm opening, making complete expulsion of the IUD very difficult.

VVF is much less common in the developed world than it is in

the developing world, and approximately 13% of genitourinary fistulas can be attributed to iatrogenic causes.⁴ In this patient, proper follow up may have made the difference of detecting the expelled IUD at an earlier time. When an IUD migrates, it can cause debilitating symptoms such as seen in our patient with chronic urinary tract infections, vaginal bleeding, and chronic urinary incontinence.

3. Conclusion

There are only a few cases of VVF due to a foreign body in the vagina reported in the literature. This patient had a history of malignancy, radiation and foreign body, all known causes of fistula formation. A complicated medical history with unclear details regarding management made diagnosis and treatment of this patient very challenging. Imaging can be helpful to determine the relevant anatomical defects however; a thorough physical exam is essential for assessment and management of patients with suspected VVF.

Appendix A. Supplementary data

Supplementary data related to this article can be found at <https://doi.org/10.1016/j.eucr.2018.01.023>.

References

1. Shaw R, Leusley D, Monga A. *Fertility Control. Gynaecology*. fourth ed. Churchill Livingstone; 2010.
2. Chen BA, Reeves MF, Hayes JL, et al. Postplacental or delayed insertion of the levonorgestrel intrauterine device after vaginal delivery: a randomized controlled trial. *Obstet Gynecol*. 2010;116:1079–1087.
3. Kirchheiner, Nout RA, Tanderup K, et al. Manifestation pattern of early-late vaginal morbidity after definitive radiation (Chemo)Therapy and image-guided adaptive brachytherapy for locally advanced cervical cancer: an analysis from the EMBRACE study. *Int J Radiat Oncol*. 2014 January;89(1):88–95.
4. Raassen T, Ngongo C, Mahendka M. Iatrogenic genitourinary fistula: an 18-year retrospective review of 805 injuries. *Int Urogynecol J*. July 2014;25(12):1699–1706.