



## EUS-guided through-the-needle biopsy for pancreatic cystic lesions

Jason Samarasena, MD, Allen Yu, BSc, David Lee, MD, Rintaro Hashimoto, MD, Yuxin Lu, MD, Daniel Thieu, BSc, Daniel Mai, BSc, John Lee, MD, Kenneth Chang, MD

**Background and Aims:** Differentiating pancreatic cystic lesions remains a challenge when the current technique of EUS-guided FNA is used. Recently, a miniaturized biopsy forceps with an outer diameter of 0.8 mm has been developed, thus allowing it to be passed through the bore of a standard 19-gauge FNA needle to acquire tissue.

**Methods:** This study consisted of a retrospective review of all cases of EUS-guided through-the-needle forceps biopsy technique (TTNFB) performed for pancreatic cystic lesions at a single academic tertiary care center over a 12-month period. Technical success was defined as acquisition of adequate tissue for formal histologic analysis. Safety was assessed through the monitoring and recording of periprocedural and postprocedural adverse events.

**Results:** The technical success of EUS-guided TTNFB was 87% (13/15). EUS-guided TTNFB with histologic analysis yielded pancreatic cyst diagnoses in 11 of 15 (73%) patients, compared with 0 of 15 (0%) patients with the use of EUS-FNA and cytologic analysis ( $P < .001$ ). Of the 15 cystic lesions, 8 were diagnosed as intrapapillary mucinous neoplasm based on EUS-TTNFB.

**Conclusion:** This TTNFB technique has the potential to improve the diagnostic yield of EUS-FNA for pancreatic cystic neoplasms. (VideoGIE 2019;4:436-9.)

The management of cystic lesions of the pancreas remains a challenge for the practicing gastroenterologist. Since the release of the latest 2012 international consensus guidelines<sup>1</sup> regarding the management of intrapapillary mucinous neoplasms (IPMNs) and mucinous cystic neoplasms (MCNs), there has been an increased impetus to properly identify and manage these lesions. Proper diagnosis is critical to subsequent medical decision making; yet, obtaining a definitive diagnosis has been troublesome to even the most experienced endoscopist. Current guidelines by the American Society for Gastrointestinal Endoscopy endorse the characterization of a concerning pancreatic cystic lesion with EUS, but the guidelines recognize that US features alone are not accurate enough for diagnosis or for determining the malignant potential of a cystic lesion.<sup>2</sup>

The proper diagnosis of these pancreatic cystic lesions has also been hampered by the difficulty of obtaining a sufficient sample of the cyst wall for histologic diagnosis. Rather, sampling of the cystic fluid with EUS-FNA has been the conventional technique used to infer the nature of the cyst itself. Unfortunately, the use of EUS-FNA has been hampered by low diagnostic yield and nonspecific fluid markers.

Recently, a through-the-needle forceps biopsy (TTNFB) device has become available: the Moray forceps (US Endoscopy, Mentor, Ohio, USA). This single-use microforceps device has an outer diameter of 0.8 mm and can be passed through the bore of a standard 19-gauge EUS-FNA needle. It has a working length of 230 cm, with a spring sheath that allows it to be used in tortuous positions, and a jaw opening width of 4.3 mm.

In this study, we retrospectively review our center's consecutive case experience with the Moray microforceps device, and we report on the technical success and safety of EUS-guided TTNFB for pancreatic cystic lesions.


### METHODS

This study consisted of a retrospective review of all cases of EUS-guided TTNFB performed for pancreatic cystic lesions at a single academic tertiary care center over a 12-month period. Technical success was defined as acquisition of adequate tissue for formal histologic analysis. Safety was assessed through the monitoring and recording of periprocedural and postprocedural adverse events.

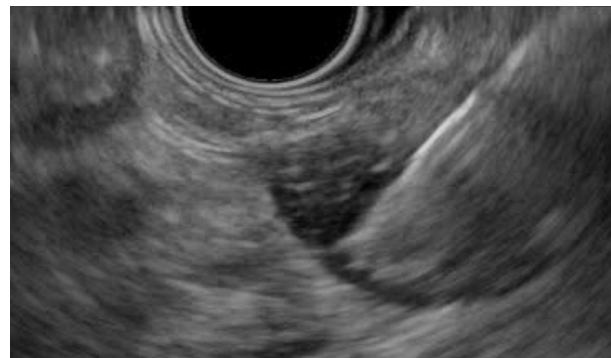The technique used for the TTNFB device can be viewed in [Video 1](#) (available online at [www.VideoGIE.org](http://www.VideoGIE.org)). The



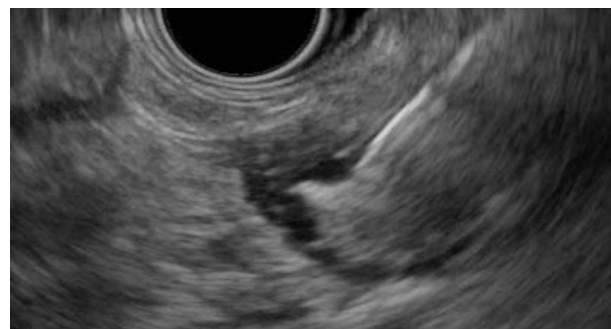**Figure 1.** Through-the-needle forceps.



**Figure 2.** Forceps extending through a 19-gauge FNA needle.



**Figure 3.** Closed forceps extending through a 19-gauge FNA needle after successful EUS puncture of a pancreatic cystic lesion.



**Figure 4.** Open forceps extending through a 19-gauge FNA needle after successful EUS puncture of a pancreatic cystic lesion.

pancreatic cystic lesion was localized under EUS, and a 19-gauge FNA needle was used to enter the cystic space. We then advanced the forceps device through the bore of the FNA needle. The entire needle with forceps was advanced to the cystic wall in the manner described in the video. Three to 4 passes of the forceps were used to obtain an adequate histologic specimen for analysis. One biopsy bite was performed per forceps pass. The tissue obtained was delivered in formalin to the pathology service for analysis. With the forceps withdrawn, aspiration of the cystic fluid through the EUS-FNA needle was performed on each patient when possible. When an IPMN was suspected, mucin staining was performed to verify the histologic characteristics and to subtype the IPMN.

## RESULTS

A total of 15 cases in 15 patients were found for inclusion. The population consisted of a fairly even split between men (7) and women (8), with a mean age of 67 years (range, 54-80 years). The location of the cysts were the head (5), neck (3), body (2), and tail (5). The mean diameter of the cystic lesion was 25 mm, but there was a

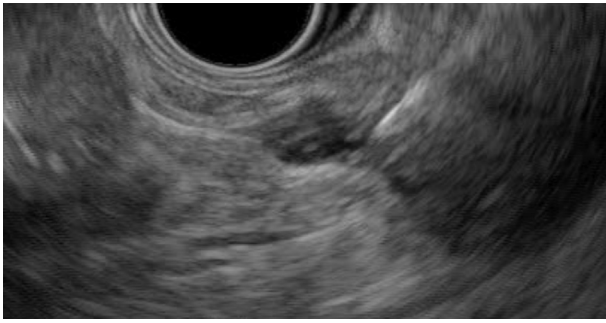wide range: 4.8 mm to 39.3 mm. The median number of forceps passes and bites was 3.5 per case.

The technical success of EUS-guided TTNFB was 87% (13/15). One case was terminated after 1 pass because of the appearance of intracystic bleeding (6.7%). Another case was completed with 3 passes of the Moray device, but no adequate specimen was obtained. There were no cases of serious adverse events, including infection, perforation, clinically significant bleeding, or postprocedure pancreatitis.

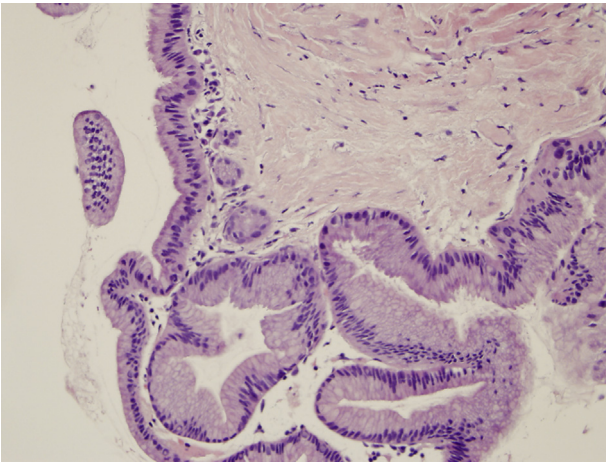
EUS-guided TTNFB with histologic analysis yielded pancreatic cyst diagnoses in 11 of 15 (73%) patients, compared with 0 of 15 (0%) patients with the use of EUS-FNA and cytologic analysis ( $P < .001$ ). Of the 15 cystic lesions, 8 were diagnosed as IPMN based on EUS-TTNFB. All 8 IPMNs were successfully subtyped based on histologic analysis and mucin staining (7 gastric, 1 pancreaticobiliary). Other histologic diagnoses included serous cystadenoma (2) and neuroendocrine tumor (1).

## DISCUSSION

In this study, we have examined the technical feasibility of a novel TTNFB technique using the Moray microforceps



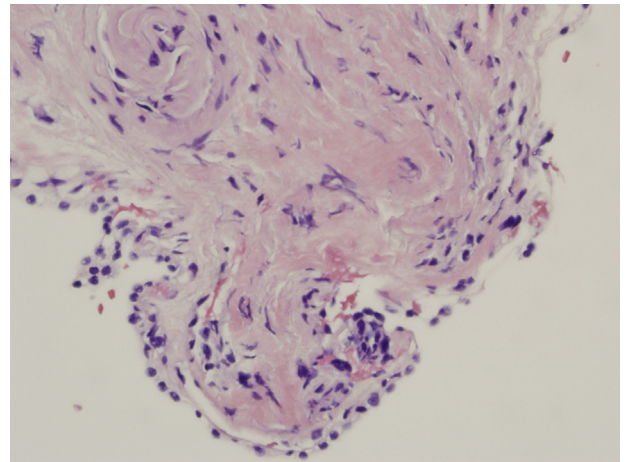
**Figure 5.** Tenting observed after the forceps has been closed around the cyst wall and the FNA needle subsequently retracted.



**Figure 6.** Specimen obtained by EUS through-the-needle forceps biopsy technique for histologic analysis, showing tissue consistent with an intra-papillary mucinous neoplasm (gastric type) (H&E, orig. mag.  $\times 40$ ).

device. We have examined a total of 15 cases over a 12-month period in which the forceps were used, with technical success in 13 of the 15 cases (87%). Of those, 11 cases yielded samples sufficient to provide a histologic diagnosis (73%), compared with 0 cases in which EUS-FNA with cytologic analysis provided a diagnosis. Eight of 11 cases diagnosed by the use of TTNFB were IPMNs, and all 8 IPMNs were successfully subtyped on the basis of histologic analysis and mucin testing, with 7 gastric and 1 pancreaticobiliary subtypes.

The ability to directly obtain biopsy specimens of a pancreatic cystic lesion for histologic analysis represents a great advance in the timely and accurate diagnosis of these lesions. Furthermore, we found that the forceps biopsy specimens we obtained were sufficient for IPMN subtyping. Although the current 2012 guidelines do not differentiate treatment of IPMNs based on subtype (gastric, intestinal, pancreaticobiliary, oncocytic), they do recognize that each subtype has been associated with different potentials for malignant transformation.<sup>1</sup> The ability to obtain tissue and perform mucin staining on IPMNs may thus inform the development of future guidelines



**Figure 7.** Specimen obtained by EUS through-the-needle forceps biopsy technique for histologic analysis, showing tissue consistent with a serous cystadenoma (H&E, orig. mag.  $\times 40$ ).

addressing the differential management of IPMNs based on subtype.

There are several strengths of this study. We have demonstrated technical feasibility in practice for this device with a high rate of successful tissue acquisition from pancreatic cystic walls. Furthermore, we have shown that the biopsy specimens obtained are sufficient to enable differentiation of mucinous from nonmucinous lesions and even to subtype IPMNs.

There are some weaknesses of this study as well. This is a retrospective analysis of only 1 center's experience, with expert endoscopists who accept high volumes of such cases. Further, the 0% diagnosis rate by EUS-FNA and cytology is lower than reported in other studies. Finally, the relatively small sample size of this study rendered it underpowered to detect rarer adverse events that may occur in more widespread practice.

Despite these shortcomings, these microforceps have the potential to increase the timeliness and accuracy of diagnosing pancreatic cystic lesions. TTNFB is readily adaptable to the practice of endoscopic sonographers and can provide sufficient histologic specimens for analysis. Further study is needed to gauge the rates of adverse events in widespread practice and to further refine the technique. However, we believe that these microforceps are a potentially valuable addition to the diagnostic tools available to the practicing gastroenterologist in the management of pancreatic cystic lesions.

## DISCLOSURE

*Dr Samarasena is a consultant for Medtronic, Olympus, US Endoscopy, Mauna Kea, Pentax, and Motus. Dr Chang is a consultant for Olympus, Cook Medical, Medtronic, Pentax, and Endogastric Solutions. All other*

*authors disclosed no financial relationships relevant to this publication.*

*Abbreviations: IPMN, intrapapillary mucinous neoplasm; MCN, mucinous cystic neoplasm; TTNFB, through-the-needle forceps biopsy technique.*

## REFERENCES

1. Tanaka M, Fernandez-del Castillo C, Adsay V, et al. International consensus guidelines 2012 for the management of IPMN and MCN of the pancreas. *Pancreatology* 2012;12:183-97.

2. Jacobson BC, Baron TH, Adler DG, et al. ASGE guideline: the role of endoscopy in the diagnosis and the management of cystic lesions and inflammatory fluid collections of the pancreas. *Gastrointest Endosc* 2005;61:363-70.

---

H. H. Chao Comprehensive Digestive Disease Center, University of California – Irvine, Orange, California, USA.

Copyright © 2019 American Society for Gastrointestinal Endoscopy. Published by Elsevier Inc. This is an open access article under the CC BY-NC-ND license (<http://creativecommons.org/licenses/by-nc-nd/4.0/>).

<https://doi.org/10.1016/j.vgie.2019.04.020>

---