



Since January 2020 Elsevier has created a COVID-19 resource centre with free information in English and Mandarin on the novel coronavirus COVID-19. The COVID-19 resource centre is hosted on Elsevier Connect, the company's public news and information website.

Elsevier hereby grants permission to make all its COVID-19-related research that is available on the COVID-19 resource centre - including this research content - immediately available in PubMed Central and other publicly funded repositories, such as the WHO COVID database with rights for unrestricted research re-use and analyses in any form or by any means with acknowledgement of the original source. These permissions are granted for free by Elsevier for as long as the COVID-19 resource centre remains active.



## Case Report

# A case of COVID-19 pneumonia successfully treated with favipiravir (Avigan) in which serum SARS-CoV-2 RNA detected by LAMP method was clinically useful



Takatomo Hirouchi <sup>a</sup>, Shinichiro Ota <sup>a, \*</sup>, Dai Mashima <sup>b</sup>, Ryuichi Boku <sup>c</sup>, Yuto Yoshida <sup>a</sup>, Koki Iwata <sup>c</sup>, Kanako Shinada <sup>a</sup>, Takashi Matsumoto <sup>c</sup>, Miwa Morikawa <sup>a</sup>, Takashi Sato <sup>a</sup>, Masahiro Shinoda <sup>a</sup>, Kenichi Kamachi <sup>c</sup>, Masaharu Shinkai <sup>a</sup>

<sup>a</sup> Department of Respiratory Medicine, Tokyo Shinagawa Hospital, Japan

<sup>b</sup> Department of Laboratory Testing, Tokyo Shinagawa Hospital, Japan

<sup>c</sup> Department of Emergency Medicine, Tokyo Shinagawa Hospital, Japan

## ARTICLE INFO

## Article history:

Received 21 August 2020

Received in revised form

6 October 2020

Accepted 8 October 2020

Available online 10 October 2020

## Keywords:

Favipiravir

COVID-19

Viremia

Loop-mediated isothermal amplification

(LAMP)

## ABSTRACT

A 49-year-old Japanese male was managed by mechanical ventilation due to coronavirus disease 2019 (COVID-19) pneumonia. Favipiravir as an antiviral therapy, and anti-inflammatory treatment were administered. SARS-CoV-2 RNA was detected in serum by the loop-mediated isothermal amplification (LAMP) method on Day 9; favipiravir treatment was continued. On Day 13, negative serum RNA was confirmed, followed by mechanical ventilation was removed. On Day 23, LAMP negative was confirmed in nasopharynx, after that the patient discharged on Day 27. We could treat successfully for severe COVID-19 pneumonia based on the LAMP method. We consider this method will be useful in COVID-19 treatment.

© 2020 Japanese Society of Chemotherapy and The Japanese Association for Infectious Diseases. Published by Elsevier Ltd. All rights reserved.

## 1. Introduction

Coronavirus disease 2019 (COVID-19), which is caused by SARS-CoV-2, is suspected to have occurred in Wuhan City China in December 2019 [1] and has rapidly spread to around the world [2]. In Japan, the number of infected people increased throughout the months of March until April mainly in urban areas. Currently, there are no established effective treatments for COVID-19, and many medical institutions have been conducting clinical trials and clinical researches to develop treatments against this disease. We performed antiviral treatment with favipiravir and anti-inflammatory treatment mainly with steroids for a severe COVID-19 pneumonia case that required intubation and mechanical ventilation. During the treatment course, we detected serum SARS-CoV-2 RNA using Loop-Mediated Isothermal Amplification (LAMP) method [3,4] and assessed the disease conditions and determined treatment

strategies based on the information (hereafter, the detection of SARS-CoV-2 RNA with LAMP method is expressed as LAMP). The LAMP method is a quick and simple compared with the RT-qPCR method, and serum LAMP can be applied to evaluate the disease conditions. We report this case because it may be useful for treatment of COVID-19 in the future.

## 2. Case presentation

A 49-year-old Japanese male visited our outpatient department for chief complains of fever, cough, malaise and arthralgia that developed 3 days before the visit. Blood test findings showed elevations of CRP and LDH, and a chest CT showed patchy ground-glass opacities in all fields of both lungs. COVID-19 pneumonia was suspected because the patient was engaged in extracorporeal membrane oxygenation (ECMO) management for COVID-19 patients as a medical engineer several days before onset of the symptoms, and the patient was hospitalized. There was no past medical history or a travel history. As history of life, the patient was a never smoker, and he was drinking 350–700 ml/day of beer 3

\* Corresponding author. Department of Respiratory Medicine, Tokyo Shinagawa Hospital, 6-3-22, Higashi-ooi, Shinagawa-ku, Tokyo, 140-8522, Japan.

E-mail address: [shin.ota0915@gmail.com](mailto:shin.ota0915@gmail.com) (S. Ota).

days/week. Height was 170.9 cm, weight was 76.5 kg, and BMI was 26.2. Vital signs on admission were as follows; consciousness: clear, body temperature: 38.4 °C, blood pressure: 117/81 mmHg, pulse rate: 91/min, respiratory rate: 20/min, and SpO<sub>2</sub>: 96% (ambient air). Breath sounds were clear on chest auscultation without asymmetry and adventitious sound. No other special physical findings were found.

A chest X-ray showed an increased density in the right lower lung field. A chest CT images showed peripheral dominant ground glass opacities (GGO) in both upper lobes and left lower lobe. In addition, an extensive GGO was observed in the right lower lobe (Fig. 1). Blood test findings showed increases in inflammatory response and LDH (Table 1). On admission, respiratory status was stable (SpO<sub>2</sub>: 96%); however, fever of 38 °C or higher persisted after onset. Therefore, conventional doses of peramivir, ceftriaxone (CTRX), and intravenous azithromycin (AZM) were started.

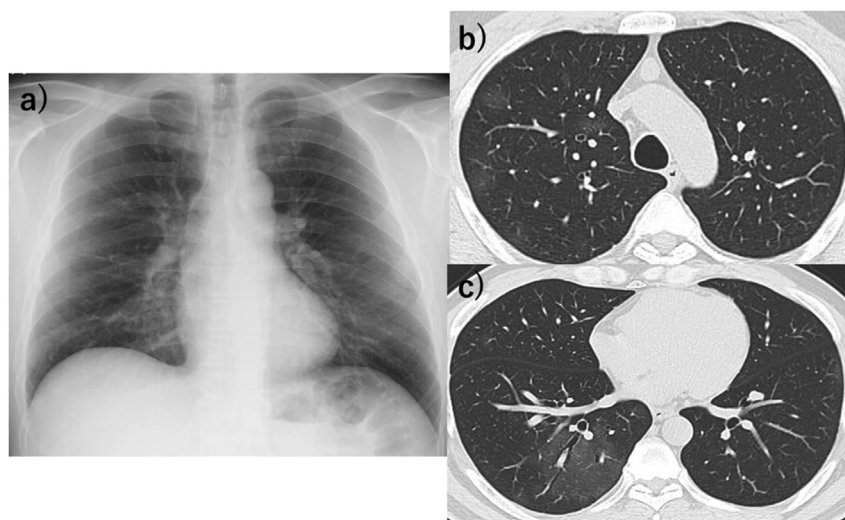
Methylprednisolone (mPSL) (80mg/day) was started with reference of the acute respiratory distress syndrome (ARDS) treatment guidelines. In spite of these medication, respiratory status worsened and oxygen supplement was required on day 2. On day 3, SARS-CoV-2 specific RNA was detected from nasopharyngeal sample by LAMP method [3–5] using Loopamp® SARS-CoV-2 RT-LAMP reaction kit (LMP403, Eiken Chemical Co. Ltd., Tokyo, Japan) and the real-time turbidimeter LoopampEXIA® (Eiken Chemical Co. Ltd., Tokyo, Japan). Compassionate use of favipiravir (Avigan®, 3,600mg for the first day and 1600mg for the following days) started with written consent of the patient.

On Day 4, mPSL was increased to 250 mg since respiratory state further worsened. On Day 6, the oxygen demand was further increased, and a rapid worsening of the shadow was observed on a chest CT (Fig. 2). Then, the patient was transferred to the high care unit (HCU) to start assisted respiratory therapy with the nasal high-flow cannula (NHFC). On Day 7, progression of respiratory failure was determined because controlling inflammatory response was difficult, blood gas analysis (5 L/min was supplied through oxygen mask) showed pH 7.451, PaO<sub>2</sub> 68.4 Torr, and PaCO<sub>2</sub> 35.9 Torr, and respiratory rate increased; therefore, tracheal intubation and mechanical ventilation management were started (Fig. 3). While anti-inflammatory treatment with mPSL was continued, another anti-inflammatory treatment with 400 mg of intravenous tocilizumab (Actemra®), an anti-IL-6 receptor antibody, was added. As fever and increased level of inflammatory markers persisted regardless of

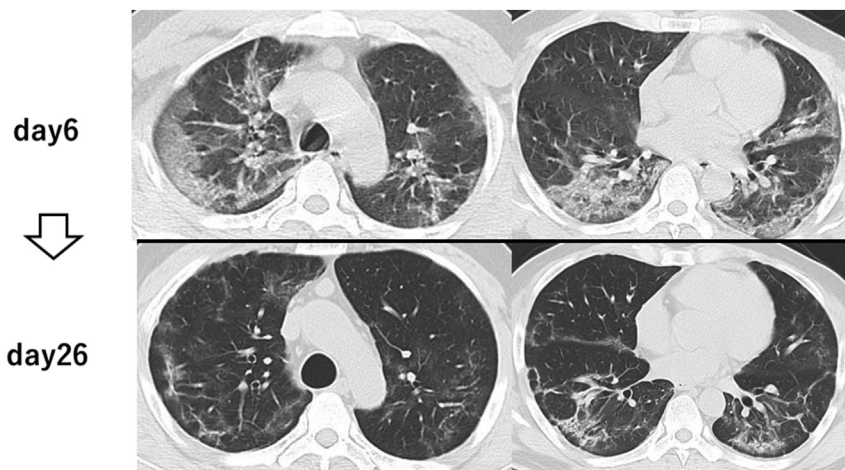
**Table 1**  
Blood test data on admission are shown.

Complete Blood Cell Count	
White Blood Cells	6000/μL
Neutrophils	74.3%
Lymphocytes	20.8%
Monocytes	4.7%
Eosinophils	0.2%
Red Blood Cells	5.46 × 10 <sup>6</sup> /μL
Hematocrit	49.5%
Hemoglobin	16.7 g/dL
Coagulation	
PT-INR	1.03
FBG	453 mg/dL
FDP	<0.25μg/mL
D-D	0.1 pg/mL
Biochemistry	
T-Bil	0.55 mg/dL
AST	31 U/L
ALT	40 U/L
LDH	231 U/L
Alb	4.2 g/dL
BUN	16.4 mg/dL
Crea	1.12 mg/dL
HbA1c	6.0%
CRP	1.39 mg/dL
sIL-2R	445 U/mL
KL-6	172 U/mL
SP-A	24.1 ng/mL
SP-D	18.4 ng/mL

those anti-inflammatory therapies, 200 mg/day of intravenous remdesivir (Veklury®), which was added to the National Health Insurance drug price list as the first COVID-19 drug in Japan, was started on Day 8 to enhance antiviral treatment. However, renal dysfunction and electrolytes abnormal (hyperkalemia) were found on Day 9, and remdesivir was discontinued after administration for only one day because those events were determined to be adverse event of remdesivir. On Day 9, LAMP was performed in nasopharynx and serum samples to understand the disease conditions and determine if antiviral therapy should be continued. The results showed that viral RNA was positive in both samples (Fig. 4 and Fig. 5). As shown in Fig. 5, the periods of time to detect turbidity after run was faster in the nasopharynx samples than in serum samples, suggesting that a copy number of viral genomes was higher in



**Fig. 1.** Imaging findings on admission. No abnormal findings were observed on chest X-ray (a). On chest CT, the right upper lobe dominant patchy Ground Glass Opacities (GGO) were observed (b). A relatively extensive GGO was observed in the right lower lobe (c).



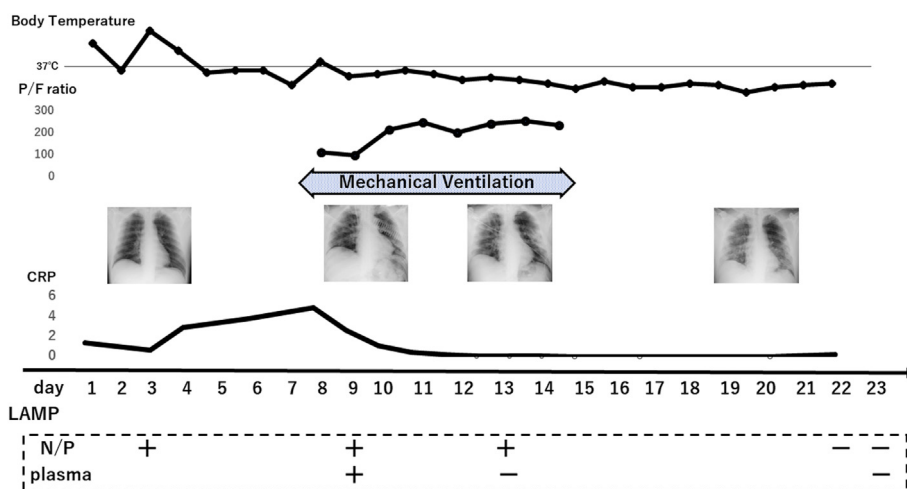
**Fig. 2.** CT imaging findings after admission. Consolidation and GGOs increased in all lung fields on Day 6, with a decrease in volume (upper image). On disease Day 26, consolidation and GGOs were mostly decreased while they were partially remained. The area of increased linear shadows with collapse was observed (lower image).

nasopharynx samples than in serum samples. Nevertheless, the patient was considered to have viremia in addition to pneumonia, and favipiravir was continued because continuous antiviral therapy was determined to be necessary. Following the discontinuation of remdesivir, the renal function and electrolytes abnormal rapidly recovered. mPSL 250 mg/day was continued from Day 4 to Day 12 for anti-inflammatory treatment; however, new infiltrative shadows were observed in the right lower lung field on chest X-ray on Day 13. Of note, viral RNA was not detected in serum by LAMP, suggesting that the patient was free from viremia. Therefore, although the nasopharyngeal LAMP on the same day was positive (Fig. 4), the dose of mPSL increased to 500 mg/day to enhance anti-inflammatory treatment. Interestingly, Fig. 4 showed that the time taken for positive detection in LAMP assay was continuously reduced according to the administration of favipiravir (from 12 min at day 3–19 min at day 13). According to the results, we predicted that the viral load continuously reduced in the nasopharynx along with medications. On Day 15, improvement of the shadow was observed, and weaning from mechanical ventilation was achieved. Thereafter, no exacerbation of respiratory status was observed, and the dose of mPSL was gradually decreased. On Day 19, the patient was transferred to a general ward, and the dose of mPSL was

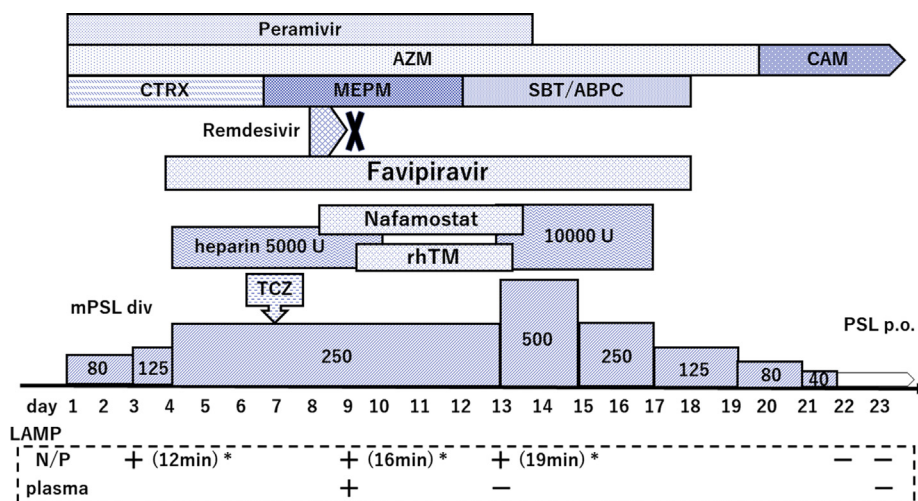
gradually decreased to 40 mg/day by Day 22, and then, it was switched to oral prednisolone. Nasopharyngeal LAMP was negative on Day 22, and both nasopharynx and serum LAMPs became negative on Day 23 (Fig. 4). Improvement of the shadow on the chest CT was confirmed on Day 26 (Fig. 2), and the patient was discharged on Day 27. The patient is currently managed and followed-up on an outpatient basis. This Patient provided written informed consent for publishing this case report and the accompanying images. The present case report also was approved by the ethics committee of Tokyo Shinagawa Hospital (approval no. 20-A-06).

### 3. Discussion

The definitive diagnosis of COVID-19 is currently made by the RT-qPCR method using samples collected mainly from the nasopharynx, but also from blood, sputum, bronchoalveolar lavage fluid (BALF), etc [6]. It can be used for diagnosis and monitoring the course of antiviral treatment in quantitative assays [7,8]. The detection of SARS-CoV in serum RNA indicates viremia [9], although it has been reported that the RNA detection rate vary depending on the time elapsed from onset [6–10]. Detection of viral RNA in sera is also clinically significance in COVID-19, which is



**Fig. 3.** Body temperature during hospitalization, PaO<sub>2</sub>/FiO<sub>2</sub> ratio (P/F ratio) during mechanical ventilation, and changes in blood test data are shown. N/P: nasopharynx.



**Fig. 4.** The used drugs, nasopharyngeal swab samples and serum LAMP results during hospitalization are shown. AZM: azithromycin, CAM: clarithromycin, MEPM: meropenem, CTRX: ceftriaxone, SBT/ABPC: Sulbactam/Ampicillin, rhTM: recombinant human soluble thrombomodulin, mPSL: methylprednisolone, PSL: prednisolone, TCZ: Tocilizumab. \* The time taken for positive detection in LAMP assay.

caused by SARS-CoV-2. Although the problem of serum samples is low detection rate of 41% in RT-PCR method (when the detection rate in the airway samples is 100%), the rate of detection was higher in patients with severe disease than in patients with mild disease [10]. Thus SARS-Cov-2 viral detection in serum appears to be useful for monitoring the course of antiviral treatment.

On the contrary, the viral load of nasopharynx was reported not to associate with clinical progression in SARS-CoV [7], and there is no report that the detection of PCR in the nasopharyngeal samples is correlated with the severity in COVID-19, and it has only a diagnostic value. The sensitivity of the nasopharyngeal samples vary depending on the collection method and the procedure, whereas serum sample is easy to handle, blood sampling is easy, and the results are less affected by procedure. Serum may be a relatively stable sample in assessing disease conditions over time. Risk of exposure to health care providers is also lower compared to the nasopharyngeal samples.

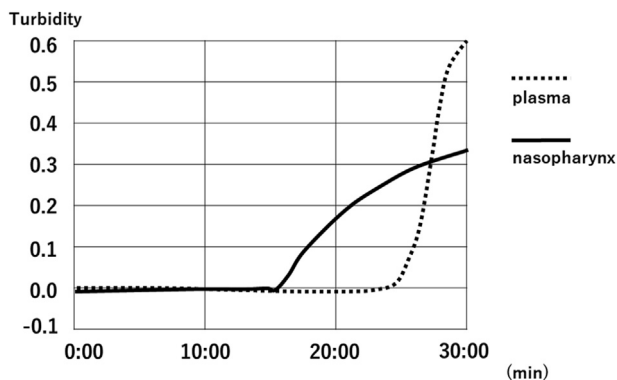
We adopted the LAMP methods to measure viral RNA in serum samples in addition to nasopharyngeal samples and demonstrated that a transient detection of viral genomes in serum in a patient with severe infection with SARS-COV-2. The LAMP is less sensitive than RT-PCR, however, we overcame the problem by extensive enrichment of viral genome from samples with use of QIAamp Viral RNA Mini Kit (QIAGEN) prior to the assay. The viral RNA was first

detected in the nasopharyngeal samples (Fig. 4), followed by a transient detection in serum samples, as a result of the viremia (Fig. 5), although viral copy numbers in serum was lower than in nasopharynx. Later on, the viral RNA was detected in the nasopharyngeal sample, but not in the serum sample, indicating the improvement in clinical state, although with active inflammation in pneumonia.

Later on viral genomes detected in the nasopharynx sample, but not in the serum sample. The results show improvement in viremia, although accompanying active inflammation in pneumonia. Finally, LAMP was negative in both nasopharyngeal and serum samples, suggesting improvement in the general conditions including pneumonia, with confirmation by, and the patient was discharged. We performed a genetic amplification test rapidly and simply using the LAMP method, and it was helpful to evaluate the disease conditions of COVID-19 and determine its treatment strategies.

In COVID-19, respiratory organs are especially impaired among organs leading to ARDS [11]. Cases requiring high flow oxygen such as NHFC should be monitored so that intubation can be performed at any time. In the present case, oxygen demand increased in a general ward, so the patient was transferred to HCU on Day 6 (10 days after onset) and required intubation on Day 7 (next day). The median days from symptom onset to progress to ARDS is considered to be 9–12 days [12], and the median days in the present case was consistent with the previous reports. While a study reported that longer duration of steroid treatment prolonged PCR-positive period [10], and there are negative opinions on the use of steroids for COVID-19 [13], treatment with mPSL was reported to reduce the intubation period and mortality in ARDS [14], and efficacy of mPSL for ARDS caused by COVID-19 was reported [15]. The steroid treatment for COVID-19 has not been established, and the results of future clinical studies and interventional studies are awaited.

Various antiviral treatments are currently being studied, and other existing drugs are being interventional investigated. Although shortened recovery time in hospitalized COVID-19 pneumonia patients treated with remdesivir was reported, no significant difference was observed in the hazard ratio of mortality up to 14 days [16]. While favipiravir is an antiviral agent for novel influenza virus infections, its antiviral effects against SARS-CoV-2 have been confirmed in vitro [17]. Early treatment effect of favipiravir was reported in a combination use with interferon alpha-1b in China [18], the results of clinical researches and clinical trials are



**Fig. 5.** Turbidity measurement in the LAMP method on Day 13. Each amplification curve of the nasopharyngeal and serum samples is shown.

also awaited in Japan. In the present case, both favipiravir and remdesivir were used. Although remdesivir was discontinued due to adverse reactions of function kidney decreased and electrolytes abnormality, a 14-day administration of favipiravir was successfully completed without any adverse reactions, viremia and pneumonia improved, and favorable outcome was observed.

As of May 27, a total of 66 COVID-19 pneumonia patients have been treated at our hospital. Among those patients, the actual respiratory status sometimes differed from images or blood test data, and we often encountered cases difficult to evaluate accurately the disease conditions. The disease conditions of the present case was firstly difficult to evaluate due to persistent fever and high inflammation; however, we successfully treated the case by continuing antiviral therapy combined with anti-inflammatory treatment because we considered that the serum LAMP positive indicated viremia and the difference from the nasopharyngeal LAMP results reflected the severity of the disease. If interpretation is difficult in the clinical course, combining LAMP information from different sample types can be applied to the disease assessment.

#### 4. In conclusion

We detected serum SARS-CoV-2 RNA using the LAMP method to evaluate disease conditions and continued antiviral treatment with favipiravir, and successfully treated a severe COVID pneumonia patient requiring mechanical ventilation management. The LAMP method is a quick and simple compared with the RT-PCR method and could also be applied to disease evaluation, suggesting the potential use in COVID-19 treatment in the future.

#### Contributors

All authors were involved in this patient treatment. YY and MS were physician in charge of the patient. RB, KI and TM were responsible for intensive care. DM was in charge of clinical examination. TH and SO drafted the manuscript. All authors have read and approved the final manuscript. All authors confirm that they met the criteria established by the International Committee of Medical Journal Editors.

#### Conflicts of interest

There is no COI to be disclosed in this case report.

#### Acknowledgments

We would like to express our deep gratitude to Dr. Toshitada Takemori, the Department of Clinical Research of the Tokyo

Shinagawa Hospital, for his advice for the measurement of RNA in SARS-CoV-2.

#### References

- [1] Zhu N, Zhang D, Wang W, Li X, Yang B, Song J, et al. A novel coronavirus from patients with pneumonia in China, 2019. *N Engl J Med* 2020;382(8):727–33.
- [2] Dong E, Du H, Gardner L. An interactive web-based dashboard to track COVID-19 in real time. *Lancet Infect Dis* 2020;20(5):533–4.
- [3] Notomi T, Okayama H, Masubuchi H, Yonekawa T, Watanabe K, Amino N, et al. Loop-mediated isothermal amplification of DNA. *Nucleic Acids Res* 2000;28(12):E63.
- [4] Tomita N, Mori Y, Kanda H, Notomi T. Loop-mediated isothermal amplification (LAMP) of gene sequences and simple visual detection of products. *Nat Protoc* 2008;3(5):877–82.
- [5] Yu L, Wu S, Hao X, Dong X, Mao L, Pelechano V, et al. Rapid detection of COVID-19 coronavirus using a reverse transcriptional loop-mediated isothermal amplification (RT-LAMP) diagnostic platform. *Clin Chem* 2020;66(7):975–7.
- [6] Kannan S, Shaik Syed Ali P, Sheeza A, Hemalatha K. COVID-19 (Novel Coronavirus 2019) - recent trends. *Eur Rev Med Pharmacol Sci* 2020;24(4):2006–11.
- [7] Peiris JS, Chu CM, Cheng VC, Chan KS, Hung IF, Poon LL, et al. Clinical progression and viral load in a community outbreak of coronavirus-associated SARS pneumonia: a prospective study. *Lancet* 2003;361(9371):1767–72.
- [8] Perchetti GA, Nalla AK, Huang ML, Zhu H, Wei Y, Stensland L, et al. Validation of SARS-CoV-2 detection across multiple specimen types. *J Clin Virol* 2020;128:104438.
- [9] Chen W, Xu Z, Mu J, Yang L, Gan H, Mu F, et al. Antibody response and viraemia during the course of severe acute respiratory syndrome (SARS)-associated coronavirus infection. *J Med Microbiol* 2004;53(Pt 5):435–8.
- [10] Zheng S, Fan J, Yu F, Feng B, Lou B, Zou Q, et al. Viral load dynamics and disease severity in patients infected with SARS-CoV-2 in Zhejiang province, China, January–March 2020: retrospective cohort study. *BMJ* 2020;369:m1443.
- [11] Chan JF, Yuan S, Kok KH, To KK, Chu H, Yang J, et al. A familial cluster of pneumonia associated with the 2019 novel coronavirus indicating person-to-person transmission: a study of a family cluster. *Lancet* 2020;395(10223):514–23.
- [12] Li X, Ma X. Acute respiratory failure in COVID-19: is it "typical" ARDS? *Crit Care* 2020;24(1):198.
- [13] Russell CD, Millar JE, Baillie JK. Clinical evidence does not support corticosteroid treatment for 2019-nCoV lung injury. *Lancet* 2020;395(10223):473–5.
- [14] Meduri GU, Siemieniuk RAC, Ness RA, Seyler SJ. Prolonged low-dose methylprednisolone treatment is highly effective in reducing duration of mechanical ventilation and mortality in patients with ARDS. *J Intensive Care* 2018;6:53.
- [15] Wu C, Chen X, Cai Y, Xia J, Zhou X, Xu S, et al. Risk factors associated with acute respiratory distress syndrome and death in patients with coronavirus disease 2019 pneumonia in wuhan, China. *JAMA Intern Med* 2020;180(7):934–43.
- [16] Beigel JH, Tomashek KM, Dodd LE, Mehta AK, Zingman BS, Kalil AC, et al. Remdesivir for the treatment of covid-19 - preliminary report. *N Engl J Med* 2020. <https://doi.org/10.1056/NEJMoa2007764>.
- [17] Wang M, Cao R, Zhang L, Yang X, Liu J, Xu M, et al. Remdesivir and chloroquine effectively inhibit the recently emerged novel coronavirus (2019-nCoV) in vitro. *Cell Res* 2020;30(3):269–71.
- [18] Cai Q, Yang M, Liu D, Chen J, Shu D, Xia J, et al. Experimental treatment with favipiravir for COVID-19: an open-label control study. *Engineering (Beijing)* 2020.