

REVIEW

Childhood neurofibromatosis type 2 (NF2) and related disorders: from bench to bedside and biologically targeted therapies

Neurofibromatosi tipo 2 (NF2) e sindromi correlate in età infantile: dalla biologia molecolare alla pratica clinica e nuove terapie con farmaci biologici

M. RUGGIERI¹, A.D. PRATICÒ^{1,2}, A. SERRA³, L. MAIOLINO³, S. COCUZZA³, P. DI MAURO³, L. LICCIARDELLO³, P. MILONE⁴, G. PRIVITERA⁴, G. BELFIORE⁵, M. DI PIETRO⁶, F. DI RAIMONDO⁷, A. ROMANO⁷, A. CHIARENZA⁷, M. MUGLIA⁸, A. POLIZZI^{9,10}, D.G. EVANS¹¹

¹ Unit of Rare Diseases of the Nervous System in Childhood, Department of Clinical and Experimental Medicine, Section of Pediatrics and Child Neuropsychiatry, University of Catania, Italy; ² Department of Biomedical and Biotechnological Sciences, University of Catania, Italy; ³ Department of Medical and Surgical Sciences and Advanced Technologies "G. Ingrassia", Institute of Otorhinolaryngology, University of Catania, Italy; ⁴ Department of Medical and Surgical Sciences and Advanced Technologies "G. Ingrassia", Institute of Radiology, University of Catania, Italy; ⁵ Unit of Paediatric Radiology, AOU "Policlinico-Vittorio Emanuele", Catania, Italy; ⁶ Department of Medical and Surgical Sciences and Advanced Technologies "G. Ingrassia", Institute of Ophthalmology, University of Catania, Italy; ⁷ Division of Hematology, AOU "Policlinico-Vittorio Emanuele", University of Catania, Italy; ⁸ Unit of Genetics, Institute of Neurological Sciences, National Research Council, Piano Lago di Mangone, Italy; ⁹ National Centre for Rare Disease, Istituto Superiore di Sanità, Rome, Italy; ¹⁰ Institute of Neurological Sciences, National Research Council, Catania, Italy; ¹¹ Genomic Medicine, University of Manchester, Manchester Academic Health Science Centre, Institute of Human Development, Central Manchester NHS Foundation Trust, Manchester Royal Infirmary, Manchester, UK

SUMMARY

Neurofibromatosis type 2 [NF2; MIM # 101000] is an autosomal dominant disorder characterised by the occurrence of vestibular schwannomas (VSs), schwannomas of other cranial, spinal and cutaneous nerves, cranial and spinal meningiomas and/or other central nervous system (CNS) tumours (e.g., ependymomas, astrocytomas). Additional features include early onset cataracts, optic nerve sheath meningiomas, retinal hamartomas, dermal schwannomas (i.e., NF2-plaques), and (few) café-au-lait spots. Clinically, NF2 children fall into two main groups: (1) congenital NF2 - with bilateral VSs detected as early as the first days to months of life, which can be stable/asymptomatic for one-two decades and suddenly progress; and (2) severe pre-pubertal (Wishart type) NF2- with multiple (and rapidly progressive) CNS tumours other-than-VS, which usually present first, years before VSs [vs. the classical adult (Gardner type) NF2, with bilateral VSs presenting in young adulthood, sometimes as the only disease feature]. Some individuals can develop unilateral VS associated with ipsilateral meningiomas or multiple schwannomas localised to one part of the peripheral nervous system [i.e., mosaic NF2] or multiple non-VS, non-intradermal cranial, spinal and peripheral schwannomas (histologically proven) [schwannomatosis]. NF2 is caused by mutations in the NF2 gene at chromosome 22q12.1, which encodes for a protein called merlin or schwannomin, most similar to the extrin-readixin-moesin (ERM) proteins; mosaicNF2 is due to mosaic phenomena for the NF2 gene, whilst schwannomatosis is caused by coupled germ-line and mosaic mutations either in the SMARCB1 gene [SWNTS1; MIM # 162091] or the LZTR1 gene [SWNTS2; MIM # 615670] both falling within the 22q region and the NF2 gene. Data driven from in vitro and animal studies on the merlin pathway [e.g., post-translational and upstream/downstream regulation] allowed biologically targeted treatment strategies [e.g., Lapatinib, Erlotinib, Bevacizumab] aimed to multiple tumour shrinkage and/or regression and tumour arrest of progression with functional improvement.

KEY WORDS: Paediatric NF2 • Congenital NF2 • Childhood NF2 • Early onset NF2 • Mosaic NF2 • Schwannomatosis • Merlin

RIASSUNTO

La neurofibromatosi tipo 2 [NF2] è una malattia genetica a trasmissione autosomica dominante [MIM # 101000]. Clinicamente è caratterizzata da: (1) schwannomi bilaterali del (VIII) nervo acustico/vestibolare; (2) cataratta giovanile o amartomi retinici; (3) schwannomi a carico dei nervi periferici e dei nervi cranici; (4) tumori multipli del sistema nervoso centrale (es., meningiomi, astrocitomi, ependimomi); (5) lesioni cutanee: (a) placche NF2 (schwannomi cutanei); (b) (poche) macchie caffelatte; (6) "malformazioni dello sviluppo corticale cerebrale". La prevalenza della (forma sintomatica di) NF2 nella popolazione generale è di 1 su 100.000-200.000 individui con un'incidenza di 1 su 33.000 nati. La forma classica a esordio nel giovane adulto è conosciuta come forma di Gardner, (esordio intorno ai 20-30 anni d'età) con manifestazioni legate agli schwannomi bilaterali del nervo acustico/vestibolare (diminuzione/perdita progressiva dell'udito, tinnito, vertigini) e/o più raramente con manifestazioni da (altri) tumori del sistema nervoso centrale e/o periferico. In età pediatrica il fenotipo è diverso (forma di Wishart): per primi compaiono abitualmente i tumori del sistema nervoso centrale in assenza di schwannomi vestibolari; si possono avere macchie caffelatte e placche NF2 e solo dopo anni i tumori del nervo cranico VIII e di altri nervi cranici. Il quadro è più grave. Esiste anche una forma "congenita" ad esordio nei primi giorni/mesi di vita, con schwannomi vestibolari di piccole dimensioni (stabili nel tempo: anche per anni/decenni ma con improvvisa e rapida pro-

gressione) e numerose placche NF2; in questa forma le altre manifestazioni (es. meningiomi, altri tumori, altri schwannomi) sono spesso più gravi e progressive delle altre forme. Il gene responsabile della NF2 è localizzato sul cromosoma 22q12.1. Il prodotto genico della NF2 è conosciuto con il nome di schwannomina o merlina [dalla famiglia di proteine 4.1 del tipo moesina-ezrina-radixina/ERM alla quale appartiene il gene della NF2] e ha funzioni di regolazione della crescita e del rimodellamento cellulare (soppressione della crescita cellulare e della tumorigenesi). Alcune persone possono presentare tutte le (o parte delle) manifestazioni della NF2 in un emilato o in segmenti corporei circoscritti [NF2 a mosaico]. Altre persone presentano schwannomi (confermati istologicamente) dei nervi periferici (non intradermici) e/o delle radici gangliari in assenza di tumori del nervo vestibolare (o di altri nervi cranici: anche se in alcuni casi vi possono essere anche tumori unilaterali o bilaterali del nervo acustico/vestibolare e/o dei nervi cranici misti) o di altri segni diagnostici per la NF2 [Schwannomatosi, SWNTS]. L'esordio in questa forma è intorno ai 30 anni d'età (sono conosciuti casi in età pediatrica) con tumori in svariate sedi (abituamente tronco e arti). Si conoscono due forme principali: (1) SWNTS1 [MIM # 162091] causata da alterazioni del gene SMARCB1 [regolatore della cromatina actina-dipendente associato alla matrice e correlato alle proteina SWI/SBF, sub-famiglia B, membro di tipo 1; MIM # 601607], sul cromosoma 22q11.23 (posizione centromerica rispetto al gene della NF2); (2) SWNTS2 [MIM # 615670] causata da alterazioni del gene LZTR1 [regolatore della trascrizione di tipo 1 legato alla Leucina; MIM # 600574], cromosoma 22q11.21 (posizione centromerica rispetto al gene SMARCB1) che codifica per una proteina, membro della super-famiglia BTB-kelch. Il meccanismo molecolare della Schwannomatosi comprende: (1) mutazione germinale del gene SMARCB1 o del gene LZTR1; (2) ampia delezione all'interno del cromosoma 22 (con perdita del gene NF2 e dell'allele intatto SMARCB1 o LZTR1); e (3) mutazione somatica dell'allele intatto del gene NF2 [meccanismo conosciuto come "four hits": "Quadrupla alterazione" (su entrambi gli alleli dei due geni SWNTS/NF2), con tre passaggi consecutivi]. Negli ultimi anni, accanto alle tradizionali terapie chirurgiche e/o radioterapiche sono stati anche impiegati diversi farmaci "biologici" (es., Lapatinib e Bevacizumab) con effetti di riduzione/arresto della crescita dei tipici tumori NF2.

PAROLE CHIAVE: NF2 pediatrica • NF2 ad esordio precoce • NF2 a mosaico • NF2 Congenita • Schwannomatosi • Merlina

Acta Otorhinolaryngol Ital 2016;36:345-367

Introduction

Neurofibromatosis type 2 [NF2; MIM # 101000]¹⁻⁴, previously known as bilateral acoustic neurofibromatosis [BANF] or central neurofibromatosis⁵⁻⁸, is an autosomal dominant disorder caused by mutations in the NF2 gene [MIM # 607379]^{9,10}, encoding neurofibromin-2 or schwannomin [SCH], which is also called merlin [moesin-ezrin-radixin-like (ERM) protein], on chromosome 22q12.2¹¹. Clinically, NF2 is characterised by the development of vestibular schwannomas (VSs), schwannomas of other cranial, spinal and cutaneous nerves, cranial and spinal meningiomas and/or other central nervous system (CNS) tumours including ependymomas and low grade astrocytomas¹²⁻¹⁵. A variety of ocular abnormalities are also common, such as early onset cataracts (usually asymptomatic), optic nerve sheath meningiomas, retinal and/or pigment epithelial hamartomas and epithelial retinal membranes¹⁶. Skin abnormalities include flat dermal (NF2-plaques) and spherical/ovoid subcutaneous nodular schwannomas¹⁷. Less than 1% of NF2 patients have ≥ 6 café-au-lait (CAL) spots^{14,17}. Clinically, affected individuals fall into two main groups^{18,19}: (1) (Mild) Gardner type NF2^{6,7}, with bilateral VSs presenting in adulthood (mean age 22 to 27 years), often as the only feature¹⁹; (2) (Severe) Wishart type NF2⁵, with multiple (and rapidly progressive) CNS tumours other-than-VS which may present first, years before VSs²⁰⁻³³. The latter group also tends to have more marked skin and eye involvement^{14,20-33}. There is nonetheless substantial variation and patients may not fit neatly into one category. A third group, known as congenital NF2³⁴, has been also recorded with bilateral VSs detected as early as the first days to months of life, which can be stable (and asymptomatic) for one to nearly two decades and thereafter sud-

denly progress: this form may be associated with (reversible) NF2 plaques in atypical locations (e.g., face, hands and feet) and other CNS tumours (e.g., meningiomas, ependymomas)³⁴.

Some individuals may also have NF2-related tumours localised to one part of the nervous system: e.g., a unilateral vestibular schwannoma with ipsilateral meningiomas or multiple schwannomas in one part of the peripheral nervous system (mosaic NF2): these phenotypes are caused by true somatic mutations of the NF2 gene³⁵⁻⁵⁰.

Some other individuals develop multiple non-vestibular, non-intradermal cranial, spinal and peripheral [histologically proven] schwannomas and are usually referred as having schwannomatosis [SWNTS]⁵¹⁻⁵⁹: two major clinical/molecular forms have been characterised so far, caused by mutation either in the SMARCB1 gene [SWNTS1: MIM # 162091] located at 22q11.23⁶⁰⁻⁶² or in the LZTR1 gene [SWNTS2: MIM # 615670] located at 22q11.21⁶³⁻⁶⁵.

Clinically overlapping features, between classical NF2 and alternate forms of NF2 [i.e., mosaic NF2 and schwannomatosis], are increasingly recorded^{38,40,43-47,50,58} and only sometimes sorted out by means of molecular analysis⁶⁶. Unilateral VSs (without NF2-related features) are relatively common in the general population [7% of all primary CNS tumours] as well as the occurrence of multiple meningiomas [including familial multiple meningiomas]. For all the above reasons and considerations, multiple sets of diagnostic criteria have been developed over the years for NF2 and its alternate/related forms^{44,46,55,57-59,67-72}. However, even individuals with bilateral VS especially late in life can have developed these by chance rather than having NF2⁵⁰.

Clinical manifestations and natural history in the paediatric age

Patterns of initial presentations

The pattern(s) of presentation (and the natural history) of NF2 in childhood, are very protean and differ from adulthood in many respects¹⁹⁻³³. In addition, children with NF2 whose onset is at or before puberty usually present differently from adolescents^{28 32 34}. The most common initial symptoms in adult onset NF2 are usually attributed to eight cranial nerve dysfunction and include hearing loss, tinnitus, or balance dysfunction^{1-4 12-14 73}. Conversely, in the pre-pubertal NF2 age group subtle skin tumours, small posterior capsular or cortical edge cataracts or neurological signs (see below) secondary to other-than-VSs cranial nerve(s) involvement and/or brainstem or spinal cord compression are more common and manifest long before dysfunction of cranial nerve VIII¹⁹⁻³⁴. A reversal pattern is encountered in the congenital form of NF2 (see below)³⁴, whose first nervous system manifestation of the disease is the presence of small (i.e., less than 1 cm) bilateral VS, recorded (incidentally) as early as the first months or days (Zampino G., personal observation) of life.

Skin manifestations

The initial clinical presentation of some NF2 children is when they manifest with few CAL spots (larger than in NF1, with more irregular margins and paler colour) (Fig. 1), and/or peripheral nerve tumours (Fig. 2) and are initially diagnosed as having either NF1 or sporadic benign neurofibromas or schwannomas, the revision of the diagnosis only occurring when the tumours are removed for histology showing a schwannoma not a neurofibroma or when other tumours become symptomatic or other NF2 features manifest^{19 23 28 32 34}. Some of the cutaneous and

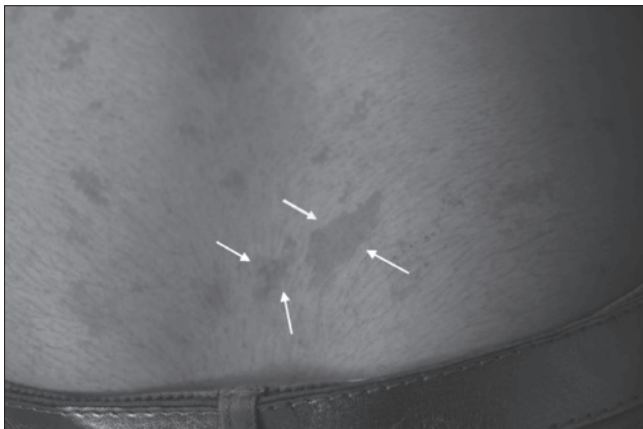


Fig. 1. Close view up of the skin of a child with NF2 showing multiple café-au-lait spots of different size and shape (the largest are indicated by white arrows): note the paler brownish colour and the irregular size and margins.

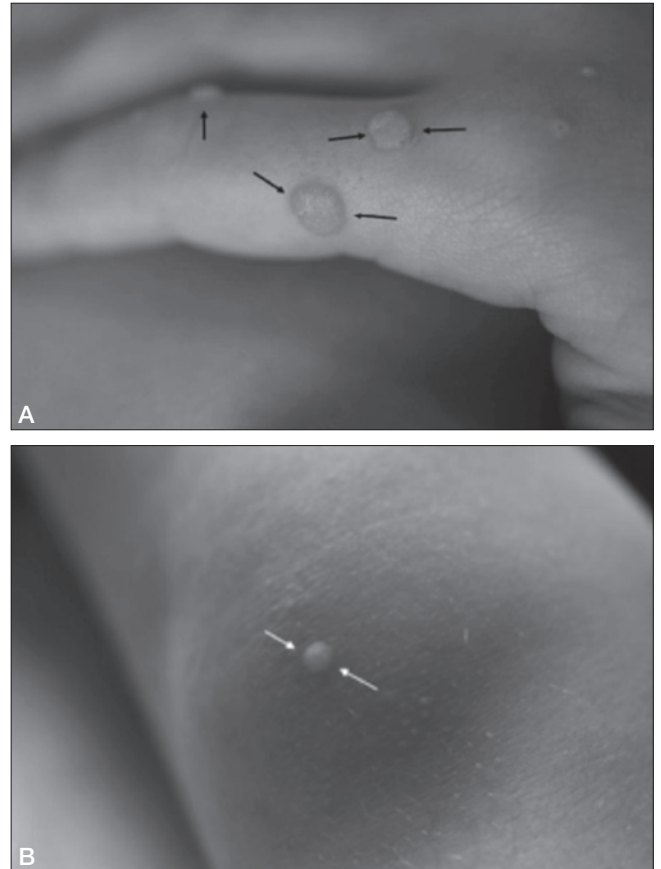


Fig. 2. Close view up of the skin of a toddler with "congenital" onset NF2 showing classical NF2 plaques (in atypical locations) over (A) the fingers (black arrows) and (B) the knee (white arrows).

nodular schwannomas are difficult to distinguish from neurofibromas from a clinical point of view. The only exception are the NF2-plaques which are schwannomas histologically and have a distinctive appearance as discrete, well-circumscribed, slightly raised pigmented cutaneous lesions (Fig. 2) often containing excess hair and usually less than 2 cm in diameter^{28 34}. Another important aspect is that the NF2-plaques, in this young age group, are usually and typically (mostly) localised in the upper and lower limbs (and the hands, feet and the face in the congenital forms) (Fig. 2 A-B)^{23 28 34}, differently from what is recorded in adult onset NF2 where the plaques are prevalently located in the trunk^{1-4 12-14}.

Ophthalmologic manifestations

Cataract is usually recorded in about 40% of NF2 children and is most commonly of the juvenile posterior sub-capsular or cortical types (Fig. 3a). A further 25% of cases may have retinal hamartomas. Overall, cataract and/or retinal changes are recorded in 40% to over 70% in the paediatric NF2 series so far reported^{19 23 28 30 32}. Notably, Evans et al.²³ recorded lower overall figures (3.3%) for cataract in their NF2 children, but these had not undergone systematic ophthalmological examination. In all the

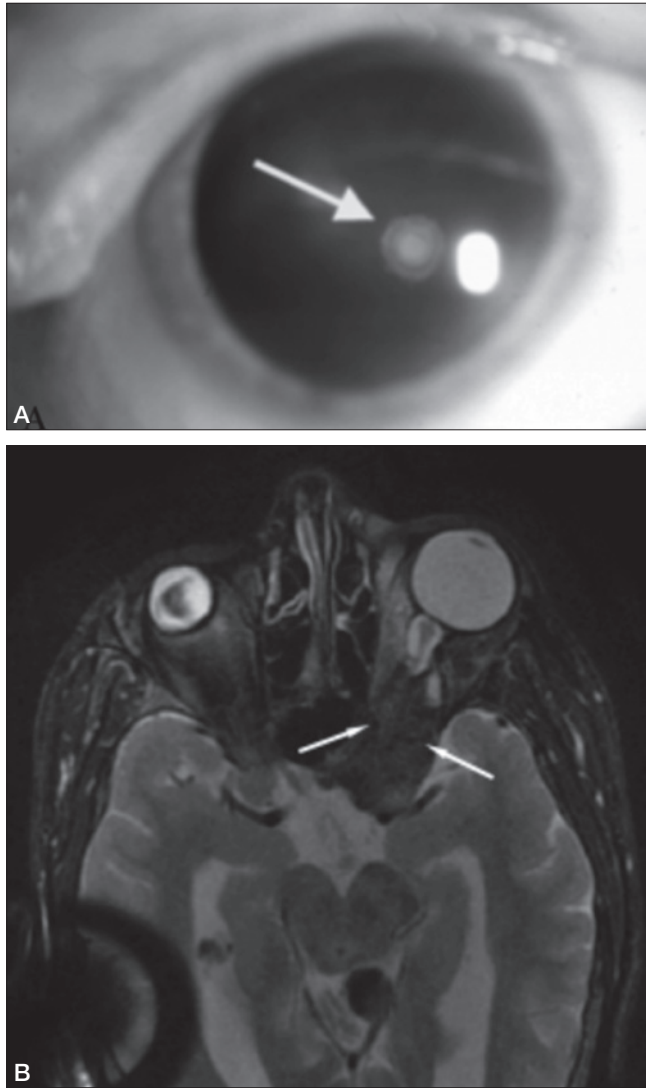


Fig. 3. (A) Magnified view of the eye in an NF2 child showing subcapsular lens opacities (white arrow); and (B) Axial T2-weighted magnetic resonance image of the brain in a child with “congenital” NF2 showing a hypointense area (white arrows) in the intra-orbital region (“intra-orbital meningioma”).

large NF2 series, lens opacities have usually been asymptomatic but when they are large can affect visual acuity in approximately 20% of NF2 patients¹⁹⁻³³. In childhood NF2 lens opacities can be detected by chance very early in life but often are thought to be sporadic and the children being discharged with follow-up^{19 24 26-28}. When the same patients later develop hearing or neurological signs, whose association with cataracts should have alerted for NF2, diagnosis was suspected²⁸.

A significant number of NF2 children may have idiopathic strabismus or amblyopia before the development of other neurological symptoms that prompt the diagnosis of NF2^{23 26-28}. Childhood onset strabismus and amblyopia have been frequently reported in adults with NF2^{1-4 12-14}. Even though either sign has been regarded as non specific²⁰ we recorded both signs in children who later on in their

NF2 course were shown at neuroimaging to have intraorbital or retro-orbital meningiomas (Fig. 3b) or schwannomas of the third, fourth, sixth and seventh cranial nerves or tumours in the brainstem.

Otolaryngology manifestations

Few NF2 children develop pure hearing or balance dysfunction as the first feature of their disease¹⁹⁻³³.

It must be noted that, in contrast to isolated unilateral VS, the NF2-associated VSs tend to cause symptoms at younger ages; in addition to that, NF2-associated VSs have larger size and a multilobulated macroscopic (Figs. 4a-b) and microscopic appearance when compared with their sporadic counterpart^{23 28} and on MRI are clearly multifocal on both branches of the vestibular nerves almost invariably including the 7th nerve branches and/or invading the internal auditory canal (Fig. 4c)⁷¹.

Some otolaryngology features can be caused by (other-than-eight) cranial nerve(s) involvement (Fig. 5) and/or to brain meningiomas (Fig. 6)^{23-26 28}.

Neurological phenotype

Neurological manifestations are dictated by the presence, localisation and extension of the lesions in the cranial and/or spinal regions and in the major cranial and/or peripheral nerve trunks: because of their initial, other-than-VSs, involvement most children with NF2 at onset may have isolated or multiple (other-than-eight nerve) cranial nerve deficits, neurological dysfunction related to intracranial, brainstem and/or spinal masses (most often meningiomas, schwannomas and ependymomas), including sensory and/or motor deficits, seizures and/or visual field defects, and peripheral neuropathy (with muscle wasting) secondary to schwannomas.

There are neither intellectual impairment nor learning difficulties.

Central nervous system imaging, which in NF2 must include full brain and spinal MRI, usually assess the tumour burden and its progression over time. In almost all children with the Wishart type NF2^{24-26 28} and in all children with congenital type NF2³⁴ we also recorded high signal lesions in the cortical or periventricular regions resembling those of cortical dysplasia or cortical alterations of the polymicrogyria type. These hyperintensities (which do not enhance after gadolinium administration) have been so far attributed either to meningoangiomas or to hamartomatous tissue; the “pure” cortical dysplasia is often associated with other brain anomalies (e.g., colpocephaly). Interestingly, these cortical abnormalities do not behave as true masses or classical dysplasia being asymptomatic initially: however, after puberty we recorded generalised tonic-clonic seizures [easily treatable with classical anti-convulsants (e.g., valproic acid)] in most of these children with cortical abnormalities^{28 34}.

The brainstem and/or the spine are usually involved by in-

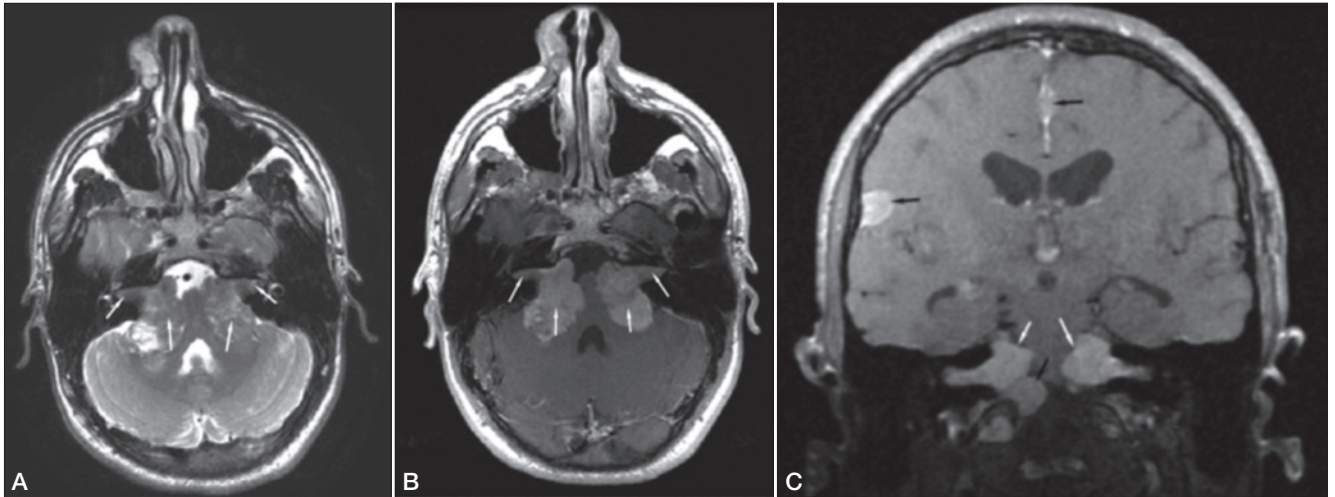


Fig. 4. Axial T2-weighted (A) and T1-weighted contrast enhanced (gadolinium) (B) magnetic resonance images of the brain in an adolescent with Nf2 showing bilateral schwannomas (as hypointense lesions: white arrows) with intracanalicular extension (outer white arrows); (C) Coronal T1-weighted contrast enhanced (gadolinium) magnetic resonance image of the brain in a child with NF2 showing bilateral schwannomas (as hyperintense lesions: white arrows) and multiple meningiomas (black arrows).

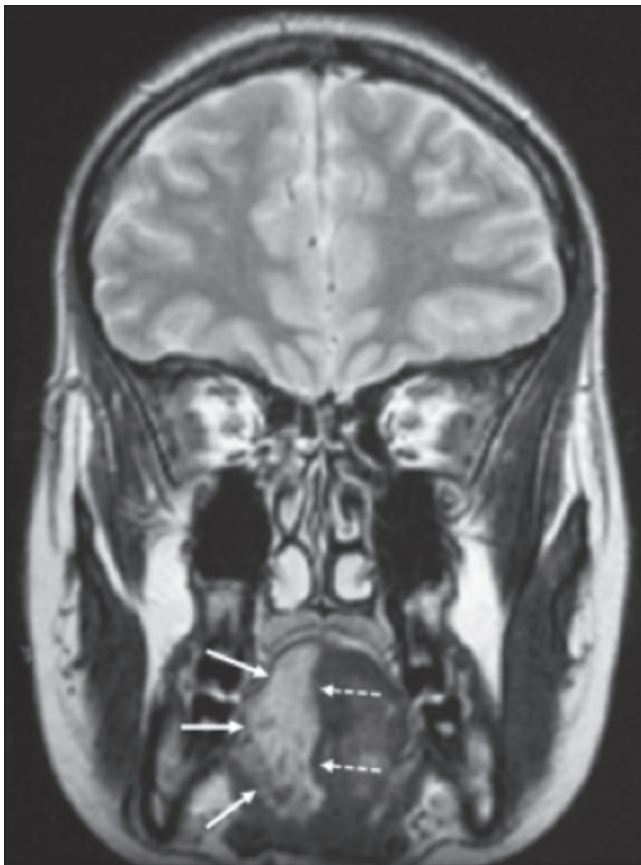


Fig. 5. Coronal T2-weighted magnetic resonance image of the brain showing a hyperintense aspect of the right hemi-tongue (seen in the left side of the Fig.: white arrows), which is atrophic because of a schwannoma of the 12th cranial nerve (note the normal aspect of the contralateral tongue delineated by the dashed white arrows).

trinsic tumours (e.g., ependymomas, astrocytomas) (Fig. 7), intradural meningiomas (Fig. 8a), and/or by peripheral schwannomas affecting the paravertebral ganglia and/or extending into the extra- or intradural spaces (Fig. 8b).

Peripheral nervous system imaging reveals solitary or (more often) multiple schwannomas affecting, with variable extension, multiple nerves or multiple (major) nerve trunks and/or the paravertebral ganglia²⁰⁻³³. MRI is essential for initial diagnosis and differential diagnosis with NF1 and related forms, mosaic/segmental NF2 and schwannomatosis (see below).

Peripheral (axonal/demyelinating) neuropathy (confirmed by neurophysiology testing and without MRI evidence of underlying tumours) and monomelic atrophy (with wasting of a single limb) are frequently recorded (but often under-recognised) irrespective of age in children (and adults) with NF2 [symmetric and/or asymmetric distal sensorimotor neuropathy ranging from mild to severe degrees]²⁰⁻³³: this neuropathy is thought to arise from neurofibromatous changes in peripheral nerves.

Congenital NF2

This form is characterised by the occurrence of^{20 23 27 34}: (1) small (< 1 cm), bilateral vestibular schwannomas (VSS) detected (as an incidental finding) at MRI by the first months of life (Fig. 9a) [or at birth: Zampino G., et al. at the Department of Paediatrics of the Catholic University of Rome, Italy, 2015; personal observation] that are asymptomatic for 10 to 15 years, with usually sudden and rapid (< 12 months) progression; (2) devel-

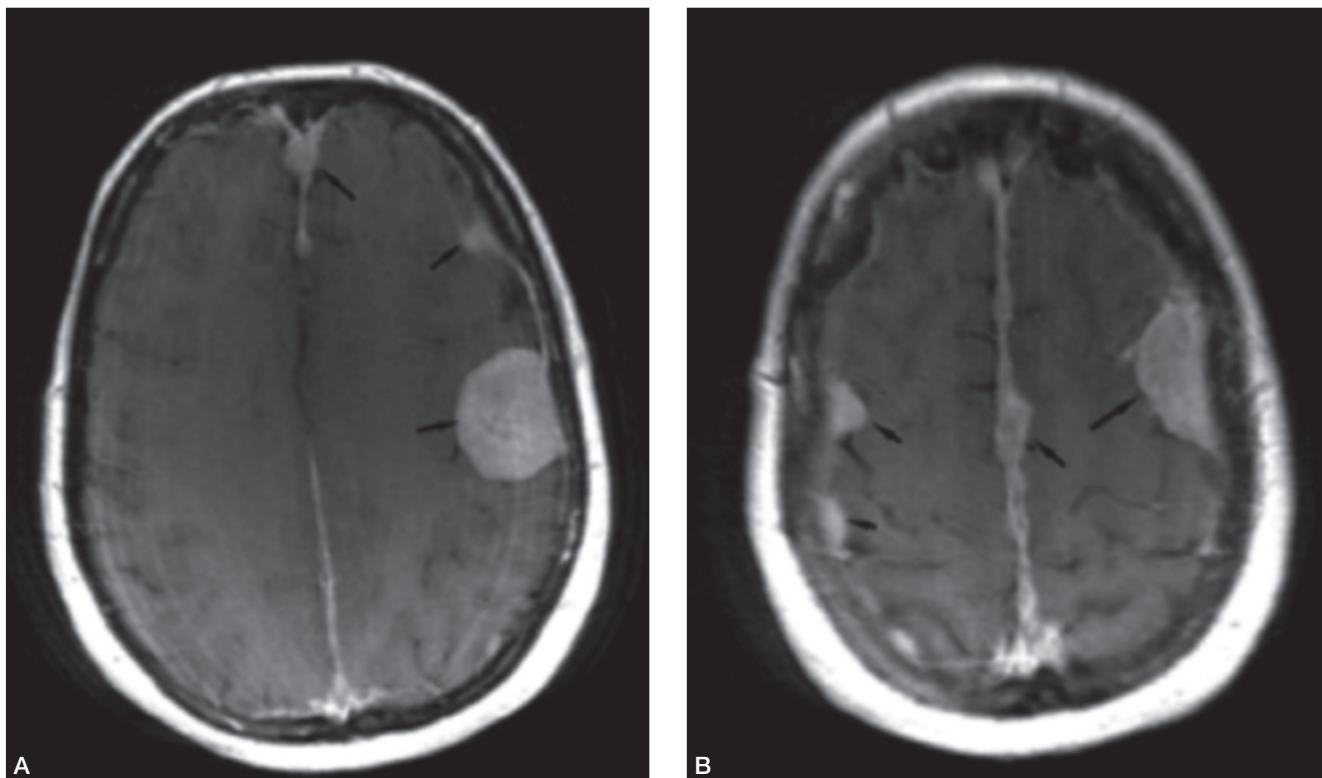


Fig. 6. Axial T1-weighted contrast enhanced (gadolinium) (A-B) magnetic resonance images of the brain showing multiple meningiomas as hyperintense lesions (“meningiomatosis”).

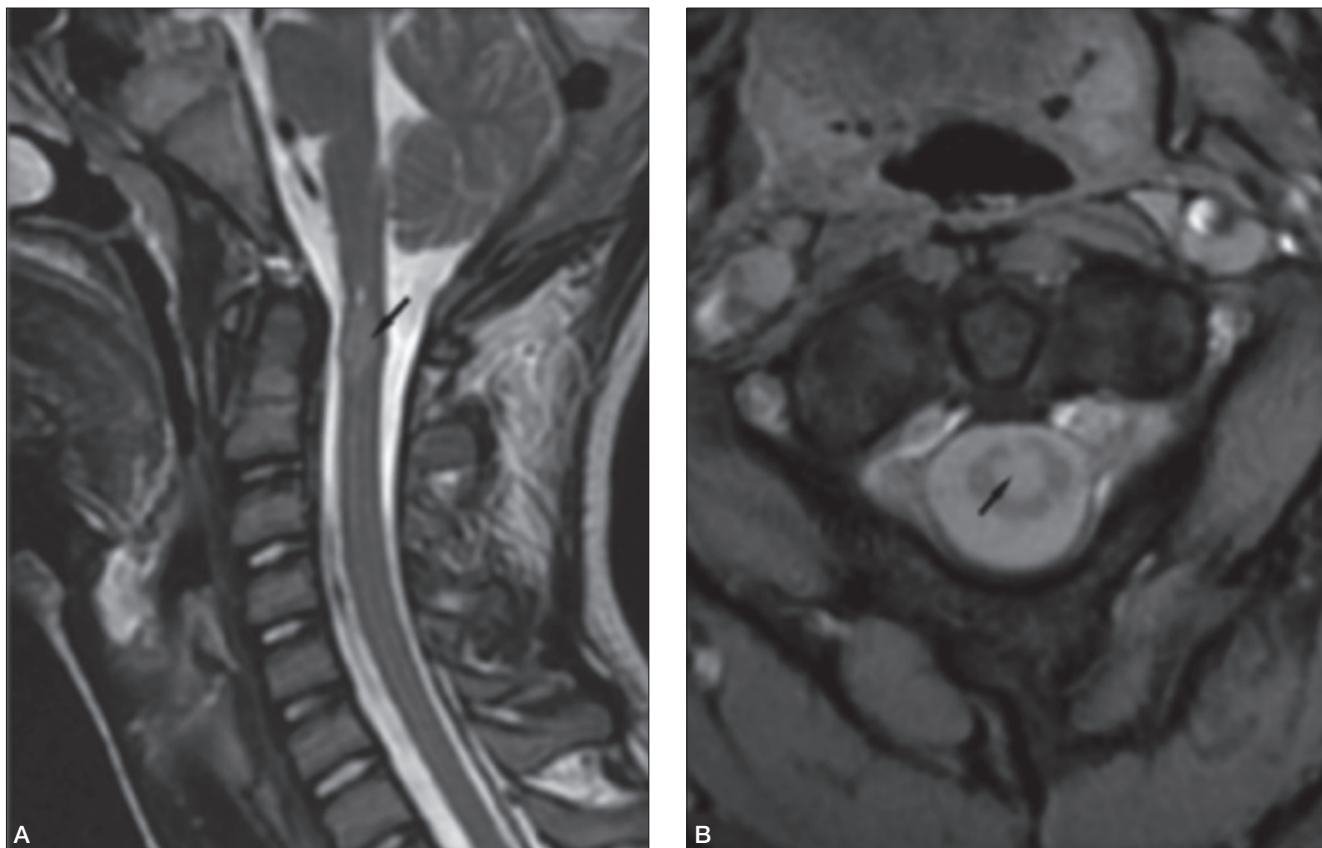


Fig. 7. Sagittal (A) and axial (B) T2-weighted magnetic resonance images of the spinal cord in a child with NF2 showing round hyperintense lesions of the cervical cord at the C1 level (intraspinial ependymoma).

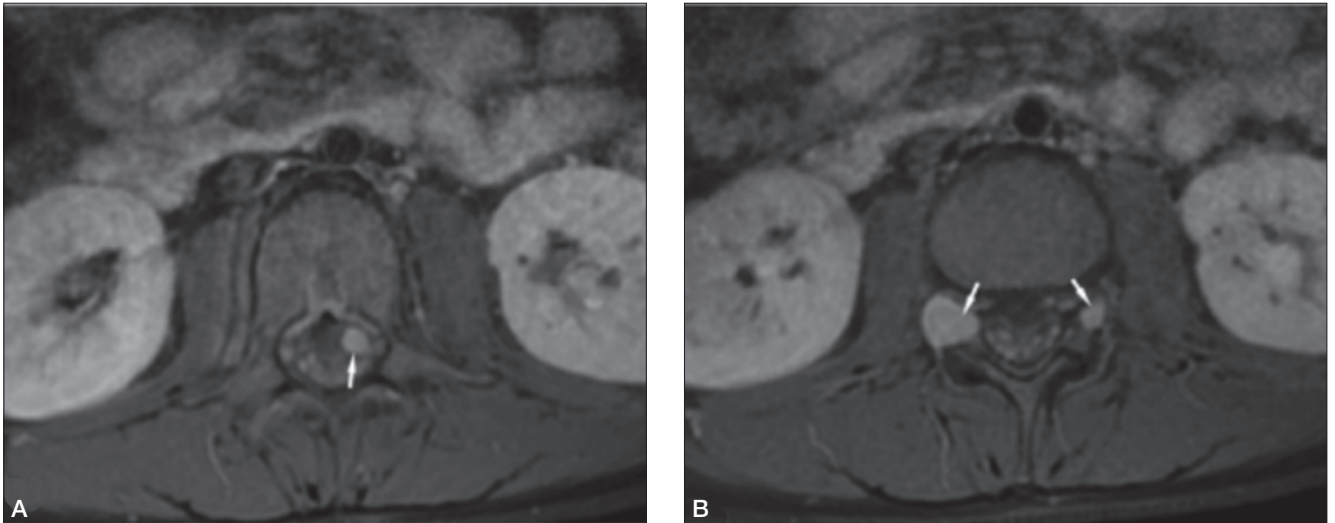


Fig. 8. Axial T1-weighted contrast enhanced (gadolinium) (A-B) magnetic resonance images of the spinal cord in an adolescent with NF2, showing (A) an intradural meningioma (white arrow) and (B) two schwannomas of the spinal nerves (white arrows).

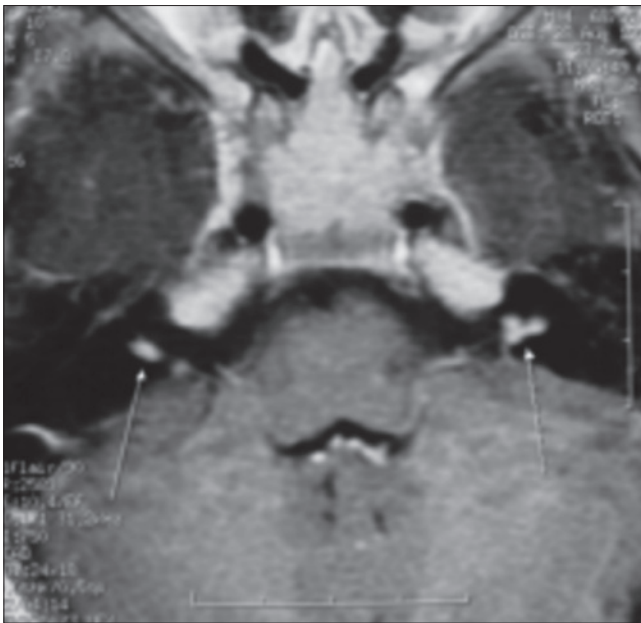


Fig. 9. Axial T1-weighted magnetic resonance image of the brain in a child with a congenital form of NF2 obtained at age 4 months showing bilateral vestibular schwannomas (case 1, ref. 34).

opment of large numbers of skin NF2 plaques mainly in atypical locations (i.e., face, hands and knees) (Fig. 2), which reverted to normal skin appearance at the time of VSs progression in the series so far reported³⁴; (3) lens opacities (Fig. 1) and NF2 retinal changes detected as early as the first months of life; (4) cortical malformations and/or diffuse (asymptomatic) high signal lesions at brain MRI in the periventricular regions; and (5) unaffected first-degree relatives who do not harbour NF2 gene abnormalities.

Pathophysiology: NF2 gene and merlin/schwannomin

NF2 gene

NF2 is caused by mutations in the NF2 gene at chromosome 22q12.1, which encodes for a protein called merlin or schwannomin, most similar to the extrin-reaxin-moesin (ERM) proteins (Fig. 10)⁹⁻¹¹: these are membrane-cytoskeleton scaffolding proteins (i.e., linking actin filaments to cell membrane or membrane glycoproteins), which act as critical regulators of contact-dependent inhibition of proliferation and function at the interface between cell-to-cell adhesion, transmembrane signalling, and the actin cytoskeleton, thus contributing to maintain normal cytoskeletal organisation, to modulate cellular motility, attachment, remodelling and spreading and to regulate growth (tumour suppression function)⁷⁴.

Merlin structure and conformation

Merlin isoforms. The NF2 gene encodes two merlin isoforms⁷⁵: (1) the longer, dominant isoform 1 (merlin-1 or merlin), a 595-residue protein, which presents an extended carboxy-terminal tail that is encoded by exon 17; and (2) the merlin isoform 2 (merlin-2), which contains an alternatively spliced exon 16 which ends in a stop codon, encoding 11 unique residues following amino acid 579 (as compared to Merlin-1)⁷⁶. Merlin-2 lacks the carboxy-terminal residues required for intra-molecular binding between the amino-terminal FERM domain and the carboxy-terminal hydrophilic tail, possibly leading to a constitutively open conformation (Fig. 10). In vitro and in vivo studies have demonstrated that merlin-2 inhibits cell proliferation and attenuates the downstream mitogenic signalling to the same extent of its isoform merlin-1 (thus, apparently irrespective of the open vs. closed state)⁷⁷.

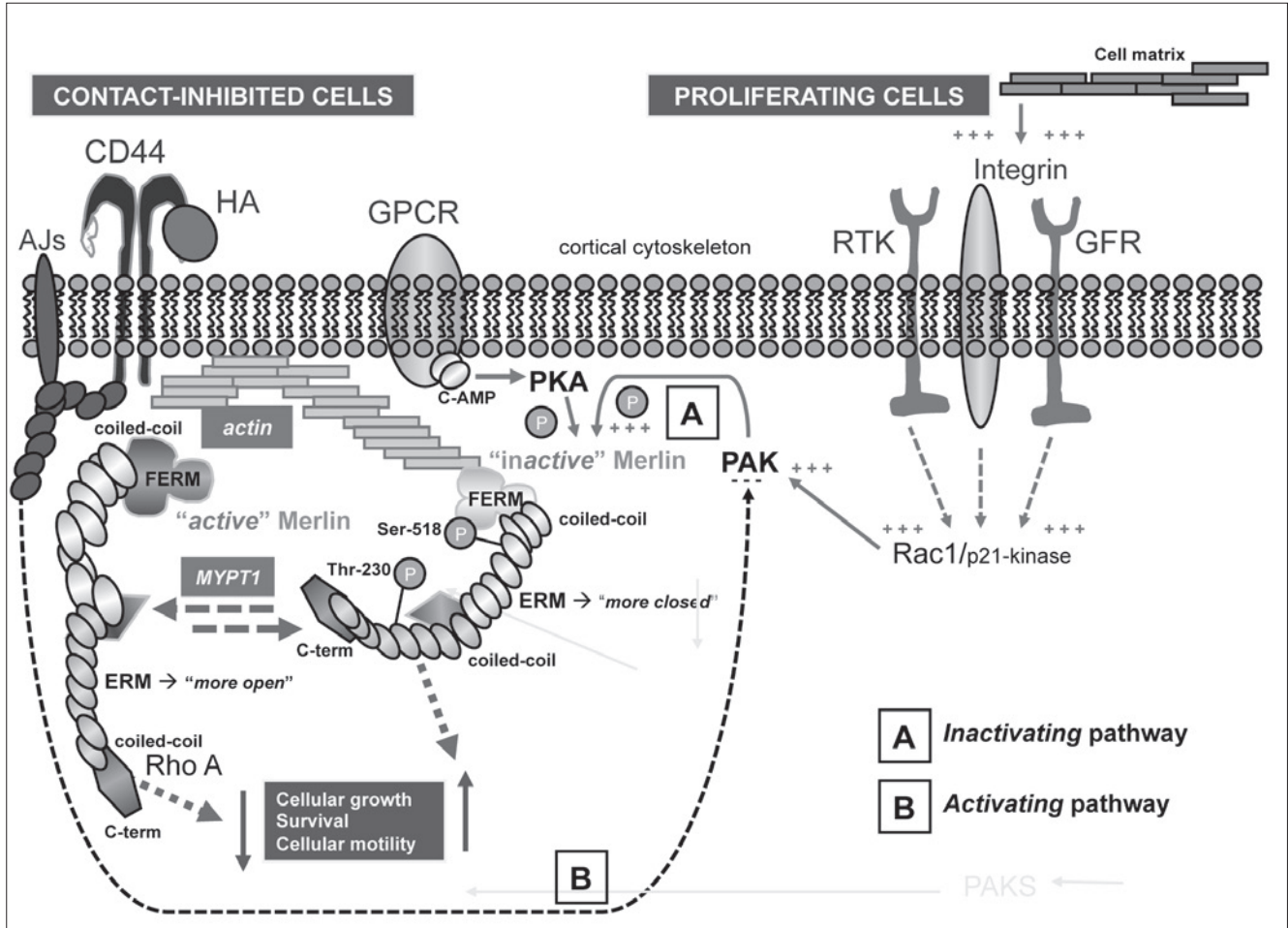


Fig. 10. Merlin-signalling pathway - In more recent years, several lines of evidence have suggested that Merlin exists in multiple states, which vary from "fully open" to "fully closed" [including "more closed" and "more open" states (see text for further explanation)]. In its "more closed" frame **Merlin** is hyperphosphorylated (has many "P" groups) and connected to cytoskeletal actin (because of an increase in intra-molecular bounds - secondary to the increased "P" groups - which contribute to fold the protein structure) (**inactive Merlin**): thus, the *mitogen-signalling* pathway [activated via the PAK and PKA pathways], is active and increases the cellular proliferative phenomena; in its "more open" frame **Merlin** is dephosphorylated (has less "P" groups) and is disconnected from actin (**active Merlin**): thus, the *mitogen-signalling* pathway, is inactive and decreases cellular growth, survival and cellular motility. In *proliferating cells*: (a) interactions between the extracellular matrix and the GFR/RTK/integrin proteins (and their membrane receptors) trigger the Rac1/PAK pathway; and (b) interactions between the GPCR receptors and c-AMP trigger the PKA pathway, both activating in turn the structural changes of Merlin [i.e., phosphorylation, increase in intra-cellular bounds and protein folding], which switches to a "more closed" (inactive) state [**A: inactivating pathway**]. In *contact-inhibited cells*, different phosphatases (mediated by the adhesion junctions' molecules and by HA bounds to CD44 receptors), via activation of the MYPT1 dephosphorylation and inhibition of the PAK/PKA pathway, dephosphorylate Merlin (\rightarrow switching to active form), which in turn leads to decreased cellular growth [**B: activating pathway**]. AJs = adhesion junction proteins; c-AMP = cyclic AMP; CD44 = antigen CD44; C-term = carboxy-terminal hydrophilic tail of the Merlin protein; coiled-coil = a structural motif (part) of the Merlin protein in which alpha-helices are coiled together like the strands of a rope; ERM = Ezrin-radixin-moesin proteins; FERM = (F)-Four-point-one (4.1) protein-ERM domain of the Merlin protein (amino-terminal); GFR = growth factor receptor; GPCR = G-protein-coupled receptor; HA = hyaluronic acid; MYPT1 = myosin phosphatase target, subunit 1; P = phosphorylation groups; PAK = serine/threonine p21-activated kinase; PKA = protein kinase A enzyme; Rac1 = Rho family small GTP binding proteins; Rho = RAS homologue gene family; RTK = receptor tyrosine kinase; Ser-518 = Serine-518; Thr-230 = Threonine 230; + + + = stimulation; - - - = inhibition (from Ruggieri et al., 2015³⁵ and Ruggieri et al., 2015³⁶, adapted and modified).

Merlin properties. The similarities of merlin to its familial group of ERM proteins are responsible for its cytoskeletal-binding properties: e.g., merlin links the cytoskeleton to the cell membrane either directly (through integral membrane proteins) or indirectly (through membrane-associated proteins)⁷⁸.

Merlin domains. Merlin is divided into three structurally

distinct regions: (1) an amino-terminal FERM (Four-point-one, ezrin, radixin, and moesin) domain; (2) an α -helical coiled-coil domain; and (3) a carboxy-terminal hydrophilic tail. The FERM domain shares 65% sequence identity with canonical ERMs, but, differently from the other ERM proteins, merlin lacks the actin-binding site in the C-terminal domain, which is highly conserved in the

other ERMs protein providing these proteins with their function at the cortical cytoskeleton⁷⁹. In merlin, the binding site of actin is located in the glutathione S-transferase N-terminal domain.

“Closed” (active) vs. “open” inactive forms. Merlin switches from a closed state to an open state by phosphorylation at serine 518 (Fig. 10)⁸⁰. In the past decades, the evidence that Merlin-2 -which lacks the carboxy-terminal domain, thus lacking the possibility to reach a “closed” state - failed to exert tumour suppression activity and/or contact inhibition, led researchers to state that “active” merlin functioned in a closed conformation caused by the dephosphorylation at Serine-518, while the open form [i.e., the solely form thought to be reached by merlin-2] was “inactive” and phosphorylated.

“More closed” (inactive) vs. “more open” (active) forms. In more recent years, the above (simplified) interpretation was questioned and several lines of evidence now suggest that merlin exists in multiple states, which vary from “fully open” to “fully closed”. In addition to that, it was demonstrated^{79,81} that merlin-2 is able to suppress growth in mammalian cell lines, suggesting that the interdomain binding is dispensable for Merlin’s adhesion signalling: the phosphorylated merlin [merlin-2] displays higher interdomain binding and therefore it is able to inhibit cell growth (even) in its open state. Furthermore, it has been observed that a stably closed merlin mutant does not suppress cell growth, whereas merlin-2 and the S-518 phospho-deficient mutant, which are defective in interdomain binding and therefore more open, can suppress cellular growth in the same way as it does the wild-type merlin. It is now accepted that the “more open” forms (Fig. 10B) of merlin are more active as anti-oncogenic proteins, while the “more closed” forms (Fig. 10A) lacks this function.

FERM domain. Recent genetic evidence has suggested that a crucial role in Merlin’s anti-tumour efficacy is played by the FERM domain, and in particular by the “Blue-box motif” within the subdomain F2, correspondent to the residues 177-183 in human merlin. In this respect, it is now well known that patients with truncating mutations show a more severe clinical picture, with a higher tumour burden. However, it must be said also that missense mutations involving residues 177-183 in the F2 domain can lead to more severe forms of NF2. Substitution of F2 domain with that of ERM protein Ezrin abolishes Merlin’s anti-oncogenic activity, while substitutions of F1 or F3 domains does not affect cell proliferation^{81,82}. In contrast, mutations involving the coiled-coil region or the carboxy-terminal tail have rarely been observed in NF2 patients, thus demonstrating the crucial role of FERM domain in the pathogenesis of the disease⁸³. It is presumable, that the α -helical domain and the C-terminus function in maintaining merlin in its inactive conformation during the normal biological cellular growth and could contribute to contact inhibition.

Post-translational regulation of Merlin

Merlin’s function is mediated by different signalling pathways within the cell, which have been extensively characterised⁸⁴.

Inactivating pathways. In proliferating cells, integrin-mediated anchorage to the cell matrix and stimulation of receptor tyrosine kinases (RTKs) activate Rac [Rac1/p21-kinase], in turn activating PAK and leading to phosphorylation of merlin at serine 518 (Fig. 10B). Serine 518 phosphorylation increases the interdomain binding between Merlin’s carboxy-terminus and FERM domain, maintaining merlin in a “more closed”, inactive form: the inactivation is probably due to (a) masking of protein-interacting domains on FERM domain, which are necessary for downstream signalling or (b) occlusion of a presumable nuclear localization signal⁸⁵. Merlin is inactivated mostly via the PAK/Rac pathway, which is initiated by RTK and Integrin receptors in the cell wall. The activation of PAK leads to the phosphorylation of Merlin in position 518 and the latter may be necessary for subsequent phosphorylation of other sites. Moreover, also protein kinase A enzymes can independently phosphorylate Merlin at serines 518 and 10⁸⁶: this could be particularly relevant in Schwann cells, which are sensitive to the cyclic AMP-PKA signalling axis⁸⁷. Protein kinase B, also named AKT, can induce phosphorylation at threonine 230 and serine 315, causing decreased interdomain binding, and the interaction with Phosphoinositide and PIKE-L⁸⁸. Loss of PTEN function (related to an increased oncogenic risk) which results in increased PI3K-AKT activity can induce further merlin inactivation⁷⁷.

Activating pathways. In contact-inhibited cells, dephosphorylated merlin accumulates (Fig. 10B) as a result of intercellular adhesions, which lead to PAK inhibition^{82,84}. Different phosphatases may contribute in dephosphorylating merlin, regulating its activity, but the key role is played by cadherins and CD44 receptors, which activate merlin through its dephosphorylation by myosin phosphatase targeting subunit 1 (MYPT1)⁸⁹. It has been showed that the protein kinase CPI-17 (c-potentiated phosphatase inhibitor 17 kDa weighed) inhibits MYPT1 and causes a reduced activation of merlin⁹⁰. By contrast, cadherins cause loss of function of PAK protein, thus inhibiting the inactivation of Merlin.

Merlin downstream

Effects mediated by Merlin in the membrane organisation of proteins include cell-to-cell adhesion, cytoskeletal architecture, interaction with cytosolic proteins and regulation of diverse downstream pathways, including nuclear and hippo pathway regulation.

Merlin-2, via the GTPase Rho/RhoKinase signalling network, promotes phosphorylation of neurofilaments that are neuron-specific intermediate filaments essential for axon structure and caliber⁸².

Merlin-1 interacts with membrane associated proteins

where it regulates the formation of membrane domain, with a function of contact inhibition, by interacting with several proteins localised in the plasma membrane, including other ERMs, the intracellular domain of CD44, α -catenin and angiomin.

The interactions with α -catenin have been demonstrated in keratinocytes and skin epithelium: Merlin promotes the binding of β -catenin and Par3, needed for the maturation of adherence junctions, and with 14-3-3 protein, which sequesters phosphorylated YAP, suppressing YAP-mediated transcription. β -catenin also interacts with APC tumour suppressor, enhancing its activity⁹¹. The interaction with angiomin regulates contact inhibition and tumour suppression through Patj, Pals1 and Mupp1 proteins by suppressing the Rac-PAK signalling. It is important to underline that both inactive and active forms of merlin interact with angiomin, independently from growth suppressive stimuli⁹². Other interactions of merlin occur with cholesterol-dependent membrane domains as a result of phosphoinositide binding, or directly with cytoplasm proteins to control cytoskeletal dynamics, vesicular transport and microtubule stabilisation, which could function in promoting the transport of anti-mitogenic biomolecules or regulating the availability of growth factors in the cytoplasm⁹³⁻⁹⁶.

In the nucleus, dephosphorylated Merlin inhibits the pro-oncogenic CRL4^{DCAF1} E3 ubiquitin ligase, even if Merlin lacks a canonical nuclear localisation sequence. It is presumable that Merlin interacts with the nucleus through a motif in the C-terminus promoting nuclear export by the CRM1-exportin pathway, or by FERM domain residues necessary for nuclear translocation⁸⁵.

The reduction of functions of CRL4 is mediated by interactions of merlin with DCAF1 (DDB1 and Cul4-associated factor 1), a substrate recognition component of the CRL4^{DCAF1} complex, essential for epigenetic modifications that regulate DNA methylation and therefore gene transcription, in particular during embryogenesis and tumourigenesis⁹⁷. Merlin's FERM domain binds one of the carboxy-terminal acidic tail of DCAF1, directly competing with CRL4 or causing structural changes, inhibiting its binding with CRL4⁸⁵.

A further role of Merlin is in the Hippo pathway, which is a potent regulator of organ size in the whole animal kingdom. Disruption of this pathway causes organ overgrowth and tumourigenesis, through an overexpression of YAP and TAZ transcriptional coactivator, which lead to increased transcription of genes that drive proliferation, evasion of apoptosis and stemness⁹⁸⁻⁹⁹. It has recently been shown that merlin can interact with Kibra to activate the Hippo kinase cascade, maybe through interactions and modulation of angiomin in the tight junctions. Interestingly, angiomin directly binds YAP and TAZ and retains them at the cortex.¹⁰⁰ Moreover, Merlin's inhibition of CRL4^{DCAF1} ligase causes a reduced inhibition of the Lats kinases, restrict YAP signalling¹⁰¹.

The interplay of pathways

In summary, Merlin regulates proliferation acting via some cascades, which include Hippo/Mst and Warts/Lats proteins which in turn regulate the Yorkie/Yap complex on one side, and on the (RTK) Ras GAP/Raf proteins [which regulate the MEK/ERK pathway] and the PI3K/AKT proteins [which regulate the mTOR pathway] (Figs. 10, 11)⁷⁴⁻⁸¹⁻⁸⁴.

Despite the common action on Ras/MEK/ERK and PI3K/AKT/mTOR pathways, schwannomin does not interfere with learning and memory formation as it does neurofibromin (i.e., the affected protein in NF1) and the NF2 neurological phenotype seems, apparently, solely secondary to tumour formation and progression.

For the four-hit, three-steps model of tumourigenesis explaining the schwannomatosis phenotypes see below (under schwannomatosis) (Fig. 12).

Genotype-phenotype correlations

Germline mutations occur throughout the first 15 exons but not in exons 16 and 17 of NF2⁴⁹. The predominant mutations are nonsense mutations at CpG islands but all forms of NF2 mutation occur including large multiexon and whole gene deletions. There is a relatively strong genotype phenotype correlation both with type and position of NF2 germline mutation¹⁰²⁻¹⁰⁶.

Individuals with truncating mutations (nonsense/frameshift) have earlier onset of symptoms, more meningiomas and spinal tumours and die younger. Truncating mutations in exon 1 and 14/15 cause milder disease. Splice site mutations are milder than truncating mutations and there is also a positional effect with early mutations being more severe. Large deletions/duplications are intermediate with missense mutations being associated with the mildest form¹⁰⁴⁻¹⁰⁶⁻¹⁰⁷.

Alternate/related forms of Neurofibromatosis 2

Mosaic NF2

Some individuals may have a unilateral eighth-nerve schwannoma associated to ipsilateral meningiomas [i.e., unilateral NF2 involvement of the CNS] or multiple schwannomas localised to one part of the peripheral nervous system³⁵⁻⁵⁰ (the latter going into the differential diagnosis with schwannomatosis: see below)⁶⁶. As somatic mosaicism for the NF2 gene is the causative phenomenon they are also referred to as having mosaic NF2⁴⁴.

Schwannomatosis

Schwannomatosis [SWNTS] is characterised by the development of multiple non-vestibular, non-intradermal cranial, spinal and peripheral schwannomas [histologically proven]⁵¹⁻⁵⁹. Other NF2 features such as cataracts and ependymoma are absent, but meningiomas may occur with SMARCB1 mutations¹⁰⁸, even though these are not

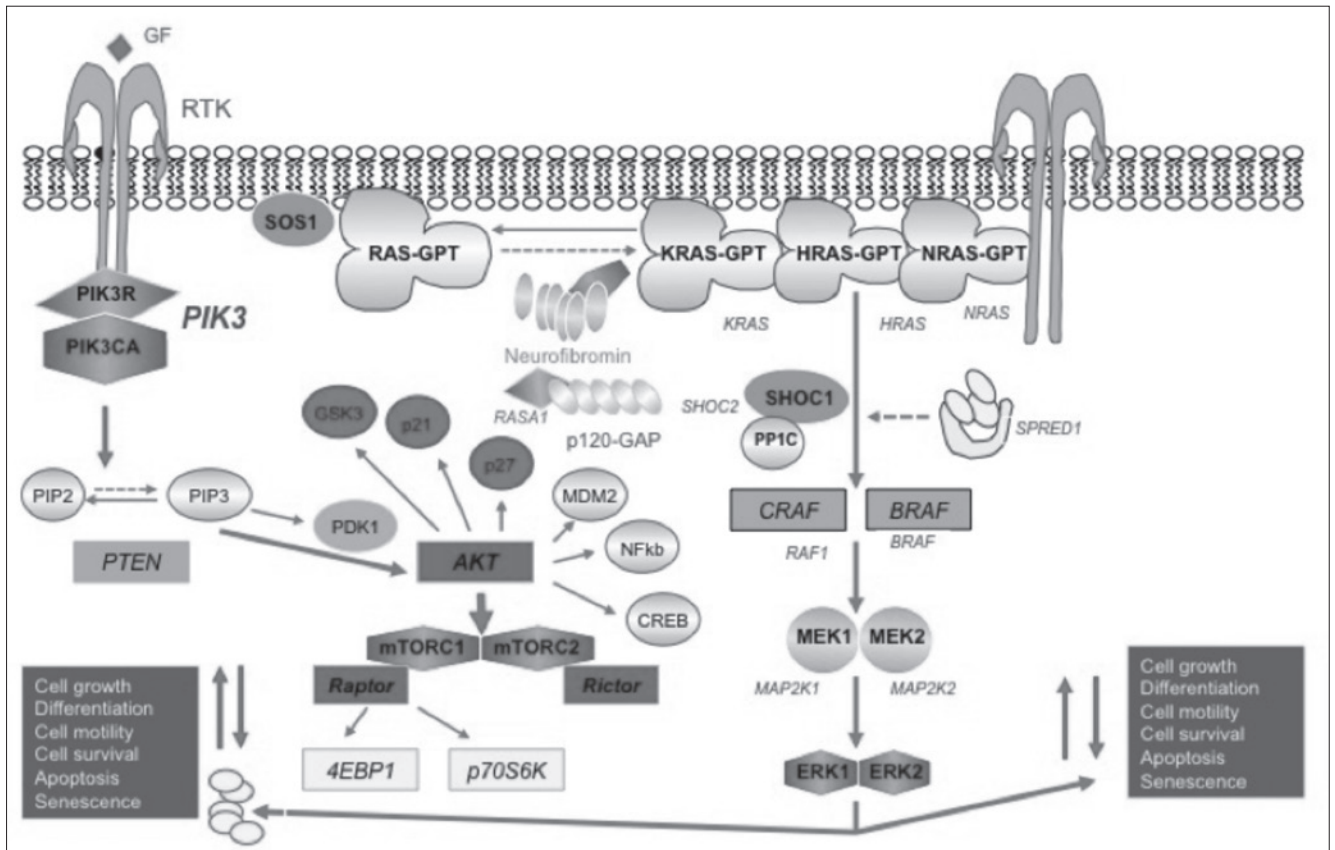


Fig. 11. Diagram showing the PIK3/AKT/MAPK signalling pathway (see text for explanation): AKT, AK (Akr mouse) strain transforming; BRAF, B-raf (rapidly accelerated fibrosarcoma); CRAF, C-raf (rapidly accelerated fibrosarcoma); CREB, cAMP response element-binding protein; 4EBP1, Eukaryotic translation initiation factor 4E-binding protein 1; ERK1, extracellular signal regulated kinase 1; ERK2, extracellular signal regulated kinase 2; GSK3, glycogen synthase kinase 3; HRAS, Harvey rat sarcoma viral (V-ras) oncogene homolog; HRAS-GTP, Harvey rat sarcoma viral (V-ras) oncogene homolog glucose triphosphate; KRAS, Kirsten rat sarcoma viral (V-ras) oncogene homolog; KRAS-GTP, Kirsten rat sarcoma viral (V-ras) oncogene homolog glucose triphosphate; GF, growth factor; MAP2K1, mitogen activated protein 2 kinase 1; MAP2K2, mitogen activated protein 2 kinase 2; MDM2, mouse double minute 2 homolog; MEK1, MAPK-extracellular kinase 1; MEK2, MAPK-extracellular kinase 2; mTORC1, mammalian target of rapamycin complex-1; mTORC2, mammalian target of rapamycin complex-2; NFkb, nuclear factor kappa-light-chain-enhancer of activated B cells; NRAS, Neuroblastoma rat sarcoma viral (V-ras) oncogene homolog; NRAS-GTP, Neuroblastoma rat sarcoma viral (V-ras) oncogene homolog glucose triphosphate; p70S6K, protein 70 serine/threonine 6 kinase; p120-GAP, p120-GTPase activating protein; PDK1, Phosphoinositide dependent kinase 1; PIK3, phosphatidylinositol-3-kinase; PIK3CA, phosphatidylinositol-3-kinase catalytic a subunit; PIK3R, phosphatidylinositol-3-kinase regulatory subunit; PIP2, phosphatidylinositol bi-phosphate; PIP3, phosphatidylinositol tri-phosphate; PP1C, protein phosphatase 1 catalytic subunit C; PTEN, phosphatase and tensin homolog; RAF, rapidly accelerated fibrosarcoma protein; Raptor, regulatory associated protein of mTOR; RAS-GTP, rat sarcoma viral (V-ras) oncogene homolog glucose triphosphate; RASA1, rat sarcoma viral (V-ras) oncogene homolog GTPase activating protein 1; Rictor, rapamycin insensitive companion of mTOR; RTK, tyrosine kinase receptor; SHOC1, suppressor of *C. elegans* homolog 1 protein; SHOC2, suppressor of *C. elegans* homolog 2 protein; SOS1, son of Sevenless 1 homolog; SPRED, Sprouty-related EVH1 domain-containing protein 1 (from Ruggieri et al., 2015³⁶, adapted and modified).

a prominent feature: SMARCB1 mutations are not a common cause of multiple meningiomas¹⁰⁹.

Two major clinical/molecular forms have been characterised so far⁵⁹⁻⁶⁶: (1) SWNTS1 [MIM # 162091]⁶⁰⁻⁶² caused by constitutional (germ-line) inactivating mutations of the SMARCB1 gene [SWI/SBF-related matrix-associated actin-dependent regulator of chromatin, subfamily B, member 1; MIM # 601607] located 6 Mb centromeric to the NF2 gene at 22q11.23, which encodes a SWI/SNF ATP-dependent nuclear chromatin remodelling protein, which is part of a complex that: (a) relieves repressive chromatin

structures, allowing the transcriptional machinery to access its targets more effectively; (b) also binds to and enhances the DNA joining activity of HIV-1 integrase [SWI/SNF is a tumour suppressor implicated also in the genesis of malignant rhabdoid tumours]. The SWNTS1 phenotype includes families with multiple schwannomas and multiple extra-axial/extra-medullary meningiomas (and also a unilateral vestibular schwannoma)⁵⁸; and (2) SWNTS2 [MIM # 615670]⁶³⁻⁶⁵ caused by constitutional/germ-line inactivating mutations of the LZTR1 gene [Leucine zipper-like transcriptional regulator 1; MIM # 600574],

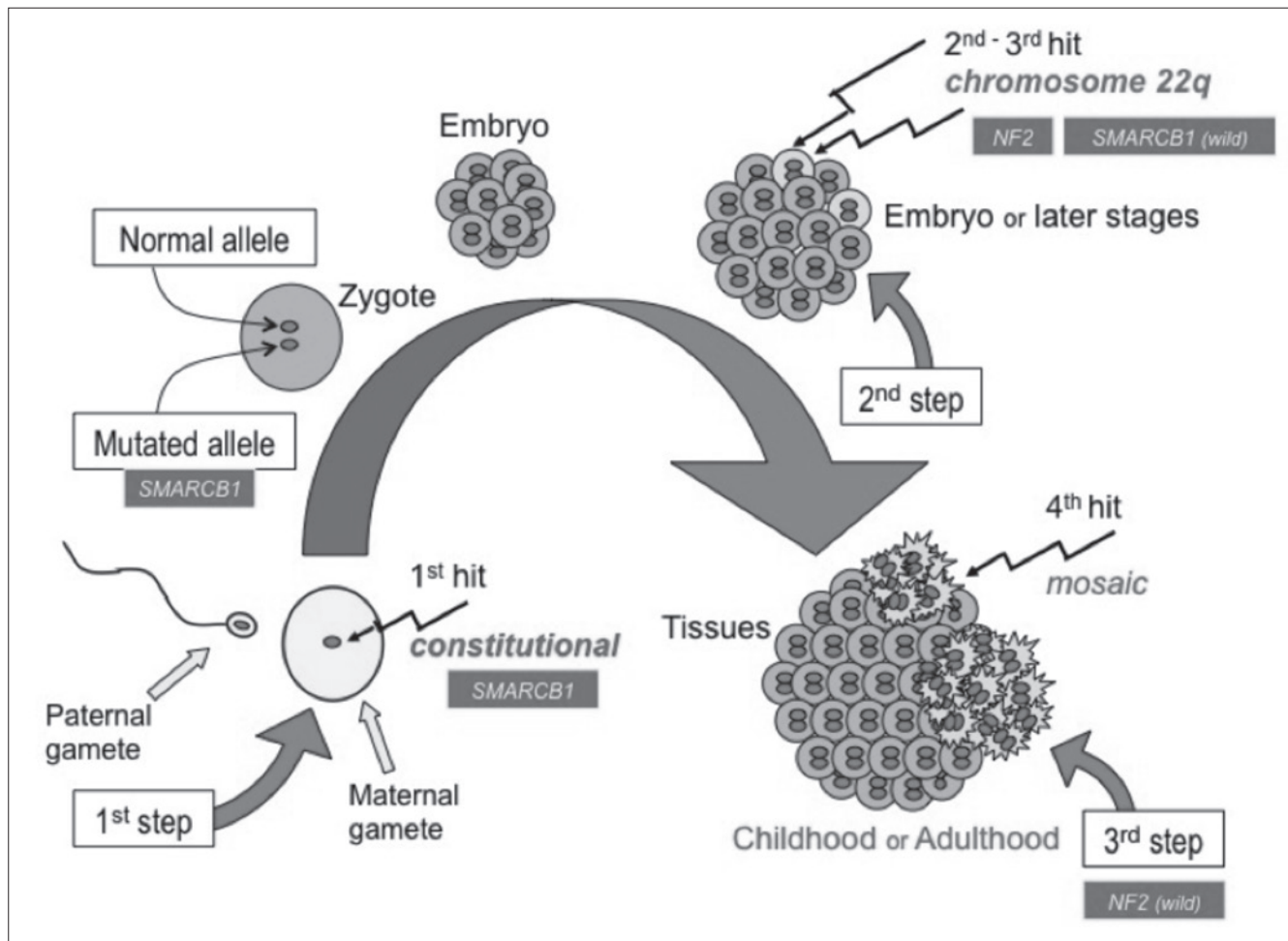


Fig. 12. The four hits-three steps model of tumorigenesis in schwannomatosis [in the Fig. the SMARCB1 gene is represented, but the model is alike for the LZTR1 gene]: (1) during the first step the constitutive SMARCB1 gene is inactivated (1st hit); (2) in addition to the constitutional SMARCB1 mutation, a second step consists in the loss of chromosome 22q, or a segment of it, involving the two loci [i.e., the wild-type SMARCB1 gene and the constitutional NF2 gene] (2nd and 3rd hits); followed (3) by a somatic mutation of the remaining wild-type NF2 allele that constitutes the third step (4th hit) giving rise to the local growth of the schwannoma (from Ruggieri et al., 2015³⁶, adapted and modified).

centromeric to the SMARCB1 gene at 22q11.21, which encodes a member of the BTB-kelch superfamily: it localises exclusively to the Golgi network where it may help stabilize the Golgi complex. The SWNTS2 phenotype is characterised by a later onset of disease (i.e., 20-60 years) and schwannomas affecting various body regions including extremities, spinal cord, chest wall and subcutaneous regions. To complicate matters, vestibular schwannomas do occur at a low frequency in individuals with LZTR1 mutations⁶⁵.

Mosaic NF2 and schwannomatosis

As stated above, schwannomatosis is partially explained by mutations in the SMARCB1 gene. Approximately 10-15% of patients with schwannomatosis have a family history, while the remaining 85-90% have sporadic disease. About 40-50% of familial schwannomatosis, and less than 10% of sporadic patients, have an identifiable SMARCB1

mutation⁶⁰⁻⁶². The other gene, LZTR1, has been recently reported to be mutated in ~80% of schwannomatosis patients negative for SMARCB1 mutation with evidence of a four hit mechanism⁶³. However, further research has shown that a substantial portion of schwannomatosis remains unexplained by LZTR1⁶⁴⁻⁶⁵. Schwannomas from SMARCB1 positive patients follow a four-hit, three-step model of tumorigenesis (Fig. 12) in which both alleles of SMARCB1 and NF2 genes are inactivated in the tumour⁶⁰⁻⁶⁶. In addition to the constitutive SMARCB1 mutation, a second step consists in the loss of chromosome 22q, or a segment of it, involving the two loci, followed by a somatic mutation of the remaining wild-type NF2 allele that constitutes the third step and the four hit. The four-hit, three-step model is also present in schwannomas from LZTR1 patients, involving LZTR1 and NF2 genes. There is a phenotypic overlap among patients that are mosaic NF2 and patients with sporadic schwannomatosis, consisting of the presence of

multiple non-vestibular nerve schwannomas. The sensitivity of blood genetic analysis is challenged in these situations and the histopathological features of schwannomas in either condition (i.e., NF2, schwannomatosis and mosaic NF2) are very similar. Recently⁶⁶, an adult patient with only multiple schwannomas in a single body segment (i.e., her leg) - thus, entirely fulfilling the diagnostic criteria for schwannomatosis - was demonstrated to harbour a double hit inactivation of the NF2 gene in two different schwannomas of the same body segment, demonstrating to be a true mosaic NF2 patient.

Diagnosis

Clinical criteria for the diagnosis of NF2 were first formulated at the National Institutes of Health (NIH) Consensus Conference on NF1 and NF2 in 1987⁶⁷ and revised in 1990⁶⁸. These criteria emphasised the presence of bilateral VSs in a high percentage of NF2 patients (Table I). Alternatively, patients could qualify for a diagnosis of NF2 with a family history of NF2 and either unilateral VS or any two other tumours typically associated with NF2 (Table I). Under NIH criteria, however, patients without bilateral VSs or a family history of NF2 cannot qualify for a diagnosis of

NF2. This was (and still is) particularly relevant for childhood NF2 whose initial presentation, and part of its natural history, progress without eight-nerve dysfunction and often lack affected members in the family tree.

Revised criteria were proposed by the Manchester group in 1992⁶⁹ and by the National Neurofibromatosis Foundation (NNFF) in 1997 (Table I)⁷⁰. The goal of these revisions was to improve the sensitivity for patients with features associated with NF2 but who did not reach formal NIH criteria. None of these criteria, however, can distinguish perfectly unaffected adults and children from those with NF2 and each has its strengths and weaknesses. Unfortunately, mutational analysis cannot replace clinical criteria for diagnosis of NF2 since a causative mutation cannot be identified still in a high percentage of affected NF2 children. The diagnostic work-up is further complicated by the occurrence of alternate forms within the spectrum of NF2: i.e., mosaic NF2, schwannomatosis and multiple meningiomas, even though either form is rare in the paediatric age.

Baser et al.^{71,72} attempted to encompass all the above problems by empirically developing and testing an improved set of diagnostic criteria⁷² that uses current understanding

Table I. Previous sets of diagnostic criteria for NF2.

NIH Criteria [1987] ⁶⁷	NIH Criteria [1991] ⁶⁸	Manchester Criteria [1992] ⁶⁹	NNFF Criteria [1997] ⁷⁰
<i>Patients who meet either condition A or B have NF2</i>	<i>Patients who meet either condition A or B have NF2</i>	<i>Patients who meet either condition A, condition B, condition C, or condition D have NF2</i>	<i>Patients who meet either condition A or B have NF2</i>
A. Bilateral vestibular schwannoma	A. Bilateral vestibular schwannoma	A. Bilateral vestibular schwannoma	A. Bilateral vestibular schwannoma
B. 1 st degree family relative with NF2 and either unilateral VS or any two of: neurofibroma, meningioma, glioma, schwannoma, or juvenile posterior subcapsular lens opacity	B. 1 st degree family relative with NF2 and either unilateral VS or any one of: neurofibroma, meningioma, glioma, schwannoma, or juvenile posterior subcapsular lens opacity	B. 1 st degree family relative with NF2 and either unilateral VS or any two of: neurofibroma, meningioma, glioma, schwannoma, or juvenile posterior subcapsular lens opacity	B. 1 st degree family relative with NF2 and either unilateral VS at < 30 years of age or any two of: meningioma, schwannoma, glioma, juvenile lens opacity (posterior subcortical cataract or cortical cataract)
		C. Unilateral VS and any two of: neurofibroma, meningioma, glioma, schwannoma, or juvenile posterior subcapsular lens opacity	
		D. Multiple meningiomas (≥ 2) and unilateral VS or any two of: neurofibroma, glioma, schwannoma, cataract	
Presumptive or probable NF2			<i>Patients who meet either condition C or D have probable NF2</i>
			C. Unilateral VS < 30 years of age and at least one of: meningioma, schwannoma, glioma, juvenile lens opacity
			D. Multiple meningiomas and either unilateral VS < 30 years of age or at least one of: schwannoma, glioma, juvenile lens opacity

Table II. The Baser criteria for diagnosis of NF2 [2011] ^{71 72}.

Feature	If present at or < age 30 years	If present > age 30 years
First-degree relative with NF2 diagnosed by these criteria	2	2
Unilateral vestibular schwannoma	2	1 ^a
Second vestibular schwannoma	4	3 ^a
One meningioma	2	1
Second meningioma (no additional points for > than 2 meningiomas)	2	1
Cutaneous schwannomas (one or more)	2	1
Cranial nerve tumour (excluding vestibular schwannoma) (one or more)	2	1
Mononeuropathy	2	1
Cataract (one or more)	2	0

The patient is given points as shown in the table.

^aPoints are not given for unilateral or second vestibular schwannoma if age at diagnosis is more than 70 yr.

- A diagnosis of definite NF2 is established if the total number of points is 6 or more.
- A diagnosis of definite NF2 is established if a constitutional pathogenic NF2 mutation is found on mutation testing.
- If no constitutional pathogenic NF2 mutation is found on mutation testing:
 - A diagnosis of **mosaic NF2** is established if mosaicism for a pathogenic NF2 mutation is found in the blood or no detectable pathogenic NF2 mutation is found in the blood but the same pathogenic NF2 mutation is found in two separate NF2-associated tumours.
 - Otherwise, a temporary diagnosis of **possible NF2** is made, pending further clarification. Clarification may occur if the patient is established to have a different condition (e.g., schwannomatosis or multiple meningiomas) by standard diagnostic criteria or if evolution of the patient's disease over time permits establishing a diagnosis of definite NF2 or mosaic NF2 according to the criteria given above.

of the natural history and genetic characteristics of NF2 to increase sensitivity while maintaining very high specificity (Table II): these criteria currently permit early diagnosis in a greater proportion of patients with NF2 than previous sets of diagnostic criteria ⁷².

Initial evaluation

Initial evaluation of children who have or are at risk for NF2 should include testing to confirm a diagnosis and to identify potential problems ¹⁹⁻³³.

A medical history should include questions about focal neurologic symptoms, skin tumours and/or cutaneous spots, seizures, headache, and visual symptoms as well as auditory and vestibular function. A family history should explore unexplained neurological and audiology symptoms in all first-degree relatives.

MRI scan of the brain should include gadolinium and include axial and coronal thin cuts (1-3 mm) through the brainstem to identify VSs ^{23 28 34}. MRI scan of the cervical spine should be performed given the predilection of ependymomas for this site and of meningiomas and/or schwannomas for the paravertebral regions ^{28 34}. Some clinicians recommend imaging of the thoracic and lumbar spine whereas others reserve these exams for patients with neurologic symptoms referable to these locations ^{2-4 19 28}.

Ophthalmologic examination serves to identify characteristic lesions such as lens opacities, retinal hamartomas, or epiretinal membranes ^{19 23 26 28}.

A complete neurological examination serves as a baseline for future comparison and may assist in the selection of sites within the nervous system that require further imaging studies.

Audiology (including pure tone threshold and word

recognition) and brainstem auditory evoked responses (BAER) document eighth cranial nerve dysfunction related to VSs and set a baseline for future comparisons. Abnormalities of pure tone thresholds are present in 90% of patients between 10 and 72 years with NF2. Word recognition serves as a measure of functional hearing. BAERs are a more sensitive measure of auditory function and is abnormal in 100% of patients with symptomatic VSs. In cases where the diagnosis is uncertain, biopsy of any skin lesion and review of any pathologic material may be helpful.

Follow-up

After initial diagnosis, children should be seen relatively frequently (every 3-6 months) until the growth rate and biologic behaviour of tumours is determined (this holds especially true in congenital NF2). Consultation with an experienced surgeon after initial diagnosis is often helpful for pre-symptomatic patients (i.e., those with adequate hearing) to discuss the feasibility of hearing-sparing surgery (see below). Most patients without acute problems can be followed on a 6-month to an annual basis. Evaluation at these visits should include complete neurological examination, MRI scan of the brain and spinal cord with thin cuts through the brainstem, MRI scans of symptomatic lesions outside the brain if present, audiology, and BAER. Ophthalmologic evaluation should be performed in selected patients with visual impairment or facial weakness. Yearly audiology serves to document changes in pure tone threshold and word recognition. This information can be helpful in planning early surgical intervention for VSs and in counselling patients about possible deafness. Changes in BAERs may precede hearing loss. The

frequency with which routine spinal imaging is obtained varies among clinics, but is clearly indicated in patients with new or progressive symptoms referable to the spinal cord. We prefer to obtain it at every MRI follow-up, unless there is no evidence of spinal tumours on first scan. In adulthood less frequent screening on a 3-5 yearly basis is warranted.

Classical management of childhood NF2

The approach to management of NF2-associated tumours has been always different from that of their sporadic counterparts. Because children (but also adults) with NF2 develop multiple cranial, spinal and peripheral nerve tumours, surgical removal of every lesion is not possible or advisable. Instead, the primary goal has been (and still is) to preserve function and to minimize quality of life.

Currently, despite frequent functional impairment, surgical removal remains the standard therapy for VSs (and for non-VSs nervous system tumours): indeed, patients undergoing surgery for VSs often experience iatrogenic hearing loss in the treated ear requiring rehabilitation through the use of a cochlear implant or an auditory brainstem implant (ABI). As an alternative or in addition to tumour removal, stereotactic irradiation and/or chemotherapy can be used to delay tumour progression, but it is thought to increase the risk for secondary malignancies in these patients. Moreover, radiation therapy frequently accelerates loss of hearing. Complete surgical resection is curative, but the timing for tumour removal is controversial, with a complex risk-benefit ratio, between risks of surgery and tumour's natural history.

Until the last decade, the above strategies were the sole therapeutic options for NF2-related vestibular schwannomas, and more in general for NF2-associated tumours: more recent biologically targeted therapies (see below) employing molecules driven from the increased knowledge of the molecular pathways involved in the pathogenesis of NF2 have been successfully employed in adult and paediatric patients with NF2. As these newer therapeutic options have been employed only very recently and in a limited number of NF2 children and are still under study here below, we will review the classical management options still employed worldwide.

Surgical strategies. The tumour load in childhood NF2 series^{6 14 15 20} is usually extensive and involves the skin, brain and spine.

Few NF2 children undergo resection of dermal tumours because of cosmetic burden^{23 28 34}; this is in line with the patterns of growth of peripheral schwannomas, which rarely are disfiguring at this young ages^{6 15 20}. Interestingly, resection of typical NF2-plaques is being asked for diagnostic clarification as in the paediatric population VSs are not apparent until older ages²⁸.

Surgery is clearly indicated for NF2 children with significant brainstem or spinal cord compression or with ob-

structive hydrocephalus. In patients with little or no neurological dysfunction related to their tumours, watchful waiting may allow children to retain neurological function for many years. For this reason, timing of intervention is often a difficult decision for patients and physicians.

A great number of NF2 children imaged have usually one or more extradural spinal masses compatible with schwannomas or meningiomas. Despite this extensive load of spinal nerve sheath tumours only rarely at these young ages these tumours indent the cord itself and require surgical removal because of progressive spinal cord impairment. Resection is usually successful in the majority of NF2 children with spinal tumours (usually ependymomas) without need of repeated neurosurgical intervention or regrowth^{23 28-30}. Conversely, pontine (and bulbar) tumours (usually, ependymomas and astrocytomas) most often need repeated partial resection with severe sequelae. According to our experience, the tumour burden in this location is high and changes the course of disease. As a general rule, indications for resection include rapid tumour growth and worsening neurologic symptoms. In contrast to what occur with brainstem tumours in NF1 (which are low grade astrocytomas, are often asymptomatic and have an indolent course with later tumour regression) these tumours' location in NF2 is associated with higher-grade histology, relentlessly progressive course and often a fatal outcome. However, the mere presence of an asymptomatic ependymoma should prompt a watch and wait policy as many remain indolent.

The decision to operate early on vestibular schwannomas or wait until symptoms or complete deafness ensue is difficult. Recent consensus proposed surgical resection of the largest tumours (> 3 cm in diameter) permitting facial nerve preservation and brainstem protection^{23 28}. There is no consensus for the management of VS less than 3 cm in diameter. Unresectable tumours and hearing impairment following surgery justify the introduction of new effective and safe therapies (see below). Surgical extirpation of VSs is usually accomplished using middle cranial fossa, posterior sub-occipital, and trans-labyrinthine approaches. The goal of pre-symptomatic surgery is retention of hearing with a minimum of post-operative complications such as facial weakness or dysphagia. In patients with a documented change in hearing, bony decompression of the internal auditory canal through a middle cranial fossa can stabilize hearing for a period of time. Pre-operative tumour size as an indicator of outcome in VSs surgery is still debated. A sub-occipital approach for small tumours can result in hearing preservation although precise numbers using this technique have not been published. Alternatively, a trans-labyrinthine approach with placement of an auditory brainstem implant (ABI) can provide auditory sensations in some patients. Children opting for this approach should be counselled that about 10% of patients do not receive auditory sensations, that ABI's do not provide

normal sound quality, that processor optimisation requires regular follow-up, and that maximal benefit is often not achieved for many years¹¹⁰. For most patients with ABI's, the primary benefit occurs when the implant is used in conjunction with lip reading. At the present time, little information is available about the efficacy of hearing sparing surgery in paediatric NF2 patients but outcomes appear to be inferior to that for adults.¹¹¹ A further option is cochlear nerve preserving surgery when the tumour is small via the translabyrinthine approach and insertion of a cochlear implant that produces far superior results to ABI¹¹².

The decision to proceed with hearing-sparing surgery must be individualised for each patient. Options include observation without surgical intervention and hearing-sparing surgery; stereotactic radiation has not yielded comparable results for preservation of hearing (see below). For those with tumours that are multilobulated or greater than 1.5 cm in greatest dimension, the risk of peri-operative complications (including hearing loss and cranial nerve dysfunction) likely outweighs the potential benefits. In these patients, tumour resection should be deferred until another indication for surgery such as increased intracranial pressure, impending hydrocephalus, or new neurologic symptoms develops.

Indications for surgical resection of other (non-VSs) cranial nerve schwannomas are less well defined. In general, schwannomas of other cranial nerves are slow growing and produce few symptoms. Surgical resection in these patients should be reserved for those with unacceptable neurologic symptoms or rapid tumour growth.

Radiation therapy. Radiation is often used as adjuvant therapy for treatment of sporadic brain tumours. Treatment outcomes for (paediatric and adult) patients with NF2-related VSs are worse than for patients with sporadic tumours. In early studies of stereotactic radiosurgery, 18-20 Gy were delivered to tumours. Local control was achieved in 90% of patients but no serviceable hearing was preserved in patients with serviceable hearing pre-operatively. For this reason, the dose of radiation to the tumour margin was reduced to 12-16 Gy. Using modern regimens, treatment with stereotactic radiosurgery results in tumour control in 98% of patients with NF2 with preservation of useful hearing in 40-67%. Decreased facial and trigeminal function occurs in 5-16% and 10% of patients, respectively. The risk of deafness in patients with serviceable hearing pre-operatively is about 20%. More recently, fractionated stereotactic radiotherapy has been advocated to minimise the risk of hearing loss. The actuarial 5-year local control rate using this technique is 93% and the hearing-preservation rate is 64%. The use of radiation therapy for benign tumours in NF2 children must nonetheless be used with caution because of the greater risk of future tumour induction and malignant transformation⁸².

The role of adjuvant radiation in other tumours such as meningiomas and ependymomas is not established, but

the majority of these tumours demonstrate benign histology and can be controlled surgically. No case series have been published on treatment of NF2-related meningiomas. In general, treatment of sporadic tumours with stereotactic radiosurgery results in local control in 90-95% of cases. Peritumoural cerebral oedema develops in up to 25% of patients, but symptoms referable to cerebral oedema develop in less than 10% of patients.

Most clinicians prefer surgical extirpation of tumours when possible and reserve radiation treatment for tumours that are not surgically accessible. This practice is based on the experience that radiation therapy makes subsequent resection of VSs and function of ABI's more difficult. In addition, there are anecdotal reports of malignant transformation of NF2-associated schwannomas after radiation treatment and indirect evidence of increased numbers of malignancy in NF2 patients who have received radiation.

Chemotherapy. At the present time, there is no effective chemotherapy for treatment of NF2-related tumours. Sporadic meningiomas represent the best-studied tumour at the present time. Typically, patients with refractory or non-surgical tumours have been included in chemotherapy trials. Although some initial reports suggested efficacy of hydroxyurea in treating meningiomas, more recent reports do not support this view. Furthermore, there seems to be little role for use of tamoxifen or temozolomide for recurrent tumours. No trials of chemotherapy for treatment of vestibular schwannomas or ependymomas have been reported. Gene therapy remains a potential option for the future as injection of oncolytic recombinant herpes virus into schwannomas in mice results in significant tumour shrinkage.

NF2 patients who are managed at multidisciplinary specialty treatment centres have a significantly lower risk of mortality than those who are treated at non-specialty centres with higher rates of favourable outcome in VSs surgery and lower rates of serious complications with increasing surgical experience²⁷.

Genetic counselling. Individuals at risk for NF2 need genetic counselling and pre-symptomatic testing. Clinically, a normal MR image at 16 or 18 years reduces the chances of having inherited NF2. A normal MRI at 30 years makes inheritance very unlikely, except in late-onset families, and may justify cessation of formal screening¹¹³. Notably, most of our NF2 cases were sporadic and the earlier the onset of NF2 the lower the risk for siblings and parents.

As clinical and radiological screening cannot reassure at-risk individuals that they have not inherited the condition until 30 years of age, molecular genetic testing for NF2 has had a major impact on clinical practice^{2,5}. Constitutional mutation testing for NF2 is now available worldwide and mutations are found in about half the sporadic individuals tested but over 90% of families with vertical transmission⁴⁵. Identified mutations can be used for a pre-symptomatic testing and the latter is warranted even in children.

Biologically targeted pharmacological strategies in childhood NF2

Recently, following the studies on merlin pathway(s), different pharmacological strategies have been developed, in order to obtain tumour volumetric shrinkage and/or arrest of progression of tumours including a reduction in time to progression¹¹⁴. Given the complexity of the Merlin's pathway(s), different targets have been proposed¹¹⁵⁻¹²¹.

Antagonists of the ErbB family. Lapatinib, an antagonists of the Her1-2members of the ErbB family of tyrosine kinase receptors, was clinically tested in NF2-patients, with volumetric regression of VSs and improvement of hearing, in 4 of 17 patients treated¹²²; however, patients

treated with another inhibitor of ErbB tyrosine kinase receptors, Erlotinib, did not experience tumour regression, even if in 27% of the cases there was a stabilisation of the disease¹²³.

Inhibitors of the mTOR pathway. The attempt to use mTOR pathway inhibition (i.e., Everolimus) did not yield appreciable results, with no patients (out of 9 enrolled) showing a volumetric response of the schwannomas, nor clear evidence of a stabilization of the disease¹²⁴.

Inhibitors of IGF1 receptor/PDGF/Akt/MEK. In vitro studies on the employment of different potential drugs have shown appreciable results, in particular with picropodophyllin, an anti-IGF1 receptor¹²⁵, OSU-03012, an Akt inhibitor¹²⁶, and nilotinib, a C-kit cascade inhibitor¹²⁷.

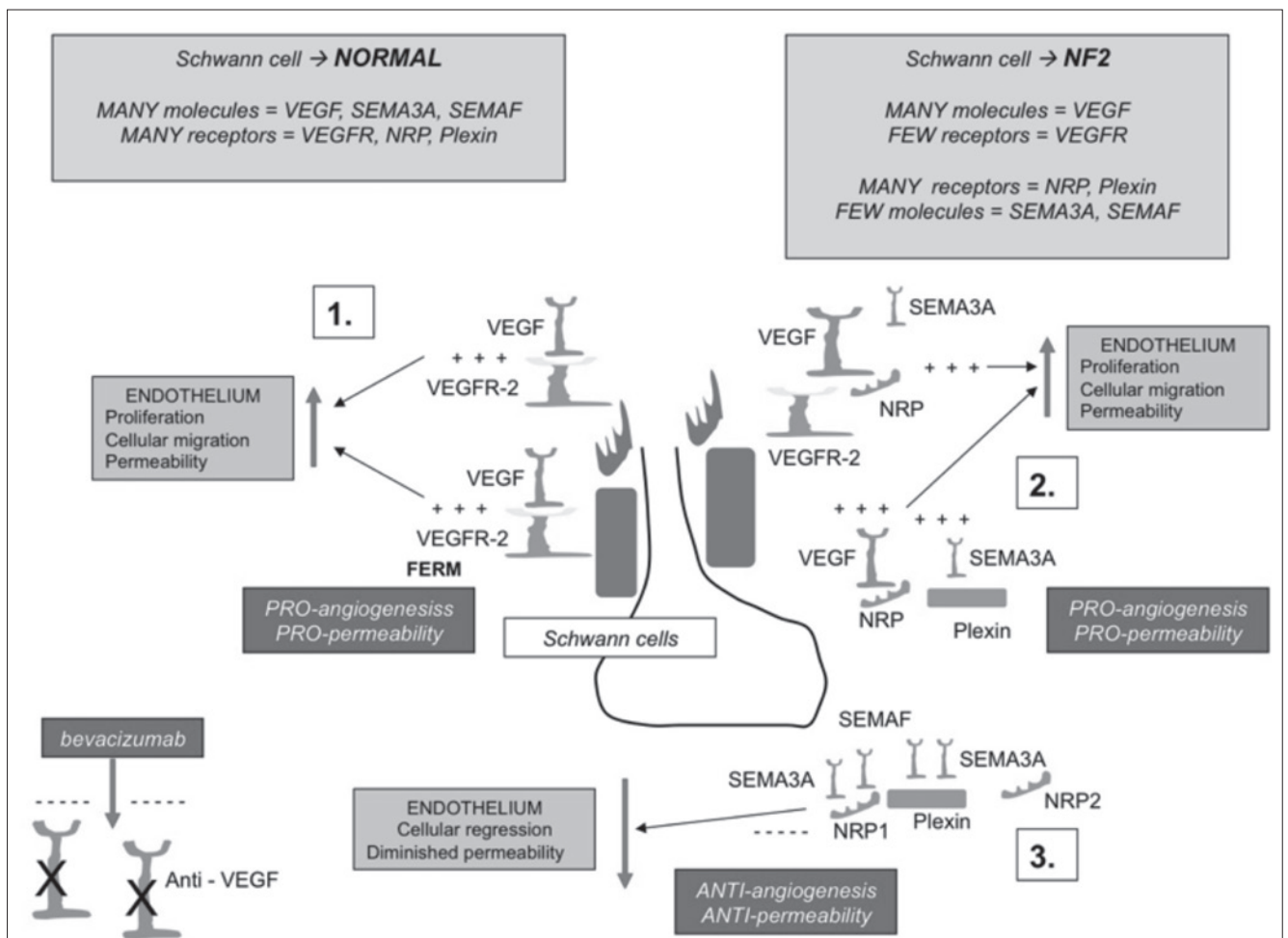


Fig. 13. VEGF/VEGFR signalling pathway in normal vs. NF2 Schwann cells [Avastin]: in normal Schwann cells VEGF (vascular endothelial growth factor), SEMA3A (semaphorin 3 A) and SEMAF (semaphorin F) molecules and VEGFR (VEGF receptors), NRP (neuropilin) and Plexin receptors are normally expressed; in NF2 Schwann cells VEGF are normally expressed vs. lower expressed VEGFR; in addition to that, in NF2 Schwann cells NRP and Plexin receptors are normally expressed vs. lower expressed SEMA3A and SEMAF molecules (see boxes). VEGF typically binds to VEGFR2 [Panel 1] inducing endothelial proliferation, migration and permeability; VEGF can also compete with SEMA3A to bind to Neuropilin (NRP) receptors directly or can form a bridge between VEGFR2 and NRP potentiating its signalling via VEGFR2 [Panel 2]; SEMA3A and SEMAF bind NRP1 and NRP2, respectively, to induce endothelial cell regression and diminished permeability [Panel 3]. Thus, Avastin [an anti-VEGF antibody], when administered in NF2 patients acts not only via VEGFR inhibition (as VEGFR are lower expressed in NF2 Schwann cells) but also because it displaces VEGF from binding to NRP and Plexin receptor, thus allowing SEMA3A and SEMAF to bind to these receptors inducing endothelial cell regression and diminished permeability [see Panel 3 (from Ruggieri et al., 2015³⁵ and Ruggieri et al., 2015³⁶, adapted and modified).

Table III. NF2 patients treated with bevacizumab in the literature (from Ruggieri et al., 2015³⁵ and Ruggieri et al., 2015³⁶, adapted and modified).

Author	Year	Total no.	Average age [Current]	Age range (years)	Sex	Median duration of Treatment	Hearing Response	Radiologic Response	Side effects
Plotkin et al	2009 & 2012	31	26	12-73	14 M 17 F	14 months	90% had stable or improved hearing after 1 year of treatment and 61% at 3 years	17/31 (55%) reduction in size of VS; 10/31 stable disease (32%). [87% of patients had stable or decreased tumour size after 1 year of treatment and 54% at 3 years]	50% menorrhagia and Irregular menstruation; 35% proteinuria and hypertension; 26% epistaxis; 23% fatigue and hyponatremia
Mautner et al	2010	2	31	23-39	2 M	1 year	1/2 improvement	2/2 volumetric reduction	Patient 1: slightly fatigue and epistaxis; Patient 2 hypertension
Eminowicz et al	2012	2	34	31-37	1 M 1 F	Case 1 18 weeks; Case 2 > 16 weeks	2/2 improvement	2/2 volumetric reduction	NR
Riina et al [Intra-arterial infusion]	2012	3	39.7	31-56	2 M 1 F	1 day	NA	Patient 1: Reduction 11 and 19% of VSs; Patient 2: stable disease; Patient 3: stable disease	None
Subbiah et al [Total 6 patients; 4 treated with BEV]	2012	4	30	16-41	2 M 2 F	(4-10+ months)	3/4 stable disease; 1/4 improvement	3/4 stable disease; 1/4 33% tumour shrinkage	2/4 proteinuria and hyperlipidemia
Hawasli et al [Total 10 patients; 5 affected by NF2 and treated with BEV]	2013	5	22,8	14-38	NR	11 months	2/5 stable disease; 3/5 improvement	4/5 stable; 1/5 volumetric reduction	2/5 hypertension; 1/5 epistaxis; 1/5 weight loss; 1/5 abdominal pain and diarrhea; 1/5 chest pain
Nunes et al [Meningiomas; Same patients of Plotkin 2012]	2013	15	29.5	16-63	7 M 8 F	18 months	NA	29% (14/48 meningiomas): volumetric radiographic response; median time to progression was 15 months. Median duration of response was 3.7 months	4 grade 3 adverse events (hypertension, elevated liver enzymes, menorrhagia, irregular menses) and 2 grade 4 events (delayed wound healing)
Alanin et al	2014	12	34	23-78	5 M 7 F	22 months (range 7-34)	5/12 subjective benefit; 3/12 objective benefit	6/12 radiologic response	92% fatigue; 71% oligomenorrhea; 67% proteinuria; 33% hypertension; 17% epistaxis; one patient presented cerebral haemorrhage (fatal event)
Farschtschi et al [reduced dosage; 5 to 2.5 mg]	2015	3	28.3	22-38	2 M 1 F	66-76 months	3/3 hearing improvement	3/3 radiologic response	Hypertension 3/3; proteinuria 2/3; The side effects ceased after treatment reduction to 2.5 mg/g
Hochart et al	2015	7	15	11.4-18.8	3 M 4 F	11.3 months (range 3.2-55.6)	3/7 stable; 3/7 Non eligible; 1/7 improvement	3/7 shrinkage; 2/7 Reduction of growth rate; 1/7 stable disease	1/7 severe hypertension and proteinuria; 1/7 osteomyelitis; 1/7 epistaxis; 1/7 inter-mensual bleeding; 1/7 malaise
Morris KA et al	2016	61	25	10-57	36 M 25 F	23 months (range 3-53)	Hearing stabilisation or improvement in 86%	Partial volumetric tumour response (all tumours) was in 39% and stabilisation in 51%	Hypertension in 30% and proteinuria in 16%. 12/61 treatment breaks.

Legend: BEV = Bevacizumab; NR = Not reported; NA = Not available; VS = Vestibular schwannoma

Imatinib, a PDGF inhibitor¹²⁸, has also been employed in a NF2 patient¹²⁹. Even if preliminary results were appreciable, the treatment was suspended after only 4 months for severe adverse reactions, including headache, vomiting, abdominal pain and increased unsteadiness. Sorafenib, which acts by inhibiting C-kit, PDGF and MEK1-2 system, was employed in a single patient and afterward suspended because of the appearance of a rash¹³⁰.

Anti-VEGF antibodies. Bevacizumab, a monoclonal antibody directed against anti-vascular endothelial growth factor (VEGF) has shown the most promising results in terms of tumour volume shrinkage, stabilisation of the disease and hearing improvement, since its first employment by Plotkin et al, at the dose of 5 mg/kg/biweekly (Fig. 13)¹³¹. Even if associated with different side effects (including haemorrhage, delayed wound healing, proteinuria and hypertension)¹³² it is by and large extremely well tolerated in NF2 patients¹³³. Bevacizumab has demonstrated its efficacy in the treatment of VSs^{129 131 134}, with a stable or improved hearing in 90% of patients after 1 year and 61% after 3 years¹³⁵; a stable or decreased tumour volume was observed in 88% of patients after 1 year of treatment and in 54% at 3 years. The same usefulness was not demonstrated in the meningiomas of the same cohort of NF2 patients^{135 136}: a volumetric response was observed in 29% and the median duration of the response was 3.7 months and a median time to progression of 15 months. Among the 10 patients affected by non-malignant brain tumours and treated with anti-VEGF therapy enrolled by Hawasli et al.¹³⁶, six were affected by NF2: 5 were treated with bevacizumab, and one with pazopanib, a pleiotropic tyrosine kinase receptor inhibitor, which inhibits also the angiogenesis. All the six NF2 patients showed benefits from anti-VEGF, while among the non-NF2 patients, two (affected by recurrent meningiomas) continued to present tumour growth after VEGF therapy.

Subbiah et al.¹²⁹ demonstrated the utility of a combined treatment with bevacizumab and temsirolimus, an mTOR inhibitor, in two patients: one of them had a 33% volumetric response in size, while the other presented a stable disease. A radiological response was observed in 7 of 18 tumours (39%) of the 12 patients enrolled by Alanin et al.¹³⁷, with a continued response (for more than 2 months) in 6/18 (33%). Three patients (25%) showed an objective hearing improvement and five (41.7%) reported subjective benefit in neurological symptoms, including improved hearing.

Anti-VEGF in the paediatric age (Table III) (Fig. 13). Among the seven children and teenagers affected by NF2 (median age 15 years) treated by Hochart et al.¹³⁸, one showed a tumour regression of more than 20%, two a tumour shrinkage between 5 and 19% and the other four showed a decreased tumour growth. A hearing benefit was showed in 1 out of 4 patients eligible for audiometric evaluation, while the others presented a stable disease¹³⁸. Severe adverse (hypertension and osteitis) events were registered

in two patients, who had to discontinue treatment; another patient needed a reduction of the doses after recurrent episodes of epistaxis, while another experienced a grade 2 inter-menstrual bleeding. Six children with NF2 with 8 evaluable VS had significantly poorer responses to bevacizumab than 51 adults in a large multi-institution study¹³³. Other smaller groups of NF2-related tumours have been treated with bevacizumab. These studies have demonstrated that a reduced dose bevacizumab treatment to 2.5 mg bi- or tri-weekly, also if prolonged for 66-76 months, could still provide a clinically stable, radiographic and audiology sustained response¹³⁹, that tumour shrinkage can be more than 40%¹⁴⁰, and that bevacizumab can also be effective in patients previously unsuccessfully treated with gamma knife radiotherapy¹⁴¹. Moreover, a super-selective intra-arterial cerebral infusion of bevacizumab was reported in 3 patients has showed a likely efficacy, with one patient presenting a decreased tumour volume and two showing a stable disease¹⁴².

Mortality in NF2 and in NF2 children

Overall, patients with NF2 have diminished lifespan compared to non-affected family members^{106 107 143} with overall 5-, 10-, and 20-years survival rates after diagnosis of 85%, 67% and 38%, respectively¹³⁷. Early age at diagnosis and the presence of intracranial meningiomas are usually associated with increased mortality, and having a mosaic, rather than non-mosaic, NF2 mutation is associated with reduced mortality¹⁰⁶. The most frequent causes of death include tumour burden, peri-operative complications, and malignancy from NF2-related tumour^{28 107 143}. A decreased risk of mortality is associated with treatment at a specialty medical centre and with splice-site or missense mutations vs. truncating mutations [patients with splice-site mutations in exons 6-15 have lower mortality than patients with splice-site mutations in exons 1-5]. Notably, the overall mortality of children and adults with NF2 diagnosed in more recent decades is lower than that of patients diagnosed earlier^{28 106}.

References

- Huson SM, Hughes RAC. *The Neurofibromatoses*. A Pathogenetic and Clinical Overview. London: Churchill Livingstone, 1994.
- Evans DG. *Neurofibromatosis type 2 (NF2): a clinical and molecular review*. Orphanet J Rare Dis 2009;4:16.
- Asthagiri AR, Parry DM, Butman JA, et al. *Neurofibromatosis type 2*. Lancet 2009;373:1974-86.
- Evans DG. *Neurofibromatosis 2 Bilateral acoustic neurofibromatosis, central neurofibromatosis, NF2, neurofibromatosis type II*. Genet Med 2009;11:599-610.
- Wishart JH. *Case of tumours in the skull, dura mater, and brain*. Edinburgh Med Surg J 1822;18:393-7.
- Gardner WJ, Frazier CH. *Hereditary bilateral acoustic tumors*. J Hered 1933;22:7-8.

- 7 Gardner WJ, Turner O. *Bilateral acoustic neurofibromas: further clinical and pathologic data on hereditary deafness and Recklinghausen's disease.* Arch Neurol Psychiatr 1940;44:76-99.
- 8 Young DF, Eldridge R, Gardner WJ. *Bilateral acoustic neuroma in a large kindred.* JAMA 1970;214:347-53.
- 9 Seizinger BR, Martuza RL, Gusella JF. *Loss of genes on chromosome 22 in tumorigenesis of human acoustic neuroma.* Nature 1986;322:644-7.
- 10 Rouleau GA, Merel P, Lutchman M, et al. *Alteration in a new gene encoding a putative membrane-organizing protein causes neurofibromatosis type 2.* Nature 1993;363:515-21.
- 11 Trofatter JA, MacCollin MM, Rutter JL, et al. *A novel moesin-, ezrin-, radixin-like gene is a candidate for the neurofibromatosis 2 tumor suppressor.* Cell 1993;72:791-800.
- 12 Evans DG, Huson SM, Donnai D, et al. *A genetic study of type 2 neurofibromatosis in the United Kingdom. I. Prevalence, mutation rate, fitness, and confirmation of maternal transmission effect on severity.* J Med Genet 1992;29:841-6.
- 13 Evans DG, Huson SM, Donnai D, et al. *A genetic study of type 2 neurofibromatosis in the United Kingdom. II. Guidelines for genetic counselling.* J Med Genet 1992;29:847-52.
- 14 Parry DM, Eldridge R, Kaiser-Kupfer MI. *Neurofibromatosis type 2 (NF2): Clinical characteristics of 63 affected individuals and clinical evidence for heterogeneity.* Am J Med Genet 1994;52:450-61.
- 15 Mautner VF, Baser ME, Takkar SD, et al. *Vestibular schwannoma growth in patients with neurofibromatosis type 2: a longitudinal study.* J Neurosurg 2002;96:223-28.
- 16 Ragge NK, Baser ME, Riccardi VM, et al. *The ocular presentation of neurofibromatosis 2.* Eye (Lond) 1997;11:12-8.
- 17 Mautner VF, Lindenau M, Baser ME, et al. *Skin abnormalities in neurofibromatosis type 2.* Arch Dermatol 1997;133:1539-43.
- 18 Eldridge R, Parry DM, Kaiser-Kupfer MI. *Neurofibromatosis 2 (NF2): clinical heterogeneity and natural history based on 39 individuals in 9 families and 16 sporadic cases.* Am J Hum Genet 1991;49:A133.
- 19 Ruggieri M. *The different forms of neurofibromatosis.* Child's Nerv Syst 1999;15:295-308.
- 20 Mautner VF, Tatagiba M, Guthoff R, et al. *Neurofibromatosis type 2 in the paediatric age group.* Neurosurgery 1993;33:92-6.
- 21 MacCollin M, Bove C, Kluwe L et al. *The natural history of neurofibromatosis 2 in 31 affected children.* Ann Neurol 1996;44:A576.
- 22 MacCollin M, Mautner VF. *The diagnosis and management of neurofibromatosis type 2 in childhood.* Semin Pediatr Neurol 1998;5:243-52.
- 23 Evans DGR, Birch JM, Ramsden RT. *Paediatric presentation of type 2 neurofibromatosis.* Arch Dis Child 1999;81:496-9.
- 24 Ruggieri M, Huson SM. *Clinical presentations of neurofibromatosis type 2 in childhood.* Eur J Pediatr Neurol 1999;3:A66.
- 25 Huson SM, Ruggieri M. *The various presentations of neurofibromatosis type 2 (NF2) in childhood.* J Med Genet 1999;36:S6926.
- 26 Ruggieri M, Polizzi A, Rampello L, et al. *Neurofibromatosis type 2 (NF2) in childhood.* NeurolSci 2000;21:356.
- 27 Nunes F, MacCollin M. *Neurofibromatosis type 1 in the pediatric population.* J Child Neurol 2002;18:718-724.
- 28 Ruggieri M, Iannetti P, Polizzi A, et al. *Earliest clinical manifestations and natural history of neurofibromatosis type 2 (NF2) in childhood: a study of 24 patients.* Neuropediatrics 2005;36:21-34.
- 29 Rushing EJ, Olsen C, Mena H, et al. *Central nervous system meningiomas in the first two decades of life: a clinicopathological analysis of 87 patients.* J Neurosurg 2005;103:489-95.
- 30 Bosch MM, Boltshauser E, Harpes P, et al. *Ophthalmologic findings and long-term course in patients with neurofibromatosis type 2.* Am J Ophthalmol 2006;141:1068-77.
- 31 Pascual-Castroviejo I, Pascual-Pascual SI, Viaño J. *Neurofibromatosis type 2. A study of 7 patients.* Neurologia 2009;24:457-61.
- 32 Matsuo M, Ohno K, Ohtsuka F. *Characterization of early onset neurofibromatosis type 2.* Brain Dev 2014;36:148-52.
- 33 Choi JW, Lee JY, Phi JH, et al. *Clinical course of vestibular schwannoma in pediatric neurofibromatosis Type 2.* J Neurosurg Pediatr 2014;13:650-7.
- 34 Ruggieri M, Gabriele AL, Polizzi A, et al. *Natural history of neurofibromatosis type 2 with onset before the age of 1 year.* Neurogenetics 2013;14:89-98.
- 35 Ruggieri M, Praticò AD, Evans DG. *Diagnosis, management, and new therapeutic options in childhood neurofibromatosis type 2 and related forms.* Semin Pediatr Neurol 2015;22:240-58.
- 36 Ruggieri M, Praticò AD, Muglia M, et al. *Biochemical insights into Merlin/NF2 pathophysiology and biologically targeted therapies in childhood NF2 and related forms.* J Ped Biochem 2015;5:120-30.
- 37 MacCollin M, Ramesh V, Jacoby LB, et al. *Mutational analysis of patients with neurofibromatosis 2.* Am J Hum Genet 1994;55:314-20.
- 38 Kluwe L, Mautner VF. *A missense mutation in the NF2 gene results in moderate and mild clinical phenotypes of neurofibromatosis type 2.* Hum Genet 1996;97:224-7.
- 39 Kluwe L, Mautner VF. *Mosaicism in sporadic neurofibromatosis 2 patients.* Hum Mol Genet 1998;7:2051-5.
- 40 Evans DG, Wallace AJ, Wu CL, et al. *Somatic mosaicism: a common cause of classic disease in tumor-prone syndromes? Lessons from type 2 neurofibromatosis.* Am J Hum Genet 1998;63:727-76.
- 41 Ruggieri M, Huson SM. *The neurofibromatoses.* An overview. NeurolSci 1999;20:89-108.
- 42 Ruggieri M, Polizzi A. *Segmental neurofibromatosis.* J Neurosurg 2000;93:530-32.
- 43 Ruggieri M. *Mosaic (segmental) neurofibromatosis type 1 (NF1) and type 2 (NF2) – no longer neurofibromatosis type 5.* Am J Med Genet 2001;101:178-80.
- 44 Ruggieri M, Huson S. *The clinical and diagnostic implications of mosaicism in the neurofibromatosis.* Neurology 2001;56:1433-43.
- 45 Kluwe L, Mautner V, Heinrich B, et al. *Molecular study of frequency of mosaicism in neurofibromatosis 2 patients with bilateral vestibular schwannomas.* J Med Genet 2003;40:109-14.
- 46 Evans DG, Ramsden RT, Shenton A, et al. *Mosaicism in neurofibromatosis type 2: an update of risk based on uni/bilat-*

- erality of vestibular schwannoma at presentation and sensitive mutation analysis including multiple ligation-dependent probe amplification. *J Med Genet* 2007;44:424-28.
- 47 Evans DG, Ramsden RT, Shenton A et al. *What are the implications in individuals with unilateral vestibular schwannoma and other neurogenic tumors?* *J Neurosurg* 2008;108:92-6.
- 48 Evans DG, Wallace A. *An update on age related mosaic and offspring risk in neurofibromatosis 2 (NF2).* *J Med Genet* 2009;46:792.
- 49 Evans DG, Bowers N, Huson SM, et al. *Mutation type and position varies between mosaic and inherited NF2 and correlates with disease severity.* *Clin Genet* 2013;83:594-95.
- 50 Evans DG, Freeman S, Gokhale C, et al. *Bilateral vestibular schwannomas in older patients: NF2 or chance?* *J Med Genet* 2015;52:422-24.
- 51 Ruggieri M, Praticò AD. *Mosaic neurocutaneous disorders and their causes.* *Semin Pediatr Neurol* 2015;22:207-33.
- 52 Niimura M. *Neurofibromatosis.* *Rinsho Derma* 1973;15:653-63.
- 53 Jacoby LB, Jones D, Davis K, et al. *Molecular analysis of the NF2 tumor-suppressor gene in schwannomatosis.* *Am J Hum Genet* 1997;61:1293-302.
- 54 Antinheimo J, Sankila R, Carpen O, et al. *Population-based analysis of sporadic and type 2 neurofibromatosis-associated meningiomas and schwannomas.* *Neurology* 2000;54:71-6.
- 55 MacCollin M, Chiocca EA, Evans DG, et al. *Diagnostic criteria for schwannomatosis.* *Neurology* 2005;64:1838-45.
- 56 MacCollin M, Woodfin W, Kronn D, et al. *Schwannomatosis: a clinical and pathologic study.* *Neurology* 1996;46:1072-9.
- 57 Baser ME, Friedman JM, Evans DG. *Increasing the specificity of diagnostic criteria for schwannomatosis.* *Neurology* 2006;66:730-2.
- 58 Smith MJ, Kulkarni A, Rustad C, et al. *Vestibular schwannomas occur in schwannomatosis and should not be considered an exclusion criterion for clinical diagnosis.* *Am J Med Genet A* 2012;158A:215-9.
- 59 Plotkin SR, Blakeley JO, Evans DG, et al. *Update from the 2011 International Schwannomatosis Workshop: from genetics to diagnostic criteria.* *Am J Med Genet A* 2013;161A:405-16.
- 60 Hulsebos TJ, Plomp AS, Wolterman RA, et al. *Germline mutation of INI1/SMARCB1 in familial schwannomatosis.* *Am J Hum Genet* 2007;80:805-10.
- 61 Sestini R, Bacci C, Provenzano A, et al. *Evidence of a four-hit mechanism involving SMARCB1 and NF2 in schwannomatosis-associated schwannomas.* *Hum Mutat* 2008;29:227-31.
- 62 Hadfield KD, Newman WG, Bowers NL, et al. *Molecular characterisation of SMARCB1 and NF2 in familial and sporadic schwannomatosis.* *J Med Genet* 2008;45:332-39.
- 63 Piotrowski A, Xie J, Liu YF, et al. *Germline loss-of-function mutations in LZTR1 predispose to an inherited disorder of multiple schwannomas.* *Nat Genet* 2014;46:182-7.
- 64 Paganini I, Chang VY, Capone GL, et al. *Expanding the mutational spectrum of LZTR1 in schwannomatosis.* *Eur J Hum Genet* 2015;23:963-8.
- 65 Smith MJ, Isidor B, Beetz C, et al. *Mutations in LZTR1 add to the complex heterogeneity of schwannomatosis.* *Neurology* 2015;84:141-7.
- 66 Castellanos E, Bielsa I, Carrato C, et al. *Segmental neurofibromatosis type 2: discriminating two hit from four hit in a patient presenting multiple schwannomas confined to one limb.* *MC Med Genomics* 2015;8:2.
- 67 National Institutes of Health Consensus Development Conference Statement. *Neurofibromatosis.* *Arch Neurol* 1988;45:575-8.
- 68 Mulvihill JJ, Parry DM, Sherman JL, et al. *NIH conference. Neurofibromatosis 1 (Recklinghausen disease) and neurofibromatosis 2 (bilateral acoustic neurofibromatosis). An update.* *Ann Intern Med* 1990;113:39-52.
- 69 Evans DG, Huson SM, Donnai D, et al. *A clinical study of type 2 neurofibromatosis.* *Q J Med J* 1992;304:603-18.
- 70 Gutmann DH, Aylsworth A, Carey JC, et al. *The diagnostic evaluation and multidisciplinary management of neurofibromatosis 1 and neurofibromatosis 2.* *JAMA* 1997;278:51-3.
- 71 Baser ME, Friedman JM, Wallace AJ, et al. *Evaluation of clinical diagnostic criteria for neurofibromatosis 2.* *Neurology* 2002;59:1759-65.
- 72 Baser ME, Friedman JM, Joe H, et al. *Empirical development of improved diagnostic criteria for neurofibromatosis 2.* *Genet Med* 2011;13:576-81.
- 73 Stivaros SM, Stemmer-Rachamimov AO, Alston R, et al. *Multiple synchronous sites of origin of vestibular schwannomas in neurofibromatosis Type 2.* *J Med Genet* 2015;52:557-62.
- 74 Curto M, McClatchey A. *Nf2/Merlin: a coordinator of receptor signalling and intercellular contact.* *Brit J Cancer* 2008;98:256-62.
- 75 Cheng JQ, Lee WC, Klein MA, et al. *Frequent mutations of NF2 and allelic loss from chromosome band 22q12 in malignant mesothelioma: evidence for a two-hit mechanism of NF2 inactivation.* *Genes Chromosomes Cancer* 1999;24:238-42.
- 76 Bianchi AB, Hara T, Ramesh V, et al. *Mutations in transcript isoforms of the neurofibromatosis 2 gene in multiple human tumour types.* *Nat Genet* 1994;6:185-92.
- 77 Sher I, Hanemann CO, Karplus PA, et al. *The tumor suppressor merlin controls growth in its open state, and phosphorylation converts it to a less-active more-closed state.* *Dev Cell* 2012;22:703-5.
- 78 Schroeder RD, Angelo LS, Kurzrock R. *NF2/merlin in hereditary neurofibromatosis 2 versus cancer: biologic mechanisms and clinical associations.* *Oncotarget* 2014;5:67-77.
- 79 McClatchey AI, Fehon RG. *Merlin and the ERM proteins-regulators of receptor distribution and signaling at the cell cortex.* *Trends Cell Biol* 2009;19:198-206.
- 80 Surace EI, Haipek CA, Gutmann DH. *Effect of merlin phosphorylation on neurofibromatosis 2 (NF2) gene function.* *Oncogene* 2004;23:580-7.
- 81 Lallemand D, Saint-Amaux AL, Giovannini M. *Tumor-suppression functions of merlin are independent of its role as an organizer of the actin cytoskeleton in Schwann cells.* *J Cell Sci* 2009;122:4141-9.
- 82 Cooper J, Giancotti FG. *Molecular insights into NF2/Merlin tumor suppressor function.* *FEBS Lett* 2014;588:2743-52.
- 83 Ahronowitz I, Xin W, Kiely R, et al. *Mutational spectrum of the NF2 gene: a meta-analysis of 12 years of research and diagnostic laboratory findings.* *Hum Mutat* 2007; 28:1-12.
- 84 de Vries M, van der Mey AG, Hogendoorn PC. *Tumor biology of vestibular schwannoma: a review of experimental*

- data on the determinants of tumor genesis and growth characteristics. *OtolNeurotol* 2015;36:1128-36.
- ⁸⁵ Li W, You L, Cooper J, et al. *Merlin/NF2 suppresses tumorigenesis by inhibiting the E3 ubiquitin ligase CRL4(DCAF1) in the nucleus.* *Cell* 2010;140:477-90.
- ⁸⁶ Alfthan K, Heiska L, Grönholm M, et al. *Cyclic AMP-dependent protein kinase phosphorylates merlin at serine 518 independently of p21-activated kinase and promotes merlin-ezrin heterodimerization.* *J Biol Chem* 2004;279:18559-66.
- ⁸⁷ Kim HA, DeClue JE, Ratner N. *cAMP-dependent protein kinase A is required for Schwann cell growth: interactions between the cAMP and neuregulin/tyrosine kinase pathways.* *J Neurosci Res* 1997;49:236-47.
- ⁸⁸ Rong R, Tang X, Gutmann DH, Ye K. *Neurofibromatosis 2 (NF2) tumor suppressor merlin inhibits phosphatidylinositol 3-kinase through binding to PIKE-L.* *Proc Natl Acad Sci U S A* 2004;101:18200-5.
- ⁸⁹ Rong R, Surace EI, Haipek CA, et al. *Serine 518 phosphorylation modulates merlin intramolecular association and binding to critical effectors important for NF2 growth suppression.* *Oncogene* 2004;23:8447-54.
- ⁹⁰ Jin H, Sperka T, Herrlich P, Morrison H. *Tumorigenic transformation by CPI-17 through inhibition of a merlin phosphatase.* *Nature* 2006;442:576-9.
- ⁹¹ Lallemand D, Curto M, Saotome I, et al. *NF2 deficiency promotes tumorigenesis and metastasis by destabilizing adherens junctions.* *Genes Dev* 2003;17:1090-100.
- ⁹² Yi C, Troutman S, Fera D, et al. *A tight junction-associated Merlin-angiomotin complex mediates Merlin's regulation of mitogenic signaling and tumor suppressive functions.* *Cancer Cell* 2011;19:527-40.
- ⁹³ Stickney JT, Bacon WC, Rojas M, et al. *Activation of the tumor suppressor merlin modulates its interaction with lipid rafts.* *Cancer Res* 2004;64:2717-24.
- ⁹⁴ Mani T, Hennigan RF, Foster LA, et al. *FERM domain phosphoinositide binding targets merlin to the membrane and is essential for its growth-suppressive function.* *Mol Cell Biol* 2011;31:1983-96.
- ⁹⁵ Brault E, Gautreau A, Lamarine M, et al. *Normal membrane localization and actin association of the NF2 tumor suppressor protein are dependent on folding of its N-terminal domain.* *J Cell Sci* 2001;114:1901-12.
- ⁹⁶ Hennigan RF, Moon CA, Parysek LM, et al. *The NF2 tumor suppressor regulates microtubule-based vesicle trafficking via a novel Rac, MLK and p38(SAPK) pathway.* *Oncogene* 2013;32:1135-43.
- ⁹⁷ Yu C, Zhang YL, Pan WW, et al. *CRL4 complex regulates mammalian oocyte survival and reprogramming by activation of TET proteins.* *Science* 2013;342:1518-21.
- ⁹⁸ Pan D. *The hippo signaling pathway in development and cancer.* *Dev Cell.* 2010;19:491-505.
- ⁹⁹ Johnson R, Halder G. *The two faces of Hippo: targeting the Hippo pathway for regenerative medicine and cancer treatment.* *Nat Rev Drug Discov* 2014;13:63-79.
- ¹⁰⁰ Chan SW, Lim CJ, Chong YF, et al. *Hippo pathway-independent restriction of TAZ and YAP by angiomotin.* *J Biol Chem* 2011;286:7018-26.
- ¹⁰¹ Li Y, Zhou H, Li F, et al. *Angiomotin binding-induced activation of Merlin/NF2 in the Hippo pathway.* *Cell Res* 2015;25:801-17.
- ¹⁰² Selvanathan SK, Shenton A, Ferner R, et al. *Further Genotype-phenotype correlations in neurofibromatosis type 2.* *Clin Genet* 2010;77:163-70.
- ¹⁰³ Smith MJ, Higgs JE, Bowers NL, et al. *Cranial meningiomas in 411 neurofibromatosis type 2 (NF2) patients with proven gene mutations: clear positional effect of mutations, but absence of female severity effect on age at onset.* *J Med Genet* 2011;48:261-5.
- ¹⁰⁴ Evans DGR, Trueman L, Wallace A, et al. *Genotype phenotype correlations in NF2: evidence for more severe disease associated with truncating mutations.* *J Med Genet* 1998;35:450-5.
- ¹⁰⁵ Baser ME, Kuramoto L, Woods R, et al. *The location of constitutional neurofibromatosis 2 (NF2) splice-site mutations is associated with the severity of NF2.* *J Med Genet* 2005;42:540-6.
- ¹⁰⁶ Hexter A, Jones A, Joe H, et al. English Specialist NF2 Research Group, Friedman JM, Evans DG. *Clinical and molecular predictors of mortality in neurofibromatosis 2: a UK national analysis of 1192 patients.* *J Med Genet* 2015;52:699-75.
- ¹⁰⁷ Baser ME, Friedman JM, Aeschliman D, et al. *Predictors of the risk of mortality in neurofibromatosis 2.* *Am J Hum Genet* 2002;71:715-23.
- ¹⁰⁸ van den Munckhof P, Christiaans I, et al. *Germline SMARCB1 mutation predisposes to multiple meningiomas and schwannomas with preferential location of cranial meningiomas at the falx cerebri.* *Neurogenetics* 2012;13:1-7.
- ¹⁰⁹ Hadfield KD, Smith MJ, Trump D, et al. *SMARCB1 mutations are not a common cause of multiple meningiomas.* *J Med Genet* 2010;47:567-8.
- ¹¹⁰ Otto SR, Brackmann DE, Hitselberger WE, et al. *Multichannel auditory brainstem implant: update on performance in 61 patients.* *J Neurosurg* 2002;96:1063-71.
- ¹¹¹ Nunes F, MacCollin M. *Neurofibromatosis 2 in the pediatric population.* *J Child Neurol* 2003;18:718-24.
- ¹¹² Lloyd SK, Glynn FJ, Rutherford SA, et al. *Ipsilateral cochlear implantation after cochlear nerve preserving vestibular schwannoma surgery in patients with neurofibromatosis type 2.* *Otol Neurotol* 2014;35:43-51.
- ¹¹³ Evans DG, Raymond F, Barwell J, et al. *Genetic testing and screening of individuals at risk of NF2.* *Clin Genet* 2012;82:416-24.
- ¹¹⁴ Gutmann DH, Blakeley JO, Korf BR, et al. *Optimizing biologically targeted clinical trials for neurofibromatosis.* *Expert Opin Investig Drugs* 2013;22:443-62.
- ¹¹⁵ Lim SH, Ardern-Holmes S, McCowage G, et al. *Systemic therapy in neurofibromatosis type 2.* *Cancer Treat Rev* 2014;40:857-61.
- ¹¹⁶ Trovato A, Siracusa R, Di Paola R, et al. *Redox modulation of cellular stress response and lipoxin A4 expression by *Hericium Erinaceus* in rat brain: relevance to Alzheimer's disease pathogenesis.* *Immun Ageing* 2016;13:23.
- ¹¹⁷ Matin N, Tabatabaie O, Falsaperla R, et al. *Efficacy and safety of omalizumab in paediatric age: an update of literature data.* *J Biol Regul Homeost Agents* 2016;30:579-84.
- ¹¹⁸ Dattilo S, Mancuso C, Koverech G, et al. *Heat shock proteins*

- and hormesis in the diagnosis and treatment of neurodegenerative diseases. *Immun Ageing* 2015;12:20.
- ¹¹⁹ Serra A, Di Mauro P, Andaloro C, et al. *A selective mutism arising from first language attrition, successfully treated with paroxetine-cbt combination treatment.* *Psychiatry Investig* 2015;12:569-72.
- ¹²⁰ Vitaliti G, Tabatabaie O, Matin N, et al. *The usefulness of immunotherapy in pediatric neurodegenerative disorders: a systematic review of literature data.* *Hum Vaccin Immunother* 2015;11:2749-63.
- ¹²¹ Serra A, DI Mauro P, Cocuzza S, et al. *Audiological findings in a case of cerebellar angioreticuloma.* *Acta Otorhinolaryngol Ital* 2015;35:212-4.
- ¹²² Karajannis MA, Legault G, Hagiwara M, et al. *Phase II trial of lapatinib in adult and pediatric patients with neurofibromatosis type 2 and progressive vestibular schwannomas.* *Neuro Oncol* 2012;14:1163-70.
- ¹²³ Plotkin SR, Halpin C, McKenna MJ, et al. *Erlotinib for progressive vestibular schwannoma in neurofibromatosis 2 patients.* *Otol Neurotol* 2010;31:1135-43.
- ¹²⁴ Karajannis MA, Legault G, Hagiwara M, et al. *Phase II study of everolimus in children and adults with neurofibromatosis type 2 and progressive vestibular schwannomas.* *Neuro Oncol* 2014;16:292-97.
- ¹²⁵ Ammoun S, Hanemann CO. *Emerging therapeutic targets in schwannomas and other merlin-deficient tumors.* *Nat Rev Neurol* 2011;7:392-9.
- ¹²⁶ Lee TX, Packer MD, Huang J, et al. *Growth inhibitory and anti-tumour activities of OSU-03012, a novel PDK-1 inhibitor, on vestibular schwannoma and malignant schwannoma cells.* *Eur J Cancer* 2009;45:1709-20.
- ¹²⁷ Ammoun S, Schmid MC, Triner J, et al. *Nilotinib alone or in combination with selumetinib is a drug candidate for neurofibromatosis type 2.* *Neuro Oncol* 2011;13:759-66.
- ¹²⁸ Mukherjee J, Kamnasaran D, Balasubramaniam A, et al. *Human schwannomas express activated platelet-derived growth factor receptors and c-kit and are growth inhibited by Gleevec (ImatinibMesylate).* *Cancer Res* 2009;69:5099-107.
- ¹²⁹ Subbiah V, Slopis J, Hong DS, et al. *Treatment of patients with advanced neurofibromatosis type 2 with novel molecularly targeted therapies: from bench to bedside.* *J Clin Oncol* 2012;30:e64-8.
- ¹³⁰ Lim S, de Souza P. *Imatinib in neurofibromatosis type 2.* *BMJ Case Rep* 2013. pii: bcr2013010274.
- ¹³¹ Plotkin SR, Stemmer-Rachamimov AO, Barker FG 2nd, et al. *Hearing improvement after bevacizumab in patients with neurofibromatosis type 2.* *N Engl J Med* 2009;361:358-67.
- ¹³² Kamba T, McDonald DM. *Mechanisms of adverse effects of anti-VEGF therapy for cancer.* *Br J Cancer* 2007;96:1788-95.
- ¹³³ Morris KA, Golding JF, Axon PR, et al. *The UK NF2 Research group, Evans DG, McCabe MG, Parry A. Bevacizumab in Neurofibromatosis type 2 (NF2) related vestibular schwannomas: a nationally coordinated approach to delivery and prospective evaluation.* *Neuro-Oncology Practice* 2016;0:1-9. doi:10.1093/nop/npv06 [in press].
- ¹³⁴ Plotkin SR, Merker VL, Halpin C, et al. *Bevacizumab for progressive vestibular schwannoma in neurofibromatosis type 2: a retrospective review of 31 patients.* *Otol Neurotol* 2012;33:1046-52.
- ¹³⁵ Nunes FP, Merker VL, Jennings D, et al. *Bevacizumab treatment for meningiomas in NF2: a retrospective analysis of 15 patients.* *PLoS One* 2013;8:e59941.
- ¹³⁶ Hawasli AH, Rubin JB, Tran DDet al. *Antiangiogenic agents for nonmalignant brain tumors.* *J Neurol Surg B Skull Base* 2013;74:136-41.
- ¹³⁷ Alanin MC, Klausen C, Caye-Thomasen P, et al. *The effect of bevacizumab on vestibular schwannoma tumour size and hearing in patients with neurofibromatosis type 2.* *Eur Arch Otorhinolaryngol* 2015;272:3627-33.
- ¹³⁸ Hochart A, Gaillard V, Baroncini M, et al. *Bevacizumab decreases vestibular schwannomas growth rate in children and teenagers with neurofibromatosis type 2.* *J Neurooncol* 2015;124:229-36.
- ¹³⁹ Farschtschi S, Kollmann P, Dalchow C, et al. *Reduced dosage of bevacizumab in treatment of vestibular schwannomas in patients with neurofibromatosis type 2.* *Eur Arch Otorhinolaryngol* 2015;272:3857-60.
- ¹⁴⁰ Mautner VF, Nguyen R, Kutta H, et al. *Bevacizumab induces regression of vestibular schwannomas in patients with neurofibromatosis type 2.* *Neuro Oncol* 2010;12:14-8.
- ¹⁴¹ Eminowicz GK, Raman R, Conibear J, et al. *Bevacizumab treatment for vestibular schwannomas in neurofibromatosis type two: report of two cases, including responses after prior gamma knife and vascular endothelial growth factor inhibition therapy.* *J Laryngol Otol* 2012;126:79-82.
- ¹⁴² Riina HA, Burkhardt JK, Santillan A, et al. *Short-term clinico-radiographic response to super-selective intra-arterial cerebral infusion of Bevacizumab for the treatment of vestibular schwannomas in Neurofibromatosis type 2.* *Interv Neuroradiol* 2012;18:127-32.
- ¹⁴³ Otsuka G, Saito K, Nagatani T, et al. *Age at symptom onset and long-term survival in patients with neurofibromatosis Type 2.* *J Neurosurg* 2003;99:480-3.

Received: February 10, 2016 - Accepted: April 29, 2016

Address for correspondence: Martino Ruggieri, Unit of Rare Diseases of the Nervous System in Childhood, Department of Clinical and Experimental Medicine Section of Pediatrics and Child Neuropsychiatry, A.O.U. "Policlinico-Vittorio Emanuele" University of Catania via S. Sofia 78, 95124 Catania. Tel. +39 095 3781281. Fax +39 095 7466385. E-mail: m.ruggieri@unict.it