

Case report

Sixth cranial nerve palsy and ipsilateral trigeminal neuralgia caused by vertebrasilar dolichoectasia

Thong Pham^{a,*}, Jeffrey Wesolowski^c, Jonathan D. Trobe^{a,b}^a Kellogg Eye Center, Department of Ophthalmology and Visual Sciences, University of Michigan, USA^b Department of Neurology, University of Michigan, USA^c Department of Radiology (Neuroradiology), University of Michigan Medical Center, USA

ARTICLE INFO

Keywords:

Dolichoectasia
Sixth nerve palsy
Diplopia
Trigeminal neuralgia

ABSTRACT

Purpose: To report an unusual case of vertebrasilar dolichoectasia causing both trigeminal neuralgia and ipsilateral sixth cranial nerve palsy.

Observations: A patient had undergone surgical decompression of trigeminal neuralgia caused by dolichoectatic vertebral and basilar arteries years before presenting with ipsilateral sixth nerve palsy. Brain MRI showed deviant vertebrasilar arteries that presumably now compressed the sixth cranial nerve. The unaffected left sixth cranial nerve was visible on MRI, but the affected right sixth cranial nerve was not. The central spinal fluid space in Dorello's canal on the affected side was relatively ample, suggesting atrophy of the affected sixth cranial nerve. On follow-up examination one year after presentation, the patient's diplopia was palliated with spectacle prism.

Conclusions and importance: This is the tenth reported case of dolichoectasia causing sixth cranial nerve palsy, but only the second to occur with dolichoectatic trigeminal neuralgia. It provides more detailed imaging than previously reported cases. Review of reported cases of dolichoectatic compression of cranial nerves indicates that vascular decompression may be effective for trigeminal neuralgia, but is not indicated for dolichoectatic sixth nerve palsy, which will resolve spontaneously or can be effectively managed with prism or eye muscle surgery.

1. Introduction

Dolichoectasia (Greek “dolichos” = long, and “ektasis” = stretching) describes enlarged, tortuous, and dilated intracranial arteries. For the basilar artery, it refers to uniform enlargement of the arterial diameter and lateral or vertical arterial displacement. In CT angiography, vertebrasilar dolichoectasia has been defined as a basilar artery diameter greater than 4.5 mm and a coursing of the basilar artery lateral to the clivus or a basilar artery bifurcation that occurs above the level of the suprasellar cistern.¹

Dolichoectasia is seen most commonly in middle-aged men with hypertension and high cholesterol who smoke tobacco.^{2,3} There are four categories of presentation: 1) acute ischemia in the vertebrasilar arterial territory; 2) compression of cranial nerves, brain stem, or third ventricle; 3) parenchymal or subarachnoid hemorrhage; 4) incidental finding.^{2,3}

In 28% of cases with clinical manifestations, compression of the brainstem or cranial nerves is the cause of the symptoms.³ Trigeminal and facial nerves are most often affected, resulting in trigeminal neuralgia and hemifacial spasm, respectively. There are rare reports of third,

fourth, eighth, ninth, and tenth cranial nerve compression from vertebrasilar dolichoectasia. Among the 9 reports of dolichoectatic sixth cranial nerve palsy,^{4–11} only one has involved more than one cranial nerve. In that case, sixth cranial nerve palsy was combined with ipsilateral trigeminal neuralgia and hemifacial spasm.¹² We report a similar case, in which sixth cranial nerve palsy caused by dolichoectasia followed ipsilateral trigeminal neuralgia by an interval of 6 years.

2. Case report

A 58-year-old man presented with a 6-month history of painless binocular horizontal double vision. At first the diplopia was intermittent, but after a month, it became constant. Diplopia was present mostly on right gaze. Six years earlier, he had undergone vascular decompressive surgery for trigeminal neuralgia on the right side.

A former heavy smoker, the patient also had systemic hypertension, hemochromatosis, and arthritis.

All aspects of the ophthalmic examination were normal except for incomplete right abduction and an incomitant esodeviation measured by prism and cover test as 3 prism-diopters (PD) in primary position, 6

* Corresponding author. Kellogg Eye Center, 1000 Wall Street, USA.
E-mail address: jdtrobe@umich.edu (T. Pham).

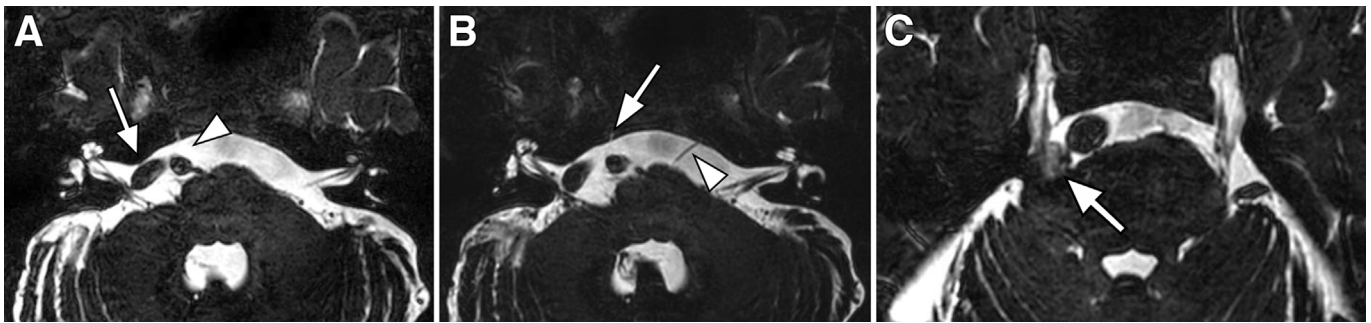


Fig. 1. MRI performed six months after onset of right sixth nerve palsy, axial constructive interference in steady state (CISS) sequence. A. At the pontomedullary junction, dolichoectatic right vertebral artery courses rightward into the right cerebellopontine angle, adjacent to the seventh and eighth cranial nerves (arrow); the right sixth cranial nerve is not seen (arrowhead). B. Axial level slightly rostral to A. There is more high signal in Dorello's canal on the right side than on the left side (arrow), suggesting atrophy of the right sixth cranial nerve. The left sixth cranial nerve is visible (arrowhead). C. Axial level rostral to B. Decompression pad used 6 years earlier to treat right trigeminal neuralgia is visible adjacent to cisternal trigeminal nerve (arrow).

PD on right gaze, and orthotropic on left gaze. He was fitted with a Fresnel press-on 4 base-out prism over the distance segment of the left lens of his bifocal spectacles.

Brain MRI, with constructive interference in steady state (CISS), demonstrated a 7.5mm diameter basilar artery that was shifted into the right cerebellopontine angle, at the point of brainstem exit of the right sixth cranial nerve. The right sixth cranial nerve was not discernible. By comparison, the left sixth cranial nerve was easily visible as it exited the pons and traveled toward Dorello's canal (Fig. 1). The right Dorello's canal contained increased cerebrospinal fluid signal as compared to the left side, suggesting the possibility of an atrophic right sixth cranial nerve. A small mass on the right side remote from the path of the sixth cranial nerve had signal characteristics of a pad used in earlier treatment of ipsilateral trigeminal neuralgia. The size and position of the vertebral and basilar arteries had not changed in relation to an MRI performed 3 years earlier.

Follow-up examination 12 months later indicated a slight increase in the right abduction deficit with a 6 PD esotropia in primary gaze, 10 PD on right gaze, and orthotropic on left gaze. There were no other new neuro-ophthalmic abnormalities. Ground-in 5 PD base-out prism OU palliated his diplopia.

3. Discussion

There have been 9 case reports of sixth cranial palsy caused by dolichoectasia^{4–12} (Table). Only one case¹² described a patient with multiple cranial neuropathies including the sixth cranial nerve, such as we report. That case involved a patient with diplopia owing to a left abduction deficit, together with episodic left facial pain and ipsilateral facial muscle twitches (“tic convulsive”), attributed to compression of the fifth, sixth, and seventh nerves by dolichoectatic vertebral and basilar arteries. MRI showed non-visualization of the affected nerves by the deviant blood vessels. The patient's painful facial twitches were controlled with carbamazepine and pregabalin; the sixth nerve palsy had resolved spontaneously within one month.

Review of the 9 prior reported cases of dolichoectatic sixth nerve palsy reveals an age range of 46–71 years. Eight of the 9 cases have involved men and 6 have involved the left side (unlike our case, which involved the right side). Six cases had hypertension as a presumably contributory factor.

Among the 6 reports that specified the MRI sequence, 2 had spoiled gradient echo (SPGR) and 4 had CISS, as did our case. In 5 cases, MRI showed contact of the dolichoectatic vertebrobasilar arteries with the sixth cranial nerve, and in 4 cases there was distortion of the root entry zone.

MRI in our case did not reveal the affected sixth cranial nerve, but clearly showed the extra-axial course of the unaffected sixth cranial nerve. Our case adds an additional finding an enlarged CSF space in

Dorello's canal on the affected side, suggesting atrophy of the affected sixth cranial nerve.

In 7 reported cases, no surgical treatment was performed. In 6 of those cases, outcome of the sixth cranial nerve palsy was reported, with a follow-up time ranging from 6 months to 4 years. The palsy remained stable in 3 cases, improved in 1 case, and resolved spontaneously in 1 case after 1 month.¹² One case was deemed to have “improved”, but no further details were provided.⁶ In 1 case, the palsy was described as having recurred 3 times over 6 months, but no further details were given.¹¹

One reported case underwent vascular decompression, and the palsy improved immediately post-operatively with resolution after “a few days”.¹⁰ One case was treated with eye muscle surgery, which was successful in restoring single binocular vision in all directions of gaze.⁹ In none of the reported cases was palliation of diplopia with spectacle prism described, such as was performed in our case.

In combining the previous case reports with our case, the following profile of dolichoectatic sixth cranial nerve palsy emerges. Patients are generally older men with hypertension. MRI with T1-weighted SPGR sequence or with the T2-weighted CISS sequence shows vertebrobasilar dolichoectasia in contact with the sixth cranial nerve near its exit from the pons. In most cases, patients have not undergone surgical treatment and the sixth cranial nerve palsy has remained stable or resolved.

Based on a review³ of patients with dolichoectasia found incidentally or in conjunction with other neurological manifestations, outcomes have depended on the clinical manifestations and whether the vessel enlarges. The main adverse outcomes associated with dolichoectasia are stroke, hemorrhage, and increased general mortality not driven solely by neurologic or cardiovascular causes. Among patients without clinical manifestations or with isolated cranial neuropathies, prognosis is relatively good as long as the vessels do not enlarge. There is a slight increase in stroke risk reflective of underlying arteriosclerotic risk factors. Among patients who present with stroke, there is a high risk of recurrent stroke. In patients who present with hemorrhage, symptoms of parenchymal brain compression, or enlargement of the dolichoectatic vessel over time, there is a greatly increased mortality rate.

There is currently no satisfactory treatment of vertebrobasilar dolichoectasia. Microvascular surgical decompression, often used for refractory trigeminal neuralgia, as in our patient, is not necessary in the management of sixth cranial nerve palsy as the sixth cranial nerve palsy will remain stable or spontaneously resolve. Unrelenting diplopia can be managed with spectacle prism or eye muscle surgery.

Patient consent

Written consent to publish this case report has not been obtained. This report does not contain any personal identifying information.

Table
Reported cases of sixth cranial nerve palsy caused by vertebrobasilar dolichoectasia.

Author	Year of publication	Patient Age/Gender	Side of Palsy	Severity of Palsy	Risk Factors	Other Clinical Manifestations	Imaging modality	MRI Pulse sequence	Site of compression	Treatment	Outcome of Palsy
Ohtsuka ⁴	1996	46/M	Left	Slow abduction on EOG	HTN	Isolated	MRI	SPGR	Nerve and root entry zone	None	Stable after 1 year
Nara ⁵	2000	47/M	Right	ND	HTN	Isolated	MRI	SPGR	Nerve	ND	ND
Ohhashi ⁶	2001	71/F	Left	ND	HTN	Isolated	MRI	CISS	Root entry zone	Treatment of HTN	"Improved"
Goldenberg-Cohen ⁷	2003	65/M	Left	35° abduction; ET 25 PD primary, 45 PD left gaze, 15 PD right gaze	HTN, HLD	Isolated	MRI, MRA, CTA	ND	Root entry zone	None	Stable after 4 years
Gray ⁸	2005	53/M	Right	ND	None	Isolated	MRI, MRA	ND	Nerve	None	Stable after 6 months
Zhu ⁹	2005	68/M	Left	50% abduction; ET: 35 PD primary, 40 PD left gaze, 20 PD right gaze	HTN	Isolated	MRI	ND	Root entry zone	Eye muscle surgery	Stable for 13 months before surgery. Resolved 3 months after eye muscle surgery.
De Ridder ¹⁰	2007	56/M	Right	"Near total palsy"	None	Previous carotid artery aneurysm causing L 3rd nerve palsy	MRI	CISS	Nerve	Vascular decompression	Resolved over "a few days" after decompressive surgery
Kato ¹¹	2010	49/M	Left	ND	None	Isolated	MRI	CISS	Nerve	None	Recurrent 3 times in 6 months, no further details
Madhugiri ¹²	2012	68/M	Left	ND	HTN	Ipsilateral trigeminal neuralgia, hemifacial spasm ("tic convulsif")	MRI	CISS	Root entry zone	None	Resolved spontaneously after 1 month; followed for 14 months
Pham (current case)	2016	58/M	Right	90% abduction. ET 4 PD primary, 6 PD right gaze, 2 PD left gaze	HTN, former smoker	Ipsilateral trigeminal neuralgia s/p decompression 6 years earlier	MRI	CISS	Right sixth nerve not clearly seen	Press-on Prism	Stable during 8-month follow-up

Key: ND: not described; ET = esotropia; PD = prism-diopters; CISS = constructive interference in steady state; SPGR = spoiled gradient recalled acquisition.

Funding

There is no funding or grant support.

Conflicts of interest

The following authors have no financial disclosures; JDT, TP, JW.

Authorship

All authors attest that they meet the current ICMJE criteria for authorship.

Acknowledgments

None.

References

- Smoker WRK, Price MJ, Keyes WD, Price MJ, McKusker S. High-resolution computed tomography of the basilar artery. Vertebrobasilar dolichoectasia: clinical-pathologic correlation and review. *AJNR Am J Neuroradiol*. 1986;7(1):61–72.
- Passero SG, Rossi S. Natural history of vertebrobasilar dolichoectasia. *Neurology*. 2008;70(1):66–72.
- Shapiro M, Becske T, Riina HA, Raz E, Zumofen D, Nelson PK. Non-saccular vertebrobasilar aneurysms and dolichoectasia: a systematic literature review. *J Neurointerventional Surg*. 2014;6(5):389–393.
- Ohtsuka K, Sone A, Igarashi Y, Akiba H, Sakata M. Vascular compressive abducens nerve palsy disclosed by magnetic resonance imaging. *Am J Ophthalmol*. 1996;122(3):416–419.
- Narai H, Manabe Y, Deguchi K, Iwatsuki K, Sakai K, Abe K. Isolated abducens nerve palsy caused by vascular compression. *Neurology*. 2000;55(3):453–454.
- Ohhashi G, Irie K, Tani S, Ogawa T, Abe T, Hata Y. Isolated abducens nerve palsy caused by the compression of the basilar artery: a case report. *No Shinkei*. 2001;53(1):69–72.
- Goldenberg-Cohen N, Miller NR. Noninvasive neuroimaging of basilar artery dolichoectasia in a patient with an isolated abducens nerve paresis. *Am J Ophthalmol*. 2004;137(2):365–367.
- Giray S, Pelit A, Kizilkilic O, Karatas M. Isolated abducens nerve palsy caused by contralateral vertebral artery dolichoectasia. *Neurol India*. 2005;53(2):246–247.
- Zhu Y, Thulborn K, Curnyn K, Goodwin J. Sixth cranial nerve palsy caused by compression from a dolichoectatic vertebral artery. *J Neuro Ophthalmol*. 2005;25(2):134–135.
- De Ridder D, Menovsky T. Neurovascular compression of the abducent nerve causing abducent palsy treated by microvascular decompression. Case report. *J Neurosurg*. 2007;107(6):1231–1234.
- Kato H, Nakajima M, Ohnaka Y, Ishihara K, Kawamura M. Recurrent abducens nerve palsy associated with neurovascular compression. *J Neurol Sci*. 2010;295(1–2):135–136 15.
- Madhugiri VS, Roopesh Kumar VR, Gopalakrishnan MS, Shankar Ganesh CV, Sudheer Kumar G. Cranial polyneuropathy associated with vertebrobasilar dolichoectasia. *Clin Neurol Neurosurg*. 2012;114(7):1059–1061.