



CASE REPORT

**REVISED** Case Report: An incidental finding of an metastases noted in a “cancer to cancer adrenal tumor ” from a large malignant nerve sheath tumor of the thigh [version 2; referees: 2 approved]

Previously titled: Case Report: An incidental finding of an adrenal metastases noted in a “collision tumor” from a large malignant nerve sheath tumor of the thigh

Matthew D. Shaines , Shitij Arora

Department of Internal Medicine, Division of Hospital Medicine, Montefiore Medical Center, Albert Einstein College of Medicine, Bronx, New York City, NY, USA

**v2** First published: 07 Nov 2017, 6:1964 (doi: 10.12688/f1000research.12647.1)  
 Latest published: 09 Apr 2018, 6:1964 (doi: 10.12688/f1000research.12647.2)

**Abstract**







Current guidelines are vague for the management of soft tissue sarcomas, specifically malignant peripheral nerve sheath tumors (MPNST), regarding staging the disease with the use of routine abdominal imaging. The most recent guidelines from the National Comprehensive Cancer Network (NCCN) recommends to “consider” abdominal/pelvic CT imaging for certain sub groups of sarcomas (e.g., myxoid/round cell liposarcoma, epithelial sarcoma, angiosarcoma, leiomyosarcoma), but provide no guidance on other sarcoma subtypes regardless of tumor size. We report a case of a very large large MPNST in a 40 year-old-female with neurofibromatosis type 1 who was incidentally found to have adrenal metastasis.



**Keywords**

nerve sheath tumor, adrenal, lung, metastasis

**Open Peer Review**

Referee Status:  

	Invited Referees	
	1	2
<b>REVISED</b>		
<b>version 2</b>	report	report
published 09 Apr 2018		
<b>version 1</b>		
published 07 Nov 2017	report	report

- 1 **Ahmed Abu-zaid** , University of Tennessee Health Science Center, USA
- 2 **Shweta Gera** , Montefiore Medical Center, USA

**Discuss this article**

Comments (0)

**Corresponding author:** Shitij Arora ([sharora@montefiore.org](mailto:sharora@montefiore.org))

**Author roles:** Shaines MD: Conceptualization, Data Curation, Writing – Original Draft Preparation, Writing – Review & Editing; Arora S: Visualization

**Competing interests:** No competing interests were disclosed.

**How to cite this article:** Shaines MD and Arora S. **Case Report: An incidental finding of an metastases noted in a “cancer to cancer adrenal tumor ” from a large malignant nerve sheath tumor of the thigh [version 2; referees: 2 approved]** *F1000Research* 2018, **6**:1964 (doi: [10.12688/f1000research.12647.2](https://doi.org/10.12688/f1000research.12647.2))

**Copyright:** © 2018 Shaines MD and Arora S. This is an open access article distributed under the terms of the [Creative Commons Attribution Licence](https://creativecommons.org/licenses/by/4.0/), which permits unrestricted use, distribution, and reproduction in any medium, provided the original work is properly cited.

**Grant information:** The author(s) declared that no grants were involved in supporting this work.

**First published:** 07 Nov 2017, **6**:1964 (doi: [10.12688/f1000research.12647.1](https://doi.org/10.12688/f1000research.12647.1))

**REVISED** Amendments from Version 1

We have addressed the reviewer concerns and added to the Abstract, Introduction and Case report sections. We agree with changing the title from "collision tumor" to "cancer to cancer" metastasis given the ambiguous definitions.

See referee reports

## Introduction

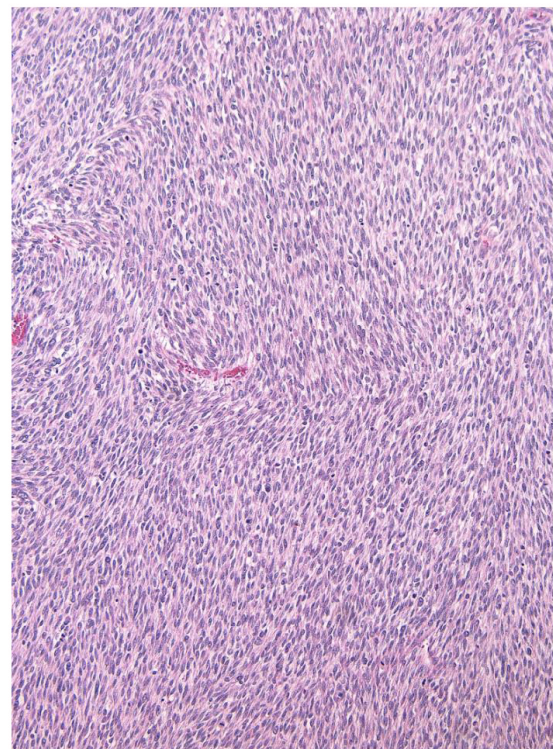
Soft tissue sarcomas of the extremity are a rare disease process, comprising less than 1% of all malignancies<sup>1</sup>. The majority of soft-tissue sarcomas occur in the limb or limb girdle or within the abdomen, with 40% being found in the lower extremities. These sarcomas are a histologically heterogeneous group of tumors (over 50 tumor subtypes have been identified) with a predilection for hematogenous spread. Distant metastatic disease is found in approximately 20–30% of patients<sup>1–3</sup>, with pulmonary lesions accounting for 75% of these cases<sup>1,4,5</sup>. Because of the relatively low incidence of extra-pulmonary metastasis, the current guidelines from the National Comprehensive Cancer Network (NCCN) recommends to only “consider” abdominal/pelvic CT imaging for certain subgroups of sarcomas (myxoid/round cell liposarcoma, epithelial sarcoma, angiosarcoma, leiomyosarcoma)<sup>6</sup>. A similar recommendation is made by the European Society of Medical Oncology (ESMO)/European Sarcoma Network Working Group<sup>7</sup>. No specific recommendation is made for any additional sarcoma subtype regardless of size of the tumor, despite this being a known prognostic factor.

Malignant peripheral nerve sheath tumors (MPNST) are highly malignant sarcomas which originate from peripheral nerves or from cells associated with the nerve sheath, such as Schwann cells, perineural cells, or fibroblasts. MPNSTs comprise 5–10% of all soft tissue sarcomas with 22–50% of the tumors associated with a diagnosis of Neurofibromatosis-1 (NF1)<sup>8–10</sup>. We report a case of a malignant peripheral nerve sheath tumor of the thigh, without evidence of concomitant pulmonary metastases, which was found to have metastasized to the adrenal gland. Thus, we pose the question of should the staging work up for large sarcomas be expanded to include abdominal imaging, even if the CT chest is unrevealing?

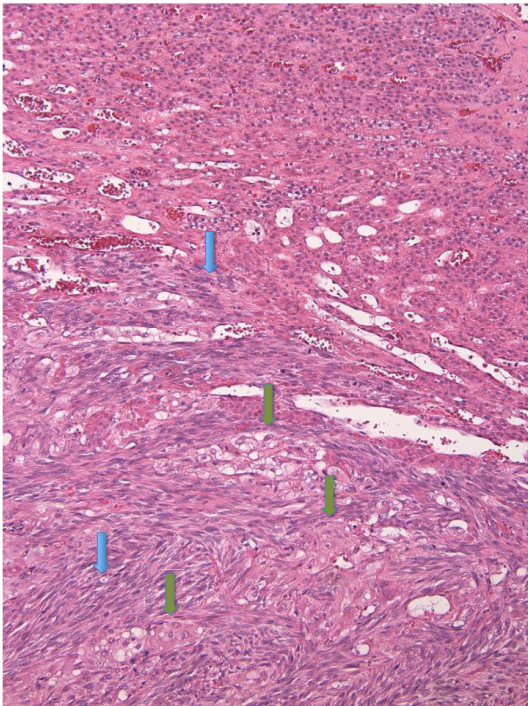
## Case report

A 40 year old woman with NF1 presented for a hemorrhagic right thigh mass which had been enlarging over the past 3 months. The mass had previously been stable in size for a few years and was thought to be consistent with a neurofibroma. On presentation her exam was notable for a very large soft tissue tumor of the right posterior upper leg (>15cm). The distal portion of the lesion revealed skin breakdown and active bleeding with exposed muscle and tumor. Laboratory analyses revealed a white blood cell count of 23.0k/ $\mu$ L and hemoglobin of 10.7 g/dL with an unremarkable basic metabolic panel. Computerized tomogram (CT) of the extremities revealed a large

heterogeneously enhancing mass within the posterior compartment of the right thigh, measuring 13.4 × 13.4 × 24.8 cm. In addition, an incidental 2 × 2 cm left adrenal gland mass was noted. Of note, a CT scan of the thorax, completed for staging purposes, did not reveal any suspicious pulmonary nodules or masses. After an initial excisional biopsy of the thigh mass, she underwent a radical resection of the right thigh mass. Pathology confirmed a high grade spindle cell sarcoma, negative for S100 protein and SOX10 (variable expression in MPNST), Desmin (rhabdomyosarcoma differentiation), CD31 and AE1:AE3 (vascular sarcomas, myoepitheliomas), HMB45, MelanA (epitheloid MPNST). Given the clinical history of NF-1 and the lack of immunoreactivity for all performed markers for this tumor was most compatible with an undifferentiated MPNST (Figure 1) AMRI of the abdomen, to further evaluate the adrenal mass, revealed 2 small left adrenal gland lesions in the medial and lateral limbs. Given the known association of neurofibromatosis with pheochromocytoma, a biochemical workup was pursued and confirmed this diagnosis. The patient underwent a laparoscopic adrenalectomy, with gross pathological exams revealing two tumor nodules and with a histological exam revealing an intermixed “cancer to cancer metastasis” involving pheochromocytoma and sarcoma, consistent with MPNST (Figure 2). The patient refused radiation therapy and did not follow up with oncology.



**Figure 1.** Section from the thigh mass (10x, H&E) shows a hypercellular tumor, with spindle cells in sheets and fascicular arrangement. The spindle-shaped nuclei have clumped chromatin. These features are compatible with a malignant peripheral nerve sheath tumor.



**Figure 2.** The area on the right shows two populations of tumor cells that are intermingling with each other, representing a collision tumor (20x, H&E). One population is composed of hypercellular malignant spindle cells with hyperchromatic nuclei (blue arrow) that are infiltrating the adjacent adrenal tissue. This is morphologically compatible with malignant peripheral nerve sheath tumor. The other population is composed of the nests of polygonal cells with abundant eosinophilic cytoplasm (green arrow), compatible with pheochromocytoma.

## Discussion

The above case describes a patient with a MPNST of the thigh with pathologically confirmed metastases to the adrenal gland, yet without evidence of pulmonary metastases. The adrenal mass was found incidentally upon imaging of the thigh mass, but based on current NCCN guidelines<sup>6</sup>, a screening CT of the abdomen/pelvis (A/P) would not be indicated and thus could have potentially missed the presence of metastatic disease.

To the best of our knowledge there have only been 2 case series that comment on the indication for A/P imaging in sarcoma patient and they reached contradictory conclusions. In the first case series, King, *et al.* evaluated 124 adult patients with sarcoma who underwent CT chest(C)/A/P imaging at their institution for staging and surveillance. Twenty (16%) of the patients had evidence of A/P metastasis, 7 on the initial scan and 13 on the surveillance<sup>11</sup>. Of note, six of the 20 patients (5% of the cohort) were found to have isolated A/P metastases without the development of pulmonary metastases during

the study period. MPNST, specifically, made up 6% of the sarcomas evaluated and while no A/P metastases were found on screening, 2 patients had evidence on surveillance scans. Based on the finding that a wide variety of sarcoma subtypes were found to have extra-pulmonary disease, the authors conclude that A/P imaging should be included in the evaluation of all sarcoma subtypes. In contrast, Thompson *et al.* reviewed 140 patients of all ages who had a diagnosis of a malignant neoplasm of the upper or lower extremity and underwent screening and/or surveillance with a CT C/A/P<sup>12</sup>. Of those patients, 14 (10%) had evidence of abdominal/pelvic metastasis, with only 4 (2.9%) with evidence of isolated A/P disease. Additionally, of the 10 patients who developed metastases to both the chest and abdomen/pelvis, none developed evidence of disease in the abdomen/pelvis prior to the chest. Of note, though, there were only 2 MPNSTs in the entire cohort and neither one had evidence of abdominopelvic disease on imaging. Based on their results, the authors offer up the contrary opinion from King and do not support routine abdomen/pelvis imaging.

Our case adds a patient to the literature with a peripheral MPNST who was found to have an isolated adrenal metastasis without evidence of concomitant pulmonary disease. One striking feature of this case is the very large size of the primary tumor (>20 cm). Factors known to be associated with the development of metastases are tumor grade, tumor size, tumor depth, and certain histopathologies. Specifically, tumors > 5cm have been found to be associated with an increased risk of metastatic recurrence<sup>13</sup>. Currently, though, guidelines only recommend CT of the chest for all patients and to consider CT A/P in patients with myxoid/round cell liposarcoma, epithelial sarcoma, angiosarcoma and leiomyosarcoma. Based on our case and the literature, we also would suggest adding screening CT A/P for large (>5 cm), deep tumors of any histology.

## Conclusions

Soft tissue sarcomas are a heterogeneous group of tumors with a variety of prognoses. Deciding on a unified set of guidelines will be challenging, but given the clinical significance of finding metastatic disease, adding additional parameters (size and depth) to a more complete screening process would seem prudent.

## Consent

Written informed consent was obtained by the patient for publication of their clinical details. There are no potentially identifying images included in this paper.

## Competing interests

No competing interests were disclosed.

## Grant information

The author(s) declared that no grants were involved in supporting this work.

## References

---

1. Clark MA, Fisher C, Judson I, *et al.*: **Soft-tissue sarcomas in adults.** *N Engl J Med.* 2005; **353**(7): 701–11.  
[PubMed Abstract](#) | [Publisher Full Text](#)
2. Kane JM 3rd: **Surveillance strategies for patients following surgical resection of soft tissue sarcomas.** *Curr Opin Oncol.* 2004; **16**(4): 328–332.  
[PubMed Abstract](#) | [Publisher Full Text](#)
3. Pisters PW, Leung DH, Woodruff J, *et al.*: **Analysis of prognostic factors in 1,041 patients with localized soft tissue sarcomas of the extremities.** *J Clin Oncol.* 1996; **14**(5): 1679–1689.  
[PubMed Abstract](#) | [Publisher Full Text](#)
4. Billingsley KG, Lewis JJ, Leung DH, *et al.*: **Multifactorial analysis of the survival of patients with distant metastasis arising from primary extremity sarcoma.** *Cancer.* 1999; **85**(2): 389–395.  
[PubMed Abstract](#) | [Publisher Full Text](#)
5. Potter DA, Glenn J, Kinsella T, *et al.*: **Patterns of recurrence in patients with high-grade soft-tissue sarcomas.** *J Clin Oncol.* 1985; **3**(3): 353–366.  
[PubMed Abstract](#) | [Publisher Full Text](#)
6. von Mehren M, Randall RL, Benjamin RS, *et al.*: **Soft tissue sarcoma.** Version 2. 2017, 2017.
7. ESMO/European Sarcoma Network Working Group: **Soft tissue and visceral sarcomas: ESMO Clinical Practice Guidelines for diagnosis, treatment and follow-up.** *Ann Oncol.* 2014; **25**(Suppl 3): iii102–iii112.  
[PubMed Abstract](#) | [Publisher Full Text](#)
8. Baehring JM, Betensky RA, Batchelor TT: **Malignant peripheral nerve sheath tumor: the clinical spectrum and outcome of treatment.** *Neurology.* 2003; **61**(5): 696–8.  
[PubMed Abstract](#) | [Publisher Full Text](#)
9. Kim DH, Murovic JA, Tiel RL, *et al.*: **A series of 397 peripheral neural sheath tumors: 30-year experience at Louisiana State University Health Sciences Center.** *J Neurosurg.* 2005; **102**(2): 246–55.  
[PubMed Abstract](#) | [Publisher Full Text](#)
10. Ducatman BS, Scheithauer BW, Piepgras DG, *et al.*: **Malignant peripheral nerve sheath tumors. A clinicopathologic study of 120 cases.** *Cancer.* 1986; **57**(10): 2006–21.  
[PubMed Abstract](#) | [Publisher Full Text](#)
11. King DM, Hackbarth DA, Kilian CM, *et al.*: **Soft-tissue Sarcoma Metastases Identified on Abdomen and Pelvis CT Imaging.** *Clin Orthop Relat Res.* 2009; **467**(11): 2838–2844.  
[PubMed Abstract](#) | [Publisher Full Text](#) | [Free Full Text](#)
12. Thompson MJ, Ross J, Domson G, *et al.*: **Screening and surveillance CT abdomen/pelvis for metastases in patients with soft-tissue sarcoma of the extremity.** *Bone Joint Res.* 2015; **4**(3): 45–9.  
[PubMed Abstract](#) | [Publisher Full Text](#) | [Free Full Text](#)
13. Zagars GK, Ballo MT, Pisters PW, *et al.*: **Prognostic factors for patients with localized soft-tissue sarcoma treated with conservation surgery and radiation therapy: an analysis of 1225 patients.** *Cancer.* 2003; **97**(10): 2530–2543.  
[PubMed Abstract](#) | [Publisher Full Text](#)

# Open Peer Review

Current Referee Status:  

---

## Version 2

Referee Report 14 May 2018

doi:[10.5256/f1000research.15689.r32955](https://doi.org/10.5256/f1000research.15689.r32955)

 **Shweta Gera** 

Department of Pathology, Montefiore Medical Center, Bronx, NY, USA

Authors have addressed the majority of the concerns except few. Eg. No correction of epithelial sarcoma to epithelioid sarcoma, expanding on the physical and gross examination for thigh mass and adrenal metastasis. There is some problem with spacing between the words as well, eg- "AMRI", "withNF1". Please consider addressing these issues.

**Competing Interests:** No competing interests were disclosed.

**Referee Expertise:** Pathology, oncology

**I have read this submission. I believe that I have an appropriate level of expertise to confirm that it is of an acceptable scientific standard.**

Referee Report 13 April 2018

doi:[10.5256/f1000research.15689.r32956](https://doi.org/10.5256/f1000research.15689.r32956)

 **Ahmed Abu-zaid** 

College of Graduate Health Sciences, University of Tennessee Health Science Center, Memphis, TN, USA

With interest, I read the revised version of manuscript. Authors have addressed almost all the comments. The manuscript needs minor English polishing prior to final publication (for example, the title mentions "an metastases") and many others throughout the manuscript.

**Competing Interests:** No competing interests were disclosed.

**Referee Expertise:** Medical oncology, surgical oncology

**I have read this submission. I believe that I have an appropriate level of expertise to confirm that it is of an acceptable scientific standard.**

---

## Version 1

Referee Report 08 January 2018

doi:10.5256/f1000research.13693.r29117



**Shweta Gera**

Department of Pathology, Montefiore Medical Center, Bronx, NY, USA

The case report describes an interesting finding but it needs major revision. Some of the changes suggested as below-

- It describes an NF type-1 patient with MPNST with metastasis to the adrenal gland. The patients with NF type-1 have increased risk for pheochromocytoma. Likely the patient had undiagnosed pheochromocytoma (was the patient hypertensive?) and the patient developed metastasis to pheochromocytoma. So it describes more of cancer-to-cancer metastasis than collision tumor. Add more references with respect to cancer-to-cancer metastasis. Collision tumor is defined as two distinct tumors developing in juxtaposition to one another without areas of intermingling. In the current case, as in Figure 2, there is an intermingling of both components- so again it is not a collision tumor. The title needs to be changed and make it apt.
- Spelling errors like prognoses (mentioned in conclusion). There is nothing called epithelial sarcoma, the correct terminology is epithelioid sarcoma. MPNST stands for malignant peripheral nerve sheath tumor so no need for peripheral MPNST (mentioned in the first line of the last paragraph of discussion). Please check for grammatical errors as well.
- Abstract- talks about guidelines for staging peripheral nerve sheath tumors, which sounds like it was a benign tumor. So use MPNST instead of just peripheral nerve sheath tumor. Abstract and discussion mention isolated adrenal metastasis, which is not true; she had both bone and adrenal metastasis. There is mention that- "She underwent primary and adrenal metastasis resection." consider revising it to primary tumor resection and adrenalectomy for metastasis.
- Expand on physical exam of thigh mass- size, tenderness, consistency etc. Elaborate on findings of MRI with details of imaging findings of adrenal metastasis.
- Expand on gross findings of thigh mass and adrenal nodules- eg. size, color, infiltrative or well-circumscribed etc. Did both the adrenal nodules have similar histological findings? Were any immunostains done to confirm pheochromocytoma component?
- Ref 9 talks about patients with malignant neoplasm of the upper or lower extremity. There is no mention of that those were sarcomas. Check for that.
- Expand on abstract- add more about the significance of the findings of the case; expand on introduction and discussion- add more details for sarcoma, development of MPNST in association to NF-1, adrenal metastasis, management guidelines, more references for the recommendation for screening CT A/P for sarcomas. In the discussion, authors have suggested adding screening CT A/P for large (>5cm), deep tumors of any histology- expand more on this by adding more references.
- Add limitations of the study, the major limitation being small sample size.

**Is the background of the case's history and progression described in sufficient detail?**

Partly

**Are enough details provided of any physical examination and diagnostic tests, treatment given and outcomes?**

Partly

**Is sufficient discussion included of the importance of the findings and their relevance to future understanding of disease processes, diagnosis or treatment?**

Partly

**Is the case presented with sufficient detail to be useful for other practitioners?**

Partly

**Competing Interests:** No competing interests were disclosed.

**Referee Expertise:** Pathology, oncology

**I have read this submission. I believe that I have an appropriate level of expertise to confirm that it is of an acceptable scientific standard, however I have significant reservations, as outlined above.**

Author Response ( *Member of the F1000 Faculty* ) 23 Mar 2018

**Shitij Arora**, Montefiore Medical Center, Albert Einstein College of Medicine, USA

We thank you for the review and the excellent suggestions. Our response is included below

t describes an NF type-1 patient with MPNST with metastasis to the adrenal gland. The patients with NF type-1 have increased risk for pheochromocytoma. Likely the patient had undiagnosed pheochromocytoma (was the patient hypertensive?) and the patient developed metastasis to pheochromocytoma. So it describes more of cancer-to-cancer metastasis than collision tumor. Add more references with respect to cancer-to-cancer metastasis. Collision tumor is defined as two distinct tumors developing in juxtaposition to one another without areas of intermingling. In the current case, as in Figure 2, there is an intermingling of both components- so again it is not a collision tumor. The title needs to be changed and make it apt.

Response - term collision tumor is removed.

Spelling errors like prognoses (mentioned in conclusion). There is nothing called epithelial sarcoma, the correct terminology is epithelioid sarcoma. MPNST stands for malignant peripheral nerve sheath tumor so no need for peripheral MPNST (mentioned in the first line of the last paragraph of discussion). Please check for grammatical errors as well.

Response - corrected

Abstract- talks about guidelines for staging peripheral nerve sheath tumors, which sounds like it was a benign tumor. So use MPNST instead of just peripheral nerve sheath tumor. Abstract and discussion mention isolated adrenal metastasis, which is not true; she had both bone and adrenal metastasis. There is mention that- "She underwent primary and adrenal metastasis resection."



consider revising it to primary tumor resection and adrenalectomy for metastasis.

Response - corrected

Expand on physical exam of thigh mass- size, tenderness, consistency etc. Elaborate on findings of MRI with details of imaging findings of adrenal metastasis.

Response- corrected

Expand on gross findings of thigh mass and adrenal nodules- eg. size, color, infiltrative or well-circumscribed etc. Did both the adrenal nodules have similar histological findings? Were any immunostains done to confirm pheochromocytoma component?

Response- immunostains are included in the findings described

dd limitations of the study, the major limitation being small sample size.

Response- We intend to publish this as a case report

**Competing Interests:** None

Referee Report 20 December 2017

doi:10.5256/f1000research.13693.r29129



**Ahmed Abu-zaid**

College of Graduate Health Sciences, University of Tennessee Health Science Center, Memphis, TN, USA

With interest, I read the article Shaines and Arora. Overall, the article reads very well, and should deserve acceptance following some minor/major changes to improve its quality and scientific soundness.

1. Title:

- You may want remove the phrase "case report".
- Also, please change to "an adrenal metastasis".

2. Abstract.

- Please expand the abstract.
- You may want to include a couple of sentences about definition of soft tissue sarcomas (STSs), incidence, biological behavior (with respect to abdominal/pelvis and distant metastasis) and percentage of MPNSTs.
- You may also want to precisely mention the names of guidelines and dates.
- All these recommended sentences above will highlight the importance of your case report.
- The abstract says the STS of thigh was resected although this is not mentioned in the "case report" section.
- Lastly, check if journal mandates a STRUCTURED format for the abstract section.

3. Introduction:

- It is recommended to add sentences that shed light on the most common sites of STSs and the

percentage of MPNSTs among all STSs.

— Mention the dates of guidelines.

#### 4. Case Report:

— Add details about physical examination.

— Add details about initial laboratory findings.

— Add CT scans of the thigh mass (to highlight its large size) and adrenal mass (to highlight the collision tumor).

— You add the MRI picture of the adrenal mass, too (or the CT scan).

— Please do mention of the patient received surgery for the STS of the thigh as it is not clearly mentioned in this section.

#### 5. Discussion:

— Since the two series presented in manuscript had contradictory conclusions, it is recommended (if available) to add additional data from one to two more series.

— For reference (9), please add specific details about MPNSTs (if available).

— Briefly mention how (why) MPNST are different from the myxoid liposarcoma, epithelial sarcoma, angiosarcoma etc in terms of the recommendation for CT A/P scanning.

— please provide citations for the following sentence "Factors known to be associated with the development of metastases are tumor grade, tumor size, tumor depth, and certain histopathologies".

5. "Based on our case and the literature, we also would suggest adding screening CT A/P for large (>5cm), deep tumors of any histology". How depth was assessed in your case report.

#### 6. Conclusion:

— Modify the conclusion so it will reflect the specific histopathological variant of MPNST (since it is not normally recommended by guidelines as opposed to the others).

#### 7. References:

— Good

#### 8. English:

— Minor English polishing.

**Is the background of the case's history and progression described in sufficient detail?**

Yes

**Are enough details provided of any physical examination and diagnostic tests, treatment given and outcomes?**

Yes

**Is sufficient discussion included of the importance of the findings and their relevance to future understanding of disease processes, diagnosis or treatment?**

Partly

**Is the case presented with sufficient detail to be useful for other practitioners?**

Partly

**Competing Interests:** No competing interests were disclosed.

**Referee Expertise:** Medical Oncology, Surgical Oncology

**I have read this submission. I believe that I have an appropriate level of expertise to confirm that it is of an acceptable scientific standard, however I have significant reservations, as outlined above.**

Author Response ( *Member of the F1000 Faculty* ) 23 Mar 2018

**Shitij Arora**, Montefiore Medical Center, Albert Einstein College of Medicine, USA

We thank the reviewer for their excellent suggestions. Our response is included below

Reviewers Response /1

Abstract. — Please expand the abstract. — You may want to include a couple of sentences about definition of soft tissue sarcomas (STSs), incidence, biological behavior (with respect to abdominal/pelvis and distant metastasis) and percentage of MPNSTs. — You may also want to precisely mention the names of guidelines and dates. — All these recommended sentences above will highlight the importance of your case report. — The abstract says the STS of thigh was resected although this is not mentioned in the "case report" section. — Lastly, check if journal mandates a STRUCTURED format for the abstract section.

Response- We included much of the above in an updated version of the introduction

Introduction: — It is recommended to add sentences that shed light on the most common sites of STSs and the percentage of MPNSTs among all STSs. — Mention the dates of guidelines.

Response -Updated

Case Report: — Add details about physical examination. — Add details about initial laboratory findings. — Add CT scans of the thigh mass (to highlight its large size) and adrenal mass (to highlight the collision tumor). — You add the MRI picture of the adrenal mass, too (or the CT scan). — Please do mention of the patient received surgery for the STS of the thigh as it is not clearly mentioned in this section.

Response- Updated much of this.

We have attached an image of the thigh mass with this response instead – please click [here](#) to see this.

Discussion: — Since the two series presented in manuscript had contradictory conclusions, it is recommended (if available) to add additional data from one to two more series. — For reference (9), please add specific details about MPNSTs (if available). — Briefly mention how (why) MPNST are different from the myxoid liposarcoma, epithelial sarcoma, angiosarcoma etc in terms of the recommendation for CT A/P scanning. — please provide citations for the following sentence "Factors known to be associated with the development of metastases are tumor grade, tumor size, tumor depth, and certain histopathologies". 5. "Based on our case and the literature, we also would suggest adding screening CT A/P for large (>5cm), deep tumors of any histology". How depth was assessed in your case report.

Response -Updated much of this

These are the only 2 case series we could find that address this issue of A/P imaging we removed “depth” from that last sentence as it really does appear that size if what matters

Conclusion: — Modify the conclusion so it will reflect the specific histopathological variant of MPNST (since it is not normally recommended by guidelines as opposed to the others).

Response- Wepurposely left this vague because this this was only one case of MPNST and there are so many variants of soft tissue sarcoma. I thought it would be more generalizable to state tumor size, in general, should be thought of as important when it comes to screening imaging since it is noted as a risk factor for all STS.

**Competing Interests:** None

The benefits of publishing with F1000Research:

- Your article is published within days, with no editorial bias
- You can publish traditional articles, null/negative results, case reports, data notes and more
- The peer review process is transparent and collaborative
- Your article is indexed in PubMed after passing peer review
- Dedicated customer support at every stage

For pre-submission enquiries, contact [research@f1000.com](mailto:research@f1000.com)

F1000Research