

Values of ^{99m}Tc -methoxyisobutylisonitrile imaging after first-time large-dose ^{131}I therapy in treating differentiated thyroid cancer

Xiaomei Pan
Dong Duan
Yuquan Zhu
Hua Pang
Lili Guan
Zhixiang Lv

Department of Nuclear Medicine, The First Affiliated Hospital of Chongqing Medical University, No 1 Youyi Road, Yuzhong District, Chongqing 400016, People's Republic of China

Objective: The aim of this study is to investigate the use of ^{99m}Tc -methoxyisobutylisonitrile (MIBI) imaging for evaluating the treatment response of differentiated thyroid cancer (DTC) after the first administration of a high dose of ^{131}I .

Methods: Patients with DTC who received ^{131}I therapy underwent ^{99m}Tc -MIBI imaging after successive increases in the therapeutic dose of ^{131}I , and the serum levels of thyroglobulin (Tg) were measured.

Results: A total of 191 patients were enrolled in the final analysis, including 65 metastases and/or thyroid remnant-positive patients (22 patients with metastases and 43 patients with thyroid remnants). The sensitivity of ^{99m}Tc -MIBI imaging for detecting positive cases and thyroid remnants was 56.9% and 39.5%, respectively, which was significantly lower than that of ^{131}I imaging (92.3% and 100%, respectively, $P < 0.01$ for both). The sensitivity of ^{99m}Tc -MIBI imaging for detecting metastases was 90.9%, which was slightly higher than that of ^{131}I imaging (77.3%, $P > 0.05$). The Tg levels in the positive group were significantly higher than that in the negative group ($P < 0.01$). In addition, the Tg levels in the ^{99m}Tc -MIBI/ ^{131}I group were significantly higher than that in the ^{131}I / ^{99m}Tc -MIBI group ($P < 0.05$).

Conclusion: After the first ^{131}I therapy, although ^{99m}Tc -MIBI imaging was able to detect the existence of metastatic lesions in patients with DTC better, its assessment for the removal efficiency of thyroid remnants was unsatisfactory. The results of ^{99m}Tc -MIBI imaging showed good correlations with the Tg level.

Keywords: differentiated thyroid cancer, ^{99m}Tc -MIBI imaging, therapeutic dose ^{131}I imaging, thyroglobulin

Introduction

Thyroid cancer (TC), the most common malignant tumor among endocrine and head-neck tumors, with an increasing incidence in recent years, accounts for ~3% of all malignancies.¹ Differentiated thyroid cancer (DTC) accounts for >90% of all TC cases. Currently, the routine treatment for DTC is surgery plus ^{131}I therapy plus thyroid-stimulating hormone (TSH) suppression therapy.^{2,3} Total or near-total thyroidectomy is the most commonly used surgical procedure. ^{131}I therapy includes the ablation of thyroid remnants and local/distant metastases with the postoperative use of different activities of ^{131}I . The suppression of TSH using supraphysiologic doses of levothyroxine to supplement thyroid hormone and to inhibit the growth of DTC cells is an effort to decrease the risk of recurrence.

After the first (postoperative) application of ^{131}I therapy, the patient should be evaluated for the presence of remnants or metastases, which is important for

Correspondence: Dong Duan
Department of Nuclear Medicine, The First Affiliated Hospital of Chongqing Medical University, No 1 Youyi Road, Yuzhong District, Chongqing 400016, People's Republic of China
Tel +86 131 0128 2893
Email duandong26@163.com

determining the necessity of repeated ^{131}I therapy.⁴ Serum thyroglobulin (Tg) level is the most sensitive and specific indicator for monitoring DTC recurrence or metastases, but it cannot be used to locate the lesions or distinguish remnants from metastases; therefore, combining with other imaging methods is needed for evaluation. Ultrasonography and computed tomography are commonly used, but they have certain deficiencies for detecting functional TC recurrent or metastatic lesions, especially for the diagnosis of some minor metastatic lesions. ^{131}I imaging with diagnostic dose might not be able to detect small metastases and might induce a stunning effect (a reduction in the uptake of ^{131}I therapy dose induced by a pretreatment diagnostic activity) of remnants/metastases, which might influence the efficacy of subsequent ^{131}I therapy.^{5–8} $^{99\text{m}}\text{TcO}_4$ -imaging⁹ can provide information about the clearance of thyroid remnants, but it is not a tumor-specific imaging; therefore, it cannot be used to evaluate the clearance of TC metastases. Although ^{18}F -fluoro-2-deoxy-D-glucose positron emission tomography (^{18}F FDG-PET) imaging can provide information about remnants and metastases with a high metabolism, it is too expensive for wider use in clinical application; besides, partial metastatic lesions (especially lymph node metastases) show no high intake of fluorodeoxyglucose.¹⁰ $^{99\text{m}}\text{Tc}$ -methoxyisobutylisonitrile (MIBI) is a nonspecific tumor-philic imaging agent; it has been used for diagnosing and evaluating the efficacy of treatments for lung cancer, breast cancer, bone cancer, gliomas, and other malignant tumors.^{11–16} The present study compared the results of $^{99\text{m}}\text{Tc}$ -MIBI imaging and therapeutic-dose ^{131}I imaging, aiming to assess the use of $^{99\text{m}}\text{Tc}$ -MIBI imaging in patients with DTC after surgery and the first (postoperative) application of ^{131}I therapy.

Materials and methods

Clinical data

A total of 192 patients with DTC (38 men and 154 women; aged 7–78 years [mean \pm SD: 43.2 \pm 8.6 years]) who underwent total or near-total thyroidectomy for pathologically diagnosed DTC (including 171 cases of papillary carcinoma and 21 cases of follicular carcinoma) and who were treated in our hospital between February 2010 and March 2014 were enrolled. All patients underwent $^{99\text{m}}\text{Tc}$ -MIBI imaging and high-dose ^{131}I imaging 6 months after the first (postoperative) application of ^{131}I therapy (the mean dose was 113.5 \pm 20.8 mCi) and stopped receiving thyroxin preparation as a medication, 4 weeks before the imaging. This study was conducted in accordance with the Declaration of Helsinki. This study was conducted with the approval from the Ethics Committee of the First Affiliated Hospital of Chongqing

Medical University. Written informed consent was obtained from all participants.

Laboratory tests

By using the chemiluminescence method, the serum Tg level (reference value, <35 ng/mL) was measured in all patients, both after they stopped the medication of thyroxin preparation 4 weeks prior to imaging and just before the imaging. The radioimmunoassay method was used to detect the levels of TSH (reference range, 0.3–5.0 mIU/L) and Tg antibody (TgAb, reference value, <30%).

$^{99\text{m}}\text{Tc}$ -MIBI imaging

Patients were intravenously injected with 740–925 MBq $^{99\text{m}}\text{Tc}$ -MIBI (Beijing Xinke Co., Beijing, People's Republic of China), and then, neck and chest as well as systemic planar images were obtained after 90 minutes. A single-photon emission computed tomography (SPECT)/computed tomography (CT) instrument (Symbia T2; Siemens, Munich, Germany) was used, which was equipped with a parallel low-energy high-resolution collimator with an energy peak of 140 keV and a window width of 20%. The magnification fold when performing neck and chest scanning was 1.5, with a matrix of 256 \times 256 pixels and an acquisition count of 500 K. The magnification fold when performing systemic scanning was 1.0, with a matrix of 256 \times 1,024 pixels and scanning speed of 15 cm/min.

^{131}I imaging

Patients were orally administered a mean dose of 5,550–8,140 MBq (150–220 mCi) ^{131}I (provided by Chengdu Gaotong Isotope Co., Ltd.) on the second day after $^{99\text{m}}\text{Tc}$ -MIBI imaging; they underwent neck–chest scanning and systemic scanning on the fourth day after ^{131}I administration (namely, high-dose ^{131}I imaging). A SPECT/CT instrument (Symbia T2) was used, which was equipped with a parallel low-energy high-resolution collimator with a matrix of 256 \times 1,024 pixels, an energy peak of 364 keV, and a window width of 20%; the magnification fold was 1, with a scanning speed of 15 cm/min and acquisition count of 100–150 K.

Image analysis

The images were evaluated independently by two physicians with SPECT/CT diagnostic experience. The images with consistent evaluation results were then included in the final analysis. Positive cases were defined as the presence of an abnormal radioactive uptake outside the thyroid gland bed area or the thyroid gland – as found on either of the above-mentioned imaging methods – and negative cases were

defined as no imaging agent uptake outside the thyroid gland bed area and the thyroid gland.

Statistical analysis

SPSS 13.0 software (SPSS Inc., Chicago, IL, USA) was used for the statistical analysis. The data were assessed using the chi-square test. The measurement data are expressed as $\bar{x} \pm s$. The intergroup data were compared with an independent samples *t*-test, with $P < 0.05$ considered statistically significant.

Results

Imaging results of all patients

The imaging results of a total of 191 patients with DTC were included in the study (the images of one patient were excluded owing to considerable differences between the evaluation results of the two physicians). Among them, 126 (66.0%) patients were negative on both imaging methods, 32 (16.8%) patients were positive on both imaging methods, 28 (14.7%) patients were high-dose ^{131}I whole body scan (Rx-WBS) positive but $^{99\text{m}}\text{Tc}$ -MIBI negative, and five (2.6%) patients were $^{99\text{m}}\text{Tc}$ -MIBI positive

but Rx-WBS negative. The imaging results of some patients are shown in Figures 1–4. A total of 65 patients (34.0%) were found to be positive, including 37 patients found by $^{99\text{m}}\text{Tc}$ -MIBI imaging, with a sensitivity, specificity, and accuracy of 56.9%, 100%, and 85.3%, respectively; while 60 patients were found by Rx-WBS, with a sensitivity, specificity, and accuracy of 92.3%, 100%, and 97.4%, respectively. The sensitivity of $^{99\text{m}}\text{Tc}$ -MIBI imaging in finding positive cases was significantly lower than that of Rx-WBS ($\chi^2=14.7$, $P < 0.01$) (Table 1).

Imaging results of $^{99\text{m}}\text{Tc}$ -MIBI and Rx-WBS toward residual thyroid tissues and metastases

Among the 65 positive patients, 43 patients exhibited residual thyroid tissues; $^{99\text{m}}\text{Tc}$ -MIBI imaging only detected 17 cases (39.5%) while Rx-WBS detected all 43 cases (100%). Accordingly, the sensitivity of $^{99\text{m}}\text{Tc}$ -MIBI imaging for detecting residual thyroid tissues was significantly lower than that of Rx-WBS ($\chi^2=24.0$, $P < 0.01$). Among the 22 patients with DTC metastases, $^{99\text{m}}\text{Tc}$ -MIBI imaging

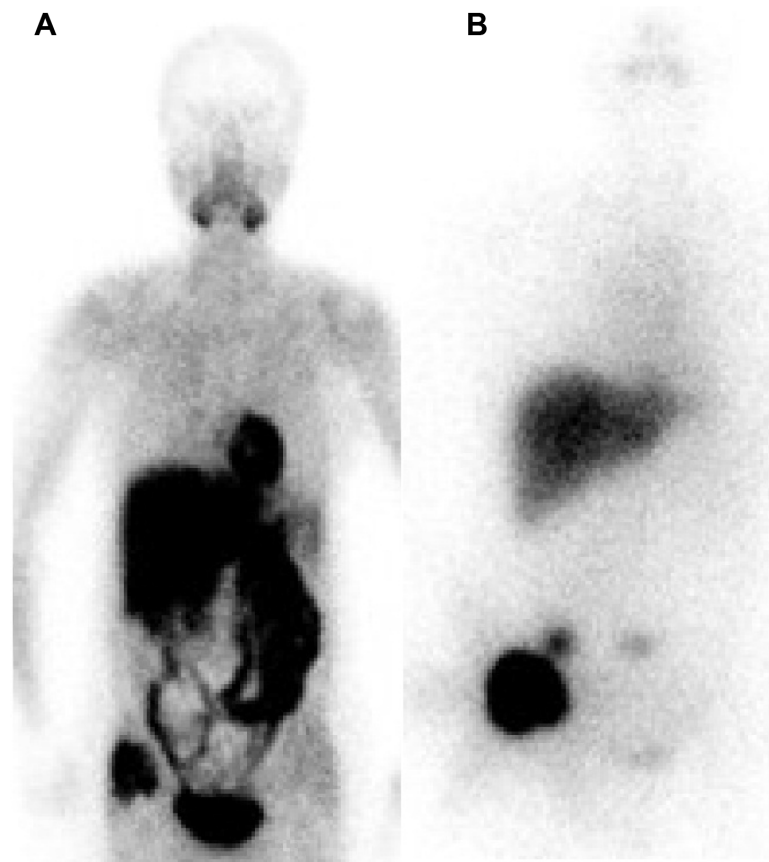


Figure 1 Imaging results from a 61-year-old female patient with FTC who felt right iliacal pain.

Notes: Right iliacal tissue has an abnormal uptake of (A) $^{99\text{m}}\text{Tc}$ -MIBI on $^{99\text{m}}\text{Tc}$ -MIBI imaging, and the liver, spleen, intestinal tract, heart, and bladder tissue have significant physiological uptake and (B) ^{131}I on Rx-WBS imaging, showing the liver also has more ^{131}I uptake, and hence, we cannot exclude that this patient has liver metastases.

Abbreviations: FTC, follicular thyroid carcinoma; MIBI, methoxyisobutylisonitrile; Rx-WBS, high-dose ^{131}I whole body scan.

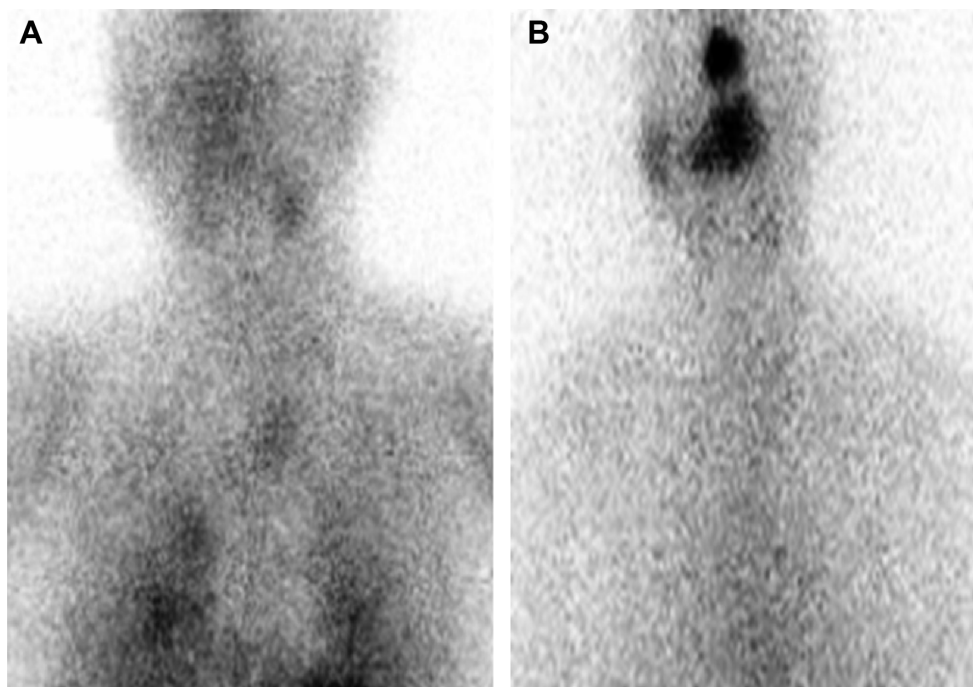


Figure 2 Imaging results from a 78-year-old male patient with PTC.

Notes: Neck and both lungs have (A) an abnormal uptake of ^{99m}Tc -MIBI on ^{99m}Tc -MIBI imaging and (B) no abnormal uptake of ^{131}I on ^{131}I imaging.

Abbreviations: PTC, papillary thyroid carcinoma; MIBI, methoxyisobutylisonitrile.

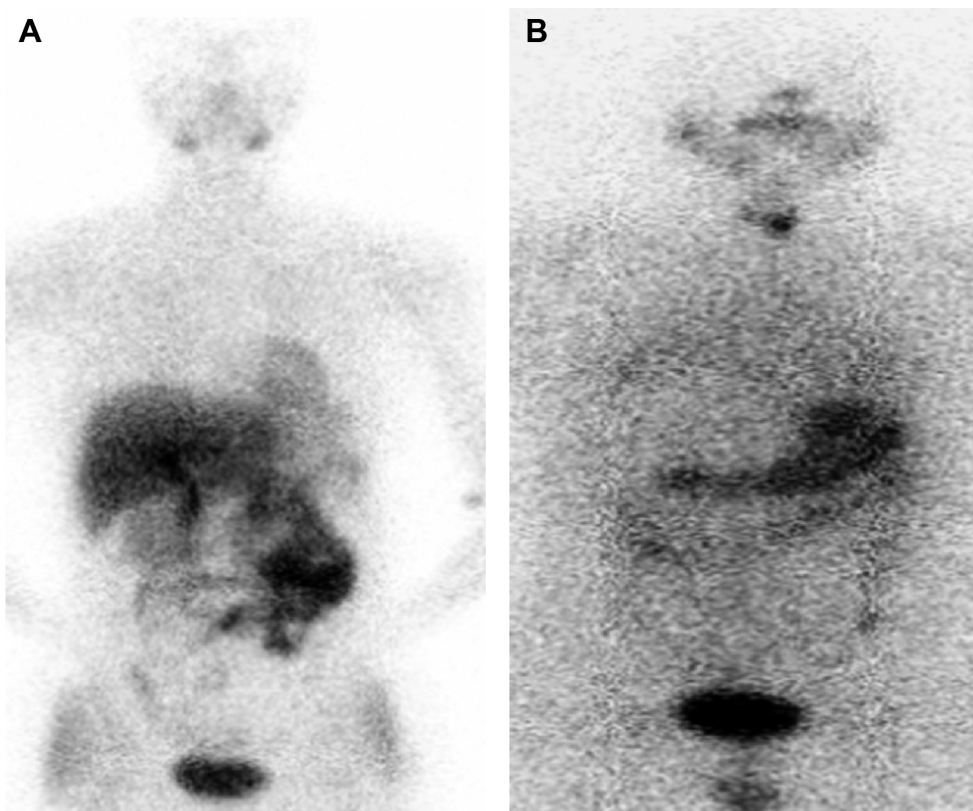


Figure 3 Imaging results from a 48-year-old female patient with PTC.

Notes: (A) Neck and whole body have no abnormal uptake of ^{99m}Tc -MIBI on ^{99m}Tc -MIBI imaging and (B) neck tissue had an abnormal uptake of ^{131}I on Rx-WBS imaging, considered as a normal residual thyroid tissue.

Abbreviations: PTC, papillary thyroid carcinoma; MIBI, methoxyisobutylisonitrile; Rx-WBS, high-dose ^{131}I whole body scan.

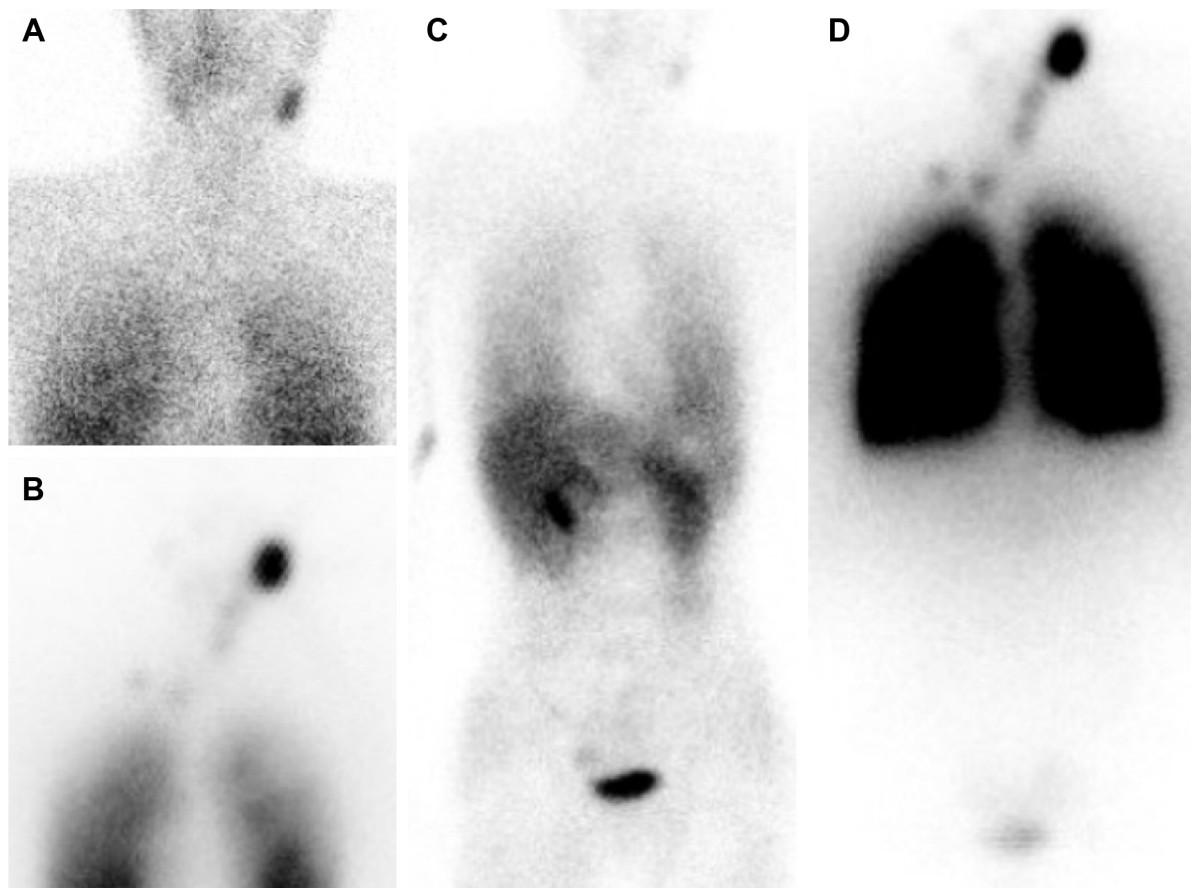


Figure 4 Imaging results from a 23-year-old male patient with PTC.

Notes: Left neck and both lung tissues have an abnormal uptake of ^{99m}Tc -MIBI on ^{99m}Tc -MIBI neck–chest (A) and whole body scan (C) imaging; left neck and both lung tissues had an abnormal uptake of ^{131}I on ^{131}I neck–chest (B) and whole body scan (D) imaging, matching with ^{99m}Tc -MIBI imaging results.

Abbreviations: PTC, papillary thyroid carcinoma; MIBI, methoxyisobutylisonitrile.

detected 20 cases (90.9%), while Rx-WBS detected 17 cases (77.3%). The sensitivity of ^{99m}Tc -MIBI imaging for detecting TC metastases was higher than that of Rx-WBS, although the difference was not significant ($\chi^2=0.57$, $P>0.05$). On further analysis, 33 positive patients showed discrepant results between the two imaging methods (only positive on ^{99m}Tc -MIBI imaging or on Rx-WBS imaging). A total of 28 cases were positive on Rx-WBS but negative on ^{99m}Tc -MIBI, among whom 26 cases exhibited radioactive ^{131}I uptake in the thyroid gland bed area and two cases exhibited an abnormal

^{131}I uptake outside the gland. Five cases were positive on ^{99m}Tc -MIBI but negative on Rx-WBS, among whom three cases exhibited ^{99m}Tc -MIBI uptake outside the thyroid gland and two cases exhibited ^{99m}Tc -MIBI uptake in the thyroid gland bed area (Table 2).

Results of serum Tg in each group

According to imaging results, all patients were classified into four groups: group I (^{99m}Tc -MIBI negative and ^{131}I negative), group II (^{99m}Tc -MIBI positive and ^{131}I positive), group III (^{99m}Tc -MIBI negative and ^{131}I positive), and group IV (^{99m}Tc -MIBI positive and ^{131}I negative). The serum Tg levels of the positive groups (namely, groups II, III, and IV) were significantly higher than the negative group (group I), and those of the ^{99m}Tc -MIBI-positive group (group IV) was significantly higher than the ^{131}I -positive group (group III). All the groups exhibited TSH levels >30 mIU/L and TgAb levels within the reference range, indicating that the Tg results (Table 3) were not influenced by TgAb.

Table I Imaging results of 191 patients

Imaging results	Cases	Percentage (%)
^{99m}Tc -MIBI/ ^{131}I -	126	66.0
^{99m}Tc -MIBI/ ^{131}I +	32	16.8
^{99m}Tc -MIBI/ ^{131}I +	28	14.7
^{99m}Tc -MIBI/ ^{131}I -	5	2.6
χ^2	14.6667	
P-value	0.0001**	

Note: ** $P<0.01$.

Abbreviation: MIBI, methoxyisobutylisonitrile.

Table 2 Imaging results of two imaging methods toward residual thyroid tissues and metastases

	Positive cases of ^{99m} Tc-MIBI imaging (sensitivity)	Positive cases of large-dose ¹³¹ I imaging (sensitivity)	χ^2	P-value
Residual thyroid tissues (n=43)	17 (39.5%)	43 (100%)	24.0385	0.00001**
Metastases (n=22)	20 (90.9%)	17 (77.3%)	0.57143	0.45*

Note: *P>0.05; **P<0.01.

Abbreviation: MIBI, methoxyisobutylisonitrile.

Discussion

The evaluation of whether postoperative TC metastases exist in patients with DTC should be preferably performed after the first (postoperative) application of ¹³¹I therapy (namely, ablation of the thyroid gland) because the existence of residual normal thyroid tissue might influence the ¹³¹I uptake of metastases, thus leading to false-negative results. The search for an imaging method that can not only sensitively detect TC metastases but also objectively assess whether residual thyroid tissues in the neck are completely resolved is important for the follow-up treatment of patients with DTC.

^{99m}Tc-MIBI is a nonspecific tumor-philic imaging agent with good physicochemical properties and a low radiation absorbance dose; therefore, it can be administered in high doses. In recent years, ^{99m}Tc-MIBI imaging has been widely used for the diagnosis of TC, breast cancer, lung cancer, bone tumors, and other malignancies.^{11–16} ^{99m}Tc-MIBI is absorbed into the cytoplasm by passive diffusion and then goes into mitochondria by active transportation. Tumor cells have a high number of mitochondria, active metabolism, and an increased local blood supply, and thus, they can absorb and temporarily retain more MIBI. This characteristic of fast uptake and relatively slow excretion is significantly different from the uptake and excretion pattern of benign cells. This is the reason why the tumor tissues can be easily identified.^{17–19} Accordingly, as the active ratio of the target tumor tissues to nontarget tissues is higher on delayed ^{99m}Tc-MIBI imaging, the delayed imaging is more obvious; therefore, this study only analyzed the results in the delayed phase.

The use of ^{99m}Tc-MIBI as a radioactive tracer has the following advantages in evaluating the existence of remnants

and metastases in patients with DTC after surgery and the first application of ¹³¹I therapy: ideal physical properties of ^{99m}Tc-MIBI led to less radiation damage in patients and are suitable for SPECT imaging; is easily prepared and has low production cost; does not get affected by the serum TSH level, no need for long-term withdrawal of levothyroxine before imaging and avoids hypothyroid symptoms; its uptake is related to the contents and metabolism of intracellular mitochondria (both functional and nonfunctional metastases can ingest ^{99m}Tc-MIBI, which could overcome the limitation of misdiagnosis of nonfunctional or dedifferentiated TC metastases of ¹³¹I imaging); and is without the “stunning” effect and does not affect the efficacy of subsequent ¹³¹I therapy.

As the most common metastatic areas of TC are the neck and chest, our department normally acquires neck and chest images (enlarged 1.5 times) and systemic images, which are helpful to discover the neck or lung metastases and provide information about iliac or other metastases. ^{99m}Tc-MIBI is excreted through the hepatobiliary system, which leads to obvious accumulation in the liver and intestines. Therefore, plain ^{99m}Tc-MIBI scanning has substantial limitations in assessing metastases in the spine, gastrointestinal tract, and other organs. Figure 1 shows that systemic ^{99m}Tc-MIBI imaging revealed lesions with an abnormal ^{99m}Tc-MIBI uptake in the right iliac region of a patient. ¹³¹I imaging also exhibited uptake in this site, so it might be considered an iliac metastasis; furthermore, as more ¹³¹I uptake was seen in the liver, we could not exclude the possibility that the lesion was accompanied by liver metastasis. While even ^{99m}Tc-MIBI imaging exhibits obvious aggregation in the liver and intestinal tract, it cannot be used to assess the possibility of liver metastasis.

Among the 65 positive cases found in this study, ¹³¹I imaging could detect 60 cases (92.3%) and ^{99m}Tc-MIBI imaging could detect 37 cases (56.9%). The positive rate on ^{99m}Tc-MIBI imaging was significantly lower than that on ¹³¹I imaging, while the combination of ^{99m}Tc-MIBI imaging with ¹³¹I imaging can increase the positive rate of diagnosis. A total of 43 patients were found to have residual thyroid tissues; the sensitivity of ¹³¹I imaging was 100% and that of

Table 3 Serum Tg levels in positive and negative groups

	Cases	Serum Tg (ng/L)
Group I (^{99m} Tc-MIBI ⁻ / ¹³¹ I ⁻)	126	2.5±1.7
Group II (^{99m} Tc-MIBI ⁺ / ¹³¹ I ⁺)	32	24.5±6.8 ^a
Group III (^{99m} Tc-MIBI ⁻ / ¹³¹ I ⁺)	28	18.9±5.6 ^b
Group IV (^{99m} Tc-MIBI ⁺ / ¹³¹ I ⁻)	5	32.8±11.8 ^{c,d}

Notes: ^aComparison between Groups II and I, $t=-20.7$, $P<0.01$; ^bcomparison between Groups III and I, $t=-18.5$, $P<0.01$; ^ccomparison between Groups IV and I, $t=-6.0$, $P<0.01$; and ^dcomparison between Groups IV and III, $t=-2.7$, $P<0.05$.

Abbreviations: Tg, thyroglobulin; MIBI, methoxyisobutylisonitrile.

^{99m}Tc -MIBI imaging was only 39.5%, which is significantly lower than that of ^{131}I imaging ($P < 0.01$). This difference might be explained owing to the following reasons: after surgery and the first application of ^{131}I therapy, residual normal thyroid tissues are rare, the number of mitochondria in the normal cells is lower, and surgical trauma affects the local blood supply, all of these reasons lead to no or reduced ^{99m}Tc -MIBI uptake. Therefore, the use of ^{99m}Tc -MIBI imaging in assessing the existence of cervical residual normal thyroid tissues is very limited, and it cannot be used on its own to assess the existence of residual thyroid tissues.

A study has shown that, although ^{99m}Tc -MIBI is a non-specific tracer for TC, it has a high sensitivity and specificity in the detection of functional and nonfunctional metastases.²⁰ Rubello et al²¹ found that even during thyroid hormone replacement suppression therapy, ^{99m}Tc -MIBI imaging shows high sensitivity (93.5%) in detecting cervical lymph node metastases (part of which had no ^{131}I intake), when combined with ultrasonography; the sensitivity was as high as 97.8%. Ronga et al²² found that ^{99m}Tc -MIBI had a high sensitivity in detecting mediastinal lymph node metastasis of TC, especially when the metastatic lesions were negative on ^{131}I imaging. In our study, 22 patients had TC metastases; among them, ^{99m}Tc -MIBI imaging detected 20 cases (15 of cervical and mediastinal lymph node, three of lung, one of iliac, and one of vertebral) with a sensitivity of 90.9%, consistent with the findings of Campenni et al,²³ while ^{131}I imaging only detected 17 cases with a sensitivity of 77.3%. The sensitivity of ^{131}I imaging was lower than that of MIBI imaging, but the difference was not significant ($P > 0.05$).

Coelho et al²⁴ reported that ~30% of the primary or metastatic lesions of patients with DTC gradually lost iodine uptake ability during or after ^{131}I treatment, probably owing to dedifferentiation. The study found that the uptake value of ^{99m}Tc -MIBI in tumor cells increases with the decrease of differentiation degree of DTC;^{25,26} poorly differentiated thyroid cancers (pDTCs) and dedifferentiated thyroid cancers (dDTCs) have higher metabolism compared to DTCs, thus enhancing ^{99m}Tc -MIBI retention in pDTC and dDTC cells and showing positive results on ^{99m}Tc -MIBI imaging, while because of losing iodine uptake ability, the patients show negative results on ^{131}I imaging. In this study, three patients with TC metastases were ^{99m}Tc -MIBI positive but ^{131}I negative (the result of one patient is shown in Figure 2). We thought that the possible reasons for this difference might be dedifferentiation or poor differentiation of TC metastases. It is a pity that not one of them had the pathological examination of the metastatic lesions; therefore, the final reason

is not clear. For these patients, the efficacy of routine ^{131}I therapy might be poor and other treatment options should be performed. Another two patients' metastatic lesions show a result of ^{131}I positive but ^{99m}Tc -MIBI negative, which might be due to the lower mitochondria content in tumor cells, but the exact reason is still not clear.

Tg is synthesized by thyroid follicular cells. The serum Tg level was a specific marker for monitoring residual tumor cells, recurrence, and metastasis of DTC and for assessing the efficacy of treatment. In patients who underwent total thyroidectomy and who had already been treated with ^{131}I ablation of the thyroid gland, the serum Tg levels should be below the reference line or undetectable; therefore, an increase in Tg might suggest a recurrence or metastasis of TC. In this study, the TgAb levels of all patients were within the reference range, indicating that antibodies did not interfere with the Tg results. The serum Tg level of the positive group was significantly higher than that of the negative group, indicating that the imaging results had good correlations with the Tg levels, consistent with previous reports.²³ We noted that the survival rate and the reliability of Tg as a tumor marker during the follow-up period were directly influenced by whether ^{131}I could completely clear patients' residual thyroid tissues.

In summary, after the first (postoperative) application of ^{131}I therapy, ^{99m}Tc -MIBI imaging could sensitively detect metastatic TC lesions in patients with DTC by not only having a high positive rate for cervical lymph node metastases but also finding distant metastases. The use of ^{99m}Tc -MIBI for detecting cervical residual thyroid tissues is limited; therefore, it cannot be used instead of ^{131}I imaging, but it can be used as one of the inspection methods for evaluating patients with DTC, thus providing important information about the need for subsequent ^{131}I therapy. ^{99m}Tc -MIBI imaging and ^{131}I imaging had good correlations with the serum Tg levels.

Disclosure

The authors report no conflicts of interest in this work.

References

1. Ward LS. Thyroid tumors: are we unveiling the puzzle? *Endocr Relat Cancer*. 2014;21(5):E7–E8.
2. American Thyroid Association (ATA) Guidelines Taskforce on Thyroid Nodules and Differentiated Thyroid Cancer, Cooper DS, Doherty GM, et al. Revised American Thyroid Association management guidelines for patients with thyroid nodules and differentiated thyroid cancer. *Thyroid*. 2009;19:1167–1214.
3. Tuttle RM, Haddad RI, Ball DW, et al. Thyroid carcinoma, version 2. 2014. *J Natl Compr Canc Netw*. 2014;12:1671–1680.
4. Lundh C, Lindencrona U, Postgård P, et al. Radiation-induced thyroid stunning: differential effects of (123)I, (131)I, (99m)Tc, and (211)At on iodide transport and NIS mRNA expression in cultured thyroid cells. *J Nucl Med*. 2009;50:1161–1167.

5. Flux GD, Haq M, Chittenden SJ, et al. A dose effect correlation for radioiodine ablation in differentiated thyroid cancer. *Eur J Nucl Med Mol Imaging*. 2010;37:270–275.
6. Mallick U, Harmer C, Yap B, et al. Ablation with low-dose radioiodine and thyrotropin alfa in thyroid cancer. *N Engl J Med*. 2012;366:1674–1685.
7. Etchebehere EC, Santos AO, Matos PS, et al. Is thyroid stunning clinically relevant? A retrospective analysis of 208 patients. *Arq Bras Endocrinol Metabol*. 2014;58:292–300.
8. McDougall IR, Iagaru A. Thyroid stunning: fact or fiction? *Semin Nucl Med*. 2011;41:105–112.
9. Kiratli PO, Kara PP, Ergün EL, et al. Metastatic insular thyroid carcinoma: visualized on Tc-99m pertechnetate, Tc-99m MDP and iodine-131 imaging; a review of the literature for other radionuclide agents. *Ann Nucl Med*. 2004;18:443–446.
10. Xu YH, Shen CT, Xue YL, et al. Iodine-131 SPET/CT and 18F-FDG PET/CT for the identification and localization of mediastinal lymph node metastases from differentiated thyroid carcinoma. *Hell J Nucl Med*. 2013;16:199–203.
11. Kanaev SV, Novikov SN, Krivorot'ko PV, et al. Combined use of 99mTc-MIBI imaging and ultrasonography (US) in the diagnosis of axillary lymphatic metastasis in patients with breast cancer. *Vopr Onkol*. 2013;59:52–58.
12. Nikoletic K, Lucic S, Peter A, et al. Lung 99mTc-MIBI imaging: impact on diagnosis of solitary pulmonary nodule. *Bosn J Basic Med Sci*. 2011;11:174–179.
13. Kanaev SV, Novikov SN, Beĭnusov DS, et al. Role of single-photon emission-computed tomography and x-ray computed tomography in diagnosing lymphatic metastases in patients with non-small cell lung cancer. *Vopr Onkol*. 2014;60:476–481.
14. Deltuva VP, Jurkienė N, Kulakienė I, et al. Introduction of novel semiquantitative evaluation of (99m)Tc-MIBI SPECT before and after treatment of glioma. *Medicina (Kaunas)*. 2012;48:15–21.
15. Spyridonidis TJ, Matsouka P, Symeonidis A, et al. (99m)Tc sestamibi as a prognostic factor of response to first-line therapy and outcome in patients with malignant lymphoma. *Clin Nucl Med*. 2013;38:847–854.
16. Riazi A, Kalantarhormozi M, Nabipour I, et al. Technetium-99m methoxyisobutylisonitrile imaging in the assessment of cold thyroid nodules: is it time to change the approach to the management of cold thyroid nodules? *Nucl Med Commun*. 2014;35:51–57.
17. Carvalho PA, Chiu ML, Kronauge JF, et al. Subcellular distribution and analysis of technetium-99m-MIBI in isolated perfused rat hearts. *J Nucl Med*. 1992;33:1516–1522.
18. Mankoff DA, Dunnwald LK, Gralow JR, et al. [Tc-99m]-sestamibi uptake and washout in locally advanced breast cancer are correlated with tumor blood flow. *Nucl Med Biol*. 2002;29:719–727.
19. Piwniaca-Worms D, Kronauge JF, Chiu ML. Up take and retention of hexakis (2-methoxy isobutyl isonitrile) technetium (I) in cultured chick myocardial dependence. *Circulation*. 1990;82:1826–1838.
20. Iwata M, Kasagi K, Misaki T, et al. Comparison of whole-body 18F-FDG PET, 99mTc-MIBI SPET, and post-therapeutic ¹³¹I-Na imaging in the detection of metastatic thyroid cancer. *Eur J Nucl Med Mol Imaging*. 2004;31:491–498.
21. Rubello D, Mazzarotto R, Casara D. The role of technetium-99m methoxyisobutylisonitrile imaging in the planning of therapy and follow-up of patients with differentiated thyroid carcinoma after surgery. *Eur J Nucl Med*. 2000;27:431–440.
22. Ronga G, Ventroni G, Montesano T, et al. Sensitivity of [99mTc] methoxyisobutylisonitrile scan in patients with metastatic differentiated thyroid cancer. *Q J Nucl Med Mol Imaging*. 2007;51:364–371.
23. Campenni A, Violi MA, Ruggeri RM, et al. Clinical usefulness of 99mTc-MIBI imaging in the postsurgical evaluation of patients with differentiated thyroid cancer. *Nucl Med Commun*. 2010;31:274–279.
24. Coelho SM, de Carvalho DP, Vaisman M. New perspectives on the treatment of differentiated thyroid cancer. *Arq Bras Endocrinol Metabol*. 2007;51:612–624.
25. Ugur O, Kostakglu L, Guler N, et al. Comparison of 99mTc(V)-DMSA, 201Tl and 99mTc-MIBI imaging in the follow-up of patients with medullary carcinoma of the thyroid. *Eur J Nucl Med*. 1996;23:1367–1371.
26. Rubello D, Saladini G, Carpi A, et al. Nuclear medicine imaging procedures in differentiated thyroid carcinoma patients with negative iodine scan. *Biomed Pharmacother*. 2000;54:337–344.

OncoTargets and Therapy

Publish your work in this journal

OncoTargets and Therapy is an international, peer-reviewed, open access journal focusing on the pathological basis of all cancers, potential targets for therapy and treatment protocols employed to improve the management of cancer patients. The journal also focuses on the impact of management programs and new therapeutic agents and protocols on

Submit your manuscript here: <http://www.dovepress.com/oncotargets-and-therapy-journal>

patient perspectives such as quality of life, adherence and satisfaction. The manuscript management system is completely online and includes a very quick and fair peer-review system, which is all easy to use. Visit <http://www.dovepress.com/testimonials.php> to read real quotes from published authors.

Dovepress