


The aorto-left ventricular tunnel from a fetal perspective: Original case series and literature review

Amber E. L. van Nisselrooij¹  | Anita J. Moon-Grady² | Annette Wacker-Gussmann³ | Viktor Tomek⁴ | Ivan Malčić⁵ | Agnieszka Grzyb^{6,7} | Anna Pavlova⁸ | Kalliopi Kazamia⁹ | Varsha Thakur¹⁰ | Elena Sinkovskaya¹¹ | A. Derk Jan ten Harkel¹ | Monique C. Haak¹

¹Department of Fetal Medicine and Obstetrics, Leiden University Medical Center, Leiden, The Netherlands

²Division of Pediatric Cardiology, Department of Pediatrics, University of California, San Francisco, California, USA

³Department of Pediatric Cardiology and Congenital Heart Disease, German Heart Center Munich, Munich, Germany

⁴Children's Heart Center Prague, University Hospital Motol, Prague, Czech Republic

⁵Department of Child's Cardiology, Zagreb University Hospital, Zagreb, Croatia

⁶Department of Perinatal Cardiology and Congenital Anomalies, Centre of Postgraduate Medical Education, Warsaw, Poland

⁷Department of Cardiology, The Children's Memorial Health Institute, Warsaw, Poland

⁸Department of Cardiology, Ukrainian Children's Cardiac Centre, Kyiv, Ukraine

⁹Children's Heart Centre Stockholm-Uppsala, Karolinska University Hospital, Stockholm, Sweden

¹⁰Division of Cardiology, Labatt Family Heart Centre, The Hospital for Sick Children, Toronto, Ontario, Canada

¹¹Department of Obstetrics and Gynecology, Eastern Virginia Medical School, Norfolk, Virginia, USA

Correspondence

Amber E. L. van Nisselrooij, Department of Fetal Medicine and Obstetrics, Leiden University Medical Centre, K6-35 Albinusdreef 2, 2333 ZA, Leiden, The Netherlands.
Email: a.e.l.nisselrooij@lumc.nl

Abstract

Introduction: Aorto-left ventricular tunnel (ALVT) accounts for <0.1% of congenital heart defects. Evidence on the prognosis from a fetal perspective is limited. With this retrospective international case series, we provide information on the outcome of fetuses with ALVT.

Methods: All members of the Association for European Pediatric and Congenital Cardiology's (AEPC) fetal working group and fetal medicine units worldwide were invited for participation. We observed antenatal parameters, neonatal outcome and postnatal follow-up. Additionally, a systematic search of the literature was performed.

Results: Twenty fetuses with ALVT were identified in 10 participating centers (2001–2019). Fetal echocardiographic characteristics of ALVT included an increased cardiac-thorax ratio (95%), left ventricular end-diastolic diameter (90%) and a dysplastic aortic valve (90%). Extracardiac malformations were rare (5%). Eight fetuses died at a median gestational age (GA) of 21 + 6 weeks (range, 19–24); all showed signs of hydrops prior to 24 weeks or at autopsy. All others (60%, 12/2) were live-born (median GA 38 + 4, range 37–40), underwent surgery and were alive at last follow up (median 3.2 years, range 0.1–17). The literature reported 22 ALVT fetuses with similar outcome.

Conclusions: In the absence of fetal hydrops, ALVT carries a good prognosis. Fetuses who survive to 24 weeks without hydrops are likely to have a good outcome.

Key points

What's already known about this topic?

- Aorto-left ventricular tunnel (ALVT) is an extremely rare diagnosis that may cause congenital heart failure and fetal hydrops, leading to fetal or neonatal death.
- A few case reports show that after corrective surgery in the neonatal period, cases with ALVT tend to have a good prognosis.

This is an open access article under the terms of the Creative Commons Attribution-NonCommercial License, which permits use, distribution and reproduction in any medium, provided the original work is properly cited and is not used for commercial purposes.

© 2022 The Authors. Prenatal Diagnosis published by John Wiley & Sons Ltd.

What does this study add?

- This is the first study that evaluates prenatal characteristics, prognostic parameters and outcome following a prenatal diagnosis of ALVT in a cohort of cases worldwide, including a systematic review of the literature as well.
- In the absence of fetal hydrops, ALVT carries a good prognosis. Fetuses who survive to 24 weeks without hydrops are likely to have a good outcome.

1 | INTRODUCTION

Although the exact incidence of an aorto-left ventricular tunnel (ALVT) is unknown, it is estimated between 0.001% and 0.1% of all congenital heart defects.^{1,2} This defect is characterized by an abnormal connection between the ascending aorta and left ventricle that bypasses the aortic valve (AoV). This 'tunnel' provides a site for diastolic run-off from ascending aorta to the left ventricle, similar to significant aortic regurgitation, which may cause left ventricular (LV) dysfunction and congestive heart failure (CHF) as a result of the LV volume overload.¹

Over the past 20 years, the introduction of an accessible and well-organized prenatal screening programs has considerably improved prenatal detection rates of CHDs in general from 23% to 59.5%,^{3,4} with a pooled estimate of 45.1% for all isolated CHDs in unselected populations.⁵ This development has likely improved the prenatal detection rate of ALVTs as well. Especially the most severely affected cases will be referred to fetal cardiology units, because of the enlarged left ventricle with an abnormal appearing LV outflow tract. Due to the rarity of this heart defect, correctly diagnosing the cause of these ultrasonographic features remains a challenge, as well as estimating the risk of intrauterine decompensation following a correct diagnosis.

The few case reports on fetal ALVT focus on the characteristics of the diagnosis rather than outcomes beyond surgery.^{6,7} Conversely, postnatal studies focus on the prognosis of ALVT following a diagnosis in the neonatal period or in childhood.⁸⁻¹¹ As the age at diagnosis is related to the severity of heart defects in general, it can be expected that the prognosis of antenatal cases is worse, compared to ALVT cases detected in early infancy.¹² On the other hand, a prenatal diagnosis of ALVT might improve the prognosis, if cases benefit from timely intervention to mitigate deterioration after birth.¹³

Severe paravalvular regurgitation and signs of LV failure are critical conditions in utero and may potentially be important predictors of fetal death (FD) or neonatal death shortly after birth in ALVT cases.¹² However, the onset, severity and progression of CHF can vary significantly between patients.¹ To enable proper prenatal counseling for this condition, studies that describe the natural history and prenatal predictors at presentation in relation to outcome, are essential. With this study we aimed to gather up-to-date information on the outcome of a relatively large cohort of prenatally diagnosed ALVT cases worldwide. In addition, we systematically reviewed the literature for risk factors of intrauterine demise and neonatal outcome in fetuses with ALVT.

2 | METHODS

We invited all members of the Association for European Pediatric and Congenital Cardiology's (AEPC) Fetal Cardiology Working Group and other fetal medicine units worldwide to participate in this retrospective multi-centre case series. Electronic databases or fetal registries were searched for patients with a prenatal diagnosis of ALVT. ALVT was defined as the presence of paravalvular aortic-left ventricular regurgitation that was visible on prenatal ultrasound and confirmation of the diagnosis on postnatal echocardiography amongst those that were liveborn. The Medical Ethics Committee of the Leiden University Medical Centre approved this study.

Participating centers reviewed the patient charts and databases. Prenatal characteristics and course of disease after diagnosis were recorded using a pre-defined case record form (CRF). This CRF included the following antenatal parameters: gestational age (GA) at diagnosis, LV function (fractional shortening [FS] or ejection fraction [EF]) and cardiac biometry at diagnosis, Doppler flow velocimetry waveforms (umbilical artery [UA], middle cerebral artery [MCA], umbilical vein [UV] and ductus venosus [DV]), signs of fetal hydrops, cardiovascular profile score (CVPS), the presence of significant additional (extra-)cardiac malformations, the use of transplacental pharmacological treatment and pregnancy outcome. We supplemented an illustration indicating how the cardiothoracic ratio by circumference (CTR),^{14,15} LV end-diastolic diameter (LVEDD),¹⁶ AoV annulus,¹⁶ ascending aorta¹⁶ and Doppler measurements¹⁷⁻¹⁹ should be measured to minimize measurement error (Supporting Information 1). The LV myocardial performance index (MPI), with a reported normal range from 0.35 ± 0.03 to 0.40 ± 0.05 with advancing gestation,²⁰⁻²² was calculated as reported by Tei et al.²³ The formula by Huhta et al.²⁴ was used to calculate the CVPS. The fetal heart was considered enlarged (cardiomegaly), if the CTR was greater than 0.5,¹⁵ by measurement or recorded as such at time of examination. The left ventricle, AoV annulus or ascending aorta was reported to be enlarged, if the specific measurement did not fall within the normal range (two standard deviations above the mean for its GA).¹⁶ Fetal LV function was defined abnormal, based on the normal range for left ventricular fractional shortening (LV-FS) or EF for its respective GA.²⁵ Fetal hydrops was defined as the presence of at least two symptoms, including ascites, pleural effusion, pericardial effusion, skin edema or polyhydramnios.

In addition, we recorded interventions to prevent fetal demise (including premature delivery), the occurrence of FD, GA at birth, birth weight, Apgar scores at 1, 5 and 10 min and neonatal intensive care unit admission. We furthermore collected data on postnatal

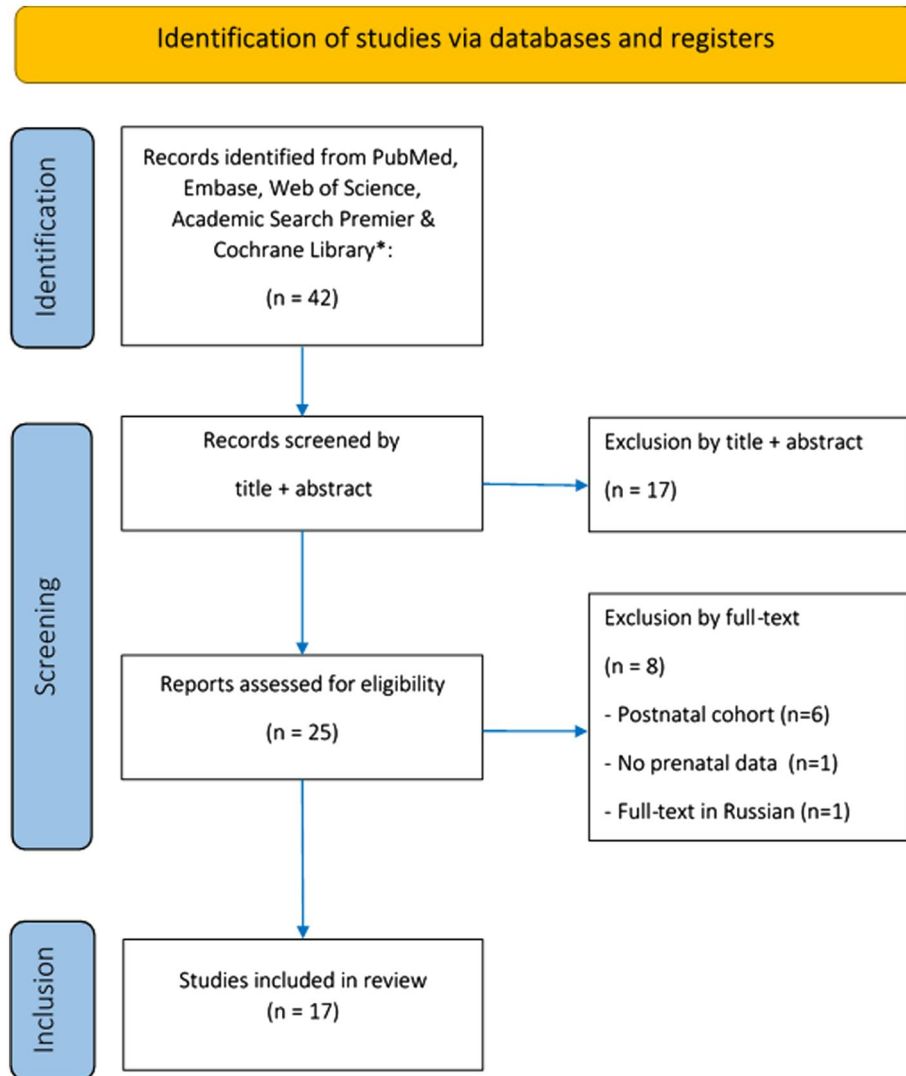


FIGURE 1 Identification of eligible studies in the literature, according to the Preferred Reporting Items for Systematic Reviews and Meta-Analyses (PRISMA) guidelines [Colour figure can be viewed at wileyonlinelibrary.com]

status: postnatal cardiac measurements, age at (corrective) surgery, site of ALVT closure, presence of a residual shunt, surgical complications, postoperative cardiac function and hospital stay, morbidity, mortality and age at last follow-up visit.

The development of fetal hydrops was chosen as our primary outcome, because a considerable number of reported fetuses with ALVT demise before a viable age is reached,^{2,26} whereas those that do make it to term generally have a good postoperative prognosis.^{6,7,27-33} To evaluate potential prognostic factors, we assessed the association between the prenatal characteristics of ALVT at diagnosis and the risk of demise, as well as postnatal outcome for those that survived until birth. Although this is the first study that describes a relatively large series of fetuses with this rare diagnosis, these numbers remain small for extensive statistical analysis. Descriptive statistics, including the median \pm range and proportions, were therefore used to report on prenatal characteristics, postnatal outcome and potential associations.

2.1 | Literature review

We systematically searched the electronic PubMed, Embase, Web of Science, Cochrane Library and Emcare databases from database inception to December 2, 2021, using search terms related to “aorto-left ventricular tunnel” and “prenatal diagnosis”, to identify reported cases with a prenatal diagnosis of ALVT in the literature (Supporting Information 2). Research results are reported in agreement with Preferred Reporting Items for Systematic Reviews and Meta-Analyses guidelines. Screening for relevant articles by title and abstract was performed by one reviewer (A. van Nissselrooij). If relevant, full-text was retrieved and selected articles were cross-referenced (Figure 1). The following data were collected from the included articles: year of publication, first author, time of diagnosis, cardiac features at prenatal diagnosis, presence of fetal hydrops, GA at birth, (age at) surgery and follow-up.

3 | RESULTS

3.1 | Prenatal diagnosis

Fifty-six percent of the approached centers (10/18) were able to contribute cases to this study. We included 20 cases with a prenatal diagnosis of ALVT from 10 fetal cardiology units worldwide over a period of 20 years (2000–2019), that had not been previously reported in the literature. Prenatal diagnoses were made in the second trimester in 75% (15/20) of cases with a median GA at diagnosis of 21 + 2 (range: 14 + 4 to 38 + 1). The diagnosis of ALVT had been confirmed on autopsy (88%, 6/7 fetal demised cases) or postnatal transthoracic echocardiography (all liveborn cases).

Characteristics of the patients with ALVT on fetal echocardiography involved an increased CTR in 95% (19/20), LV dilatation (90%,

18/20) and increased diameter of the ascending aorta (100%, 20/20) (Figure 2). The majority of cases presented with LV dysfunction (70%, 14/20) and a dysplastic AoV (90%, 18/20). Abnormal mitral valve (dysplasia/accessory tissue) was encountered in 10% (2/20). Significant extracardiac malformations were found in only one case, in which a 3p14.1 microdeletion was diagnosed (Table 1).

3.2 | Outcome

Forty percent (8/20) of cases showed signs of fetal hydrops, including skin edema, ascites and pleural or pericardial effusion at diagnosis or autopsy. The pregnancy was terminated on request of the parents before 24 weeks of gestation in 20% (4/20) of cases and spontaneous FD occurred in 3 cases (15%; 3/20), all of whom showed hydrops at

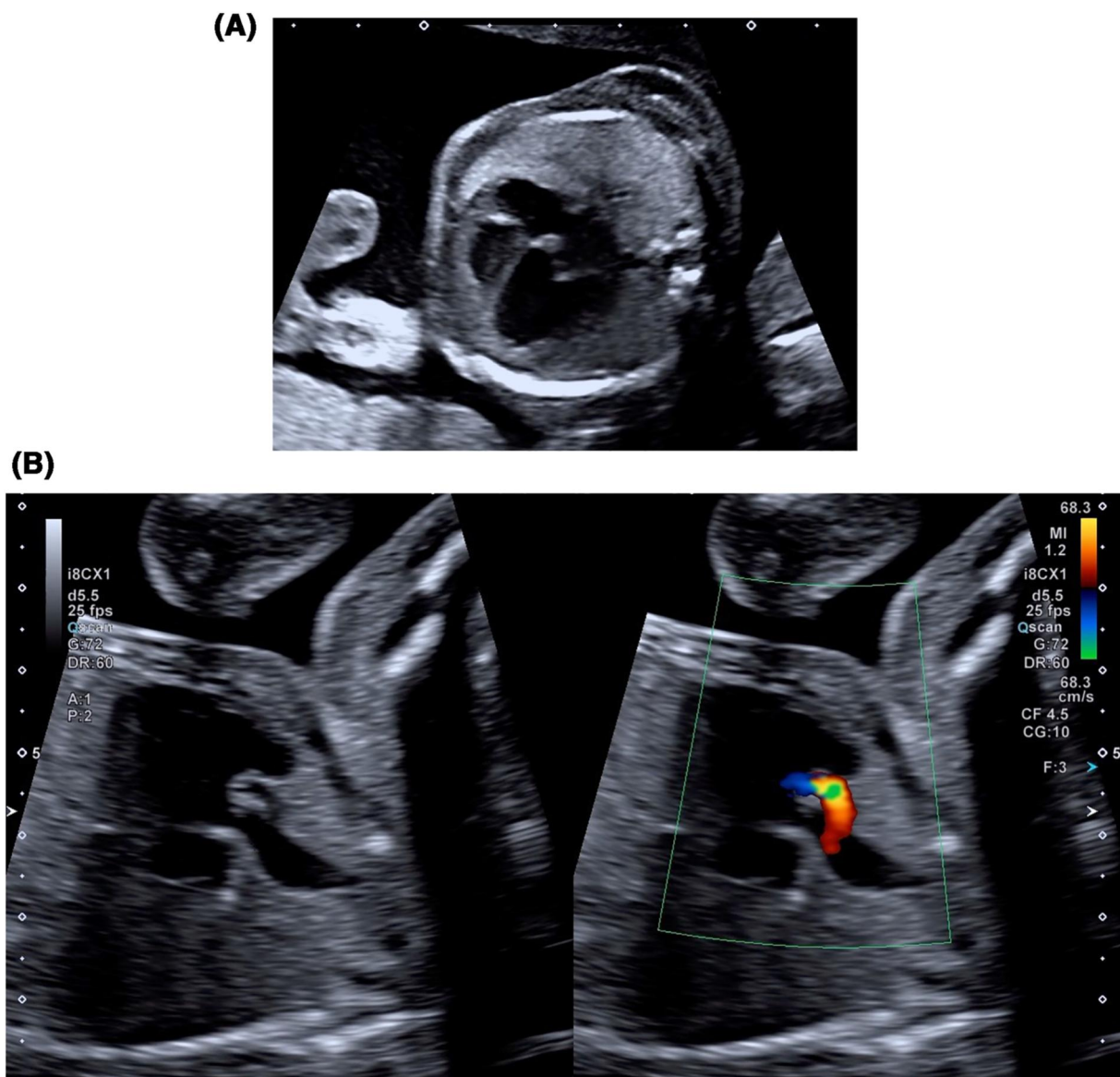


FIGURE 2 (A) Four chamber view clearly showing cardiomegaly with left ventricular (LV) dilatation, (B) LV outflow tract view in diastole. The flow through the tunnel that bypasses the aortic valve (AoV) is clearly visible [Colour figure can be viewed at [wileyonlinelibrary.com](https://onlinelibrary.wiley.com)]

TABLE 1 Prenatal characteristics at diagnosis

Number of cases		20	
GA at diagnosis	Median (weeks + days)	21 + 2	[14 + 4–38 + 1]
Number diagnosed in second trimester		16	(80.0%)
Cardiac features at first presentation			
Cardiomegaly (CTR > 0.5) ¹⁵		19	(95.0%)
CTR		59%	[43%–81%]
LVEDD ¹⁶	Enlarged	18	(90.0%)
LV aspect	Hypertrophic	11	(55.0%)
LV function	Dysfunction	14	(70.0%)
	Fractional shortening	25.0%	[11%–40%]
	Ejection fraction	48.6%	[28%–57%]
AoV annulus ¹⁶	Enlarged	11	(57.9%)
AoV aspect	Dysplastic	18	(90.0%)
AoV function	Insufficiency	7	(38.9%)
Asc. Aorta diameter ¹⁶	Enlarged	20	(100.0%)
ALVT	Size (mm)	3.4	[1.5–8.0]
	Other structural cardiac malformations	2	(10.5%)
	Extra-cardiac	1	(5.3%)

Note: Data are given as *n* (%) or median (range). Data on the size and function of the aortic valve were missing in 1 and 2 cases, respectively. The fetal heart, left ventricle, aortic valve annulus and ascending aorta were 'enlarged', if: (1) the specific measurement did not fall within the normal range with respect to the gestational age^{15,16} or (2) the exact size had not been measured, but the size appeared evidently increased according to the cardiac expert involved in the treatment for that particular case.

Abbreviations: Asc, aorta ascending aorta; ALVT, aorto-left ventricular tunnel; AoV aortic valve; CTR, cardiothoracic ratio; GA, gestational age; LV, left ventricular; LVEDD, left ventricular end-diastolic diameter.

time of diagnosis (<24 weeks GA). The remaining 65% (13/20) of cases resulted in a liveborn term neonate (median birth weight: 3420 g; 92% ≥ 50th centile). The Apgar score at 5 min was ≥7 in all but one newborn (case 8), who eventually died (5%, 1/20). This case was diagnosed at 31 weeks of gestation, showing severe LV dysfunction and fetal hydrops, and quickly deteriorated after birth, requiring mechanical ventilation and inotropic support. Postnatal echocardiography, as well as MRI, were performed, displaying signs of a non-compaction cardiomyopathy with severe systolic dysfunction and mitral valve dysplasia. As extracorporeal membrane oxygenation was not yet available at the time in this facility (2010), it was decided not to intervene and the neonate died the 8th day of life due to progression of CHF.

All other liveborn neonates (60%, 12/20) underwent corrective surgery at a median age of 16 days (range: 1–44 days) and were discharged home after 22 days (median, range: 9–45 days). In the majority of cases the tunnel was closed at the aortic site (75%, 9/12), whereas in 25% (3/12) of cases both sites were closed. The origin of the left (LCA) and right coronary artery (RCA) were normal in 83% (10/12). In two cases (case 10 and 15) the RCA had to be separated from the tunnel. A residual paravalvar leak was described in three neonates (25%, 3/12) and surgery-related complications were encountered in one neonate (8%, 1/12). The

latter involved a case that presented with clinical seizures requiring antiepileptic treatment the day after surgery, associated with hypoxic-ischemic brain injury, which was confirmed on MRI. Although the epileptic activity appeared transient, mild unilateral spastic cerebral palsy (Gross Motor Function Classification System, level 1) and delayed language development was reported on neurological follow-up (case 14). Altogether, 60% (12/20) of fetuses with a prenatal diagnosis of ALVT were alive at time of our analysis. The majority of patients are free of morbidity (58%; 7/12) at a median follow-up time of 3.2 years (range, 16 days–17 years). In the remaining, aortic stenosis (AoS) was present in three (25%, 3/12), CHF with reduced left and right ventricular function in one (8%, 1/12) and neurological symptoms in one case (8%, 1/12) (Table 2).

3.3 | Prognostic factors

If the ALVT had been diagnosed in the second trimester (75%, 15/20) and signs of hydrops did not occur before 24 weeks of gestation (8/15), the fetal condition remained stable during the course of pregnancy and all survived to surgery. However, all fetuses with signs of fetal hydrops before 24 weeks of gestation (7/20) resulted in

TABLE 2 Prenatal features in relation to outcome

Case description		Characteristics at presentation				Peripheral Dopplers				Outcome				
Nr	GA dx (mm.)	ALVT (mm.)	LVH	AoV size	LV function	Fetal hydrops	UV flow	DV α -wave ^a	UA EDF ^a	MCA EDF ^a	IUT	Pregnancy outcome	Surgery	Mortality
1	21 + 3	2.6	+	Enlarged	Dysfunction	+	-	-	-	-	No	TOP	21 + 6	+
2	18 + 2	3.0	+	Enlarged	Dysfunction	+	-	-	-	-	No	TOP	20 + 1	+
3	18 + 4	2.5	+	Enlarged	Normal	+	-	-	-	-	No	TOP	19 + 5	+
4	21 + 1	1.9	+	Enlarged	Dysfunction	+	Normal	Normal	Normal	Normal	No	TOP	21 + 5	+
5	23 + 0	3.3	-	Normal	Dysfunction	+	Pulsatile	Abnormal	Abnormal	Normal	No	FD	N.A.	+
6	20 + 3	4.5	-	Normal	Dysfunction	+	-	Abnormal	Abnormal	-	-	FD	24 + 0	+
7	20 + 0	8.0	-	Enlarged	Dysfunction	+	Pulsatile	Abnormal	Abnormal	Abnormal	Yes	FD	23 + 0	+
8	31 + 3	6.0	+	Enlarged	Dysfunction	+	-	-	-	-	No	Livebirth	37 + 6	-
9	19 + 0	1.5	-	Normal	Normal	-	Normal	-	Normal	-	No	Livebirth	38 + 6	+
10	29 + 1	-	+	-	Dysfunction	-	-	-	-	-	-	Livebirth	38 + 2	+
11	38 + 1	5.0	+	Enlarged	Dysfunction	-	-	-	-	-	No	Livebirth	38 + 0	+
12	14 + 4	5.5	+	Enlarged	Normal	-	Normal	Normal	Normal	Normal	No	Livebirth	39 + 4	+
13	23 + 0	2.8	-	Normal	Dysfunction	-	Normal	Normal	Normal	Normal	No	Livebirth	39 + 6	+
14	20 + 4	3.5	-	Enlarged	Normal	-	Normal	Normal	Normal	Abnormal	-	Livebirth	37 + 0	+
15	20 + 5	3.0	+	Normal	Normal	-	Normal	Normal	Abnormal	Abnormal	Yes	Livebirth	38 + 0	+
16	20 + 6	1.5	-	Normal	Normal	-	Normal	Normal	Normal	Normal	No	Livebirth	38 + 0	+
17	22 + 3	4.0	+	Enlarged	Dysfunction	-	Normal	Normal	Normal	Abnormal	Yes	Livebirth	40 + 0	+
18	32 + 3	-	-	Normal	Dysfunction	-	-	-	-	-	-	Livebirth	38 + 2	+
19	23 + 0	4.0	-	Normal	Dysfunction	-	Pulsatile	Normal	-	-	No	Livebirth	39 + 4	+
20	30 + 4	4.2	+	Enlarged	Dysfunction	-	Normal	Normal	Abnormal	Abnormal	Yes	Livebirth	40 + 0	+
Risk of mortality														
If normal			33.3%	25.0%	16.7%	7.7%	11.1%	11.1%	14.3%	40.0%	50.0%			
If abnormal			45.5%	54.5%	50.0%	100.0%	66.7%	100.0%	60.0%	20.0%	25.0%			
OR (95% CI)			1.7 (0.3-10.3)	3.6 (0.5-26.4)	5.0 (0.5-54.5)	n.a.	16 (0.7-383.0)	n.a.	9.0 (0.6-143.9)	0.4 (0.02-6.3)	0.3 (0.03-4.2)			40%

Abbreviation: ALVT, aorto-left ventricular tunnel; AoV, aortic valve; CHF, congestive heart failure; CI, confidence interval; DV, ductus venosus; EDF, end-diastolic flow; FD, fetal death (spontaneous); GA, dx gestational age at diagnosis; IUT, intra-uterine (pharmacological) treatment; LV, left ventricular; LVH, left ventricular hypertrophy; MCA, middle cerebral artery; TOP, termination of pregnancy; UA, umbilical artery; UV, umbilical vein.

^aabnormal, if end-diastolic flow was absent or reversed.

^bfetal hydrops was present at autopsy.

elective or spontaneous termination of pregnancy. The presence of fetal hydrops appeared equally important in cases with a prenatal diagnosis in the third trimester, as all without signs of fetal hydrops survived (4/4), whereas the one presenting with hydrops at first evaluation died in the neonatal period (1/1).

Although LV FS or EF could only be obtained in 60% (12/20) of cases, the degree of LV dysfunction at presentation seemed related to the presence of fetal hydrops. We found a LV-FS \leq 25% (range: 11%–25%) or -EF \leq 51% (range: 28%–51%) at presentation in 87.5% of cases (7/8) that developed fetal hydrops during the course of pregnancy. Decreased EF or shortening fraction, on the other hand, was never found amongst survivors (FS range: 27%–40%; EF range: 40%–57%). Other factors associated with an increased mortality risk included an enlarged AoV diameter (54.5% vs. 25%, in those with normal AoV diameter) or LV hypertrophy (LVH) at presentation (45.5% vs. 33.3%, in absence of LVH).

Furthermore, evaluation of abnormal flow patterns on pulsed wave Doppler velocimetry can potentially aid to the differentiation between ALVT fetuses with a high mortality risk and those with a better chance of survival, based on the presence of absent or reversed end-diastolic flow (EDF) in the UA (mortality: 60.0% vs. 14.3%, if UA flow was normal), pulsatile flow in the UV (mortality: 66.7% vs. 11.1%, if UV was not pulsatile) or a reverse *a*-wave in the ductus venosus (DV) (mortality: 100.0% vs. 11.1%, if DV flow was normal).

Although the proportion of fetuses with AoV insufficiency tended to increase with advancing gestation (39% at presentation vs. 82% shortly after birth), this was not associated with mortality. A correlation between mortality and abnormal flow in the MCA did not seem evident either. Unfortunately, we were unable to assess the potential predictive value of the MPI or CVPS, as these could not be calculated in 65% (13/20) and 60% (12/20) of the cases, respectively. Only a few fetuses received transplacental pharmacological treatment with digoxin alone or a combination of digoxin and metoprolol following a prenatal diagnosis of ALVT (20%, 4/20). Although there was no progression of CHF in treated fetuses, this impedes us to reliably assess this potential effect on the risk of mortality as well (Table 3).

3.4 | Literature review

The literature search yielded 42 articles. After screening of the title and abstract and reviewing of the full-text, 17 articles were found eligible for inclusion. These articles together reported on 22 fetuses prenatally diagnosed with an ALVT (1996–2021).^{2,6,7,12,26–38} Patient characteristics and outcome of the reported fetuses are summarized in Table 4. Overall, 65% (15/23) were alive and thriving at the end of the follow-up period. Fetal hydrops was reported in 6/15 (33%) fetuses with a prenatal diagnosis in the second trimester, of which four resulted in fetal or postnatal demise (68%). On the other hand, fetal hydrops was never reported in those diagnosed in the third trimester, and only one case diagnosed in the third trimester demised (14%).

4 | DISCUSSION

This is the first study that reports on the fetal course of ALVT in relation to outcome in a contemporary cohort of prenatally diagnosed cases worldwide. Despite the significant risk of fetal or neonatal demise (40% of cases in our study), we found that in the absence of symptoms of fetal hydrops, all patients survived with good clinical outcome at a median age of 3.2 years (range, 1 month to 18 years).

This series shows that the key features leading to the fetal diagnosis of ALVT are cardiomegaly, LV dilatation, dilatation of the ascending aorta and paravalvular aorto-ventricular regurgitation. The retrograde flow that passes to the left ventricle beside the AoV, is the cornerstone of the diagnosis. With modern ultrasound systems the tunnel itself may even be visible (Figure 2). Majority of cases show an abnormal LV function at presentation, defined as an impaired LV-FS or -EF.²⁵ Impaired LV contractility may eventually lead to low cardiac output, elevated venous pressure, fetal hydrops and fetal or neonatal demise. ALVT usually presents as an isolated defect, though AoV abnormalities including bicuspid AoV may also be present.

Not surprisingly, fetal hydrops appears to be associated the most with adverse outcome. Prognosis of fetuses with symptoms of hydrops (including ascites, pleural effusion or skin edema) was very poor, as all cases died before a viable age was reached or surgery could be performed. However, if fetuses did not develop hydrops, all successfully received corrective surgery and the majority are free of morbidity at 3.2 years of age. Presence or absence of hydrops was described in 15/22 ALVT cases reported in the literature.^{6,12,26,28,32,33,36,37} Six cases had signs of hydrops with similar outcome compared to this series, as the majority resulted in fetal or postnatal demise (68%).^{6,26,33} Similar to our experience, the literature review showed that in the absence of hydrops, fetal or neonatal mortality occurred in only 14% of cases.^{6,28,31,32,34–36} Our finding that stable non-hydrops fetuses with ALVT, despite the impressive cardiomegaly and impaired contractility, generally survive to term with good clinical outcome, is essential for prenatal counseling; it is important that the parents are aware that the prognosis in those who survive without hydrops to near term is better than prognosis if there is evolving hydrops in mid-gestation before they make decisions regarding the pregnancy.⁸

We encountered a strong relationship between abnormal peripheral Doppler measurements and perinatal death in fetuses with ALVT. In this study 100% of cases with a reverse *a*-wave in the DV died, compared to 13% if the *a*-wave remained positive. The risk of mortality was also considerably higher among fetuses with pulsatile flow in the UV and absent or reversed EDF in the UA. As abnormal venous Dopplers are a result of CHF,²⁴ these parameters reflect on the condition of the fetus with development of fetal hydrops as an end-stage and do not influence the prognosis independently. This is in line with a previous study by Gudmundsson et al. stating that the presence of umbilical venous pulsations is the most useful predictor of perinatal death in cases with fetal hydrops.³⁹ However, it should

TABLE 3 Postoperative outcome & follow-up

Case	Postnatal course					General well-being		
	Age at surgery ^a	LV dysfunction	Residual shunt	Complications	Discharge home (days)	Follow-up	Reinterventions	Morbidity
9	42	No	-	NEC, residual AoS	16	Alive (17 years)	2 Surgical valve repair, AoV replacement (14 + 16.5 years)	Alive and healthy
10	44	No	No	-	N.A.	Alive (10 years)	1 Commisurotomy AoV + PV (7 months)	AoS (mild-abnormal)
11	10	No	-	-	45	Alive (13 years)	1 Bentall procedure (13 years)	AoS (abnormal), AoI, AoAsc aneurysm
12	1	No	No	Unknown	10	Alive (9 years)	0	AoS (mild)
13	1	Yes	-	-	22	Alive (10 years)	0	CHF (LV + RV dysfunction)
14	5	Yes	-	Hypoxic-ischemic brain injury po.	21	Alive (4 years)	0	Spastic cerebral palsy (GMFCS I), AoI, residual aneurysm ALVT ^b
15	25	Yes	Yes	-	34	Alive (2 years)	0	Alive and healthy
16	1	Yes	No	SVT	19	Alive (16 months)	0	Alive and healthy
17	29	No	Yes	-	22	Alive (1.5 months)	0	Alive and healthy
18	4	-	Yes	-	16	Alive (16 days)	0	Alive and healthy
19	25	Yes	-	-	9	Alive (3.5 weeks)	0	Alive and healthy
20	21	No	No	Unknown	30	Alive (1.5 months)	0	Alive and healthy

Note: Data are given as **median** or **proportion** of cases with complete information.

Abbreviations: ALVT, aorto-left ventricular tunnel; AoAsc, ascending aorta; AoS, aortic stenosis; AoV, aortic valve; CHF, congestive heart failure; GMFCS, I Gross Motor Function Classification System grade I; LV, left ventricular; mo, months; NEC, necrotizing enterocolitis; po, postoperative; PV, pulmonary valve; RV, right ventricular; SVT, supraventricular tachycardia; wks, weeks; yr, years.

^aAge at surgery in days.

^bSupraventricular tachycardia requiring medication.

be stressed that abnormal flow in the UA may be incorrectly interpreted as a sign of placental dysfunction, rather than a result of the presence and size an ALVT. Finally, an enlarged AoV diameter at presentation also seemed associated with the development of fetal hydrops and adverse outcome.

Safe and effective treatment options for ALVT patients in fetal life have not been reported to date. Although some studies suggest that the use of intrauterine digoxin and beta-blocker therapy may improve CVPS with little risk to do potential harm, case numbers in our study were limited and current evidence is too scarce to suggest Intra-uterine (pharmacological) treatment as a fetal therapy in cases with fetal ALVT.

The majority of liveborn neonates (92%) received corrective surgery without significant postoperative complications. Neonatal death occurred in the only liveborn that had presented with hydrops in the third trimester and quickly deteriorated after birth. Although we did not observe postoperative deaths in this study, postoperative

mortality has been reported in three cases in the literature.^{6,34,36} All demised due to rapid progressive deterioration perioperatively and/or postoperative complications. The age at surgery varied considerably amongst our original cases from a few hours after birth to 6 weeks of age. This is consistent with the literature, describing neonates that require surgery within the first days of life,^{6,30-32,34,35,37} as well as those in which surgery could be delayed up to 3 months or even 1 year of age.^{6,28} This reflects the heterogeneity in clinical conditions in ALVT patients, as well as changing attitudes regarding and expertise with neonatal surgical interventions in general. Altogether, our results stress that close monitoring of these neonates is warranted, given the risk of rapid and sudden deterioration despite aggressive anti-congestive therapy and the unpredictability of postoperative recovery.

Overall survival in fetuses with ALVT was 60% with good clinical outcome in the survivors. Fifty-eight percent of these cases did not show signs of additional morbidity with a normal cardiac function at a

TABLE 4 Summary of fetuses diagnosed with aorto-left ventricular tunnel (ALVT) reported in the literature ($n = 22^{38}$)

Prenatal diagnosis in second trimester								
Case	Year	Author	Time of diagnosis	Cardiac features at prenatal diagnosis	Fetal hydrops	GA at birth	Surgery (age, days)	Follow-up
1	1995	Cook ²	22 GA	LV dilatation and hypertrophy, turbulent flow through ALVT	Unknown	-	-	Termination of pregnancy
2	1996	Sousa-Uva ²⁶	22–24 GA	Severe LV dysfunction and dilatation, dysplastic aortic cusps, paravalvular aortoventricular reflux	Yes	-	-	Termination of pregnancy
3	1996	Sousa-Uva ²⁶	22–24 GA	Severe LV dysfunction, myocardial hypertrophy, dysplastic regurgitant aortic cusps	Yes	-	-	Spontaneous fetal demise (27 weeks of gestation)
4	2013	Terry ¹²	21 GA	Severe LV dilation/hypertrophy, poor contractility, reverse LVOT flow adjacent to aortic valve. Endocardial fibrosis	Yes	-	-	Spontaneous fetal demise (30 weeks of gestation)
5	2007	Pascoli ³⁴	26 GA	LV dilatation and hypertrophy, enlarged aortic root, displastic AoV and aortic regurgitation	No	39	Yes (-)	Neonatal death (day 10), due to persistent ischemic failure of extremities
6	2011	Singh ⁶	20 GA	-	Yes	37	Yes (2)	Postnatal demise (5 weeks), due to multisystem failure
7	2005	Biffanti ³³	22 GA	LV dilatation and dysfunction, ALVT	Yes	35	Yes (2)	Alive and thriving at discharge, FU 9 weeks postoperatively
8	2007	Kenny ⁷	26 GA	Significant eccentric jet of aortic regurgitation with LV dilatation, large ALVT	Unknown	40	Yes (11)	Alive, FU on postoperative course unknown
9	2008	Henaïne ²⁹	22 GA	Enlarged LV, abnormal systolo–diastolic flow in the ascending aorta	Unknown	Term	Yes (6)	Alive and thriving, FU 2 years
10	2011	Singh ⁶	22 GA	-	No	38	Yes (1)	Alive and thriving, FU unknown
11	2011	Singh ⁶	20 GA	-	No	40	Yes (1)	Alive and thriving, FU unknown
12	2011	Singh ⁶	23 GA	-	No	40	Yes (1)	Alive and thriving, FU unknown
13	2014	Jone ³¹	25 GA	LV dilatation and dysfunction, dysplastic aortic cusps, ascending aorta dilatation, ALVT	No	36	Yes (3)	Alive and thriving at 9 months FU
14	2016	Smith ³⁵	23 GA	Left and right ventricular dilatation and dysfunction	No	Term	Yes (3)	Alive and asymptomatic at 5 months FU
15	2020	Truong ³⁷	24 GA	LV dilatation, dysfunction, endocardial fibrosis and aortic regurgitation through a tunnel near the IVS	Yes	Term	Yes (3)	Alive with normal LV function at 2 years FU
Prenatal diagnosis beyond second trimester (or unknown)								
16	2017	Kosutic ³⁶	30 GA	LV and ascending aorta dilatation, separate ALVT	No	38	Yes (9 days)	Postnatal demise (8 weeks), due to peri-/postoperative complications
17	2000	Grab ²⁸	31 GA	LV and aortic root dilatation, large ALVT around the annulus	No	40	Yes (3 months)	Alive and thriving at 8 months FU
18	2005	Kolcz ³⁰	35 GA	Enlargement/severe hypertrophy LV, aortic root dilatation, ALVT with paravalvular regurgitation	Unknown	40	Yes (1 day)	Alive and thriving at 2 years FU
19	2015	Christmann ²⁷	35 GA	LV dilatation/hypertrophy, paravalvular regurgitation around the annulus	Unknown	-	Yes (18 days)	Alive and asymptomatic at 5 years FU
20	2016	Nakamura ³²	31 GA	LV dilatation/dysfunction, dysplastic aortic valve, ALVT	No	37	Yes (1 h)	Alive and thriving at 2 months FU

(Continues)

TABLE 4 (Continued)

Prenatal diagnosis beyond second trimester (or unknown)								
21	2021	Ito ³⁸	30 GA	LV dilatation, severe regurgitation through ALVT	Unknown	36	Yes (1)	Alive, trivial aortic regurgitation at 1 month after surgery
22	2016	Smith ³⁵	Unknown	-	Unknown (CHF reported)		Yes (1 day)	Alive and thriving, mild cardiomyopathie at 12 years FU

Abbreviations: FU, follow-up; IVS, intraventricular septum; LVOT, left ventricular outflow tract.

median age of 3.2 years. The majority of cases remained asymptomatic until the end of primary school, after which cardiac signs, such as a mild to moderate AoS, became more apparent and surgical intervention involving replacement of the AoV was necessary. In this study three cases needed AoV replacement at a median age of 14 years and 3/4 patients over age 10 has had additional surgery at the time of this writing.

Despite the international character of this study, with the aim to include a maximal number of available fetuses with this extremely rare heart defect, we were still underpowered to perform extensive statistical analyses. The retrospective character and broad time-period from which cases were retrieved, therewith precluded us to evaluate all potentially prognostic factors for adverse outcome, amongst which the presence of pathogenic variants after genetic testing. As a third, the considerable changes in the prenatal detection of CHDs in general, as well as care for these patients over the past decades may have resulted in the description of a selected population and the results may not be applicable to cases in the current period. To develop an accurate prediction model that aids prenatal counseling by truly discriminating those at risk of fetal or neonatal demise from those with a generally good clinical outcome, a global registry is necessary to obtain a larger study population with time.

In conclusion, evaluation of fetal hydrops and concomitant fetal Doppler anomalies before 24 weeks of gestation seem particularly useful to indicate cases of ALVT at risk for perinatal death. In the absence of signs of fetal hydrops, all cases reached term and were liveborn. Although close monitoring after birth is warranted, the vast majority will make it to surgery and survive with good clinical outcome. To improve our understanding of this disorder and the variability in clinical presentations, autopsy and genetic studies are necessary.

ACKNOWLEDGMENTS

We would like to thank Jan Schoones, a medical librarian at the Leiden University Medical Centre, for the assistance in the literature search. This research received no specific grant from any funding agency in the public, commercial, or not-for-profit sectors.

CONFLICT OF INTEREST

The authors whose names are listed immediately below certify that they have no affiliations with or involvement in any organization or entity with any financial interest, or non-financial interest in the subject matter or materials discussed in this manuscript.

DATA AVAILABILITY STATEMENT

The data that support the findings of this study are available on request from the corresponding author upon reasonable request. The data are not publicly available due to privacy or ethical restrictions.

ORCID

Amber E. L. van Nisselrooij  <https://orcid.org/0000-0003-1752-5834>

REFERENCES

- McKay R. Aorto-ventricular tunnel. *Orphanet J Rare Dis.* 2007;2:41.
- Cook AC, Fagg NL, Ho SY, et al. Echocardiographic-anatomical correlations in aorto-left ventricular tunnel. *Br Heart J.* 1995;74(4):443-448.
- van Velzen CL, Clur SA, Rijlaarsdam ME, et al. Prenatal detection of congenital heart disease--results of a national screening programme. *Br J Obstet Gynaecol.* 2016;123(3):400-407.
- Khoshnood B, De Vigan C, Vodovar V, et al. Trends in prenatal diagnosis, pregnancy termination, and perinatal mortality of newborns with congenital heart disease in France, 1983-2000: a population-based evaluation. *Pediatrics.* 2005;115(1):95-101.
- van Velzen CL, Ket JCF, van de Ven PM, Blom NA, Haak MC. Systematic review and meta-analysis of the performance of second-trimester screening for prenatal detection of congenital heart defects. *Int J Gynaecol Obstet.* 2018;140(2):137-145.
- Singh A, Reinhardt Z, Desai T, Rasiyah SV. Case series of antenatally diagnosed aortico-left ventricular tunnel. *Pediatr Cardiol.* 2011;32(6):822-825.
- Kenny D, Chen Q, Uzun O. Antenatal diagnosis of aortico-left ventricular tunnel. *Pediatr Cardiol.* 2007;28(3):241-242.
- Martins JD, Sherwood MC, Mayer JE, Jr., Keane JF. Aortico-left ventricular tunnel: 35-year experience. *J Am Coll Cardiol.* 2004;44(2):446-450.
- Horvath P, Balaji S, Skovranek S, Hucin B, Deleval M, Stark J. Surgical treatment of aortico-left ventricular tunnel. *Eur J Cardio Thorac Surg.* 1991;5(3):113-116; discussion 117.
- Hovaguimian H, Cobanoglu A, Starr A. Aortico-left ventricular tunnel: a clinical review and new surgical classification. *Ann Thorac Surg.* 1988;45(1):106-112.
- Diraneyya OM, Alhabshan F, Alghamdi A, Moafa H, Alnasef M, Kabbani MS. Aorto-left ventricular tunnel: case series of a rare disease. *Cardiol Young.* 2021;31(1):47-51.
- Terry J, Tapas M, Nowaczyk MJ. Prenatal and pathologic features of aorto-left ventricular tunnel causing fetal hydrops and intrauterine demise. *Pediatr Dev Pathol.* 2013;16(2):97-101.
- Bove KE, Schwartz DC. Aortico-left ventricular tunnel. A new concept. *Am J Cardiol.* 1967;19(5):696-709.
- Awadh AM, Prefumo F, Bland JM, Carvalho JS. Assessment of the intraobserver variability in the measurement of fetal cardiothoracic ratio using ellipse and diameter methods. *Ultrasound Obstet Gynecol official J Int Soc Ultrasound Obstet Gynecol.* 2006;28(1):53-56.

15. Paladini D, Chita SK, Allan LD. Prenatal measurement of cardiothoracic ratio in evaluation of heart disease. *Arch Dis Child*. 1990;65(1 Spec No):20-23.
16. Schneider C, McCrindle BW, Carvalho JS, Hornberger LK, McCarthy KP, Daubeny PEF. Development of Z-scores for fetal cardiac dimensions from echocardiography. *Ultrasound Obstet Gynecol official J Int Soc Ultrasound Obstet Gynecol*. 2005;26(6):599-605.
17. Hecher K, Campbell S, Snijders R, Nicolaides K. Reference ranges for fetal venous and atrioventricular blood flow parameters. *Ultrasound Obstet Gynecol official J Int Soc Ultrasound Obstet Gynecol*. 1994;4(5):381-390.
18. Mari G, Deter RL, Carpenter RL, et al. Noninvasive diagnosis by Doppler ultrasonography of fetal anemia due to maternal red-cell alloimmunization. Collaborative Group for Doppler Assessment of the Blood Velocity in Anemic Fetuses. *N Engl J Med*. 2000;342(1):9-14.
19. Parra-Cordero M, Lees C, Missfelder-Lobos H, Seed P, Harris C. Fetal arterial and venous Doppler pulsatility index and time averaged velocity ranges. *Prenat Diagn*. 2007;27(13):1251-1257.
20. Hernandez-Andrade E, Figueroa-Diesel H, Kottman C, et al. Gestational-age-adjusted reference values for the modified myocardial performance index for evaluation of fetal left cardiac function. *Ultrasound Obstet Gynecol official J Int Soc Ultrasound Obstet Gynecol*. 2007;29(3):321-325.
21. Ichizuka K, Matsuoka R, Hasegawa J, et al. The Tei index for evaluation of fetal myocardial performance in sick fetuses. *Early Hum Dev*. 2005;81(3):273-279.
22. Tsutsumi T, Ishii M, Eto G, Hota M, Kato H. Serial evaluation for myocardial performance in fetuses and neonates using a new Doppler index. *Pediatr Int*. 1999;41(6):722-727.
23. Tei C, Ling LH, Hodge DO, et al. New index of combined systolic and diastolic myocardial performance: a simple and reproducible measure of cardiac function--a study in normals and dilated cardiomyopathy. *J Cardiol*. 1995;26(6):357-366.
24. Huhta JC, Paul JJ. Doppler in fetal heart failure. *Clin Obstet Gynecol*. 2010;53(4):915-929.
25. Hsieh YY, Chang FC, Tsai HD, Tsai CH. Longitudinal survey of fetal ventricular ejection and shortening fraction throughout pregnancy. *Ultrasound Obstet Gynecol official J Int Soc Ultrasound Obstet Gynecol*. 2000;16(1):46-48.
26. Sousa-Uva M, Touchot A, Fermont L, et al. Aortico-left ventricular tunnel in fetuses and infants. *Ann Thorac Surg*. 1996;61(6):1805-1810.
27. Christmann M, Dave H, Buechel EV. Prenatal diagnosis of aorto-left ventricular tunnel: introducing the 'cockade sign'. *Eur Heart J*. 2015;36(18):1136.
28. Grab D, Paulus WE, Terinde R, Lang D. Prenatal diagnosis of an aortico-left ventricular tunnel. *Ultrasound Obstet Gynecol*. 2000;15(5):435-438.
29. Henaine R, Di Filippo S, Dauphin C, Bozio A, Ninet J, Lussan J-R. Simple repair of aortico-left ventricular tunnel in a newborn with early prenatal diagnosis. *J Card Surg*. 2008;23(4):368-370.
30. Kolcz J, Januszewska K, Malec E. Successful repair of aorto-left ventricular tunnel diagnosed prenatally. *Cardiol Young*. 2005;15(2):219-222.
31. Jone PN, Mitchell MB, Campbell DN, da Cruz EM. Prenatal diagnosis and successful outcome in neonate of aorto-left ventricle tunnel. *Echocardiogr*. 2014;31(1):E20-E23.
32. Nakamura Y, Miyaji K, Yoshii T, Ootomo Y, Kimura S. Aorto-left ventricular tunnel successfully repaired immediately after birth. *Ann Thorac Surg*. 2016;101(5):1988-1990.
33. Biffanti R, Reffo E, Sanders SP, Maschietto N, Stellin G, Milanese O. Images in cardiovascular medicine. Two-dimensional and real-time three-dimensional echocardiographic fetal diagnosis of aorto-ventricular tunnel. *Circulation*. 2005;111(21):e367-e368.
34. Pascoli I, Cester M, Nanhorngue K, Paternoster DM. Aortico-left ventricular tunnel diagnosed prenatally: case report. *Prenat Diagn*. 2007;27(13):1263-1265.
35. Smith BM, Cochran CD, Owens ST. Aortico-left ventricular tunnel and left ventricular non-compaction: a case series. *Cardiol Young*. 2016;26(2):382-385.
36. Kosutic J, Prijic S, Stajevic M, et al. Clinical implications of prenatal diagnosis of aorto-left ventricular tunnel on postnatal treatment and final outcome. *Turk J Pediatr*. 2017;59(3):342-344.
37. Truong BL, Moreau De Bellaing A, Vialle E, et al. Prenatal diagnosis of aorto-left ventricular tunnel with dysplastic bicuspid aortic valve: from fetal cardiac failure to favorable outcome. *Front Pediatr*. 2020;8:69.
38. Ito T, Aoki M, Hagino I, Umezu K. A case of a large type IV aortico-left ventricular tunnel successfully repaired at 1 day after birth. *Cardiol Young*. 2021;31(5):851-852.
39. Gudmundsson S, Huhta JC, Wood DC, Tulzer G, Cohen AW, Weiner S. Venous Doppler ultrasonography in the fetus with nonimmune hydrops. *Am J Obstet Gynecol*. 1991;164(1):33-37.

SUPPORTING INFORMATION

Additional supporting information may be found in the online version of the article at the publisher's website.

How to cite this article: van Nisselrooij AEL, Moon-Grady AJ, Wacker-Gussmann A, et al. The aorto-left ventricular tunnel from a fetal perspective: original case series and literature review. *Prenat Diagn*. 2022;42(2):267-277. <https://doi.org/10.1002/pd.6090>