

RESEARCH

Hormone receptor expression of colorectal cancer diagnosed during the peri-partum period

Jordyn Silverstein¹, Wesley Kidder^{1,2}, Susan Fisher³, Thomas A Hope^{1,4}, Samantha Maisel¹, Dianna Ng^{1,5}, Jessica Van Ziffle⁵, Chloe E Atreya^{1,2} and Katherine Van Loon^{1,2}

¹Helen Diller Family Comprehensive Cancer Center, University of California, San Francisco, California, USA

²Division of Hematology and Oncology, Department of Medicine, University of California, San Francisco, California, USA

³Department of Obstetrics, Gynecology and Reproductive Sciences, University of California, San Francisco, California, USA

⁴Department of Radiology and Biomedical Imaging, University of California, San Francisco, California, USA

⁵Department of Pathology, University of California, San Francisco, California, USA

Correspondence should be addressed to K Van Loon: katherine.vanloon@ucsf.edu

Abstract

Background: Colorectal carcinoma (CRC) during the peri-partum period is challenging to diagnose due to the overlapping symptoms of CRC and pregnancy. This is the first case series to investigate clinicopathologic, hormonal and molecular features of CRC diagnosed during the peri-partum period. We hypothesized that advanced presentations of CRC could possibly be mitigated by pregnancy-related hormonal factors.

Methods: We conducted a retrospective review of five women diagnosed with CRC during the peri-partum period and studied the clinical and molecular features of their cancer.

Results: All patients presented with stage IV CRC at diagnosis; three had primary tumors in the rectum and two had primary tumors in the sigmoid colon. The liver was the most common metastatic site (three of five women). Immunohistochemistry stains were negative for estrogen receptors alpha (ER α) and beta (ER β), and one tumor demonstrated low-level positivity for PR (1%). Formalin-fixed and paraffin-embedded (FFPE) biopsies from each case were tested with next-generation sequencing and found that all tumors were mismatch repair (MMR) proficient, and three harbored a KRAS mutation. Germline testing showed no predisposition to CRC; however, several somatic variants of undetermined significance (VUS) were identified.

Discussion: CRC in the peri-partum period poses significant risk factors for presentations with advanced disease due to diagnostic challenges. While our study provides no evidence that pathogenesis of CRC during pregnancy is driven by elevated estrogen and/or progesterone levels during pregnancy, additional putative etiologic factors, including placental growth factors, the immunosuppressive state of pregnancy and other physiologic processes during pregnancy, warrant future study.

Key Words

- ▶ colorectal cancer
- ▶ pregnancy
- ▶ estrogen
- ▶ progesterone
- ▶ molecular features

Endocrine Connections
(2019) 8, 1149–1158

Case reports

Patient 1: A 34-year-old female presented with bloody stools, both before and during pregnancy, which were attributed to hemorrhoids. Following her vaginal delivery, she continued to experience bright red blood per rectum, which she treated with diet modifications. At 10 months post-partum, fullness in the right upper quadrant was noted on examination, and an abdominal ultrasound detected hepatomegaly with

bilobar hepatic masses. A CT scan of the chest/abdomen/pelvis confirmed numerous hypodense metastases within the liver, with associated compression of the right portal vein, distal sigmoid colon thickening with adenopathy (Fig. 1). A colonoscopy identified a partially circumferential mass in the sigmoid colon, which was biopsied and pathology demonstrated invasive adenocarcinoma.

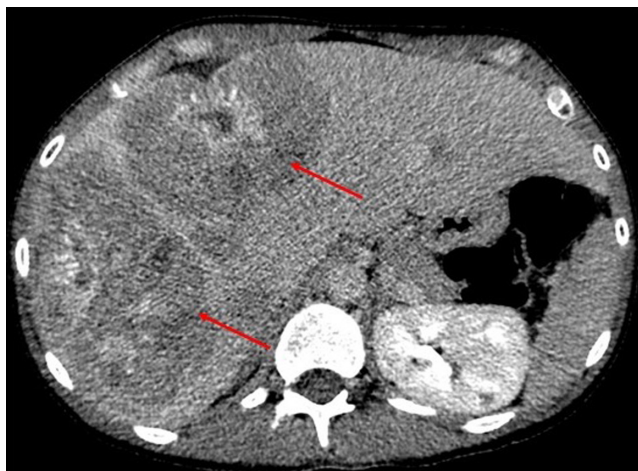

Figure 1
CT with contrast at diagnosis showing numerous hypodense metastases (red arrows) in the liver (patient 1).

Patient 2: A 30-year-old female experienced a self-limited episode of diarrhea at 25 weeks gestational age for which she was diagnosed with acute gastroenteritis. At 37 weeks, a cesarean section was performed due to arrest of descent during labor. At 2 weeks post-partum, she began experiencing copious diarrhea that was attributed to post-operative bowel changes. Treatment for *Clostridium difficile* with metronidazole and then oral vancomycin had little impact on her symptoms. Diarrhea persisted with more than ten loose stools per day and electrolyte derangements. A flexible sigmoidoscopy was performed after patient reported the passage of air and stool per vagina, which revealed an area of ulceration and nodularity in the upper rectum. Biopsies confirmed invasive adenocarcinoma. At the time of her diagnosis, she had lost 30 pounds from her pre-pregnancy weight, was incontinent of feces and had developed a rectovaginal fistula. Magnetic resonance imaging of the pelvis at diagnosis revealed a bulky infiltrative high rectal mass extending into the right pelvic sidewall, with direct invasion into the fundus of the uterus and fistulization into the endometrial canal (Fig. 2). A staging PET/CT demonstrated no evidence of metastatic disease; however, peritoneal carcinomatosis was discovered during a laparoscopic diversion procedure.

Background

In the United States, colorectal cancer (CRC) is the third most common cause of cancer-related death (1). Over the past two decades, CRC incidence has declined by 3–4% each year (2). Consistent with CRC screening patterns (3),

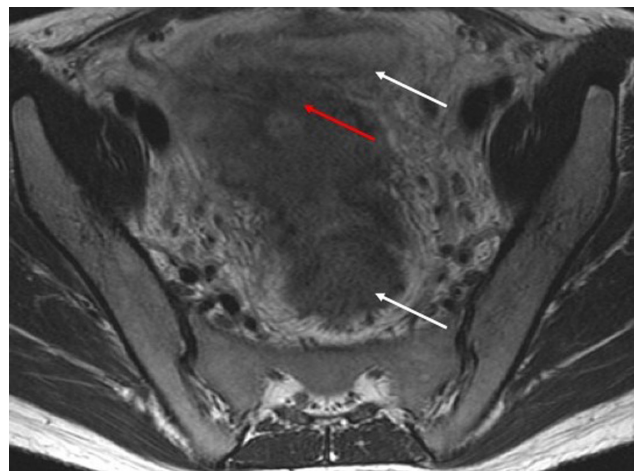


Figure 2
T2-weighted MRI without fat saturation showing a rectovaginal fistula (red arrow) and bulky infiltrative mass at diagnosis, white arrows are uterus and rectus (patient 2).

this decrease in CRC incidence is primarily among patients above the age of 50 years and greatest in patients above the age of 70 years (4). Meanwhile, the incidence of CRC in the United States is increasing among young and middle-aged adults, especially in obese women (5). Among adults between the ages of 20–39, colon cancer rates have increased by 1 to 2.4% annually since the mid-1980s; among adults between ages 40 and 54, rates have increased by 0.5–1.3% annually since the mid-1990s (6, 7).

CRC in pregnant women is rare, with estimated incidence rates between 0.002 and 0.2% of pregnancies (8). An increase in the incidence of CRC during pregnancy has been reported over time but has been assumed to be attributable, at least in part, to trends toward increasing maternal age (9). Prior studies have not consistently identified any association between reproductive history and CRC risk, although some studies have reported an inverse correlation between increased parity and CRC risk (10, 11, 12). Higher parity was however shown in one study to increase risk of CRC in the proximal colon (13). Additionally, hormone replacement therapy has been associated with reduced risk for CRC (14).

There have been few studies of patients with metastatic CRC diagnosed during the peri-partum period (15, 16, 17). A 1993 study examined 41 cases of pregnant women with metastatic CRC, reporting that the majority of cases (64%) originated in the rectum (9). A systematic review of 119 case reports of CRC diagnosed during pregnancy, compared mode of presentation, outcomes of the mother and fetus and treatment decisions (18). None of these

prior studies have evaluated relevant factors of disease biology or molecular features of the tumors.

Following our observation of five women who presented to our institution with advanced CRC diagnosed during the post-partum period, we hypothesized that advanced presentations of CRC diagnosed in the per-partum period could possibly be driven by pregnancy-related hormonal factors. While a few prior studies have sought to evaluate the expression of estrogen receptors (ERs) and progesterone receptors (PRs) in colorectal tumor cells, results have been mixed. Earlier studies reported that 20–90% of CRC tumors express ER and PR (19, 20, 21); however, more recent data using the currently accepted methodology of immunohistochemistry (IHC) with ER and PR antibodies demonstrated no ER or PR expression in a sample of 156 CRC tumors (22, 23). None of these studies included patients with CRC diagnosed during the post-partum period. Herein, we review the clinical presentations of five cases of CRC diagnosed in the post-partum period, with correlative evaluations of molecular features.

Methods

Patient selection

We performed a retrospective review of five cases of advanced CRC diagnosed in post-partum women cared for at the UCSF Helen Diller Comprehensive Cancer Center during 2016–2017. Convenience sampling was employed, and patients were identified by physician recall. Each patient provided informed consent to participate in a research protocol for the molecular characterization of gastrointestinal malignancies, approved by the UCSF Committee on Human Research (#13-12574).

Pathologic interpretation

Formalin-fixed and paraffin-embedded (FFPE) specimens from either the primary or a metastatic site obtained at the time in closest proximity to pregnancy were obtained. Histology and specimen adequacy were confirmed by a pathologist (D N).

Immunohistochemistry

Immunohistochemistry for estrogen receptor alpha (ER α) and PR were performed using a validated protocol already in use for routine clinical practice in a licensed and accredited anatomic pathology laboratory.

Estrogen receptor beta (ER β) was optimized for dilutions between 1:100 and 1:250, using a tissue microarray with ten cores of tonsillar tissue and two cores of placental tissue, as well as one case each of normal testis, normal adrenal gland and tonsil with reactive hyperplasia. For ER α and PR, a previously tested ER-positive and PR-positive breast cancer was used as a positive control. For ER β IHC, a tonsil with reactive lymphoid hyperplasia was used as a positive control.

The slides were deparaffinized in Clear-Rite™ 3 (xylene substitute) and hydrated in graded alcohols, deionized water. The staining was performed at room temperature manually. For ER α , ER β and PR, endogenous peroxidase activity was blocked with 3% hydrogen peroxide for 10 min (H1009; Sigma-Aldrich). The slides were rinsed in tap water for 2 min, and then deionized water for ten dips. For ER α and PR, heat-induced epitope retrieval (HIER) was performed using a Pascal (Dako) with Tris-EDTA pH 9.0 (BP152-500; Fisher Scientific) at 97°C for 60 min, and for ER β HIER was performed using a pressure cooker (Fagor, Scottsdale, AZ, USA) with citrate pH 6.0 (C7129-500G; Sigma-Aldrich) at 121°C for 10 min, left in the pressure cooker which is removed from the heat source to begin cooling for 10 min and then the container of buffer is removed from the pressure cooker and immersed in a cool water bath for 10 min. The slides were then rinsed in tap water for 1 min and held in distilled water. For ER α , ER β and PR IHC, the slides were rinsed and immersed in phosphate buffered saline with 1% Tween 20 (P1379-100mL; Sigma-Aldrich) for 10 min. ER α and ER β IHC slides were incubated for 30 min with primary antibody at 1:100 dilution, and PR IHC slides for 30 min at 1:50 dilution. The slides were rinsed twice with phosphate buffered saline with 1% Tween 20 for 3 min each time. The slides were then incubated with the labeled polymer (Dako Envision+ Rabbit secondary, K400311-2, lot number: 10124979; Dako Envision+ Mouse secondary, K400111-2, Secondary Lot #: 10125910) for 30 min. The slides were rinsed with phosphate buffered saline with 1% Tween 20 for 3 min, twice. The ER α and PR slides were incubated with diaminobenzidine (DAB) (K346811-2; Dako) for 3 min, while the ER β was incubated in DAB for 10 min. The slides were treated with a copper sulfate solution for DAB enhancement for 1 min, and counterstained with Mayer's hematoxylin (HXMMHGAL; American Mastertech) for 3 min. The slides were then washed in 0.08% ammonium hydroxide for four minutes (10600; Electron Microscopy Sciences) to blue the hematoxylin. The slides were rinsed with tap water for at least one minute between each step.

Details of the antibodies used are summarized in Supplemental Table A (see section on [supplementary data](#) given at the end of this article). ER α , ER β , and PR status were reported as binary variables (positive or negative). For ER α , ER β and PR, a sample was reported as positive when $\geq 1\%$ of tumor cells showed any nuclear staining and negative when $< 1\%$ of invasive cells showed any nuclear staining. Cancer tissue was compared to the normal tissue on the same slide with the same thresholds.

Next-generation sequencing

All tumors underwent next-generation sequencing (NGS) using the UCSF500 Cancer Gene Panel, which analyzes the exons of 479 genes, and select introns of 47 genes. Genomic DNA was extracted from both tumor and normal tissue using the DNA FFPE TissueKit (Qiagen), and quantified by Qubit fluorometry (Thermo Fisher Scientific). A DNA mass of 250 ng was further processed by KAPA HyperPrep Kits for Illumina – Kapa Biosystems. Target enrichment was performed by hybrid-capture (Roche Nimblegen), and sequencing on an Illumina HiSeq 2500 in rapid run mode (2×101 bp read length). An average read depth of $500\times$ was obtained for tumor sequencing, and an average read depth of $300\times$ was obtained for normal sequencing. Sequence reads are de-duplicated to allow for accurate allele frequency determination and copy number calling. Filtering of common germline polymorphisms present dbSNP, as well as technology-specific sequencing artifacts was performed before data analysis. Sanger sequencing was performed using standard reagents and methods; primer sequences for NRAS, KRAS, BRAF and EGFR are available upon request.

PCR products were purified using the Exo/SAP method, and sequencing reactions are performed using Big Dye v3.1 (Applied Biosystems). The sequencing products were separated by capillary electrophoresis on an Applied Biosystems 3500XL Genetic Analyzer. Sequence traces were analyzed using Mutation Surveyor (Softgenetics). Methylation-specific PCR for MLH1 promoter methylation was performed following DNA bisulfite conversion with the EZ DNA Methylation-Lightning™ kit (Zymo) and the EpiTect HRM PCR Kit (Qiagen) (24). PCR-based microsatellite instability (MSI) was assessed by a commercial assay (Promega) and separated by capillary electrophoresis on an Applied Biosystems 3500XL Genetic Analyzer.

Results

Patient characteristics

The clinicopathologic characteristics of the five patients are summarized in [Table 1](#). The median age of patients was 37 (range 30–45), and three were of advanced maternal age (> 35 years) at the time of delivery. Two deliveries were complicated by a breech presentation. All patients presented with stage IV disease at diagnosis. All had left-sided primary tumors, three with primary tumors in the rectum and two with primary tumors in the sigmoid colon. The most common metastatic site was to the liver (three of five). None of the patients had known risk factors for CRC including IBD or a history of CRC in a first-degree relative. Oral hormonal therapy was reported by two patients. None had previously undergone a colonoscopy prior to CRC diagnosis. Of the five women, four were alive at time of this report; thus, median overall survival was not calculable.

Molecular features

The results of ER α , ER β and PR IHC performed on tumor specimens and normal tissue are reported in [Table 2](#). All the tumors were negative for ER α and ER β , and only one was weakly positive (1%) for PR. As a comparison, all normal tissue was negative for ER α , ER β and PR. The results of NGS are summarized in [Table 3](#). An APC mutation was detected in four tumors; TP53 mutations were detected in four tumors; both APC and TP53 mutations were detected in three tumors. KRAS mutations were detected in three tumors, and both KRAS and TP53 mutations were detected in two tumors. A full summary of the types of somatic alterations is provided in [Fig. 3](#).

Discussion

CRC diagnosed during the peri-partum period is rare. However, all patients in this series presented with metastatic disease, raising the question of whether their clinical presentations could be related to unique disease biology or whether the presentations with advanced stage were due to delays in diagnosis, with symptoms masked by pregnancy.

Of all patients diagnosed with CRC, only 21% have stage IV disease at diagnosis (1). However, in a systematic review of 119 case reports of CRC diagnosed during pregnancy, 48% of women presented with metastatic

Table 1 Demographic and clinical characteristics.

	Patient 1	Patient 2	Patient 3	Patient 4	Patient 5
Demographics					
Age at diagnosis	34	30	39	37	45
Race	White	Asian	White	White	White
BMI	19	19	18	19	24
Gestational age at delivery	40 w 4 d	37 w 2 d	39 w 5 d	39 w 2 d	39 w 0 d
Type of delivery	NSVD	C-section	NSVD	NSVD	C-section
Complications during pregnancy or delivery	Breech	None	None	Cervical laceration	Breech
Obstetric history	G1P1	G1P1	G3P2	G3P1	G2P2
Conception (IUI vs IVF)	Spontaneous	Spontaneous	IUI	Spontaneous	Spontaneous
Existing medical conditions	Anemia, anxiety, bulimia, depression, patent foramen ovale, herpes genitalis	Anemia, anxiety	Gastritis	Anemia	Cholelithiasis, abnormal pap
IBD (UC or CD)	No	No	No	No	No
Alcohol use	No	No	No	No	No
Tobacco use	Former smoker	Never smoker	Never smoker	Never smoker	Current smoker
Occupation	Artist	Nurse	Administrative worker	Teacher	Horse trainer
Past colonoscopy	No	No	No	No	No
History of oral hormone use	No	Yes	No	No	Yes
Personal history of cancer	No	No	No	No	No
First-degree relative with cancer	Skin (father)	Brain (mother)	None	None	None
Clinical characteristics					
Duration between delivery and diagnosis (months)	10.7	3.4	15	5.5	17.1
Disease stage at diagnosis	IV	IV	IV	IV	IV
Histologic grade	Low	High	High	Low	Low
Primary tumor location	Sigmoid colon	Rectum	Splenic flexure	Rectum	Rectum
Metastatic sites	Liver	Peritoneum, lungs	Liver	Liver, bone	Lungs
CEA at diagnosis	726.6	5.7	1	582.4	78.6
MMR status ^a	Proficient	Proficient	Proficient	Proficient	Proficient

^aDone by IHC testing for MLH1, MSH2, MSH6 and PMS2.

CD, Crohn's disease; IBD, inflammatory bowel disease; IUI, intrauterine insemination; IVF, *in vitro* fertilization; NSVD, normal spontaneous vaginal delivery; UC, ulcerative colitis.

disease at diagnosis, and stage-for-stage overall survival was worse when compared to nonpregnant women (18). Because symptoms of CRC overlap with those of pregnancy, women may be subject to diagnostic delays. In our cohort, initial signs and symptoms of CRC included

nausea, vomiting, malaise, abdominal distension, altered bowel habits and rectal bleeding – all of which are common symptoms during pregnancy. Four out of the five women in this study experienced rectal bleeding, which was attributed to hemorrhoids typically associated

Table 2 Estrogen receptor alpha (ER α), estrogen receptor beta (ER β) and progesterone receptor (PR) status of CRC tumors and matched normal tissue.

IHC expression	Patient 1	Patient 2	Patient 3	Patient 4	Patient 5
ERα status					
Tumor	Negative	Negative	Negative	Negative	Negative
Normal tissue	Negative	Negative	Negative	Negative	Negative
ERβ status					
Tumor	Negative	Negative	Negative	Negative	Negative
Normal tissue	Negative	Negative	Negative	Negative	Negative
PR status					
Tumor	Negative	Negative	Negative	Positive (1%)	Negative
Normal tissue	Negative	Negative	Negative	Negative	Negative

Table 3 Next-generation sequencing of tumors.

	Patient 1	Patient 2	Patient 3	Patient 4	Patient 5
Pathogenic genetic mutations	APC SOX9 TP53	KRAS TP53 APC SOX9	BRAF ATM CTNNB1 ARID2 CDH1 SETD2 TP53	KRAS FBXW7 APC TP53	PIK3CA KRAS SMAD4 APC
Variants of undetermined significance (VUS)	ARFRP1 amplification, GNAS amplification, TOP1 amplification, ASXL1 amplification, IKBKE p.V365I, ZNF217 amplification, AURKA amplification, NFE2L2 p.I301T, BCL2L1 amplification, RUNX1T1 amplification, BLM p.V4A, SLIT2 p.R1500W, FANCA p.E45K, SRC amplification	NCOR1 p.K294_R295, EPHA2 p.R762C	BRCA2 amplification, FLT3 amplification, SPEN p.R193H p.Y650C, CDK8 amplification, IRS2 amplification, ERBB3 p.L1177I, PAX5 p.R122W, FAT1 p.I895T, PREX2 p.H1009L, FGF14 amplification, RB1 amplification, FLT1 amplification, SMO p.V129I	BRCA1 p.R496C, GNAS p.P345R,P349_I357del, RB1 amplification, BRCA2 amplification, CDK8 amplification, IRS2 amplification, KDR p.A20T, ZNF703 p.H402_D403>PTHL GGSSTCSAHD, FGF14 amplification, MAGI2 p.G1304D, FLT1 amplification, FLT3 amplification, MAP2K4 p.Q69E, NF1 p.I1803V	ERBB2 p.D873G, EPHA3 p.V983M
Germline mutation	None	None	None	None	None
Microsatellite status	Stable	Stable	Stable	Stable	Stable

with increased pressure in the rectal venous plexus during pregnancy. These findings are consistent with clinical observations from a case series of 119 cases of pregnancy-associated CRC, which also reported that bleeding and abdominal pain were the most common presenting symptoms, occurring in 47 and 38% of the women, respectively (18). Because early diagnosis is one of the most important contributing factors to the prognosis of CRC (25), efforts to increase awareness of the possible concurrence of CRC during pregnancy among obstetric providers could possibly reduce diagnostic delays.

Expanding upon the existing literature which only described the clinical features of CRC during pregnancy, our study sought to improve our understanding of etiologic factors that might contribute to the development of CRC in pregnant women. It is notable that all the women in our series lacked any known predisposition to CRC, including IBD, alcohol consumption, hereditary CRC syndromes and a family history of CRC (26, 27, 28, 29, 30, 31, 32). No germline mutations were detected, which is consistent with a study that found low probability of having a known germline mutation in patients with CRC <40 years old (33). However, numerous VUS were identified in all of the women, which may merit further exploration.

Etiologic mechanisms associated with pregnancy have been the subject of extensive speculation, including the overexpression of pregnancy-related growth factors and human placental growth hormones and the immunosuppressive state of pregnancy.

Other cancers have been shown to be hormonally reactive to elevated estrogen and progesterone levels that occur during gestation (19); however, the absence of ER alpha, ER beta and PR expression in the tumors we examined

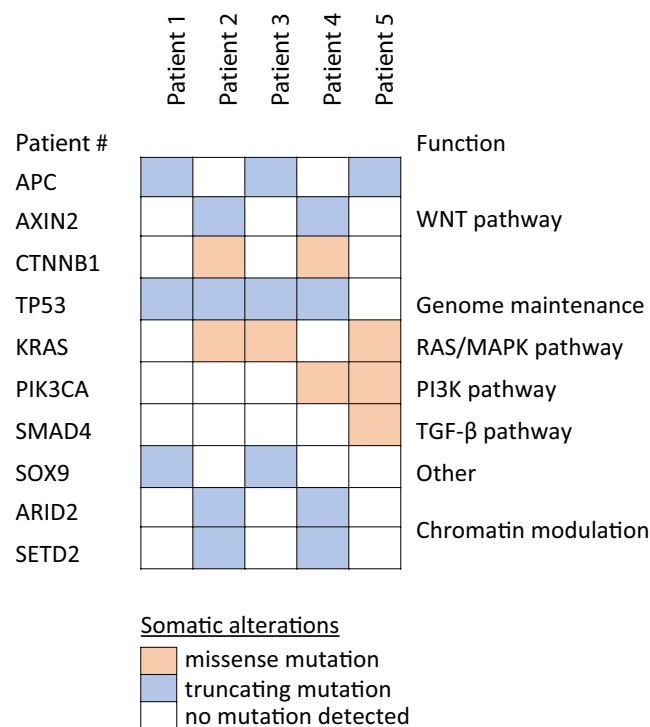


Figure 3 Types of somatic alterations in CRC tumors obtained during the peri-partum period.

revealed no evidence that these tumors were mediated by the elevated estrogen and progesterone levels that occur during pregnancy. These results are supported by a study done on 156 CRC specimens from nonpregnant individuals which used the same antibodies and found that none of the 156 tumors stained positive for ER, and only one was PR positive (22). That study and our current study used standard antibodies and contemporary techniques which determine ER status of breast cancers in the modern era. However, an earlier study, which in contrast used a dextran-coated charcoal assay, reported that both normal colon tissue and CRC express ER (40 of 60 were ER-positive) and PR (7 of 50 were PR positive) (20). The dextran-coated charcoal assay is a method that is not currently used clinically, but future studies should compare the efficacy of the different techniques for determination of ER status in colon tissue. Given the lack of detectable ER and PR expression in our five cases, elevated estrogen and progesterone levels during pregnancy seem unlikely to be driving the pathogenesis of CRC during pregnancy. The lack of ER and PR expression is further supported by The Cancer Genome Atlas RNA sequencing data for CRC (34).

In evaluating the molecular profiles of the tumors, the most common mutations were in TP53, APC and KRAS. Notably, all patients had mutations in the WNT pathway which may be relevant due to crosstalk with estrogen signaling (35); however, the specific mutations in this pathway were heterogeneous among the patients. Beyond these mutations, which are characteristic of CRC tumors (34, 36, 37), there were no clear commonalities between the mutational profiles of the five tumors in our case series.

Without clear support for our hypothesis that tumor pathogenesis was driven by pregnancy-related estrogen or progesterone, alternate hypotheses were considered. One alternate hypothesis for the aggressive pathogenesis of CRC during pregnancy is that prostaglandins and growth factors that are elevated during pregnancy could possibly incite transformation of a precursor lesion or rapid growth and metastasis. Relevant molecules include cyclooxygenase-2 (COX-2) and the insulin-like growth factor (IGF) family members. One study found that COX-2 mRNAs were abundant in CRCs and were low to undetectable in normal colon tissue (38). The IGF family has been shown to have mitogenic and anti-apoptotic effects on proliferation in various epithelial cells, including the colon (39). In addition, high blood levels of IGF-I and IGF-II have been shown to be associated with increased risk of CRC (40).

Another possible hypothesis involves elevated placental production of angiogenic factors that enter maternal blood. By the end of the first trimester of pregnancy, placental cells have invaded the uterus and initiated the flow of maternal blood to the placenta. As a result, the architecture of the maternal–fetal interface promotes the release of the vascular endothelial growth factor (VEGF) family into maternal blood. This is supported by the fact that placental growth factor (PlGF) and soluble fms-like tyrosine kinase 1 (sFlt-1) levels increase as gestation progresses (41). The VEGF family is of particular interest because it has been shown to be angiogenic and tumor promoting (42). Other molecules that the placenta releases into maternal blood include fibroblast growth factor (FGF) and transforming growth factor beta (TGF- β) (43, 44). One study showed that PlGF is overexpressed in tumor types and the circulating form is elevated in patient sera (45, 46). Given this information, it would be reasonable to explore whether the increase in VEGF family molecules and other growth factors during pregnancy could contribute to rapid tumor development.

Lastly, the immunosuppressive state of pregnancy has been postulated to accelerate tumor growth during pregnancy. Exact mechanisms of immunosuppression during pregnancy are not well understood, and the most convincing evidence is more anecdotal than experimental. Infection with the influenza virus during pregnancy is more likely to be severe (47, 48). This phenomenon has also been observed with Ebola (49, 50); however, reasons why pregnant women respond poorly to these viruses is unknown. Additionally, autoimmune diseases have dichotomous effects during pregnancy – some worsen (systemic lupus erythematosus), while others improve (rheumatoid arthritis) (51). This paradoxical response of the maternal immune system could be involved in a lowering of host defenses against CRC and perhaps other tumor types, allowing unbridled growth and rapid spread.

Several limitations of this retrospective case series should be acknowledged. This study was exploratory in nature, and our small convenience sample reflects the rarity of this condition. Although the evaluation of these tumors was notable for the absence of hormone receptor expression or genetic predisposition, these factors cannot be entirely excluded for other similar patients. Additionally, the cancer specimens available were preserved in FFPE, a process that may damage DNA (52), such that robust DNA extraction and sequencing library construction protocols must be applied.

Also, many archived samples available for testing were limited in cellularity; therefore, the specimens used for our analyses may not be representative due to the known possibility of intra-tumoral heterogeneity (53). Moreover, because all patients were diagnosed by biopsies obtained after pregnancy, the ER and PR expression of the tumor during pregnancy could not be analyzed. Theoretically, the ER and PR expression profiles of the tumors could have evolved following delivery, with the tumor hormonally reactive during pregnancy but then downregulated at the time of biopsy in the post-partum period.

Conclusion

These five patients each presented with advanced stage CRC in the peri-partum period, without genetic predisposition or known risk factors. The long periods of symptoms prior to diagnosis raise concern that the symptoms of CRC are often masked by symptoms of pregnancy, resulting in diagnostic delays. This series is notable for consistent presentations with all left-sided tumors; however, there were no other obvious consistencies in molecular and clinicopathologic features among the cases. Weak positivity for PR was detected in only one tumor, and none demonstrated positive staining for ER α or ER β . Further investigation is warranted to elucidate if and why pregnancy-related hormones and growth factors in the immunosuppressive stage of pregnancy alter the disease biology of CRC and to more completely characterize the molecular features of CRC diagnosed in the peri-partum period.

Supplementary data

This is linked to the online version of the paper at <https://doi.org/10.1530/EC-19-0063>.

Declaration of interest

The authors declare that there is no conflict of interest that could be perceived as prejudicing the impartiality of the research reported.

Funding

Jordyn Silverstein received support from the UCSF Resource Allocation Program for Trainees (RAPtr) Program. Dr Chloe Atreya is supported by the NIH and NCI under award number K08CA175143.

Acknowledgments

The authors are grateful to the patients and their family members for their generous contributions to this research study.

References

- 1 Siegel RL, Miller KD & Jemal A. Cancer statistics, 2018. *CA: A Cancer Journal for Clinicians* 2018 **68** 7–30. (<https://doi.org/10.3322/caac.21442>)
- 2 Ryerson AB, Ehemann CR, Altekruse SE, Ward JW, Jemal A, Sherman RL, Henley SJ, Holtzman D, Lake A, Noone A, *et al.* Annual report to the nation on the status of cancer, 1975–2012, featuring the increasing incidence of liver cancer. *Cancer* 2016 **122** 1312–1337. (<https://doi.org/10.1002/cncr.29936>)
- 3 Bibbins-Domingo K, Grossman DC, Curry SJ, Davidson KW, Epling JW, García FAR, Gillman MW, Harper DM, Kemper AR, Krist AH, *et al.* Screening for colorectal cancer: US Preventive Services Task Force Recommendation Statement. *JAMA* 2016 **315** 2564–2575. (<https://doi.org/10.1001/jama.2016.5989>)
- 4 Ansa BE, Coughlin SS, Alema-Mensah E & Smith SA. Evaluation of colorectal cancer incidence trends in the United States (2000–2014). *Journal of Clinical Medicine* 2018 **7** E22. (<https://doi.org/10.3390/jcm7020022>)
- 5 Liu P-H, Wu K, Ng K, Zauber AG, Nguyen LH, Song M, He X, Fuchs CS, Ogino S, Willett WC, *et al.* Association of obesity with risk of early-onset colorectal cancer among women. *JAMA Oncology* 2019 **5** 37–44. (<https://doi.org/10.1001/jamaoncol.2018.4280>)
- 6 Bailey CE, Hu C-Y, You YN, Bednarski BK, Rodriguez-Bigas MA, Skibber JM, Cantor SB & Chang GJ. Increasing disparities in the age-related incidences of colon and rectal cancers in the United States, 1975–2010. *JAMA Surgery* 2015 **150** 17–22. (<https://doi.org/10.1001/jamasurg.2014.1756>)
- 7 Siegel RL, Fedewa SA, Anderson WF, Miller KD, Ma J, Rosenberg PS & Jemal A. Colorectal cancer incidence patterns in the United States, 1974–2013. *Journal of the National Cancer Institute* 2017 **109** djw322. (<https://doi.org/10.1093/jnci/djw322>)
- 8 Heres P, Wiltink J, Cuesta MA, Burger CW, van Groeningen CJ & Meijer S. Colon carcinoma during pregnancy: a lethal coincidence. *European Journal of Obstetrics and Gynecology and Reproductive Biology* 1993 **48** 149–152. ([https://doi.org/10.1016/0028-2243\(93\)90257-D](https://doi.org/10.1016/0028-2243(93)90257-D))
- 9 Bernstein MA, Madoff RD & Caushaj PF. Colon and rectal cancer in pregnancy. *Diseases of the Colon and Rectum* 1993 **36** 172–178. (<https://doi.org/10.1007/BF02051174>)
- 10 Potter JD & McMichael AJ. Large bowel cancer in women in relation to reproductive and hormonal factors: a case-control study. *Journal of the National Cancer Institute* 1983 **71** 703–709.
- 11 Lo AC, Soliman AS, Khaled HM, Aboelyazid A & Greenson JK. Lifestyle, occupational, and reproductive factors and risk of colorectal cancer. *Diseases of the Colon and Rectum* 2010 **53** 830–837. (<https://doi.org/10.1007/DCR.0b013e3181d320b1>)
- 12 Guan HB, Wu QJ, Gong TT, Lin B, Wang YL & Liu CX. Parity and risk of colorectal cancer: a dose-response meta-analysis of prospective studies. *PLoS ONE* 2013 **8** e75279. (<https://doi.org/10.1371/journal.pone.0075279>)
- 13 Lu Y, Oddsberg J, Martling A & Lagergren J. Reproductive history and risk of colorectal adenocarcinoma. *Epidemiology* 2014 **25** 595–604. (<https://doi.org/10.1097/EDE.0000000000000077>)
- 14 Lobo RA. Hormone-replacement therapy: current thinking. *Nature Reviews Endocrinology* 2017 **13** 220–231. (<https://doi.org/10.1038/nrendo.2016.164>)
- 15 Aiyer R, Sweetman K, Larsen-Disney P & Fish A. A colorectal carcinoma imitating a primary ovarian carcinoma in a postpartum woman. *Case Reports* 2013 **2013** bcr2013201055. (<https://doi.org/10.1136/bcr-2013-201055>)
- 16 Mourra N, Lefevre JH & Arrive L. Postpartum rectal adenocarcinoma in a 26-year-old woman. *Acta Obstetrica et Gynecologica Scandinavica* 2012 **91** 270–271. (<https://doi.org/10.1111/j.1600-0412.2011.01310.x>)
- 17 Steinberg L, Nisenbaum HL, Horii SC & Salhany KE. Post-cesarean section pain secondary to intussuscepting colonic adenocarcinoma.

- Ultrasound in Obstetrics and Gynecology* 1997 **10** 362–365. (<https://doi.org/10.1046/j.1469-0705.1997.10050362.x>)
- 18 Pellino G, Simillis C, Kontovounisios C, Baird DL, Nikolaou S, Warren O, Tekkis PP & Rasheed S. Colorectal cancer diagnosed during pregnancy. *European Journal of Gastroenterology and Hepatology* 2017 **29** 743–753. (<https://doi.org/10.1097/MEG.0000000000000863>)
 - 19 Stedman KE, Moore GE & Morgan RT. Estrogen receptor proteins in diverse human tumors. *Archives of Surgery* 1980 **115** 244–248. (<https://doi.org/10.1001/archsurg.1980.01380030004002>)
 - 20 Meggouh F, Lointier P & Saez S. Sex steroid and 1,25-dihydroxyvitamin D3 receptors in human colorectal adenocarcinoma and normal mucosa. *Cancer Research* 1991 **51** 1227–1233.
 - 21 Alford TC, Do HM, Geelhoed GW, Tsangaris NT & Lippman ME. Steroid hormone receptors in human colon cancers. *Cancer* 1979 **43** 980–984. ([https://doi.org/10.1002/1097-0142\(197903\)43:3<980::aid-cncr2820430329>3.0.co;2-r](https://doi.org/10.1002/1097-0142(197903)43:3<980::aid-cncr2820430329>3.0.co;2-r))
 - 22 Slattery ML, Samowitz WS & Holden JA. Estrogen and progesterone receptors in colon tumors. *American Journal of Clinical Pathology* 2000 **113** 364–368. (<https://doi.org/10.1309/SMHB-K6XX-QV50-PCJQ>)
 - 23 Dawson PM, Shousha S, Blair SD, Carter GD, Jones J, Alaghband-Zadeh J, Theodorou NA. Oestrogen receptors in colorectal carcinoma. *Journal of Clinical Pathology* 1990 **43** 149–151. (<https://doi.org/10.1136/jcp.43.2.149>)
 - 24 Kidambi TD, Blanco A, Van Ziffle J & Terdiman JP. Constitutional MLH1 methylation presenting with colonic polyposis syndrome and not Lynch syndrome. *Familial Cancer* 2016 **15** 275–280. (<https://doi.org/10.1007/s10689-016-9868-6>)
 - 25 American Cancer Society. Colorectal Cancer Facts and Figures 2017–2019. Atlanta, GA, USA: American Cancer Society, 2017. (available at: <https://www.cancer.org/content/dam/cancer-org/research/cancer-facts-and-statistics/colorectal-cancer-facts-and-figures/colorectal-cancer-facts-and-figures-2017-2019.pdf>)
 - 26 Fedirko V, Tramacere I, Bagnardi V, Rota M, Scotti L, Islami F, Negri E, Straif K, Romieu I, La Vecchia C, *et al.* Alcohol drinking and colorectal cancer risk: an overall and dose-response meta-analysis of published studies. *Annals of Oncology* 2011 **22** 1958–1972. (<https://doi.org/10.1093/annonc/mdq653>)
 - 27 Botteri E, Iodice S, Bagnardi V, Raimondi S, Lowenfels AB & Maisonneuve P. Smoking and colorectal cancer. *JAMA* 2008 **300** 2765–2778. (<https://doi.org/10.1001/jama.2008.839>)
 - 28 Ekobom A, Helmick C, Zack M & Adami HO. Ulcerative colitis and colorectal cancer. *New England Journal of Medicine* 1990 **323** 1228–1233. (<https://doi.org/10.1056/NEJM199011013231802>)
 - 29 Tuohy TMF, Rowe KG, Mineau GP, Pimentel R, Burt RW & Samadder NJ. Risk of colorectal cancer and adenomas in the families of patients with adenomas: a population-based study in Utah. *Cancer* 2014 **120** 35–42. (<https://doi.org/10.1002/cncr.28227>)
 - 30 Pearlman R, Frankel WL, Swanson B, Zhao W, Yilmaz A, Miller K, Bacher J, Bigley C, Nelsen L, Goodfellow PJ, *et al.* Prevalence and spectrum of germline cancer susceptibility gene mutations among patients with early-onset colorectal cancer. *JAMA Oncology* 2017 **3** 464–471. (<https://doi.org/10.1001/jamaoncol.2016.5194>)
 - 31 Yurgelun MB, Kulke MH, Fuchs CS, Allen BA, Uno H, Hornick JL, Ukaegbu CI, Brais LK, McNamara PG, Mayer RJ, *et al.* Cancer susceptibility gene mutations in individuals with colorectal cancer. *Journal of Clinical Oncology* 2017 **35** 1086–1095. (<https://doi.org/10.1200/JCO.2016.71.0012>)
 - 32 Burt RW, DiSario JA & Cannon-Albright L. Genetics of colon cancer: impact of inheritance on colon cancer risk. *Annual Review of Medicine* 1995 **46** 371–379. (<https://doi.org/10.1146/annurev.med.46.1.371>)
 - 33 Thutkawkorapin J, Lindblom A & Tham E. Exome sequencing in 51 early onset non-familial CRC cases. *Molecular Genetics and Genomic Medicine* 2019 **7** e605. (<https://doi.org/10.1002/mgg3.605>)
 - 34 The Cancer Genome Atlas Network. Comprehensive molecular characterization of human colon and rectal cancer. *Nature* 2012 **487** 330–337. (<https://doi.org/10.1038/nature11252>)
 - 35 Kouzmenko AP, Takeyama K-i, Ito S, Furutani T, Sawatsubashi S, Maki A, Suzuki E, Kawasaki Y, Akiyama T, Tabata T, *et al.* Wnt/ β -catenin and estrogen signaling converge in vivo. *Journal of Biological Chemistry* 2004 **279** 40255–40258. (<https://doi.org/10.1074/jbc.C400331200>)
 - 36 Yaeger R, Chatila WK, Lipsyc MD, Hechtman JF, Cercek A, Sanchez-Vega F, Gowtham Jayakumar MS, Zehir A, Donoghue MTA, *et al.* Clinical sequencing defines the genomic landscape of metastatic colorectal cancer. *Cancer Cell* 2018 **33** 125.e3–136.e3. (<https://doi.org/10.1016/j.ccell.2017.12.004>)
 - 37 Gatalica Z, Vranic S, Xiu J, Swensen J & Reddy S. High microsatellite instability (MSI-H) colorectal carcinoma: a brief review of predictive biomarkers in the era of personalized medicine. *Familial Cancer* 2016 **15** 405–412. (<https://doi.org/10.1007/s10689-016-9884-6>)
 - 38 Eberhart CE, Coffey RJ, Radhika A, Giardiello FM, Ferrenbach S & DuBois RN. Up-regulation of cyclooxygenase 2 gene expression in human colorectal adenomas and adenocarcinomas. *Gastroenterology* 1994 **107** 1183–1188. ([https://doi.org/10.1016/0016-5085\(94\)90246-1](https://doi.org/10.1016/0016-5085(94)90246-1))
 - 39 Pollak M. Insulin-like growth factor physiology and cancer risk. *European Journal of Cancer* 2000 **36** 1224–1228. ([https://doi.org/10.1016/S0959-8049\(00\)00102-7](https://doi.org/10.1016/S0959-8049(00)00102-7))
 - 40 Manousos O, Souglakos J, Bosetti C, Tzonou A, Chatzidakis V, Trichopoulos D, Adami HO & Mantzoros C. IGF-I and IGF-II in relation to colorectal cancer. *International Journal of Cancer* 1999 **83** 15–17. ([https://doi.org/10.1002/\(sici\)1097-0215\(19990924\)83:1<15::aid-ijc4>3.0.co;2-y](https://doi.org/10.1002/(sici)1097-0215(19990924)83:1<15::aid-ijc4>3.0.co;2-y))
 - 41 Zeisler H, Llubra E, Chantraine F, Vatish M, Staff AC, Sennström M, Olovsson M, Brennecke SP, Stepan H, Allegranza D, *et al.* Predictive value of the sFlt-1:PlGF ratio in women with suspected preeclampsia. *New England Journal of Medicine* 2016 **374** 13–22. (<https://doi.org/10.1056/NEJMoa1414838>)
 - 42 Holmes DI & Zachary I. The vascular endothelial growth factor (VEGF) family: angiogenic factors in health and disease. *Genome Biology* 2005 **6** 209. (<https://doi.org/10.1186/gb-2005-6-2-209>)
 - 43 Lyall F, Simpson H, Nicola Bulmer J, Barber A & Courtenay Robson S. Transforming growth factor-beta expression in human placenta and placental bed in third trimester normal pregnancy, preeclampsia, and fetal growth restriction. *American Journal of Pathology* 2001 **159** 1827–1838. ([https://doi.org/10.1016/S0002-9440\(10\)63029-5](https://doi.org/10.1016/S0002-9440(10)63029-5))
 - 44 Relf M, Lejeune S, Scott PA, Fox S, Smith K, Leek R, Moghaddam A, Whitehouse R, Bicknell R & Harris AL. Expression of the angiogenic factors vascular endothelial cell growth factor, acidic and basic fibroblast growth factor, tumor growth factor beta-1, platelet-derived endothelial cell growth factor, placenta growth factor, and pleiotrophin in human primary breast cancer and its relation to angiogenesis. *Cancer Research* 1997 **57** 963–969.
 - 45 Taylor RN, Grimwood J, Taylor RS, McMaster MT, Fisher SJ & North RA. Longitudinal serum concentrations of placental growth factor: evidence for abnormal placental angiogenesis in pathologic pregnancies. *American Journal of Obstetrics and Gynecology* 2003 **188** 177–182. (<https://doi.org/10.1067/mob.2003.111>)
 - 46 Wei S-C, Liang J-T, Tsao P-N, Hsieh F-J, Yu SC & Wong J-M. Preoperative serum placenta growth factor level is a prognostic biomarker in colorectal cancer. *Diseases of the Colon and Rectum* 2009 **52** 1630–1636. (<https://doi.org/10.1007/DCR.0b013e3181afbdfaf>)
 - 47 Rasmussen SA, Jamieson DJ & Bresee JS. Pandemic influenza and pregnant women. *Emerging Infectious Diseases* 2008 **14** 95–100. (<https://doi.org/10.3201/eid1401.070667>)
 - 48 ANZIC Influenza Investigators and Australasian Maternity Outcomes Surveillance System. Critical illness due to 2009 A/H1N1 influenza in pregnant and postpartum women: population based cohort study. *BMJ* 2010 **340** c1279. (<https://doi.org/10.1136/bmj.c1279>)

- 49 Richens Y & Gerrard J. Ebola in pregnancy. *British Journal of Midwifery* 2014 **22** 771–775. (<https://doi.org/10.12968/bjom.2014.22.11.771>)
- 50 Mupapa K, Mukundu W, Bwaka MA, Kipasa M, De Roo A, Kuvula K, Kibadi K, Massamba M, Ndaberey D, Colebunders R, *et al.* Ebola hemorrhagic fever and pregnancy. *Journal of Infectious Diseases* 1999 **179** (Supplement 1) S11–S12. (<https://doi.org/10.1086/514289>)
- 51 Adams Waldorf KM & Nelson JL. Autoimmune disease during pregnancy and the microchimerism legacy of pregnancy. *Immunological Investigations* 2008 **37** 631–644. (<https://doi.org/10.1080/08820130802205886>)
- 52 Hedegaard J, Thorsen K, Lund MK, Hein A-MK, Hamilton-Dutoit SJ, Vang S, Nordentoft I, Birkenkamp-Demtröder K, Kruhøffer M, Hager H, *et al.* Next-generation sequencing of RNA and DNA isolated from paired fresh-frozen and formalin-fixed paraffin-embedded samples of human cancer and normal tissue. *PLoS ONE* 2014 **9** e98187. (<https://doi.org/10.1371/journal.pone.0098187>)
- 53 Gerlinger M, Rowan AJ, Horswell S, Math M, Larkin J, Endesfelder D, Gronroos E, Martinez P, Matthews N, Stewart A, *et al.* Intratumor heterogeneity and branched evolution revealed by multiregion sequencing. *New England Journal of Medicine* 2012 **366** 883–892. (<https://doi.org/10.1056/NEJMoa1113205>)

Received in final form 22 May 2019

Accepted 10 July 2019

Accepted Preprint published online 10 July 2019