

Efficiency of an endoscopic resection strategy for management of submucosal tumors < 20 mm in the upper gastrointestinal tract



Authors

Fabrice Caillol¹, Elise Meunier¹, Christophe Zemmour², Jean-Philippe Ratone¹, Jerome Guiramand³, Solene Hoibian¹, Yanis Dahel¹, Flora Poizat⁴, Marc Giovannini¹

Institutions

- 1 Endoscopy Department, Paoli Calmettes Institute, Marseille, France
- 2 Statistics Department, Paoli Calmettes Institute, Marseille, France
- 3 Surgery Department, Paoli Calmettes Institute, Marseille, France
- 4 Pathology Department, Paoli Calmettes Institute, Marseille, France

submitted 22.4.2021

accepted after revision 21.9.2021

Bibliography

Endosc Int Open 2022; 10: E347–E354

DOI 10.1055/a-1783-8675

ISSN 2364-3722

© 2022. The Author(s).

This is an open access article published by Thieme under the terms of the Creative Commons Attribution-NonDerivative-NonCommercial License, permitting copying and reproduction so long as the original work is given appropriate credit. Contents may not be used for commercial purposes, or adapted, remixed, transformed or built upon. (<https://creativecommons.org/licenses/by-nc-nd/4.0/>)

Georg Thieme Verlag KG, Rüdigerstraße 14,
70469 Stuttgart, Germany

Corresponding author

Fabrice Caillol, Endoscopy Department, Paoli Calmettes Institute, 232 bd Ste Marguerite, Marseille 13009, France
Fax: +33401223658
caillolf@ipc.unicancer.fr

ABSTRACT

Background and study aims The histologic diagnosis of submucosal tumors (SMTs) <20 mm is challenging. Monitoring is the main option offered, but compliance is debatable. Endoscopic resection (ER) of malignant SMTs or those with an uncertain diagnosis is an alternative that has already been reported about and proposed in our center. The aims of this study were to confirm the safety of this resection strategy and to perform long-term follow-up of malignant SMTs after resection.

Patients and methods All patients who underwent ER for SMTs <2 cm in a single center between 2007 and 2019 were included retrospectively. Patients were classified into two groups according to the need for postresection follow-up: benign SMTs (B-SMTs) and follow-up SMTs (FU-SMTs).

Results One hundred and one patients were included. The mean tumor size was 16.7 mm. In total, 92 of 101 SMTs had an uncertain diagnosis. Macroscopic resection was completed for 95 SMTs (93.1%), with en bloc resection in 94 (92.1%). The morbidity rate was 3%, with no mortality. A total of 84 of 101 SMTs (84%) were B-SMTs and did not need monitoring, and 17 SMTs (19.7%) were FU-SMTs (8 gastrointestinal stromal tumors, 6 neuroendocrine tumors, and 3 others). No relapse was reported in the FU-SMT group, with a median follow-up duration of 33 months [4–127] (61 months [17–127] for the gastrointestinal stroma tumor group).

Conclusions The study results suggest ER is a potentially reliable and effective strategy for upper gastrointestinal tract SMTs <20 mm. Although the strategy needs further validation in advanced care units, it could eliminate the need for long-term monitoring, therefore targeting such follow-up efforts to patients with FU-SMTs.

Introduction

Submucosal tumors (SMTs) are lesions of the digestive tract lining beneath the epithelium. Greater knowledge and technical progress have enabled an increase in the detection rate for esophagogastric or duodenal lesions, with a reported incidence

of 0.76% [1]. SMTs can include tumors with potential malignant behavior, such as gastrointestinal stromal tumors (GISTs) and neuroendocrine tumors (NETs) (to be monitored or resected), or benign tumors, such as leiomyomas, lipomas or ectopic pancreatic tumors (not to be monitored) [2]. Differentiating malig-

nant (or potentially malignant) and benign SMTs can be challenging and yet essential for follow-up.

A morphologic echo-endoscopic (EUS) evaluation (size, echogenicity, and layer location) is helpful in typical cases, with an EUS diagnostic accuracy of 88.3% for SMTs with a mean size of 25 mm. However, it may not be sufficient for smaller tumors, with an accuracy of 45% for SMTs with a mean size of 13.6 mm (range 8 to 20 mm) [3, 4]. Pathology can be obtained with endoscopic ultrasound-guided fine-needle aspiration (EUS-FNA), with a low rate of adverse events (AEs), ranging from <1% to 2.5% [5, 6]. However, their accuracy is not excellent, with a pooled rate of 59.9% [7]. The accuracy of EUS-FNA for a mean tumor size of 21 mm ranges from 49% [8] to 78% [4], while that of EUS-guided fine-needle biopsy (EUS-FNB) ranges from 76% [9] to 88% [10]. However, EUS-FNA is possible in only 46% of gastric SMTs with a mean size of 20 mm [11].

Diagnostic doubt, therefore, may persist after the initial assessment. As a result, many SMTs (benign and malignant) require regular endoscopic monitoring. Because compliance with follow-up guidelines is poor [12, 13], a monitoring strategy can be questioned.

Therefore, the policy of our unit is to perform endoscopic resection (ER) for small SMTs with a malignant diagnosis and small SMTs with an uncertain diagnosis, as reported previously [14] or proposed by some authors [3].

The aim of this study was to confirm the safety of these resection strategies and to perform long-term follow-up on malignant SMTs after resection.

Patients and methods

We conducted a single-center, retrospective study between September 2007 and January 2019 (study: YELLOW SUBMUCOSA 2-IPC 2019-013). The inclusion criteria were patients who underwent ER of SMTs located in the upper gastrointestinal tract. Computer search software in which artificial intelligence is used (CONSOE) was used to select patients with the keywords “submucosal tumor” and “endoscopic resection.” Patient data were collected from computerized medical records. Missing data and recent follow-up data were collected by questioning the patients’ general practitioners and gastroenterologists. Data collection was anonymous and performed by a practitioner in the unit, though not one of the endoscopists working in the unit.

The pretherapeutic data collected were patient birthdate, sex, American Society of Anesthesiologists score, tumor size, EUS evaluation, and suspected diagnosis. The peritherapeutic data collected were the type of technical resection performed (endoscopic mucosal resection [EMR], endoscopic submucosal dissection [ESD], or hybrid resection [HR] that combined ESD at the edges of the lesion followed by EMR for final central resection), endoscopic success (complete and one-piece characteristics of ER evaluated by the operator) and AEs (morbidity and mortality). The post-therapeutic data collected were the histological results, quality of lateral and vertical histological margins of the tumors, need for a complementary treatment

(endoscopic, medical or surgical), relapses, and malignant lesion follow-up.

R0 was defined as a microscopically negative margin that did not require a free edge of 1 mm. R1 was defined as a microscopically positive margin. If the pathologist was not confident in determining the resection margin to be free of tumor, it was reported as doubtful. If the margin of resection was not read, the margin was referred to as not reported.

Biopsy and the method of resection did not conform to protocols and were decided upon by the practitioner. The indication for ER was an uncertain diagnosis with patient assent or a malignant diagnosis.

Complications before and after endoscopy as well as their management were reported and graded according to the Clavien-Dindo classification [15]. Morbidity was defined as the rate of complications in the month following ER. Mortality was defined as the rate of death in the month following ER. Follow-up began the day of ER.

Based on definitive histology, patients were classified into two groups according to the need for postresection monitoring: benign SMTs (B-SMTs) and follow-up SMTs (FU-SMTs).

This study was conducted and monitored under institutional review board approval.

Data are summarized as counts and frequencies for categorical endpoints and as medians [min-max] or means (standard deviations) for quantitative endpoints. Frequencies were determined on the basis of available data for the selected characteristic.

Results

Preoperative assessment

One hundred and one patients (53 women, median age 60 years) who underwent ER of SMTs were included. The mean EUS tumor size was 16.7 mm (range 6 to 35 mm). Patient baseline characteristics are summarized in ► **Table 1**. The locations of the tumors were the stomach (n=67, 65.7%), duodenum (n=20, 19.6%), and esophagus (n=15, 14.7%). Fifty-seven (55.9%) SMTs were found in the third EUS layer.

Biopsy was performed in 37 patients (36.3%) (► **Fig. 1**). In 27 of 37 patients, biopsies did not give adequate samples. In only 10 of 102 patients, SMTs with a pretherapeutic diagnosis were removed (2 NETs, 3 GISTs, 1 lesion with low-grade dysplasia, and 2 esophageal granular cell tumors) at patient request. In 92 of 102 patients, SMTs were removed because of an uncertain diagnosis. On endoscopic and EUS data, the diagnosis of GISTs was suspected for 19 of 92 SMTs, and the diagnosis of NETs was suspected for 22 of 92 SMTs.

Perioperative assessment

EMR was performed on 46 patients (46%), ESD on 32 (32%), and HR on 23 (23%). Macroscopic resection was completed for 95 patients (94%), with en bloc resection in 94 (93%) (► **Table 2**).

Periendoscopic bleeding occurred in 11 patients (10.9%) treated with hot biopsy forceps and in one patient treated with puraStat. Eight cases were in the stomach, two were in

► **Table 1** Pretherapeutic assessment.

Characteristic		Statistics
Sex	Female	53 (51.96%)
	Male	48 (48.04%)
Median age [min–max]		60 [22–85]
ASA score	1	38 (37.6%)
	2	46 (45.5%)
	3	16 (16.8%)
Location	Gastric	66 (65.7%)
	Esophagus	15 (14.7%)
	Duodenum	20 (19.6%)
Median size on EUS (range)		15 (6–35)
Median pathology sign (range)		12 (5–38)
Biopsy		37 (37%)

ASA, American Society of Anesthesiologists; EUS, endoscopy ultrasound.

► **Table 2** Pretherapeutic assessment (resection results) in all patients and those with FU-SMTs.

Characteristic		All (n=101)	FU-SMTs (n=17)
Endoscopic resection	ESD	32 (32%)	9 (50%)
	EMR	46 (46%)	4 (25%)
	HR	23 (23%)	4 (25%)
ESD material	Dual Knife	23 (54.8%)	7
	Flex Knife	11 (26.2%)	4
	It Knife	6 (14.3%)	1
	Sumius Sb Knife	2 (4.7%)	1
Macroscopic complete endoscopic resection		95 (94%)	17 (100%)
Piece meal resection		3 (2.9%)	2 (12%)
En bloc resection		94 (93%)	15 (85%)

FU-SMT, follow-up submucosal tumor; ESD, endoscopic submucosal dissection; EMR, endoscopic mucosal resection.

the duodenum, and one was in the esophagus. No patient required transfusion. A perforation (target sign) was preventively treated with a clip. Standard resection without complications was considered because perioperative bleeding and preventive closure are classically not considered complications if there is no consequence for the patient.

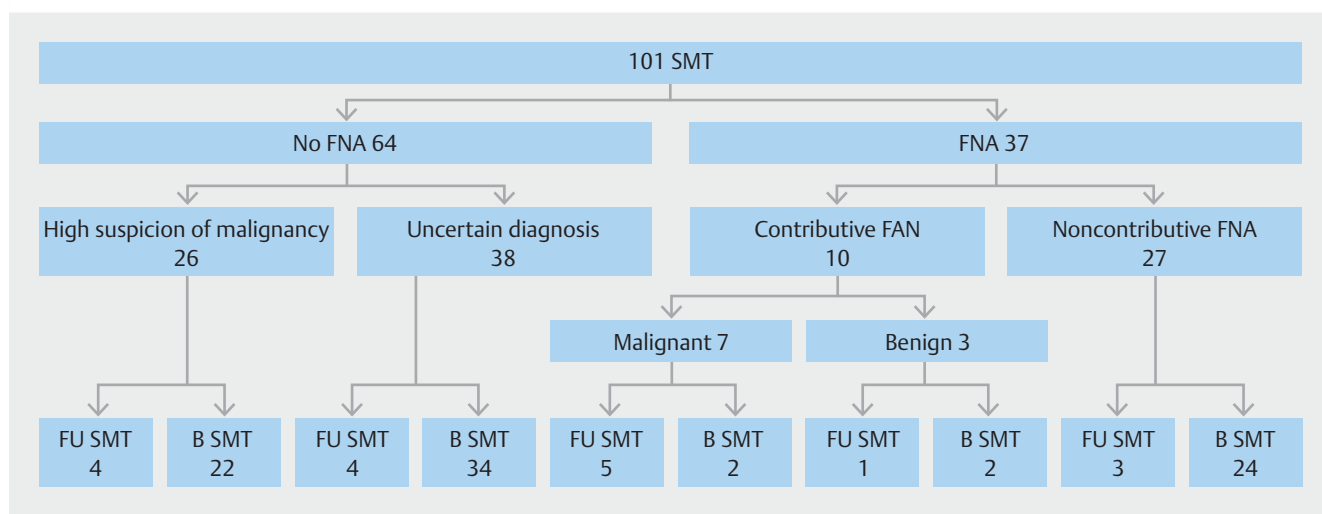
The morbidity rate was 3% (3 of 101), with no mortality. One grade IIIB complication (requiring intervention under general anesthesia) was reported because delayed bleeding (J10) required a new endoscopic intervention (a clip and Hemospray). Two grade I complications (no deviation from the normal postoperative course) (2 type IV gastric perforations) were reported and managed with a perioperative clip and antibiotics, and the patients were discharged from the hospital the day after resec-

tion. One of these patients also experienced a grade 1 anaphylactic reaction to amoxicillin clavulanate.

Postoperative assessment

Eighty-four (83%) of the 101 SMTs were benign lesions (B-SMTs), and 17 (17%) were malignant tumors or had uncertain malignant evolution (FU-SMTs). A duodenal surgical specimen could not be recovered after resection and was considered a malignant lesion. The histological assessment results and anatomical locations of B-SMTs and FU-SMTs are summarized in ► **Table 3** and ► **Table 4**.

In the case of no FNA attempt, the sensitivity for malignancy was 50%, the specificity was 62%, and the accuracy was 60%. In



► **Fig. 1** Flowchart of SMT <2 cm with uncertain diagnosis.

► **Table 3** Histological diagnosis according to SMT location.

Histological diagnosis		Duodenum (n = 20)	Stomach (n = 66)	Esophagus (n = 15)
M-SMT	GIST		7 (10.5%)	1 (7%)
	NET	3 (15%)	3 (4.5%)	
	Synovial sarcoma		1 (1.5%)	
	Lost lesion	1 (5%)		
	Metaplasia		1 (1.5%)	
B-SMT	Focal inflammatory tissue	1 (5%)	16 (23.9%)	
	Ectopic pancreas	1 (5%)	13 (19.4%)	
	Leiomyoma	1 (5%)	6 (9%)	4 (27%)
	Esophageal granular cell tumor			10 (67%)
	Inflammatory fibrous polyp	1 (5%)	9 (13.4%)	
	Brunner's gland hyperplasia	7 (35%)		
	Lipoma	4 (20%)	2 (3%)	
	Hyperplasic polypoid		3 (4.5%)	
	Schwannoma		1 (2%)	
Other ¹	1 (5%)	4 (6%)		

SMT, submucosal tumor; M-SMT, malignant submucosal tumor; GIST, gastrointestinal stromal tumor; NET, neuroendocrine tumor; B-SMT, benign submucosal tumor.

¹ Hamartoma, lymphangioma, calcifying fibrous tumor, duodenum duplication, fibrinoid tumor, angioma.

► **Table 4** Ultrasonography location in the gastrointestinal wall according to the original layer on EUS.

Histological diagnosis		Indeterminate (n = 34)	Muscularis propria (n = 11)	Submucosa (n = 57)
M-SMT	GIST	3 (8.8%)	2 (18.2%)	3 (5.3%)
	NET		1 (9.1%)	5 (8.8%)
	Synovial sarcoma	1 (2.9%)		
	Lost lesion			1 (1.8%)
	Metaplasia			1 (1.8%)
B-SMT	Focal inflammatory tissue	7 (20.6%)		10 (17.5%)
	Ectopic pancreas	5 (14.7%)		9 (15.7%)
	Leiomyoma	4 (11.8%)	3 (27.3%)	4 (27.3%)
	Abrikosoff tumor	6 (17.7%)		4 (7%)
	Inflammatory fibrous polyp	1 (2.9%)	1 (9.1%)	8 (14%)
	Brunner's gland hyperplasia	2 (5.9%)		5 (8.8%)
	Lipoma	2 (5.9%)	1 (9.1%)	3 (5.3%)
	Hyperplasic polypoid		1 (9.1%)	2 (3.5%)
	Schwannoma		1 (9.1%)	
Other ¹	3 (8.8%)	1 (9.1%)	2 (1.8%)	

EUS, endoscopic ultrasound; M-SMT, malignant submucosal tumor; B-SMT, benign submucosal tumor.

four of 38 cases, a benign lesion was suspected on EUS data, while ER revealed malignant tumors. In 22 of 26 cases, malignancy was suspected on EUS data, while ER revealed benign tumors. The diagnosis of three of eight GISTs was not suspected on EUS data (one ectopic pancreas and 2 SMTs without a diagnosis). Of the six NETs resected, one was confused with a GIST on EUS data. Among the 10 SMTs with preoperative histology resected, two were false positive (one inflammatory mucosa mistaken for low-grade dysplasia and one inflammatory mucosa mistaken for a GIST).

In the FU-SMT group, macroscopic resection was complete for all patients, with en bloc resection in 15 of 17 (85%). One GIST that underwent en bloc resection was split into 13 fragments during recovery of the endoscopic specimen. En bloc resection was performed for four of six NETs (66.6%) (► **Table 2**). Resection characteristics were available for 16 of 17 patients. The initial histological resection revealed R0 for both lateral and vertical margins in nine patients (53%), R1 in four patients, and unknown in four patients. Regarding GISTs, three of eight were R0, two were R1, and three were unknown. Concerning NETs, two of six were R1 in the vertical margin and six of six had free lateral margins. Two patients underwent partial gastrectomy: one for an intermediate-risk gastric GIST (6 of 50 mitoses; Ki-67 10%) and one for a gastrinoma G2 NET (Ki-67 3%). A patient with a G1 type 1 NET (gastric chronic gastritis) that was R1 underwent endoscopic re-excision of the scar 2 months later without a residual tumor on the final report. One patient with a GIST at a low risk of recurrence but an R1 vertical margin who refused surgery was treated with endoscopic re-excision of the scar and a 36-month course of imatinib (without a residual tumor).

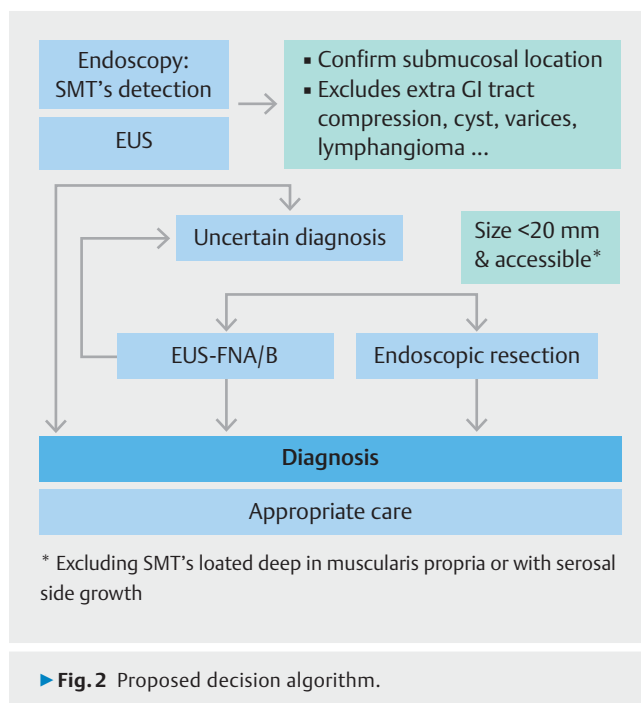
In the B-SMT group, two symptomatic relapses were noted: one patient developed anemia 1 year after he underwent HR for a hyperplastic polyp and one patient developed a hemorrhage on a recurrent hamartoma 2 years after the initial resection.

In the FU-SMT group, after a median follow-up duration of 33 months [4–127], no recurrence was found.

According to the Fletcher and Joensuu classification, seven GISTs had a low or very low risk of recurrence, and one had an intermediate risk of recurrence. Of the seven GISTs followed after ER and one after endoscopic and surgical resection, no recurrence occurred after a median follow-up duration of 61 months [17–127].

Discussion

Our study highlights that the rate of benign lesions is high (80%, 82 of 101) for SMTs <2 cm after an inconclusive EUS evaluation and an uncertain diagnosis. However, even though this rate of benign lesions is high, malignant lesions could be undiagnosed, so follow-up remains necessary. The final diagnosis obtained with ER in our series was safe (morbidity <3%). Patients with benign lesions are no longer followed up, and our follow-up period for malignant lesions was probably long enough to conclude that ER for malignant lesions is not an oncologic issue. A new strategy for SMT <2 cm could be proposed (► **Fig. 2**).



► **Fig. 2** Proposed decision algorithm.

An EUS evaluation for small SMTs is not reliable according to the literature [3, 4, 16]. Contrast-enhanced harmonic endoscopy has a diagnostic accuracy that ranges from 60% to 89% for discriminating benign SMTs and GISTs >30 mm. Nevertheless, its value for smaller tumors is probably not as reliable because of the lack of enhancement on smaller SMTs [17, 18]. The muscularis propria (fourth layer) is the main site of GIST. However, localization in the muscularis mucosae (third layer) is also possible, increasing diagnostics difficulties for GIST [19].

EUS diagnosis

The accuracy of EUS is debatable. We included only SMTs with an uncertain diagnosis, which decreased the accuracy because many typical lipomas (4% in our study vs 14% in the literature) [18] or cases of ectopic pancreas were excluded. Therefore, the accuracy of EUS represents the accuracy when the operator is not certain of the diagnosis (i.e., an uncertain diagnosis is recorded). Moreover, ER of SMTs was left to the discretion of the operators. Some SMTs were followed up, but data for these patients were not available. The retrospective design is a limitation of the current study.

Our low rate of EUS biopsies (37%) could be explained by the small size of the lesions. We must keep in mind that the feasibility of EUS-FNA is low (46%) because of the sizes and locations of SMTs [11]. Incisional biopsies were not performed. Incisional or stacked biopsy offers greater accuracy (90%) for tumors with a mean size ranging from 20.3 mm to 25 mm [8], but their AE rate can reach 10% [9].

The grade and management of NETs are based on the Ki-67 index. ER is recommended for type 1 gastric NETs and shows excellent overall outcomes, since the 24-month recurrence-free survival rate is 100%. The ER approach allows proper discrimination between aggressive g-NETs and others for which

curative treatment with ER is an option. In our study, two of four NETs had an underestimated Ki-67 index and one had an underestimated grade (G1 on biopsy, G2 on the surgical specimen) [20,21].

For duodenal NETs, optimal management has long been debated because their natural history is poorly understood. ER has proven effective and safe for lesions <10 mm and is an option for tumors <20 mm if the lesions are confined to the submucosal layer and without lymph node or distant metastasis. ER is mostly curative because 50% to 75% of d-neuroendocrine neoplasms (NENs) are well differentiated; otherwise, ER provides complete histology and appropriate management [21]. A limitation of this management is the low rate of endocrine tumors. We only took into account NET with negative standard biopsies. And most of NETs can be diagnosed with standard biopsies.

GISTs are rare, with an incidence of 10 to 15 per million per year [22], but they are the most common mesenchymal tumors in the gastrointestinal tract. GISTs are a poorly known type of tumor with an unpredictable and variable evolution and prognosis. The latest European standard recommendations consist of an endoscopic ultrasound assessment and conservative lifelong follow-up because of the potential for malignancy evolution. Excision is recommended when a tumor increases in size or becomes symptomatic [23]. On one hand, we know that microGISTs (1.5 mm) are not rare and detected in 35% of patients in surgical series of 100 patients with gastrectomy [24]. On the other hand, we know that 8.5% to 25% of upper gastrointestinal SMTs 30 mm and 55% of gastric GISTs >9.5 mm show significant size increments at median follow-ups of 24, 30, and 36 months, respectively [25,26]. Their growth is not linear and can occur up to 60 months after detection [1]. However, an evidence-based optimal surveillance policy is lacking, and compliance with follow-up guidelines is poor: Only 45% of patients complete follow-up after 17 or 30 months [12,13]. GISTs with a diameter <20 mm and a mitotic index <5 of 50 high-power fields are not believed to present any risk of lymph node extension regardless of their anatomical location [27,28]. As a result, because of a potential uncertain diagnosis, patients lost to follow-up, and high potential for evolution, early endoscopic management is challenging.

R1 resection seems to have no influence on disease-free survival or the recurrence of GISTs [29–32]. As a result, an R1 resection margin that is noninterpretable does not seem to be a carcinologic issue. Avoiding pseudocapsule rupture seems more important than R0 resection [29]. Pseudocapsule rupture is an independent poor prognostic factor for GISTs with a high risk of peritoneal or hepatic recurrence [33]. Digestive spread probably presents less of a risk. In our experience, R0 was not obtained for all cases, and one GIST that underwent en bloc resection was split into 13 fragments during recovery of the endoscopic specimen. An R1 or doubtful margin should not impact carcinologic issues in the case of en bloc resection, and fragmentation of a GIST during recovery probably has little impact because ER occurs in the lumen of the digestive tract but is a limitation and should be avoided. A major limitation of ER is the type of GIST. GISTs can be classified according to their location in the gastric wall: type I GISTs are those with a very narrow

connection with the proper muscle layer and protrude into the luminal side like a polyp; type II GISTs have a wider connection with the proper muscle layer and protrude into the luminal side at an obtuse angle; type III GISTs are located in the middle of the gastric wall; and type IV GISTs protrude mainly into the serosal side of the gastric wall [34]. Complete ER of small type I and II and accessible type III GISTs for treatment is acceptable. Inaccessible GISTs were excluded from our study, which is a limitation.

The retrospective design of the present study limited the resection specimens. ER was performed when it was possible. GIST type III were not resected and we do not know in how many cases GISTs were type III. Only malignant lesions or lesions with uncertain diagnosis were resected. Therefore, sensitivity and specificity of pretherapeutic assessment was difficult to evaluate. As a result, conclusion, about management with ER of TSM have to made cautiously.

Another limitation was the inclusion of mixed esophageal, stomach, and duodenal lesions. Complications of resection are not the same, duodenal resection must be done very carefully, and frequency of pathological piece resection differs depending on lesion location. This should be investigated further with more patients.

The protocol for ER was left at to endoscopist discretion and evolved from the beginning of the study to the end of the study. ESD started being performed in the unit in 2006 and improvements in the technique are ongoing. That could be a limitation because all these procedures represented in the present study probably should have been performed by ESD. Performing ESD should improve ER and avoid piecemeal resection of malignant lesions. Endoscopic full-thickness resection or tunneling techniques may be options but they were not used in this study. Those options may be chosen, depending on lesion location (esophagus, stomach, duodenum) [35].

The strengths of this study are the 4-year duration and the good level of compliance. The risk of recurrence after surgery is highest within 2 years, and the majority of recurrences occurred within 5 years, but recurrences after 10 years are possible [36]. Therefore, longer follow-up is needed. Diagnostic ER should be studied prospectively to validate its safety and efficacy.

Conclusions

This retrospective observational study suggests that ER for upper gastrointestinal tract SMTs <20 mm is a potentially reliable and effective strategy. Given the insufficient accuracy of EUS or biopsy, ER might be an option for both complete histological examination and definitive cure of malignant lesions. The morbidity rate in selected cases seems to be low in expert' hands. Although this strategy is not yet considered standard management and needs further validation in advanced care units, its use has potential to eliminate monitoring of benign lesions.

Competing interests

Marc Giovannini is a consultant for Cook medical and Pentax.
Fabrice Caillol received honorary from Ambu.

References

- [1] Lim YJ, Son HJ, Lee J-S et al. Clinical course of subepithelial lesions detected on upper gastrointestinal endoscopy. *World J Gastroenterol* 2010; 16: 439–444
- [2] Gong EJ, Kim DH. Endoscopic ultrasonography in the diagnosis of gastric subepithelial lesions. *Clin Endosc* 2016; 49: 425–433
- [3] Karaca C, Turner BG, Cizginer S et al. Accuracy of EUS in the evaluation of small gastric subepithelial lesions. *Gastrointest Endosc* 2010; 71: 722–727
- [4] Seo SW, Hong SJ, Han JP et al. Accuracy of a scoring system for the differential diagnosis of common gastric subepithelial tumors based on endoscopic ultrasonography. *J Dig Dis* 2013; 14: 647–653
- [5] de Moura DTH, McCarty TR, Jirapinyo P et al. EUS-guided fine-needle biopsy versus fine-needle aspiration in the diagnosis of subepithelial lesions: a large multicenter study. *Gastrointest Endosc* 2020; 92: 108–119.e3
- [6] Polkowski M, Larghi A, Weynand B et al. Learning, techniques, and complications of endoscopic ultrasound (EUS)-guided sampling in gastroenterology: European Society of Gastrointestinal Endoscopy (ESGE) Technical Guideline. *Endoscopy* 2012; 44: 190–206
- [7] Zhang X-C, Li Q-L, Yu Y-F et al. Diagnostic efficacy of endoscopic ultrasound-guided needle sampling for upper gastrointestinal subepithelial lesions: a meta-analysis. *Surg Endosc* 2016; 30: 2431–2441
- [8] Mekky MA, Yamao K, Sawaki A et al. Diagnostic utility of EUS-guided FNA in patients with gastric submucosal tumors. *Gastrointest Endosc* 2010; 71: 913–919
- [9] Sanaei O, Fernández-Esparrach G, De La Serna-Higuera C et al. EUS-guided 22-gauge fine needle biopsy versus single-incision with needle knife for the diagnosis of upper gastrointestinal subepithelial lesions: a randomized controlled trial. *Endosc Int Open* 2020; 8: E266–E273
- [10] Hedenstrom P, Marschall HU, Nilsson B et al. High clinical impact and diagnostic accuracy of EUS-guided biopsy sampling of subepithelial lesions: a prospective, comparative study. *Surg Endosc* 2018; 32: 1304–1313
- [11] Eckardt AJ, Adler A, Gomes EM et al. Endosonographic large-bore biopsy of gastric subepithelial tumors: a prospective multicenter study. *Eur J Gastroenterol Hepatol* 2012; 24: 1135–1144
- [12] Kushnir VM, Keswani RN, Hollander TG et al. Compliance with surveillance recommendations for foregut subepithelial tumors is poor: results of a prospective multicenter study. *Gastrointest Endosc* 2015; 81: 1378–1384
- [13] Lok K-H, Lai L, Yiu H et al. Endosonographic surveillance of small gastrointestinal tumors originating from muscularis propria. *J Gastrointest Liver Dis* 2009; 18: 177–180
- [14] Godat S, Robert M, Caillol F et al. Efficiency and safety of endoscopic resection in the management of subepithelial lesions of the stomach. *United Europ Gastroenterol J* 2016; 4: 250–256
- [15] Clavien PA, Vetter D, Staiger RD et al. The Comprehensive Complication Index (CCI(R)): added value and clinical perspectives 3 years "Down the Line". *Ann Surg* 2017; 265: 1045–1050
- [16] Pesenti C, Bories E, Caillol F et al. Characterization of subepithelial lesions of the stomach and esophagus by contrast-enhanced EUS: A retrospective study. *Endosc Ultrasound* 2019; 8: 43–49
- [17] Tang JY, Tao KG, Zhang LY et al. Value of contrast-enhanced harmonic endoscopic ultrasonography in differentiating between gastrointestinal stromal tumors: A meta-analysis. *J Dig Dis* 2019; 20: 127–134
- [18] Landi B, Palazzo L. The role of endosonography in submucosal tumours. *Best Pract Res Clin Gastroenterol* 2009; 23: 679–701
- [19] Nishida T, Goto O, Raut CP. Diagnostic and treatment strategy for small gastrointestinal stromal tumors. *Cancer* 2016; 122: 3110–3118
- [20] Grillo F, Valle L, Ferone D et al. KI-67 heterogeneity in well differentiated gastro-entero-pancreatic neuroendocrine tumors: when is biopsy reliable for grade assessment? *Endocrine* 2017; 57: 494–502
- [21] Fave GD, O'Toole D, Sundin A et al. ENETS Consensus Guidelines Update for Gastroduodenal Neuroendocrine Neoplasms. *Neuroendocrinology* 2016; 103: 119–124
- [22] Søreide K, Sandvik OM, Søreide JA et al. Global epidemiology of gastrointestinal stromal tumours (GIST): A systematic review of population-based cohort studies. *Cancer Epidemiol* 2016; 40: 39–46
- [23] Casali PG, Abecassis N, Bauer S et al. Gastrointestinal stromal tumours: ESMO-EURACAN Clinical Practice Guidelines for diagnosis, treatment and follow-up. *Ann Oncology* 2018; 29: iv68–iv78
- [24] Kawanowa K, Sakuma Y, Sakurai S et al. High incidence of microscopic gastrointestinal stromal tumors in the stomach. *Hum Pathol* 2006; 37: 1527–1535
- [25] Gao Z, Wang C, Xue Q et al. The cut-off value of tumor size and appropriate timing of follow-up for management of minimal EUS-suspected gastric gastrointestinal stromal tumors. *BMC Gastroenterol* 2017; doi:10.1186/s12876-016-0567-4
- [26] Kim M-Y, Jung H-Y, Choi KD et al. Natural history of asymptomatic small gastric subepithelial tumors. *J Clin Gastroenterol* 2011; 45: 330–336
- [27] Miettinen M, Lasota J. Gastrointestinal stromal tumors: pathology and prognosis at different sites. *Semin Diagn Pathol* 2006; 23: 70–83
- [28] Fletcher CDM, Berman JJ, Corless C et al. Diagnosis of gastrointestinal stromal tumors: A consensus approach. *Hum Pathol* 2002; 33: 459–465
- [29] McCarter MD, Antonescu CR, Ballman KV et al. Microscopically positive margins for primary gastrointestinal stromal tumors: analysis of risk factors and tumor recurrence. *J Am Coll Surg* 2012; 215: 53–59
- [30] Kim SG. Interpretation of pathologic margin after endoscopic resection of gastrointestinal stromal tumor. *Clin Endosc* 2016; 49: 229–231
- [31] Joo MK, Park J-J, Kim H et al. Endoscopic versus surgical resection of GI stromal tumors in the upper GI tract. *Gastrointest Endosc* 2016; 83: 318–326
- [32] Dai W-J, Liu G, Wang M et al. Endoscopic versus laparoscopic resection of gastric gastrointestinal stromal tumors: a multicenter study. *Oncotarget* 2017; 8: 11259–11267
- [33] Joensuu H, Vehtari A, Riihimäki J et al. Risk of recurrence of gastrointestinal stromal tumour after surgery: an analysis of pooled population-based cohorts. *Lancet Oncol* 2012; 13: 265–274
- [34] Kim HH. Endoscopic treatment for gastrointestinal stromal tumor: Advantages and hurdles. *World J Gastrointest Endosc* 2015; 7: 192–205
- [35] Aslanian HR, Sethi A, Bhuthani MS et al. ASGE guideline for endoscopic full-thickness resection and submucosal tunnel endoscopic resection. *VideoGIE* 2019; 29: 343–350
- [36] DeMatteo RP, Lewis JJ, Leung D et al. Two hundred gastrointestinal stromal tumors: recurrence patterns and prognostic factors for survival. *Ann Surg* 2000; 231: 51–58

CORRECTION**Efficiency of an endoscopic resection strategy in the management of submucosal tumors less than 20 mm in size and located in the upper gastrointestinal**

Fabrice Caillol, Elise Meunier, Cristophe Zemmour, Jean-Philippe Ratone, Jerome Guiramand, Christian Pesenti, Solene Hoibian, Yanis Dahel, Mariola Marx, Florat Poizat, Marc Giovannini.

Endoscopy International Open 2022; 10: E347–E353.

DOI: 10.1055/a-1783-8675

In the above-mentioned article an author's given name was corrected. This was corrected in the online version on April 27 2022.