

CASE REPORT

Parosteal osteosarcoma: Report of a rare juxtacortical variant of osteosarcoma affecting the maxilla

Surekha Rudrayya Puranik, Rudrayya Shivanand Puranik¹, Praveen Kumar Ramdurg, Gunjan Ram Chandra Choudhary

Departments of Oral Medicine and Radiology and ¹Oral Pathology and Microbiology, P. M. Nadagowda Memorial Dental College and Hospital, Bagalkot, Karnataka, India

Address for correspondence:

Dr. Surekha Rudrayya Puranik,
Department of Oral Medicine and Radiology,
P. M. Nadagowda Memorial Dental College and
Hospital, Bagalkot - 587 101, Karnataka, India.
E-mail: puraniksuekha19@rediffmail.com

Received: 28-06-2014

Accepted: 08-01-2015

ABSTRACT

Parosteal osteosarcomas are rare, low-grade juxtacortical variant of osteosarcoma, especially in the jaws, representing 1.6% of all bony malignant tumours and upto 5% of all osteosarcomas. Only 12 cases of intraoral parosteal osteosarcomas have been reported in the English literature. In the jaws males are more commonly affected with peak occurrence at 39 years and nearly equal site predilection for maxilla and mandible. Radiographically, parosteal osteosarcomas are radiodense, lobulated masses with a broad stalk to the cortex of the bone with no periosteal reaction and medullary invasion. Microscopically, shows well-differentiated tumor with minimum atypia and rare mitotic figures separating trabeculae of woven bone. Unlike classical and periosteal osteosarcoma, it is considered to have a good prognosis. A case report of this rare entity in 22-year-old female patient with bony hard, painless swelling of 9 months duration in maxillary premolar–molar region is presented. The need for differential diagnostic approach is emphasized from other seemingly benign clinical entities.

Key words: Benign osseous lesions, jaw surface tumors, juxtacortical osteosarcoma, low grade, parosteal osteosarcoma

INTRODUCTION

Osteosarcoma is a malignancy of mesenchymal cells that have the ability to produce osteoid or immature bone.^[1] Osteosarcoma of the head and neck is relatively rare and constitutes only around 8.4% of all osteosarcomas, while in the jaw there is an estimated incidence of 0.7 per million population.^[2] Gnathic osteosarcomas are broadly categorized into central (intramedullary) and peripheral (surface) subtypes. Surface tumors are further divided into parosteal well-differentiated (low-grade), periosteal low- to intermediate-grade and high-grade surface osteosarcomas.^[3,4]

In 1949, Geschickter and Copeland were the first to describe parosteal osteosarcomas under the heading of “parosteal osteoma” a group of parosteal bone tumors of which the

seemingly benign clinical and histologic aspect was belied by frequent relapse and metastasis. Unni *et al.*, defined the juxtacortical osteosarcoma as “a distinctive type of malignant bone tumor that originates on external surface of the bone specifically in relation to periosteum and/or immediate connective tissue.” The first report of parosteal osteosarcoma in craniofacial site was reported in 1961 by Som and Peimer.^[2,5]

It has predilection to occur in the 2nd and 4th decade mainly affecting distal femur. In the long bones females have a greater risk than men (3:2), whereas in jaws men are more affected as (1.75:1) compared to women. In the jaws it has nearly equal site predilection for maxilla and mandible (1.2:1). It can be mistaken for benign lesions as the clinical behavior and radiographic appearances are usually benign.^[2,6,7]

Histologically, parosteal osteosarcoma is well-differentiated and is characterized by spindle cell stroma with minimal atypia and rare mitotic figures separating irregular trabeculae of woven bone. They are considered to have a favorable prognosis compared to conventional and periosteal osteosarcomas.^[8-10] Parosteal osteosarcoma of craniofacial area behave similar to long bone counterparts with slow growth and low grade malignancy that do not tend to metastasize.

Access this article online

Quick Response Code:



Website:
www.jomfp.in

DOI:
10.4103/0973-029X.151340

This paper describes a case of parosteal osteosarcoma and emphasizes the need for differential diagnosis of this rare entity with benign reactive and neoplastic osseous lesions.

CASE REPORT

A 22-year-old female patient presented with the complaint of swelling in the right side of the face since 9 months, which was not associated with pain, discharge or neurological symptoms. It had gradually increased to present size. On extraoral examination, diffuse swelling of about 4 × 4 cm in midface region was noted on the right side of the face. Intraorally, swelling involved right maxillary buccal aspect of the ridge from second premolar to third molar measuring around 3.5 × 2.5 cm in dimensions, extending anterioposteriorly from the mesial aspect of maxillary second premolar to distal aspect of third molar and superioinferiorly from the marginal gingival level to the vestibule causing obliteration, without any palatal expansion. Overlying mucosa was slightly erythematous. On palpation, the swelling was bony hard and nontender [Figure 1]. Adjacent teeth were vital with no mobility, tenderness or displacement. Lymph nodes were nontender and nonpalpable. Provisional diagnosis of benign osseous lesion was rendered.

Occlusal radiograph revealed dome-shaped swelling with radiopaque shadow and patchy radiopacity on buccal aspect of maxilla [Figure 2]. Few striae of trabeculae were evident at lower border. Axial and coronal computed tomography (CT) scans revealed well-defined, hyperdense bony mass with patchy radiopacity emanating from the buccal cortical plate with broad base. It appeared slightly denser at the base than periphery. Cortical and medullary erosion was not evident [Figure 3a and b]. Three-dimensional CT (3D-CT) showed lobulated exophytic bony mass attached with broad base to the buccal cortical plate formed by the network of multiple inter coalescing striae of trabeculae [Figure 3c]. CT chest was taken and metastasis was ruled out. Hematological and biochemical tests were within normal range. An incisional biopsy was done for the lesion and sent for Histopathological analysis. The H and E stained sections showed parallel array of bony trabeculae in a background of spindle cells and angular cells which showed

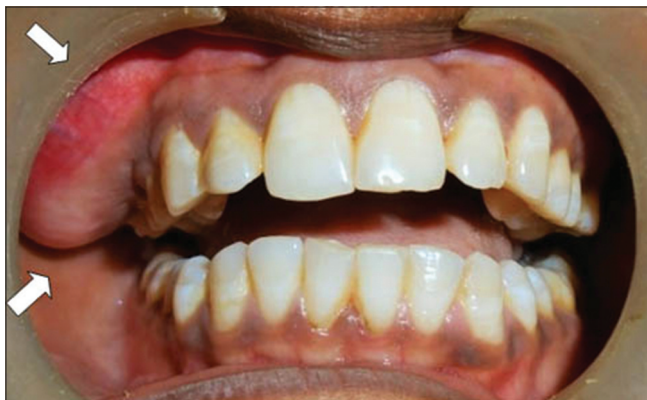

Figure 1: Exophytic bony swelling on right maxillary alveolar ridge

minimal atypia. Areas of osteoid admist the angular and spindle cells were also detected [Figures 4-6]. All these features led to the diagnosis of low-grade parosteal osteosarcoma. The patient was treated with partial maxillectomy and is under follow-up since the past 1.5 years.

DISCUSSION

Parosteal osteogenic sarcoma is an uncommon malignant tumor. In a large case series of 998 osteosarcomas of entire skeleton, Dahlin *et al.*, found only 50 juxtacortical osteosarcomas, none of which were reported in jaws.^[6] Bras *et al.*, reviewed seven cases of gnathic parosteal osteosarcomas of which five were reported in mandible and two in maxilla with an average age of 35.4 years.^[6] Simon *et al.*, in there view of 12 parosteal osteosarcomas, reported five in maxillary and seven in mandibular region with an average age of 34 years.^[5] A peak incidence between the ages of 20 and 30 years with 2:3 male to female ratio have been reported for juxtacortical osteosarcoma affecting long bones. Jaw sarcomas tend to occur 1 or 2 decades later than extragnathic osteosarcomas. Males are considered at risk for jaw parosteal osteosarcomas (1.75:1). However, we report parosteal osteosarcoma in a 22-year-old female patient, in the maxillary region. Rocha *et al.*, first reported maxillary parosteal osteosarcoma in 1970. To date only 27 cases of juxtacortical osteosarcomas have been reported of which 12 were of parosteal variant, nine were of periosteal variant and six were of periosteal/parosteal type.^[5] The present case brings the total number of parosteal osteosarcomas of jaws to 13, a rarity in itself in the literature.

Concurrent with the literature presenting features in our case were a painless, slowly growing, exophytic osseous swelling with nonlobular outer surface. Pain was mentioned as dull aching in half of the reported cases and it appeared as exophytic hard nodule on the attached gingiva appearing as soft tissue epulides mimicking benign osseous proliferative growth. Occasionally surface ulceration was noted.^[2,9]

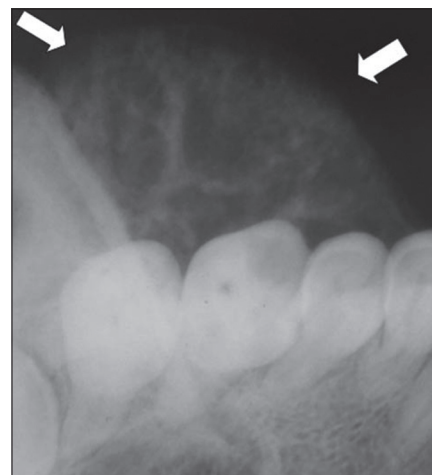

Figure 2: Occlusal view showing well-defined radiopaque lesion with patchy radiopacity

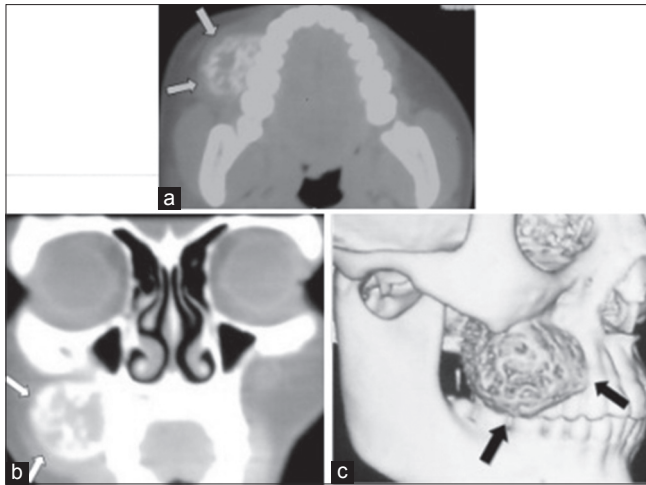


Figure 3: (a) Axial CT showing hyperdense radiopaque lesion, slightly dense at base than at periphery. (b) Coronal CT showing intact cortex and broad base of the lesion. (c) 3D-CT showing exophytic bony mass showing network of multiple intercoalescing radiating striae. 3D-CT = Three-dimensional computed tomography

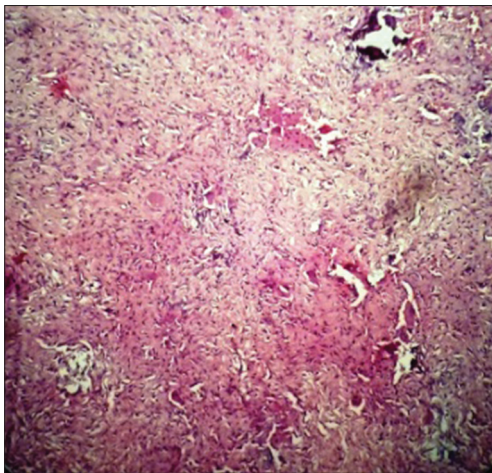


Figure 5: Background stroma consisting of spindle and angular cells with minimal atypia. Areas of subtle osteoid adjacent to epithelioid cells and calcification can be seen. (H&E stain, x100)

Radiographically, parosteal osteosarcomas are radiodense, lobulated, cauliflower-like or oval masses with a broad stalk attached to the external cortex of the underlying bone. The base often is more radiodense than the periphery. Parosteal variant is considered to arise from the outer layer of cortex, therefore does not elevate the periosteum like periosteal variant. Between underlying bone and the tumor, a thin radiolucent cleavage plane called “string sign”, a characteristic but not a constant finding, is seen in only 30% of the cases. “String sign” is a radiolucent line histopathologically corresponding to unmineralized thickened periosteum interposed between the cortex and the tumor mass. It is more difficult to demonstrate in the jaws because their anatomical form does not allow the necessary radiographic projections to be obtained. Various other radiographic patterns like cotton wool image with distinct margin, patchy radiopacity

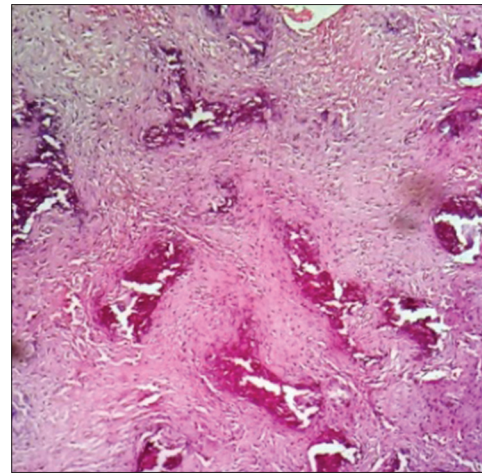


Figure 4: Irregular osteoid matrix separated by spindle and angular cells. (H&E stain, x40)

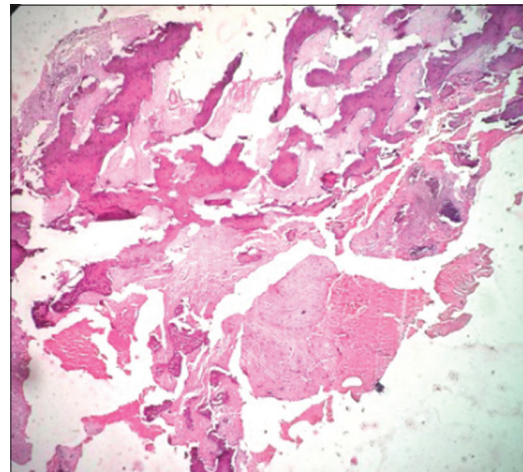


Figure 6: Photomicrograph showing thick often parallel (streamers) array of bony trabeculae in a spindle stroma. (H&E stain, x40)

and tumor mass with diffuse hazy opacification with few fine bony spicules radiating from the lower border of the lesion also have been reported.^[1,2,10-13]

In contrast, periosteal osteosarcoma presents with a radiographically intact cortex with no involvement of the underlying marrow cavity. It may have calcified spicules radiating from the cortex. The tumor matrix is not as radiographically dense or homogenous as parosteal osteosarcoma and has a poorly defined periphery. Since treatment and prognosis varies with both the variants of surface osteosarcomas, radiologic differentiation is important.^[2,3,14]

Computerized tomography scan helps to demonstrate the tumor confinement, attachment to the cortex and involvement of marrow. CT and magnetic resonance imaging (MRI) images are extremely useful for staging, detecting the presence of cortical erosion, regions of dedifferentiation, intramedullary extension or satellite lesions in the surrounding soft tissues.

MRI is further advised only when recurrence is suspected on clinical or radiologic basis. Scintigraphy and chest CT are useful in confirming the solitary nature of the tumor and absence of metastatic disease.^[1,6,7,13]

In the present case, well-defined radiodense tumor with patchy radiopacification and broad base was observed. Many interlacing coalescing trabeculae of varying thickness forming a meshwork from the lower border of the intact cortex as seen in 3DCT was an interesting finding not reported in previous cases. Radiographic differential diagnosis includes tori, exostosis and peripheral osteomas more commonly; and other rare entities like Nora's lesion (bizarre periosteal ossifying periostitis), osteochondroma, myositis ossificans and hyperostosis.^[2,5,7,12,15] Tori and exostosis occurring at the same site are painless, slow growing masses with limited growth potential and can attach to cortex of jaw via pedicle or wide base. Often the correct diagnosis is established on histologic basis. Peripheral osteomas tend to be more radiodense because of absence of cartilagenous areas and the rare trabecular strai tend to be fine and closer together, like the edge of the feather. Nora's lesion is very rare in jaws. It mimics tori and exostosis radiographically, but differs histopathologically from these entities. Intramedullary osteosarcoma and chondrosarcoma may present as exophytic nodules. However, the aggressive behavior with rapid expansion and medullary involvement should help in ruling out their presence. Osteochondroma, a rare entity in jaws, shows continuity of cortex and underlying medullary bone with the base of the lesion. Hyperostosis, an uncommon lesion encountered under the pontics in the posterior region can be confused with parosteal variant. Biopsy shows hyperplastic lamellar bone which differentiates it from this entity.^[1,2,7,12]

Histologically, it is well-differentiated and characterized by spindle cell stroma with minimal atypia and rare mitotic figures separating irregular trabeculae of woven bone. With time, the trabeculae often coalesce and form a large mass of solid bone. About 40–50% of parosteal osteosarcomas exhibit foci of cartilage. In the present case, well-formed bony trabeculae were interspersed between malignant mesenchymal cells. Fine lace-like osteoid tissues were present among hyperchromatic tumor cells with foci of cartilaginous tissue.^[11]

Microscopic evaluation of the specimen helps in screening the dedifferentiation areas and areas that represent high grade behavior. Approximately 10% of parosteal osteosarcomas dedifferentiate to high-grade osteosarcoma with a corresponding worsening of prognosis.^[3,5,6]

The histologic differential diagnosis of parosteal osteogenic sarcoma of the jaws includes Nora's lesion, benign fibro-osseous lesions like fibrous dysplasia and ossifying fibroma, low-grade intraosseous osteosarcomas and osteomas. Nora's lesion histopathologically shows characteristic cartilage capping and distinct zones which distinguishes it from parosteal

osteosarcoma. Fibrous dysplasia and ossifying fibroma apart from their histopathology, the intramedullary location negates the possibility of them in differential diagnosis. Osteoma in conjunction with mature bone lacks the spindle cell proliferation seen in parosteal osteogenic sarcoma and do not show cellular polymorphism, anaplasia and mitotic activity. Low-grade intraosseous osteosarcoma shows overlapping histologic features with parosteal osteosarcoma.^[6,8,15]

In most of the cases, the therapy of choice is radical surgical excision. Minimal local recurrence occurs with wide excision of adjacent bone and periosteum by removing satellite lesions and preventing local spread along the bone surface. Now, chemotherapy following wide excision is the recommended treatment protocol for recurrent cases and those exhibiting highly malignant features on histological examination.^[6,9,10]

Low-grade parosteal osteosarcoma has an overall good prognosis and has low metastatic potential. Local control is more limited in the maxilla than the mandible and thus mandibular parosteal osteosarcomas overall have better prognosis than those of the maxilla. Therefore maxilla has high recurrent rate. With the number of recurrences, the incidence of intramedullary involvement and dedifferentiation to high-grade sarcoma increases.^[4,9,10]

To conclude, this case illustrates the importance of correlation of clinical, radiological and histopathological features in confirming the diagnosis of parosteal osteosarcoma. Because of the less aggressive biological behavior, it is important to recognize and differentiate it from benign osseous lesions.

REFERENCES

1. Murphey MD, Robbin MR, Mcrae GA, Flemming DJ, Temple HT, Kransdorf MJ. The many faces of osteosarcoma. *Radiographics* 1997;17:1205-31.
2. Huang TC, Monsour PA, Chahoud CD. Parosteal osteosarcoma: Report of a case and review of the literature. *Aust Dent J* 2010;55:86-91.
3. Sorensen DM, Godken M, El-Naggar A, Byers RM. Periosteal osteosarcoma of the mandible. *Arch Otolaryngol Head Neck Surg* 2000;26:550, 552.
4. Anithabojan, Christy W, Chanmougananda S, Ashokan K. Osteosarcoma of mandible: A case report and review of literature. *J Clin Diagn Res* 2012;6:753-7.
5. Bras JM, Donner R, van der Kwast WA, Snow GB, van der Waal I. Juxtacorticalosteogenic sarcoma of the jaws. Review of the literature and report of a case. *Oral Surg Oral Med Oral Pathol* 1980;50:535-44.
6. Antonescu RC, Huvos AG. Low-Grade Osteogenic sarcoma arising in medullary and surface osseous locations. *Am J Clin Pathol* 2000;114(Suppl 1):S90-103.
7. Johnson K, Davie AM, Evans N, Grimer RJ. Imaging recurrent parosteal osteosarcoma. *Eur Radiol* 2001;11:460-6.
8. Neville BW, Damm DD, Allen CM, Bouquot JE. Oral and maxillofacial pathology. In: *Bone Pathology*. 3rded. Philadelphia: Saunders; 2009. p. 660-4.

9. Balwani SR, Tupkari JV, Barpande SR. Parosteal osteosarcoma of the mandible. *J Oral Maxillofac Pathol* 2006;10:10-4.
10. Simon D, Dominic S, Varghes KG. Juxtacortical osteogenic sarcoma of the jaws: Case report and review of the literature. *J Oral Maxillofac Surg* 2011;69:527-31.
11. Chaudhary M, Chaudhary SD. Osteosarcoma of jaws. *J Oral Maxillofac Pathol* 2012;16:233-8.
12. Langlis RP, Langland OE, Nortje CJ. Diagnostic imaging of jaws: Focal radiopacities. 1st ed. Baltimore: Williams and Wilkins; 1995. p. 505-15.
13. Sayin B, Yildirim N, Vural M, Dede D. Osteosarcoma of the maxilla. *Radiol Oncol* 2005;39:95-9.
14. Yarmish G, Klein MJ, Landa J, Lefkowitz RA, Hwang S. Imaging characteristics of primary osteosarcoma: Non conventional subtypes. *Radiographics* 2010;30:1653-72.
15. Dashti HM, Reith JD, Schlott BJ, Lewis EL, Cohen DM, Bhattacharya I. Bizarre parosteal osteochondromatous proliferation (Nora's lesion) of the mandible. A rare bony lesion. *Head Neck Pathol* 2012;6:264-9.

How to cite this article: Puranik SR, Puranik RS, Ramdurg PK, Choudhary GR. Parosteal osteosarcoma: Report of a rare juxtacortical variant of osteosarcoma affecting the maxilla. *J Oral Maxillofac Pathol* 2014;18:432-6.

Source of Support: Nil. **Conflict of Interest:** None declared.

New features on the journal's website

Optimized content for mobile and hand-held devices

HTML pages have been optimized for mobile and other hand-held devices (such as iPad, Kindle, iPod) for faster browsing speed.

Click on [**Mobile Full text**] from Table of Contents page.

This is simple HTML version for faster download on mobiles (if viewed on desktop, it will be automatically redirected to full HTML version)

E-Pub for hand-held devices

EPUB is an open e-book standard recommended by The International Digital Publishing Forum which is designed for reflowable content i.e. the text display can be optimized for a particular display device.


Click on [**EPub**] from Table of Contents page.

There are various e-Pub readers such as for Windows: Digital Editions, OS X: Calibre/Bookworm, iPhone/iPod Touch/iPad: Stanza, and Linux: Calibre/Bookworm.

E-Book for desktop

One can also see the entire issue as printed here in a 'flip book' version on desktops.

Links are available from Current Issue as well as Archives pages.

Click on  View as eBook