



## Altered praxis network underlying limb kinetic apraxia in Parkinson's disease - an fMRI study



Stefanie Kübel<sup>a,1</sup>, Katharina Stegmayer<sup>b,1</sup>, Tim Vanbellingen<sup>a,c</sup>, Manuela Pastore-Wapp<sup>f</sup>, Manuel Bertschi<sup>d</sup>, Jean-Marc Burgunder<sup>e</sup>, Eugenio Abela<sup>f,g</sup>, Bruno Weder<sup>f</sup>, Sebastian Walther<sup>b</sup>, Stephan Bohlhalter<sup>a,\*</sup>

<sup>a</sup> Neurocenter, Luzerner Kantonsspital, Spitalstrasse 31, 6000 Luzern 16, Switzerland

<sup>b</sup> University Hospital of Psychiatry, Bolligenstrasse 111, 3000 Bern 60, Switzerland

<sup>c</sup> Gerontechnology and Rehabilitation Group, University of Bern, Murtenstrasse 50, 3008 Bern, Switzerland

<sup>d</sup> Department of Neurology, Kantonsspital Aarau, Tellstrasse 25, 5001 Aarau, Switzerland

<sup>e</sup> Department of Neurology, Inselspital, University Hospital, University of Bern, 3010 Bern, Switzerland

<sup>f</sup> Support Center for Advanced Neuroimaging (SCAN), Inselspital, University Hospital, University of Bern, 3012 Bern, Switzerland

<sup>g</sup> Department of Basic and Clinical Neuroscience, Institute of Psychiatry, Psychology and Neuroscience (IoPPN), King's College London, Camberwell, SE5 9RX London, UK

### ARTICLE INFO

#### Keywords:

Coin rotation

Dexterity

Executive control

Functional connectivity

Hippocampus

### ABSTRACT

Parkinson's disease (PD) patients frequently suffer from dexterous deficits impeding activities of daily living. There is controversy whether impaired fine motor skill may stem from limb kinetic apraxia (LKA) rather than bradykinesia. Based on classical models of limb praxis LKA is thought to result when premotor transmission of time-space information of skilled movements to primary motor representations is interrupted. Therefore, using functional magnetic resonance imaging (fMRI) we tested the hypothesis that dexterous deficits in PD are associated with altered activity and connectivity in left parieto-premotor praxis network. Whole-brain analysis of fMRI activity during a task for LKA (coin rotation) showed increased activation of superior and inferior parietal lobule (SPL, IPL) and ventral premotor cortex (vPM) in PD patients compared to controls. For bradykinesia (assessed by finger tapping) a decreased fMRI activity could be detected in patients. Additionally, psychophysical interaction analysis showed increased functional connectivity between IPL and the posterior hippocampi in patients with PD. By contrast, functional connectivity to the right dorsolateral prefrontal cortex was decreased in patients with PD compared to controls.

In conclusion, our data demonstrates that dexterous deficits in PD were associated with enhanced fMRI activation of the left praxis network upstream to primary motor areas, mirroring a neural correlate for the behavioral dissociation of LKA and bradykinesia. Furthermore, the findings suggest that patients recruit temporal areas of motor memory as an attempt to compensate for impaired motor skills. Finally, dysexecutive function may contribute to the deficit.

### 1. Introduction

Patients with Parkinson's disease (PD) frequently suffer from loss of fine motor skills. Dexterous difficulties in PD are only partly explained by elemental motor deficits such as bradykinesia (Gebhardt et al., 2008). They may develop even at an early stage of the disease (Koop et al., 2008; Proud and Morris, 2010) and have been linked to poor outcome (Pohar and Allyson Jones, 2009). Indeed, dexterous difficulties not exclusively explained by bradykinesia significantly impair activities of daily living (ADL) (Foki et al., 2016). Therefore, exploring the

neural mechanism of impaired fine motor skills in PD is of clinical interest.

It has been suggested to introduce the notion of limb kinetic apraxia (LKA) to describe dexterous difficulty in PD (Gebhardt et al., 2008; Quencer et al., 2007). LKA adopts an intermediate position between higher-order (i.e. apraxic) and elemental motor disorders. It is characterized by impaired control of selective and coordinated hand and finger movements, but not explained by weakness or sensory deficits (Heilman, 2010). LKA can be assessed by the so-called coin rotation (CR) task. CR is a relatively simple and fast administered task to assess

\* Corresponding author.

E-mail address: [Stephan.Bohlhalter@luks.ch](mailto:Stephan.Bohlhalter@luks.ch) (S. Bohlhalter).

<sup>1</sup> Authors contributed equally.

manual dexterity in clinical settings (Barkemeyer et al., 1998; Gebhardt et al., 2008; Hill et al., 2010).

To perform a skilled movement, temporal and spatial information of the movement must be retrieved and translated into motor output. According to the movement representation hypothesis (Geschwind, 1975), brain areas forming part of the so-called praxis network (Niessen et al., 2014) are involved. Specifically, it is assumed that the inferior parietal lobule (IPL) conveys spatial and temporal content of a movement (Heilman et al., 1982; Rothi et al., 1985) to left premotor cortex (Barrett et al., 1998; Haaland et al., 2000; Kolb and Milner, 1981) and probably to the supplementary motor area (SMA) (Watson et al., 1986). The premotor regions finally program movement execution by transmitting information to motor representations of the primary motor cortex (M1). In fact, in healthy subjects, the premotor cortex is critical to perform skilled finger movements as demonstrated by functional MRI (fMRI) (Nirkko et al., 2001).

As expected from the neural basis of motor skills, LKA may result from structural and functional alterations of the praxis network. For instance, premotor lesions can cause LKA (Freund and Hummelsheim, 1985). Furthermore, premotor white matter density correlates with limb kinetic deficits in corticobasal syndrome (Borroni et al., 2008). In addition, detailed clinico-anatomical case studies have demonstrated that early LKA in corticobasal syndrome is associated with predominant premotor atrophy (Tsuchiya et al., 1997). Finally, the sensorimotor and posterior parietal cortices showed reduced cerebral blood flow in corticobasal syndrome patients with LKA (Okuda et al., 1998).

In PD neuroimaging findings of LKA are sparse. In fact, to the best of our knowledge, only one group has investigated functional correlates of LKA (altered CR) in PD (Foki et al., 2010). This study found an increased activation in parietal areas, as well as subcortical, sensory, premotor, and supplementary motor areas associated with LKA in PD. However, there was some methodological criticism (Bohlhalter et al., 2011). For instance, self and fixed paced conditions were different across tasks (CR and index finger tapping). Furthermore, unspecific activation cannot be ruled out as the kinematic (finger tapping with one finger vs. coin rotation with tree fingers) and somatosensory requirements (finger tapping without object manipulation vs. coin rotation) differed for the two fMRI tasks. Moreover, the design lacked a true baseline.

Therefore, robust imaging data on LKA in PD at the level of praxis networks is not available. Moreover, previous reports in PD point towards compensatory increased functional connectivity within the motor network during motor tasks (Wu et al., 2010a, 2010b; Yan et al., 2015) and decreased functional connectivity of attentional and executive control areas during higher order control tasks (e.g. working memory) (de Bondt et al., 2016; Helmich et al., 2009; Trujillo et al., 2015). However, functional interactions between relevant praxis areas remain to be explored.

The goal of the present study was to assess the functional brain activity during skilled fine motor tasks, as measured by the CR, in PD compared to healthy controls. Furthermore, we investigated for the first time dynamic functional connectivity within the praxis network during CR. We hypothesized increased activation and altered functional coupling of areas of the praxis network in PD, in particular, of premotor areas and the left inferior parietal lobule as well as executive control and attention areas.

## 2. Methods

### 2.1. Subjects

In total, 22 PD patients and 13 age and handedness-matched healthy controls participated in this study. Patients were recruited at the Department of Neurology, Inselspital, University Hospital of Bern. Controls were recruited from the local community. The study was performed according to the Declaration of Helsinki and was approved

by the local Ethics Committee. All participants provided written informed consent.

Patients were included if they had an established diagnosis of PD, as determined by the UK Brain Bank diagnostic criteria (Hughes et al., 1992). Exclusion criteria for all participants were sedating medication, severe medical or psychiatric conditions, as well as general exclusion criteria for magnetic resonance imaging (i.e. claustrophobia or metal implants). Further exclusion criteria for healthy controls were any neurological disorder in general, and for patients any neurological disorder other than PD. In both groups we assessed hand dominance with the Edinburgh Handedness Inventory (Oldfield, 1971) and cognitive impairment with the Mini-mental status examination (MMSE) (Folstein et al., 1975). Additionally, the forward and backward digit span (Wechsler, 1997) test was performed for specific neuropsychological testing of short-term verbal memory. In patients, disease stage was determined according to the Hoehn & Yahr criteria (Goetz et al., 2004). In addition, we measured bradykinesia-rigidity using the modified Unified Parkinson's Disease Rating Scale (UPDRS) (Goetz et al., 2008). Twelve patients received dopaminergic medication and ten patients were drug-naïve.

### 2.2. Experimental design

All participants underwent the same acquisition of clinical and behavioral data. Prior to imaging data acquisition, we provided detailed task instructions and training to ensure understanding of task procedures and accurate execution. If patients received antiparkinsonian medication, PD patients were tested in their best ON state (60 to 90 min after their last dose of dopaminergic medication). In general, all patients used their clinically less affected hand (right hand performance:  $n = 12/60\%$ ) to minimize confounding effects of bradykinesia. Controls performed the task with the same hand as patients (right hand performance  $n = 9/75\%$ ). Therefore, four participants performed with the left hand.

We employed an fMRI block design. Each of the eight blocks consisted of one of two movement tasks (Fig. 1). The order of the two movement task blocks was pseudo-randomized to control for sequence effects. Each block consisted of 3 trials.

In detail, each experimental trial (Fig. 1) started with a brief written instruction (4 s) indicating the upcoming movement task followed by an active movement phase of 26 s, followed by a 16 s rest phase. A green cross in the middle of the screen signaled the start of the active movement phase. During the resting phase a white fixation cross was presented and participants were asked to relax and not to move.

During the active movement phase, participants were instructed to perform one of two movement tasks: the CR (Barkemeyer et al., 1998; Hill et al., 2010) or a modified finger tapping (FT) task (Goetz and Stebbins, 2004; Reitan, 1969). Briefly, during CR, subjects were asked to rotate a Swiss 50-Rappen coin (18 mm in diameter) through 180°-turns between thumb, index, and middle finger. During the modified FT task subjects were asked to simply tap their fingers following an alternating sequence. The sequence was as follows: 1-2-1-3-1-2-1-3-1-2-1-3, in which 1, 2 and 3 refer to thumb, index and middle finger, respectively. Participants executed tapping on an MRI compatible response box. We used a repetitive finger tapping sequence, as it is sensitive to test bradykinesia. Furthermore, the finger sequence allowed minimizing unspecific activation based on differences in sensory-motor processing. Thus, the modified FT is closer to the kinematic and sensory demands of the CR task (i.e. same fingers involved as in the coin rotation task and some sensory component by the tapping on the box). CR and FT were performed self-paced (i.e. as fast as possible).

Performance of motor tasks was video recorded and evaluated by an independent rater blinded for diagnosis and clinical status. CR performance scores reflect mean numbers of half-turns adjusted for coin drops (Barkemeyer et al., 1998). FT performance scores reflect the number of alternating sequences (Goetz and Stebbins, 2004; Reitan, 1969). Thus



PPI regressor and CR performance for each of the 8 target regions (see Supplementary material analysis A). The PPI regressor was derived from individual time series for each target region for each subject and was further mean-corrected.

To examine the role of possible grey matter density differences between healthy controls and patients on brain activity, we performed an additional whole-brain voxel based morphometry (VBM) analysis. We used total brain volume and the same regressors as in the main analysis (see Supplementary material analysis B).

For all contrasts we used a uniform voxel-level threshold of  $P < 0.005$  (uncorrected); minimum cluster size 17 voxels (tables and figures). This threshold is equivalent to a map-wise false positive rate of  $\alpha < 0.005$  using a Monte Carlo procedure as implemented in the AlphaSim program in the Analysis of Functional Neuroimages software package (Stepens et al., 2010). All reported significant clusters were anatomically labeled using the Jülich atlas included in the SPM Anatomy Toolbox Version 1.8 (Eickhoff et al., 2005). Images were produced using SPM8 and MRICron (Rorden et al., 2007).

### 3. Results

#### 3.1. Behavioral and clinical data

Demographic and clinical data are given in Table 1. Two patients had to be excluded as MRI acquisition had to be stopped prematurely due to intolerance of the supine position in the scanner. One participant was excluded due to a coin rotation deficit to rule out any confounding effects based on musculoskeletal impairments. Thus, the data of 20 PD patients and 12 healthy controls remained for final analysis. As expected, patients performed worse than controls in the CR task. Twelve patients showed CR deficits according to Hill and colleagues (Hill et al., 2010) (deficit = mean in 10 s < 13 rotations adjusted for coin drop). However, five patients and no healthy control participant were classified as showing clear-cut LKA (LKA = mean in 10 s < 10 rotations

**Table 1**

Clinical characteristics and demographic data of Parkinson's disease patients and healthy controls.

	Controls (n = 12)		Patients (n = 20)		Between group tests		
	Men/women		Men/women		df	$\chi^2$	P
Gender (n)	Men/women		Men/women		df	$\chi^2$	P
	5/8		4/16		1	1.742	0.187
Handedness	Right/left		Right/left		df	$\chi^2$	P
	11/1		19/1		1	0.142	0.706
	M	D	M	SD	f	T	P
Age (y)	63	10	62	10	30	0.263	0.794
	[34,75]		[37,75]				
Coin rotation (CR/10s)	17.08	2.7	12.6	3.2	30	4.03	< 0.001
	[13,21]		[6,21]				
Finger tapping (FT/10s)	32.7	8.3	28.3	10.9	30	1.152	0.259
	[20,46]		[14,49]				
MMSE	28.9	1.3	28.2	1.6	30	1.161	0.255
	[26,30]		[25,30]				
Forward digit span	7.08	2.0	7.15	1.8	30	0.096	0.924
	[5,11]		[4,11]				
Backward digit span	5.17	1.9	5.5	1.9	30	0.484	0.630
	[3,9]		[3,10]				
Levodopa equivalent (mg/day)	–	–	438.3	532.2	–	–	–
			[0,1600]				
Disease duration (y)	–	–	2.9	3.1	–	–	–
			[0,8]				
Hoehn & Yahr stage (ON)	–	–	1.9	0.4	–	–	–
			[1,2]				
MDS-UPDRS III	–	–	22.4	8.2	–	–	–
			[7,34]				

M = mean; y = years; MMSE = mini-mental state examination; MDS-UPDRS III = Movement Disorders Society-Unified Parkinson disease rating scale motor part; the values in the brackets represent the minimum and maximum value.

adjusted for coin drop) (Barkemeyer et al., 1998). In contrast, although FT was slightly diminished in patients, the difference was not statistically significant. Furthermore, no task-by-group interaction was detected.

#### 3.2. Differential fMRI activation of the left IPL, SPL, SFG and vPM in Parkinson's disease

We found a significant task-by-group interaction effect in brain areas forming part of the praxis network (Figs. 2, 3): left IPL ( $F_{(1, 56)} = 14.17$ ), left superior parietal lobule (SPL) ( $F_{(1, 56)} = 13.58$ ), left superior frontal gyrus (DMPFC;  $F_{(1, 56)} = 11.6$ ), and left ventral premotor area (vPM) ( $F_{(1, 56)} = 11.54$ ). Post-hoc *t*-tests (Fig. 3) of extracted fMRI activity values in these areas indicated increased activity in patients compared to controls during CR (IPL,  $T_{(30)} = 2.77$ ,  $P = 0.009$ ; SPL,  $T_{(30)} = 2.61$ ,  $P = 0.014$ ; vPM,  $T_{(30)} = 3.33$ ,  $P = 0.002$ ). In contrast, for the FT task fMRI, activity in patients was decreased significantly in IPL ( $T_{(30)} = 2.38$ ,  $P = 0.024$ ), SPL ( $T_{(30)} = 2.35$ ,  $P = 0.026$ ), and in SFG ( $T_{(30)} = 3.2$ ,  $P = 0.003$ ). In vPM fMRI activation of FT was not different ( $T_{(30)} = 1.15$ ,  $P = 0.258$ ). These results show that the increased activation during CR in left praxis areas is not a general group effect, but specifically modulated by the task. Furthermore, the CR task differentially activates the left praxis network in patients regardless of the hand involved.

#### 3.3. Increased functional coupling of the left IPL with posterior hippocampi

We detected an increased functional connectivity in patients of the left IPL bilaterally to posterior hippocampus, extending from precuneus on the right. Furthermore, stronger connectivity of left IPL was found with lateral temporal areas including left middle and right superior temporal gyrus, as well as the left cuneus (Fig. 4; Table 2). In addition, patients showed a disturbed connectivity with the frontal lobe. We detected a decreased connectivity of the left IPL and the dorsolateral prefrontal cortex (DLPFC: right middle frontal gyrus) in patients compared to controls (Fig. 4; Table 2).

Correlation analysis revealed that functional connectivity of the left IPL with the left middle temporal gyrus (MTG) was associated with better CR performance in patients (see Supplementary material analysis A).

#### 3.4. Grey matter volume decrease in bilaterally frontal brain areas

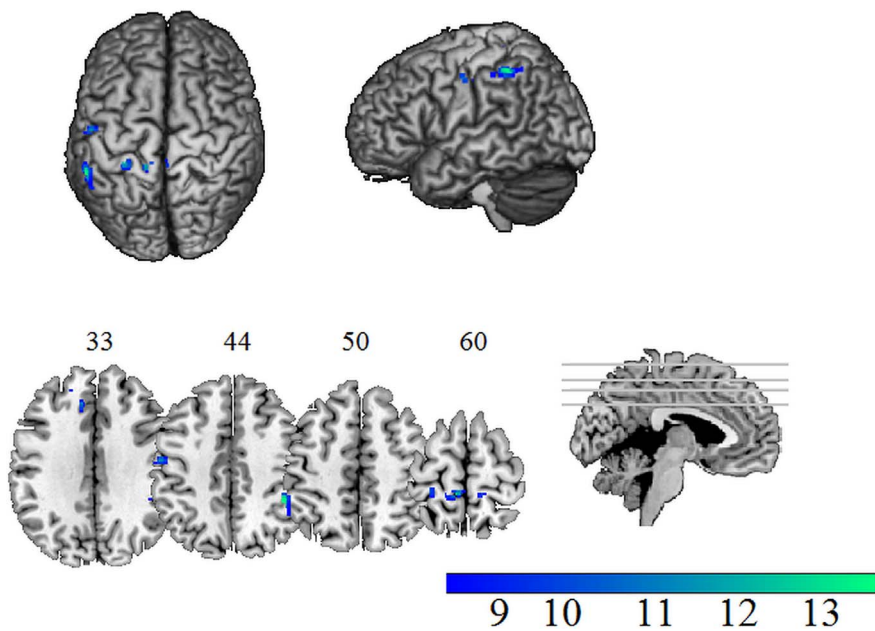
VBM analysis revealed a slight decrease of grey matter volume in widespread brain areas including the left inferior frontal gyrus and bilaterally the primary motor cortices in patients compared to controls (see Supplementary material analysis B, Table SI).

### 4. Discussion

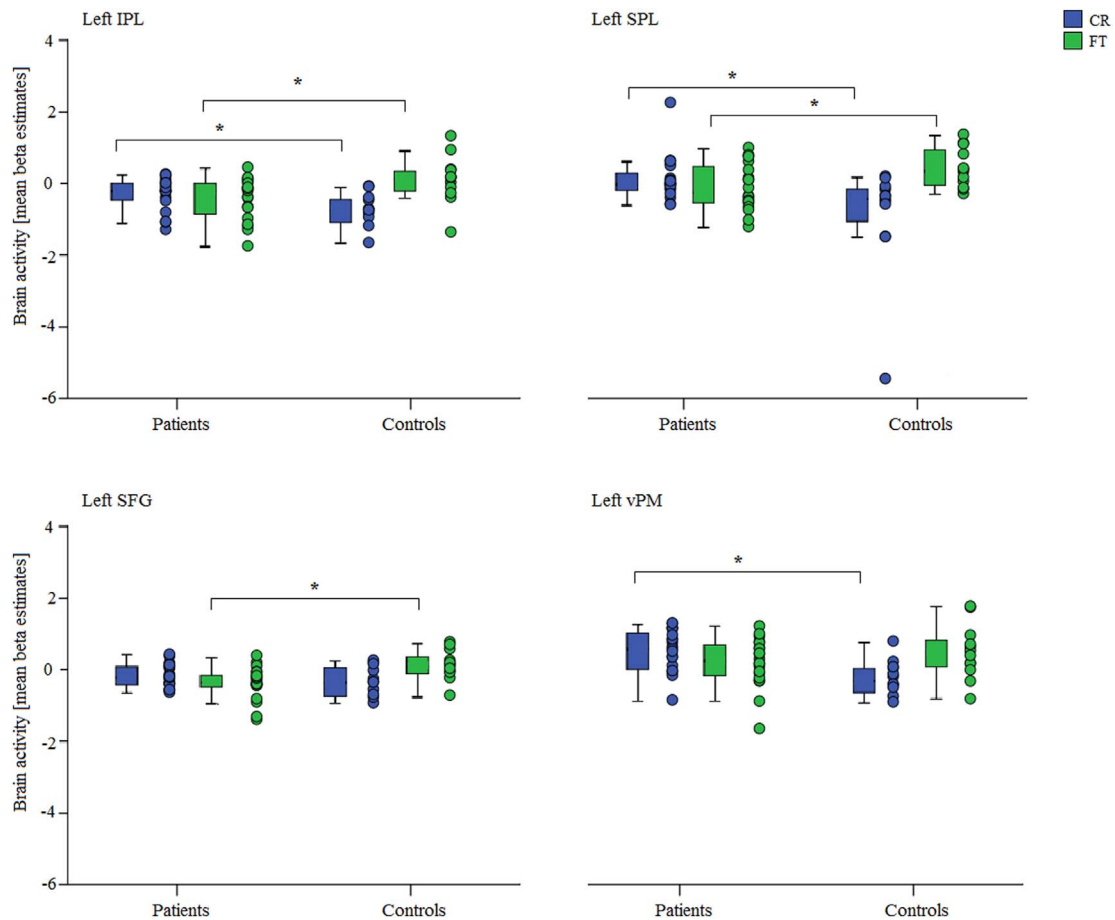
Patients with PD frequently suffer from loss of fine motor skills. Clinical studies (Foki et al., 2016; Gebhardt et al., 2008; Quencer et al., 2007; Vanbellingen et al., 2011) suggested that LKA, apart from bradykinesia, is implicated. However, whether dexterous impairment in PD is explained by apraxia is still a matter of debate (Foki et al., 2015, 2016; Gebhardt et al., 2008; Landau and Mink, 2007; Quencer et al., 2007; Swash et al., 2007; Vanbellingen et al., 2011).

Therefore, the goal of the present study was to assess the functional brain activity during skilled fine motor tasks, as measured by the coin rotation (LKA) task in PD compared to matched healthy controls. Furthermore, we investigated for the first time dynamic functional connectivity within the praxis network during CR. We hypothesized to detect increased activation in areas of the praxis network in PD patients during the CR task, which is the neural correlate of LKA. Furthermore, we expected an altered functional connectivity of the praxis network during a limb kinetic task.





**Fig. 2.** Brain areas with significant task-by-group interaction. Effect in patients with Parkinson's disease and healthy controls during a bradykinesia (finger tapping) and a limb kinetic apraxia task (coin rotation). Significant whole brain task-by-group interaction was detected within the left inferior parietal lobule, superior parietal lobule, superior frontal gyrus and ventral premotor area. The color bars show F statistic. L = left; R = Right. (For interpretation of the references to color in this figure legend, the reader is referred to the web version of this article.)



**Fig. 3.** Between group differences of brain activity within significant clusters of the interaction analysis. Brain activity in the left inferior parietal lobule (IPL), superior parietal lobule (SPL) and superior frontal gyrus (SFG) was enhanced in patients compared to controls during the limb kinetic apraxia task (CR) and decreased in the IPL, SPL and vPM during the bradykinesia task (FT). Significant differences of post-hoc pairwise group comparisons are indicated with asterisks ( $P < 0.05$ ). Note: CR = coin rotation in green; FT = finger tapping in blue, error bars:  $\pm 1$  standard error. (For interpretation of the references to color in this figure legend, the reader is referred to the web version of this article.)

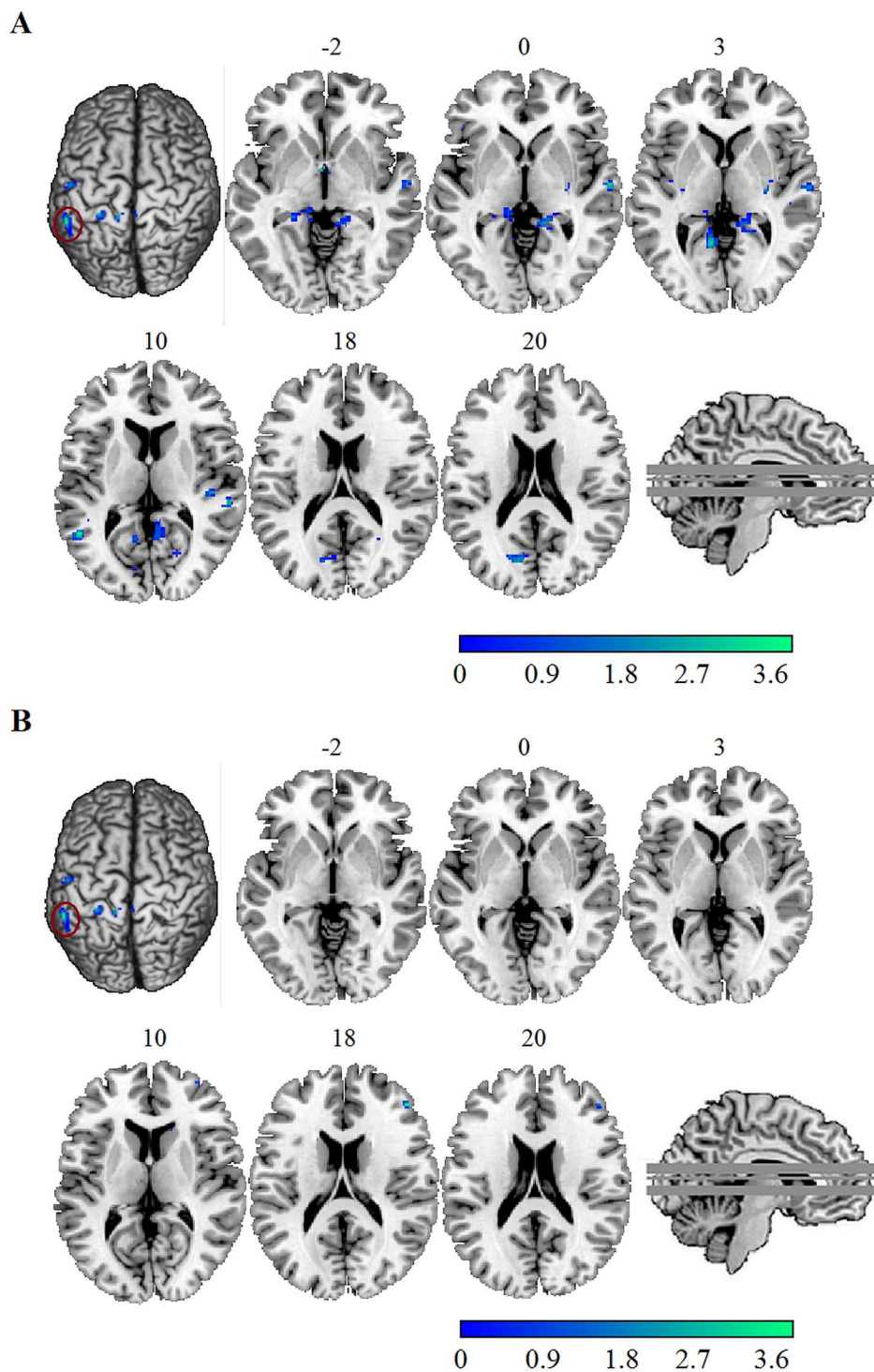


Fig. 4. Between group results of functional connectivity during limb kinetic apraxia task performance.

A. Significant enhanced functional connectivity between the inferior parietal lobule and the posterior body of the hippocampus on both sides and B. significant decreased connectivity between the inferior parietal lobule and the middle frontal gyrus (DLPFC) in patients compared to healthy controls. The color bars show T values. L = left; R = right; DLPFC = dorsolateral prefrontal cortex. (For interpretation of the references to color in this figure legend, the reader is referred to the web version of this article.)

As predicted, and in line with current models of apraxia, we detected differential activation in key areas of the left praxis network (i.e. left IPL, SPL and vPM) and additionally the DMPFC, regardless of the hand involved. These results fit nicely with the literature that shows the association of apraxic deficits with left parietal and premotor regions and thus support the notion that indeed dexterous deficits in PD stem from LKA. We confirmed our hypothesis of altered functional coupling within the praxis network associated with the LKA task. In particular, we detected increased functional connectivity of the IPL in patients with several brain areas including an area involved in visual-spatial memory (posterior hippocampus). Furthermore, unlike controls, patients failed to functionally connect the IPL with regions of executive

control during the LKA task.

#### 4.1. Differential neuronal activation of limb kinetic apraxia and bradykinesia

Altered activation of IPL is frequently found in PD (Herz et al., 2014; Samuel et al., 1997; Wu and Hallett, 2005). Moreover, the IPL is relevant for skilled fine movements (Buxbaum et al., 2007; Pause et al., 1989) and is a key region in apraxia (Buxbaum et al., 2007; Goldenberg, 2009; Heilman, 2010). In particular, time and spatial content of a movement is hypothesized to be stored in the IPL (Buxbaum et al., 2014; Heilman et al., 1982; Rothi et al., 1985). In addition, the

**Table 2**

Altered functional connectivity of the left inferior parietal lobule linked to limb kinetic apraxia in patients and controls: between-group analysis (Parkinson's disease patients > healthy controls; healthy controls > Parkinson's disease patients).

Whole brain functional connectivity of the inferior parietal lobule during coin rotation														
	Patients > controls						Controls > patients							
	Cluster	Peak	MNI coordinates			Cluster	Peak	MNI Coordinates						
Brain region	P(FWE-corr)	k	P(FWE-corr)	T <sub>(31)</sub>	x	y	z	P(FWE-corr)	k	P(FWE-corr)	T <sub>(31)</sub>	x	y	z
L Middle temporal gyrus	0.996	40	0.572	4.331	-52	-54	8	n.s.						
L Cuneus	0.979	59	0.996	3.420	-12	-74	20	n.s.						
L Hippocampus	1.000	19	0.999	3.230	-22	-36	-2	n.s.						
L Parahippal gyrus extending to hippocampus	1.000	23	0.999	3.070	-12	-36	0							
L Calcerin gyrus	0.798	115	0.647	4.220	-10	-54	4	n.s.						
R Middle frontal gyrus	n.s.							1.000	23	0.971	3.650	46	40	18
R Superior temporal gyrus	0.995	42	0.989	3.580	62	-12	0	n.s.						
	1.000	25	0.993	3.920	46	-24	8	n.s.						
R Precuneus extending to hippocampus	0.643	146	0.938	3.760	18	-46	4	n.s.						

L = left; MNI = Montreal Neurological Institute; n.s. = not significant; R = right.

premotor areas and supplementary motor area via primary motor cortex are hypothesized to transmit time and spatial information to motor representation for final motor execution (Babiloni et al., 2003; Penfield and Penfield and Welch, 1951). In general, functional imaging studies highlight the involvement of left lateralized premotor-posterior parietal areas in praxis related tasks such as pantomiming (Bohlhalter, 2009; Choi et al., 2001; Fridman et al., 2006; Króliczak and Frey, 2009; Mäki-Marttunen et al., 2014; Ohgami et al., 2004; Vingerhoets et al., 2011; Vry et al., 2015) or real tool use (Brandt et al., 2014; Imazu et al., 2007). In PD the hyper-activation of inferior frontal and inferior parietal areas is associated with diminishing pantomime skills (Matt et al., 2016). Furthermore, several studies showed increased fMRI activation reflecting a compensatory (although dysfunctional) mechanism for diminished task performance (e.g. diminished working memory) (Rottschy et al., 2013; Trujillo et al., 2015). However, so far only one group investigated functional correlates of LKA in PD (Foki et al., 2010, 2015). This study showed bilateral hyper-activity in widespread areas of the frontal and the parietal cortex (Foki et al., 2010). Hence, except for weak hypo-activity in somatosensory cortex, the findings largely lacked specificity, which may be explained by methodological issues (Bohlhalter et al., 2011).

Strikingly, we revealed differential neuronal activation of LKA within the IPL, SPL and premotor areas. Therefore, our findings fit well with the left-predominant posterior-anterior control of praxis function, in which limb kinetic deficits result if the neuronal transmission to final motor output is impaired. The dysfunction upstream to primary motor representations is further corroborated as the interaction effect of fMRI activity was controlled for performance and therefore cannot be explained by differences in motor output per se. The VBM analysis showed diminished grey matter volume in various inferior frontal and temporo-parietal brain regions as known from the literature (Borghammer et al., 2010; Postuma and Dagher, 2006; Potgieser et al., 2014). No diminished grey matter volume was found in the praxis relevant areas associated with the CR task. Therefore, the VBM findings cannot account for LKA-related fMRI alterations in PD.

For the bradykinesia task, we detected decreased activity in the left SPL, IPL and SFG in patients compared to controls. Several factors may account for this observation. Hypo-activity in cortical structures such as the primary motor cortex (Rascol et al., 1992), SPL (Haslinger et al., 2001), SMA (Rascol et al., 1992) and DLPFC (Playford et al., 1992) has been reported as a general feature of PD and has also been linked to bradykinesia (Rascol et al., 1992). Furthermore, basal ganglia and cortical activation likely depend on the medication status, as most functional imaging studies in PD demonstrated hypo-activation in OFF state and hyper-activation in ON (Buhmann et al., 2003; Kraft et al., 2009; Leenders et al., 1985; Lewis et al., 2007). Therefore, we may

speculate that cortical hypo-activity associated with bradykinesia observed herein may be explained by the fact that almost half of the patients were drug naïve. Finally, the patients reached normal performance in the modified finger tapping task despite hypo-activation. This constellation may reflect the earlier disease stage of our cohort, when compensatory cortical hyper-activity is only necessary with higher and specific task demands such as for digital dexterity associated with the CR task.

#### 4.2. Altered functional coupling with visual-spatial and executive brain areas

Previous task-based network investigations of motor performance (fMRI) detected mostly increased connectivity in PD patients in the motor network compared to healthy controls e.g. during action planning (i.e. skilled finger movements) (Wu et al., 2010b; Yan et al., 2015) and motor learning (Wu et al., 2010a). These increased connectivity patterns in patients were interpreted as compensatory mechanisms during motor control in PD (Eckert et al., 2006; Katschnig et al., 2011; Mallol et al., 2007; Yu et al., 2007). Likewise, altered functional connectivity during general higher-level planning, such as task-shifting (de Bondt et al., 2016; Helmich et al., 2009) and working memory (Trujillo et al., 2015; Weder et al., 1999), have repeatedly been demonstrated in PD. In detail, De Bondt and colleagues found a hyper-activation together with decreased connectivity between key areas of task-shifting, such as the DLPFC, superior frontal gyrus and posterior parietal cortex. Participants performing a visual-spatial working memory task showed decreased functional coupling with the DLPFC but an increased connectivity of the fronto-parietal network, including the IPL (Trujillo et al., 2015). Thus, previous studies mostly suggest increased connectivity within brain areas of the motor networks during motor performance together with decreased connectivity within attentional and executive brain areas during cognitive tasks. In contrast, studies investigating functional connectivity in PD during a LKA task are missing.

Here we reported increased connectivity of the IPL in patients with the temporal lobe, the cuneus, the precuneus, and the calcerine gyrus. In addition, increased connectivity of the IPL with the posterior hippocampi on both sides was shown. Thus, we failed to detect increased connectivity with brain areas of cortical motor networks previously reported for motor performance tasks. Instead, we detected increased connectivity with the posterior hippocampus and the left MTG. The hippocampus is hypothesized to integrate object-related information and to store and retrieve time and spatial information of a movement (Behrendt, 2013). In healthy controls, the hippocampus was detected as important also for encoding and retrieval of event related memories (Eldridge et al., 2000) and context coding (Kalisch et al., 2006).

Moreover, the hippocampus as well as the MTG seem to play important roles in retrieval of semantic knowledge about the use of a tool (Goldenberg and Randerath, 2015). Thus, corresponding lesions can cause pantomime impairments and lead to ideomotor apraxia (Speech et al., 1998). In addition, the hippocampus plays a role in movement planning (Dagher et al., 2001), motor learning (Schendan et al., 2003) and in retaining motor knowledge (Albouy et al., 2008). Therefore, the increased connectivity in patients may be a dysfunctional compensatory mechanism during the LKA task. Specifically, increased coupling of the IPL with the posterior hippocampus may reflect the attempt to retrieve temporospatial information from the hippocampus for movement planning, which is normally done in the IPL. Similarly, the association between CR performance and the connectivity of IPL to MTG in PD patients may point to a compensatory recall of motor engrams. In addition, one PET study showed the recruitment of the hippocampus to overcome the striatal deficits during planning of movement sequence in PD (Dagher et al., 2001). In addition, it was generally hypothesized that cortical reorganization in PD patients involves the modification of the type and strength of connectivity to maintain a normal performance (Husárová et al., 2013). However, whether increased connectivity with the IPL is the cause or the consequence of possible altered IPL function in PD needs to be further evaluated.

Furthermore, unlike controls, patients failed to connect the IPL functionally with the DLPFC during the LKA task. Decreased functional connectivity with the DLPFC during the LKA task is in line with studies examining general higher-level planning (de Bondt et al., 2016; Rowe et al., 2002). Moreover, the decreased coupling of the IPL with the DLPFC fits to one previous task-based fMRI study investigating novel and automatic finger sequences using a psycho-physiological interaction approach in PD (Wu et al., 2010a). The authors detected stronger functional connectivity of motor areas with the DLPFC during novel sequences in healthy subjects, showing that execution of more complex motor tasks, in contrast to automatic movements, shifted brain connectivity from more subcortical to more executive control areas compared to PD (Wu et al., 2010a). Accordingly, decreased IPL and DLPFC coupling in our patients may reflect impairments in executive functions (Trujillo et al., 2015) during the limb apraxia task, thereby adding to dexterous impairment.

Finally, the altered pattern of functional brain connectivity may be interpreted together with the differential neuronal activation of LKA and bradykinesia. PD patients often suffer from cognitive impairments in the course of the disease, specifically in memory and visual-spatial domains (Aarsland et al., 2010). Therefore, one may speculate that altered functional coupling together with the increased neural activation of brain areas of the praxis network reflects additional recruitment of regions to overcome general cognitive impairments in PD. Yet, it is unlikely that the detected altered pattern of activity and connectivity simply stem from cognitive performance deficits, particularly as cognitive performance (MMSE, digit span test) did not differ between patients and controls.

#### 4.3. Limitations

There are several limitations of our study. Patients with PD received medical treatment which may affect brain activation. In fact, if patients received medical treatment, they performed the fMRI task in best ON medication. The focus of our study, however, was on LKA underlying PD independent of confounding effects due to bradykinesia. Therefore, to minimize unspecific effects due to medication we controlled for the levodopa equivalent. Furthermore, studies on the effect of PD medication on brain activity are inconclusive (Cools et al., 2002; Fera et al., 2007; Haslinger et al., 2001; Jubault et al., 2009; Martinu et al., 2012; Rascol et al., 1994) and pinpoint to a normalizing effect of Levodopa on fMRI activation of PD patients (Haslinger et al., 2001; Ng et al., 2010). In addition, a general limitation of functional connectivity analysis with the PPI approach is that direction of connectivity between brain regions

cannot be detected (Friston et al., 1997) and may not follow structural routes. Further studies e.g. with diffusion tensor imaging need to explore structural connectivity alterations associated with LKA in PD. Finally, the adaption of the finger tapping task (involving three fingers) introduced elements of selective finger innervation that is a hallmark of Liepmann's LKA concept. Therefore, the modified paradigm for bradykinesia may have reduced the power of detecting specific differential activation with LKA as measured by the CR task.

#### 5. Conclusion

Our data demonstrates differentially altered activations within the praxis network of left hemisphere associated with LKA in PD. Moreover, for the first time, we provide evidence of decreased functional connectivity of the IPL with the DLPFC and increased connectivity of the IPL with the hippocampi, which may reflect an attempt to compensate for dexterous deficits. These results strongly support the notion that LKA, apart from bradykinesia, is implicated in dexterous deficits in PD. In addition, our findings demonstrate that CR is a valid clinical test for LKA in PD.

#### Funding

This work was supported by the Swiss National Fund [32003B\_155954] and by Parkinson Schweiz.

#### Acknowledgement

The authors would like to thank the participants for their time and commitment to this research.

#### Appendix A. Supplementary data

Supplementary data to this article can be found online at <http://dx.doi.org/10.1016/j.nicl.2017.07.007>.

#### References

- Aarsland, D., Bronnick, K., Williams-Gray, C., Weintraub, D., Marder, K., Kulisevsky, J., Burn, D., Barone, P., Pagonabarraga, J., Allcock, L., Santangelo, G., Foltynie, T., Janvin, C., Larsen, J.P., Barker, R.A., Emre, M., 2010. Mild cognitive impairment in Parkinson disease: a multicenter pooled analysis. *Neurology* 75, 1062–1069.
- Albouy, G., Sterpenich, V., Baletau, E., Vandewalle, G., Desseilles, M., Dang-Vu, T., Darsaud, A., Ruby, P., Luppi, P.H., Degueldre, C., Peigneux, P., Luxen, A., Maquet, P., 2008. Both the hippocampus and striatum are involved in consolidation of motor sequence memory. *Neuron* 58, 261–272.
- Ashburner, J., Friston, K.J., 2005. Unified segmentation. *NeuroImage* 26, 839–851.
- Babiloni, C., Carducci, F., Del Gratta, C., Demartin, M., Romani, G.L., Babiloni, F., Rossini, P.M., 2003. Hemispherical asymmetry in human SMA during voluntary simple unilateral movements. An fMRI study. *Cortex* 39, 293–305.
- Barkemeyer, C.A., Santa Maria, M.P., Browndyke, J.N., Callon, E.B., Dunn, A.M., 1998. The coin rotation task: a convenient and sensitive measure of fine motor control. *Arch. Clin. Neuropsychol.* 13, 18.
- Barrett, A.M., Schwartz, R.L., Raymer, A.L., Crucian, G.P., Rothi, L.G., Heilman, K.M., 1998. Dyssynchronous apraxia: failure to combine simultaneous preprogrammed movements. *Cogn. Neuropsychol.* 15, 685–703.
- Behrendt, R.-P., 2013. Conscious experience and episodic memory: hippocampus at the crossroads. *Front. Psychol.* 4, 304.
- Bohlhalter, S., 2009. Limb apraxia: a paradigmatic cognitive (psycho?) motor disorder. *Schweiz. Arch. Neurol. Psychiatr.* 160, 341–346.
- Bohlhalter, S., Abela, E., Hallett, M., 2011. Functional MRI of impaired finger dexterity in Parkinson's disease. *Exp. Neurol.* 227, 24–25.
- Borghammer, P., Østergaard, K., Cumming, P., Gjedde, A., Rodell, A., Hall, N., Chakravarty, M.M., 2010. A deformation-based morphometry study of patients with early-stage Parkinson's disease. *Eur. J. Neurol.* 17, 314–320.
- Borroni, B., Garibotto, V., Agosti, C., Brambati, S.M., Bellelli, G., Gasparotti, R., Padovani, A., Perani, D., 2008. White matter changes in corticobasal degeneration syndrome and correlation with limb apraxia. *Arch. Neurol.* 65, 796–801.
- Brandi, M.-L., Wohlschläger, A., Sorg, C., Hermsdörfer, J., 2014. The neural correlates of planning and executing actual tool use. *J. Neurosci.* 34, 13183–13194.
- Brett, M., Anton, J.-L., Valabregue, R., Poline, J.-B., 2002. Region of interest analysis using an SPM toolbox - abstract presented at the 8th international conference on functional mapping of the human brain, June 2–6, 2002, Sendai, Japan. *Neuroimage* 16 (abstract 497).



- Buhmann, C., Glauche, V., Stürenburg, H.J., Oechsner, M., Weiller, C., Büchel, C., 2003. Pharmacologically modulated fMRI - cortical responsiveness to levodopa in drug-naive hemiparkinsonian patients. *Brain* 126, 451–461.
- Buxbaum, L.J., Kyle, K., Grossman, M., Coslett, H.B., 2007. Left inferior parietal representations for skilled hand-object interactions: evidence from stroke and cortico-basal degeneration. *Cortex* 43, 411–423.
- Buxbaum, L.J., Shapiro, A.D., Coslett, H.B., 2014. Critical brain regions for tool-related and imitative actions: a componential analysis. *Brain* 137, 1971–1985.
- Choi, S.H., Na, D.L., Kang, E., Lee, K.M., Lee, S.W., Na, D.G., 2001. Functional magnetic resonance imaging during pantomiming tool-use gestures. *Exp. Brain Res.* 139, 311–317.
- Cools, R., Stefanova, E., Barker, R.A., Robbins, T.W., Owen, A.M., 2002. Dopaminergic modulation of high-level cognition in Parkinson's disease: the role of the prefrontal cortex revealed by PET. *Brain* 125, 584–594.
- Dagher, A., Owen, A.M., Boecker, H., Brooks, D.J., 2001. The role of the striatum and hippocampus in planning: a PET activation study in Parkinson's disease. *Brain* 124, 1020–1032.
- de Bondt, C.C., Gerrits, N.J.H.M., Veltman, D.J., Berendse, H.W., van den Heuvel, O.A., van der Werf, Y.D., 2016. Reduced task-related functional connectivity during a set-switching task in unmedicated early-stage Parkinson's disease patients. *BMC Neurosci.* 17, 20.
- Eckert, T., Peschel, T., Heinze, H.J., Rotte, M., 2006. Increased pre-SMA activation in early PD patients during simple self-initiated hand movements. *J. Neurol.* 253, 199–207.
- Eickhoff, S.B., Stephan, K.E., Mohlberg, H., Grefkes, C., Fink, G.R., Amunts, K., Zilles, K., 2005. A new SPM toolbox for combining probabilistic cytoarchitectonic maps and functional imaging data. *NeuroImage* 25, 1325–1335.
- Eldridge, L.L., Knowlton, B.J., Furmanski, C.S., Bookheimer, S.Y., Engel, S.A., 2000. Remembering episodes: a selective role for the hippocampus during retrieval. *Nat. Neurosci.* 3, 1149–1152.
- Fera, F., Nicoletti, G., Cerasa, A., Romeo, N., Gallo, O., Gioia, M.C., Arabia, G., Pugliese, P., Zappia, M., Quattrone, A., 2007. Dopaminergic modulation of cognitive interference after pharmacological washout in Parkinson's disease. *Brain Res. Bull.* 74, 75–83.
- Foki, T., Pirker, W., Klinger, N., Geißler, A., Rath, J., Steinkellner, T., Hoellinger, I., Gruber, S., Haubenberger, D., Lehrner, J., Pusswald, G., Trattinig, S., Auff, E., Beisteiner, R., 2010. fMRI correlates of apraxia in Parkinson's disease patients OFF medication. *Exp. Neurol.* 225, 416–422.
- Foki, T., Pirker, W., Geißler, A., Haubenberger, D., Hilbert, M., Hoellinger, I., Wurnig, M., Rath, J., Lehrner, J., Matt, E., Fischmeister, F., Trattinig, S., Auff, E., Beisteiner, R., 2015. Finger dexterity deficits in Parkinson's disease and somatosensory cortical dysfunction. *Parkinsonism Relat. Disord.* 21, 259–265.
- Foki, T., Vanbellingen, T., Lungu, C., Pirker, W., Bohlhalter, S., Nyffeler, T., Kraemmer, J., Haubenberger, D., Fischmeister, F.P.S., Auff, E., Hallett, M., Beisteiner, R., 2016. Limb-kinetic apraxia affects activities of daily living in Parkinson's disease: a multi-center study. *Eur. J. Neurol.* 8, 1301–1307.
- Folstein, M.F., Folstein, S.E., McHugh, P.R., 1975. "Mini-mental state". A practical method for grading the cognitive state of patients for the clinician. *J. Psychiatr. Res.* 12, 189–198.
- Freund, H.J., Hummelsheim, H., 1985. Lesions of premotor cortex in man. *Brain* 108 (Pt 3), 697–733.
- Fridman, E.A., Immisch, I., Hanakawa, T., Bohlhalter, S., Waldvogel, D., Kansaku, K., Wheaton, L., Wu, T., Hallett, M., 2006. The role of the dorsal stream for gesture production. *NeuroImage* 29, 417–428.
- Friston, K.J., Buechel, C., Fink, G.R., Morris, J., Rolls, E., Dolan, R.J., 1997. Psychophysiological and modulatory interactions in neuroimaging. *NeuroImage* 6, 218–229.
- Gebhardt, A., Vanbellingen, T., Baronti, F., Kersten, B., Bohlhalter, S., 2008. Poor dopaminergic response of impaired dexterity in Parkinson's disease: Bradykinesia or limb kinetic apraxia? *Mov. Disord.* 23, 1701–1706.
- Geschwind, N., 1975. The apraxias: neural mechanisms of disorders of learned movement. *Am. Sci.* 63, 188–195.
- Goetz, C.G., Stebbins, G.T., 2004. Assuring interrater reliability for the UPDRS motor section: utility of the UPDRS teaching tape. *Mov. Disord.* 19, 1453–1456.
- Goetz, C.G., Poewe, W., Rascol, O., Sampaio, C., Stebbins, G.T., Counsell, C., Giladi, N., Holloway, R.G., Moore, C.G., Wenning, G.K., Yahr, M.D., Seidl, L., 2004. Movement disorder society task force report on the Hoehn and Yahr staging scale: status and recommendations. *Mov. Disord.* 19, 1020–1028.
- Goetz, C.G., Tilley, B.C., Shaftman, S.R., Stebbins, G.T., Fahn, S., Martinez-Martin, P., Poewe, W., Sampaio, C., Stern, M.B., Dodel, R., Dubois, B., Holloway, R., Jankovic, J., Kulisevsky, J., Lang, A.E., Lees, A., Leurgans, S., LeWitt, P.A., Nyenhuis, D., Olanow, C.W., Rascol, O., Schrag, A., Teresi, J.A., van Hilten, J.J., LaPelle, N., 2008. Movement disorder society-sponsored revision of the unified Parkinson's disease rating scale (MDS-UPDRS): scale presentation and clinimetric testing results. *Mov. Disord.* 23, 2129–2170.
- Goldenberg, G., 2009. Apraxia and the parietal lobes. *Neuropsychologia* 47, 1449–1459.
- Goldenberg, G., Randerath, J., 2015. Shared neural substrates of apraxia and aphasia. *Neuropsychologia* 75, 40–49.
- Haaland, K.Y., Harrington, D.L., Knight, R.T., 2000. Neural representations of skilled movement. *Brain* 123 (Pt 1), 2306–2313.
- Haslinger, B., Erhard, P., Kämpfe, N., Boecker, H., Rummery, E., Schwaiger, M., Conrad, B., Ceballos-Baumann, A.O., 2001. Event-related functional magnetic resonance imaging in Parkinson's disease before and after levodopa. *Brain* 124 (Pt 3), 558–570.
- Heilman, K.M., 2010. Apraxia. *Contin.* 16, 86–98 (Minneapolis, Minn).
- Heilman, K.M., Rothi, L.J., Valenstein, E., 1982. Two forms of ideomotor apraxia. *Neurology* 32, 342–346.
- Helmich, R.C., Aarts, E., de Lange, F.P., Bloem, B.R., Toni, I., 2009. Increased dependence of action selection on recent motor history in Parkinson's disease. *J. Neurosci.* 29, 6105–6113.
- Herz, D.M., Eickhoff, S.B., Lökkegaard, A., Siebner, H.R., 2014. Functional neuroimaging of motor control in Parkinson's disease: a meta-analysis. *Hum. Brain Mapp.* 35, 3227–3237.
- Hill, B.D., Barkemeyer, C.A., Jones, G.N., Santa Maria, M.P., Minor, K.S., Browndyke, J.N., 2010. Validation of the coin rotation test: a simple, inexpensive, and convenient screening tool for impaired psychomotor processing speed. *Neurologist* 16, 249–253.
- Hughes, A.J., Ben-Shlomo, Y., Daniel, S.E., Lees, A.J., 1992. What features improve the accuracy of clinical diagnosis in Parkinson's disease: a clinicopathologic study. *Neurology* 42, 1142–1146.
- Husárová, I., Mikl, M., Lungu, O.V., Mareček, R., Vaníček, J., Bareš, M., 2013. Similar circuits but different connectivity patterns between the cerebellum, basal ganglia, and supplementary motor area in early Parkinson's disease patients and controls during predictive motor timing. *J. Neuroimaging* 23, 452–462.
- Imazu, S., Sugio, T., Tanaka, S., Inui, T., 2007. Differences between actual and imagined usage of chopsticks: an fMRI study. *Cortex* 43, 301–307.
- Jubault, T., Monetta, L., Strafella, A.P., Lafontaine, A.L., Monchi, O., 2009. L-dopa medication in Parkinson's disease restores activity in the motor cortico-striatal loop but does not modify the cognitive network. *PLoS One* 4.
- Kalisch, R., Korenfeld, E., Stephan, K.E., Weiskopf, N., Seymour, B., Dolan, R.J., 2006. Context-dependent human extinction memory is mediated by a ventromedial prefrontal and hippocampal network. *J. Neurosci.* 26, 9503–9511.
- Katschnig, P., Schwingschuh, P., Jehna, M., Svehlík, M., Petrovic, K., Ropele, S., Zwick, E.B., Ott, E., Fazekas, F., Schmidt, R., Enzinger, C., 2011. Altered functional organization of the motor system related to ankle movements in Parkinson's disease: insights from functional MRI. *J. Neural Transm.* 118, 783–793.
- Kolb, B., Milner, B., 1981. Performance of complex arm and facial movements after focal brain lesions. *Neuropsychologia* 19, 491–503.
- Koop, M.M., Shivitz, N., Bronté-Stewart, H., 2008. Quantitative measures of fine motor, limb, and postural bradykinesia in very early stage, untreated Parkinson's disease. *Mov. Disord.* 23, 1262–1268.
- Kraft, E., Loichinger, W., Diepers, M., Lule, D., Schwarz, J., Ludolph, A.C., Storch, A., 2009. Levodopa-induced striatal activation in Parkinson's disease: a functional MRI study. *Parkinsonism Relat. Disord.* 15, 558–563.
- Króliczak, G., Frey, S.H., 2009. A common network in the left cerebral hemisphere represents planning of tool use pantomimes and familiar intransitive gestures at the hand-independent level. *Cereb. Cortex* 19, 2396–2410.
- Landau, W.M., Mink, J.W., 2007. Is decreased dexterity in Parkinson disease due to apraxia? *Neurology* 68, 90–91.
- Leenders, K.L., Wolfson, L., Gibbs, J.M., Wise, R.J.S., Causon, R., Jones, T., Legg, N.J., Hospital, H., Road, D., 1985. The effects of L-DOPA on regional cerebral blood flow and oxygen metabolism in patients with Parkinson's disease. *Brain* 108 (Pt 1), 171–191.
- Lewis, M.M., Slagie, C.G., Smith, A.B., Truong, Y., Bai, P., McKeown, M.J., Mailman, R.B., Belger, A., Huang, X., 2007. Task specific influences of Parkinson's disease on the striato-thalamo-cortical and cerebello-thalamo-cortical motor circuitries. *Neuroscience* 147, 224–235.
- Mäki-Marttunen, V., Villarreal, M., Leiguarda, R.C., 2014. Lateralization of brain activity during motor planning of proximal and distal gestures. *Behav. Brain Res.* 272, 226–237.
- Mallol, R., Barrós-Loscertales, A., López, M., Belloch, V., Parcet, M.A., Ávila, C., 2007. Compensatory cortical mechanisms in Parkinson's disease evidenced with fMRI during the performance of pre-learned sequential movements. *Brain Res.* 1147, 265–271.
- Martini, K., Degroot, C., Madjar, C., Strafella, A.P., Monchi, O., 2012. Levodopa influences striatal activity but does not affect cortical hyper-activity in Parkinson's disease. *Eur. J. Neurosci.* 35, 572–583.
- Matt, E., Foki, T., Fischmeister, F., Pirker, W., Haubenberger, D., Rath, J., Lehrner, J., Auff, E., Beisteiner, R., 2016. Early dysfunctions of fronto-parietal praxis networks in Parkinson's disease. *Brain Imaging Behav.* 11, 512–525.
- Ng, B., Palmer, S., Abugharbieh, R., McKeown, M.J., 2010. Focusing effects of L-dopa in Parkinson's disease. *Hum. Brain Mapp.* 31, 88–97. <http://dx.doi.org/10.1002/hbm.20847>.
- Niessen, E., Fink, G.R., Weiss, P.H., 2014. Apraxia, pantomime and the parietal cortex. *NeuroImage Clin.* 5, 42–52.
- Nirkko, A.C., Ozdoba, C., Redmond, S.M., Bürki, M., Schroth, G., Hess, C.W., Wiesendanger, M., 2001. Different ipsilateral representations for distal and proximal movements in the sensorimotor cortex: activation and deactivation patterns. *NeuroImage* 13, 825–835.
- Ohgami, Y., Matsuo, K., Uchida, N., Nakai, T., 2004. An fMRI study of tool-use gestures: body part as object to pantomime. *Neuroreport* 15, 1903–1906.
- Okuda, B., Tachibana, H., Takeda, M., Kawabata, K., Sugita, M., 1998. Asymmetric changes in somatosensory evoked potentials correlate with limb apraxia in cortico-basal degeneration. *Acta Neurol. Scand.* 97, 409–412.
- Oldfield, R.C., 1971. The assessment and analysis of handedness: the Edinburgh inventory. *Neuropsychologia* 9, 97–113.
- Pause, M., Kuensch, E., Binkofski, F., Freund, H.-J., 1989. Sensorimotor disturbances in patients with lesions of the parietal cortex. *Brain* 112 (Pt 6), 1599–1625.
- Penfield, W., Welch, K., 1951. The supplementary motor area of the cerebral cortex. *AMA Arch. Neurol. Psychiatry* 66, 289–317.
- Playford, E.D., Jenkins, I.H., Passingham, R.E., Nutt, J., Frackowiak, R.S., Brooks, D.J., 1992. Impaired mesial frontal and putamen activation in Parkinson's disease: a positron emission tomography study. *Ann. Neurol.* 32, 151–161.
- Pohar, S.L., Allyson Jones, C., 2009. The burden of Parkinson disease (PD) and

- concomitant comorbidities. *Arch. Gerontol. Geriatr.* 49, 317–321.
- Postuma, R.B., Dagher, A., 2006. Basal ganglia functional connectivity based on a meta-analysis of 126 positron emission tomography and functional magnetic resonance imaging publications. *Cereb. Cortex* 16, 1508–1521.
- Potgieser, A.R.E., Van Der Hoorn, A., Meppelink, A.M., Teune, L.K., Koerts, J., De Jong, B.M., 2014. Anterior temporal atrophy and posterior progression in patients with Parkinson's disease. *Neurodegener. Dis.* 14, 125–132.
- Proud, E.L., Morris, M.E., 2010. Skilled hand dexterity in Parkinson's disease: effects of adding a concurrent task. *Arch. Phys. Med. Rehabil.* 91, 794–799.
- Quencer, K., Okun, M.S., Crucian, G., Fernandez, H.H., Skidmore, F., Heilman, K.M., 2007. Limb-kinetic apraxia in Parkinson disease. *Neurology* 68, 150–151.
- Rascol, O., Sabatini, U., Chollet, F., Celsis, P., Montastruc, J.L., Marc-Vergnes, J.P., Rascol, A., 1992. Supplementary and primary sensory motor area activity in Parkinson's disease. Regional cerebral blood flow changes during finger movements and effects of apomorphine. *Arch. Neurol.* 49, 144–148.
- Rascol, O., Sabatini, U., Chollet, F., Fabre, N., Senard, J.M., Montastruc, J.L., Celsis, P., Marc-Vergnes, J.P., Rascol, A., 1994. Normal activation of the supplementary motor area in patients with Parkinson's disease undergoing long-term treatment with levodopa. *J. Neurol. Neurosurg. Psychiatry* 57, 567–571.
- Reitan, R.M., 1969. Manual for Administration of Neuropsychological Test Batteries for Adults and Children. Indianap. Univ. Med. Cent.
- Rorden, C., Karnath, H.-O., Bonilha, L., 2007. Improving lesion-symptom mapping. *J. Cogn. Neurosci.* 19, 1081–1088.
- Rothi, L.J., Heilman, K.M., Watson, R.T., 1985. Pantomime comprehension and ideomotor apraxia. *J. Neurol. Neurosurg. Psychiatry* 48, 207–210.
- Rottschy, C., Kleiman, A., Dogan, I., Langner, R., Mirzazade, S., Kronenburger, M., Werner, C., Shah, N.J., Schulz, J.B., Eickhoff, S.B., Reetz, K., 2013. Diminished activation of motor working-memory networks in Parkinson's disease. *PLoS One* 8.
- Rowe, J., Stephan, K.E., Friston, K., Frackowiak, R., Lees, A., Passingham, R., 2002. Attention to action in Parkinson's disease: impaired effective connectivity among frontal cortical regions. *Brain* 125 (Pt 2), 276–289.
- Samuel, M., Ceballos-Baumann, A.O., Blin, J., Uema, T., Boecker, H., Passingham, R.E., Brooks, D.J., 1997. Evidence for lateral premotor and parietal overactivity in Parkinson's disease during sequential and bimanual movements a PET study. *Brain* 120 (Pt 6), 963–976.
- Schendan, H.E., Searl, M.M., Melrose, R.J., Stern, C.E., 2003. An fMRI study of the role of the medial temporal lobe in implicit and explicit sequence learning. *Neuron* 37, 1013–1025.
- Speech, D.P., Wong, T.M., Cattarin, J.A., Livecchi, M.A., 1998. Hypoxic brain injury with motor apraxia following an anaphylactic reaction to hymenoptera venom. *Brain Inj.* 12, 239–244.
- Stark, C.E., Squire, L.R., 2001. When zero is not zero: the problem of ambiguous baseline conditions in fMRI. *Proc. Natl. Acad. Sci. U. S. A.* 98, 12760–12766.
- Stepens, A., Stagg, C.J., Platka, A., Boudrias, M.-H., Johansen-Berg, H., Donaghy, M., 2010. White matter abnormalities in methcathinone abusers with an extrapyramidal syndrome. *Brain* 133 (Pt 12), 3676–3684.
- Swash, M., Landau, W.M., Mink, J.W., 2007. Limb-kinetic apraxia in Parkinson disease. *Neurology* 69, 810–811.
- Trujillo, J.P., Gerrits, N.J.H.M., Veltman, D.J., Berendse, H.W., van der Werf, Y.D., van den Heuvel, O.A., 2015. Reduced neural connectivity but increased task-related activity during working memory in de novo Parkinson patients. *Hum. Brain Mapp.* 36, 1554–1566.
- Tsuchiya, K., Uchihara, T., Oda, T., Arima, K., Ikeda, K., Shimada, H., 1997. Basal ganglia lesions in corticobasal degeneration differ from those in Pick's disease and progressive supranuclear palsy: a topographic neuropathological study of six autopsy cases. *Neuropathology* 17, 208–216.
- Vanbellinghen, T., Kersten, B., Bellion, M., Temperli, P., Baronti, F., Müri, R., Bohlhalter, S., 2011. Impaired finger dexterity in Parkinson's disease is associated with praxis function. *Brain Cogn.* 77, 48–52.
- Vingerhoets, G., Vandekerckhove, E., Honoré, P., Vandemaele, P., Achten, E., 2011. Neural correlates of pantomiming familiar and unfamiliar tools: action semantics versus mechanical problem solving? *Hum. Brain Mapp.* 32, 905–918.
- Vry, M.S., Tritschler, L.C., Hamzei, F., Rijntjes, M., Kaller, C.P., Hoeren, M., Umarova, R., Glauche, V., Hermsdoerfer, J., Goldenberg, G., Hennig, J., Weiller, C., 2015. The ventral fiber pathway for pantomime of object use. *NeuroImage* 106, 252–263.
- Watson, R.T., Fleet, W.S., Gonzalez-Rothi, L., Heilman, K.M., 1986. Apraxia and the supplementary motor area. *Arch. Neurol.* 43, 787–792.
- Wechsler, D., 1997. Wechsler Adult Intelligence Scale—3rd Edition (WAIS-3®). Harcourt Assessment, San Antonio, TX.
- Weder, B.J., Leenders, K.L., Vontobel, P., Nienhusmeier, M., Keel, A., Zaunbauer, W., Vonesch, T., Ludin, H., 1999. Impaired Somatosensory Discrimination of Shape in Parkinson's Disease: Association With Caudate Nucleus Dopaminergic Function. 12. pp. 1–12.
- Wu, T., Hallett, M., 2005. A functional MRI study of automatic movements in patients with Parkinson's disease. *Brain* 128 (Pt 10), 2250–2259.
- Wu, T., Chan, P., Hallett, M., 2010a. Automatic movements in PD patients effective connectivity of neural networks in automatic movements in Parkinson's disease. *NeuroImage* 49, 2581–2587.
- Wu, T., Wang, L., Hallett, M., Li, K., Chan, P., 2010b. Neural correlates of bimanual anti-phase and in-phase movements in Parkinson's disease. *Brain* 133 (Pt 8), 2394–2409. <http://dx.doi.org/10.1093/brain/awq151>.
- Yan, L.-R., Wu, Y.-B., Zeng, X.-H., Gao, L.-C., 2015. Dysfunctional putamen modulation during bimanual finger-to-thumb movement in patients with Parkinson's disease. *Front. Hum. Neurosci.* 9, 516.
- Yu, H., Sternad, D., Corcos, D.M., Vaillancourt, D.E., 2007. Role of hyperactive cerebellum and motor cortex in Parkinson's disease. *NeuroImage* 35, 222–233.