


Novel Approach to Endoscopic Foreign Body Retrieval From the Gastric Body

Journal of Investigative Medicine High
Impact Case Reports
Volume 9: 1–3
© 2021 American Federation for
Medical Research
DOI: 10.1177/23247096211040631
journals.sagepub.com/home/hic


Jason Cohen, MD¹, Samson Ferm, MD¹,
David Schwarzbaum, MD¹, Steven Tsistrakis, MD¹,
Syed Hussain, MD¹, and Sang Hoon Kim, MD¹

Abstract

Foreign body (FB) ingestion is a common occurrence in the United States with a reported incidence of 120 per 1 million people, accounting for up to 1500 fatalities annually. The majority of FB ingestions will pass through the gastrointestinal tract spontaneously, while in 10% to 20% of patients, intervention will be necessary. A variety of endoscopic devices can be utilized to facilitate FB removal from the gastrointestinal tract, including snares, retrieval nets, and grasping forceps. We report the case of a 58-year-old female who required utilization of endoscopic scissors for FB removal in the setting of multiple failed attempts with traditional methods. This case highlights a novel approach to gastric FB removal utilizing endoscopic scissor forceps, which should be considered in select cases to further improve the efficacy of endoscopic FB removal and reduce the need for surgical intervention.

Keywords

gastroenterology, foreign body removal, endoscopy, endoscopic scissors, gastric body

Introduction

Foreign body (FB) ingestion is a common occurrence in the United States with a reported incidence of 120 per 1 million people, accounting for up to 1500 fatalities annually.¹ In adults, impacted food is the most common FB ingested; however, various nonfood objects may be swallowed especially in patients with psychiatric illness.² The majority of FB ingestions will pass through the gastrointestinal tract spontaneously. In 10% to 20% of patients, intervention will be necessary; however, surgery is rarely needed.¹ Endoscopic intervention is the preferred modality for FB removal with success rates between 83% and 99%.¹

Endoscopic devices used in FB removal include snares, retrieval nets, and grasping forceps. Failure to remove an ingested FB has been mostly reported in cases associated with dental prostheses, or in complex or longer objects.¹ Endoscopic scissor forceps have been used for a variety of indications including bariatric procedures and mucosal resection, and are emerging as a valuable tool in the armamentarium. We add to the growing body of literature that describes the use of endoscissors in FB removal in the gastrointestinal tract.

Case Report

A 58-year-old female with past medical history of hypertension, pica, cerebral palsy, seizure disorder, severe cognitive

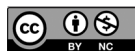deficiency, and bowel resection for FB ingestion with colostomy presented to our institution after dark red stool was noted in her colostomy bag by nursing staff. The patient had a history of multiple FB ingestions requiring both endoscopic and surgical removal. On presentation her vital signs were normal and physical examination revealed a soft, nontender abdomen. Laboratory test results were significant for a hemoglobin 10.6 g/dL. Computed tomography (CT) scan of the abdomen showed metallic foci in the stomach, presumably ingested material. The patient underwent initial endoscopy which revealed a large (5 × 3 cm) FB of unclear material in the gastric body (Figure 1). Removal was attempted with a snare but was unsuccessful as the FB was too large to safely pass through the gastroesophageal junction (Figure 2). In addition, the use of cold and hot snare was ineffective in attempting to break the FB down into smaller pieces. The patient was transferred back to the medical floors with the intent on repeating the endoscopy with endoscopic scissors.

Repeat endoscopy was then performed. An overtube was passed beyond the gastroesophageal junction and FB removal

¹New York-Presbyterian Queens, Flushing, NY, USA

Corresponding Author:

Jason Cohen, MD, Department of Internal Medicine, New York Presbyterian-Queens, 56-45 Main Street, Flushing, NY 11355, USA.
Email: Jcohen1353@gmail.com



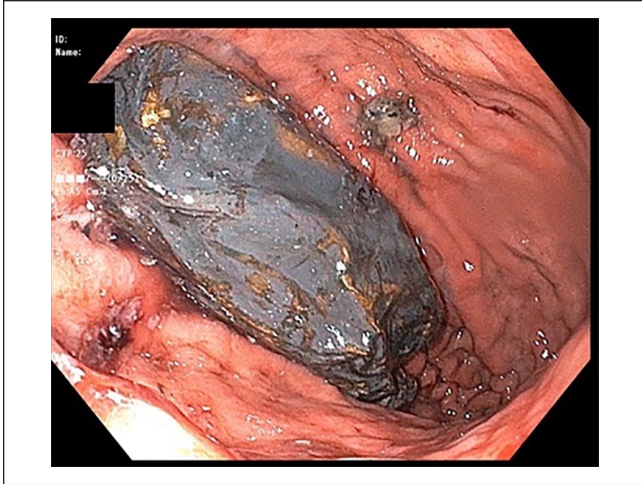


Figure 1. Large foreign body seen within the gastric corpus.

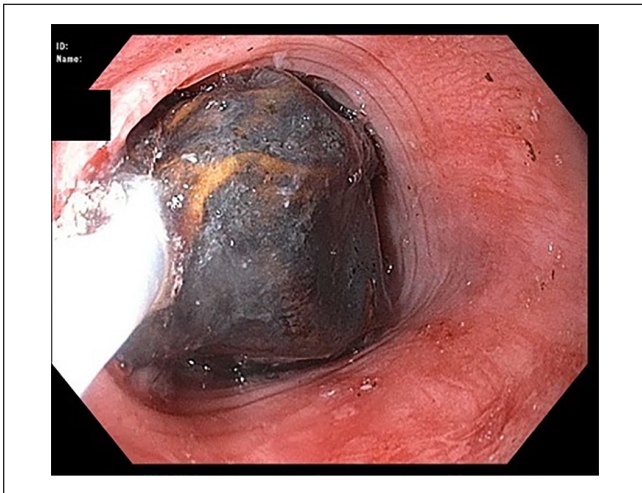


Figure 2. Foreign body unable to pass the gastroesophageal junction.

was again attempted with a snare. Retrieval was initially unsuccessful as the FB became lodged in the end of the overtube causing a fracture to the distal end of the overtube. The overtube was then removed and Ensizor Flexible Endoscopic Scissors (Apollo Endosurgery) were used to transect the FB into 2 pieces (Figure 3). The material ingested appeared to be a congealed and hardened plastic medical glove. The individual pieces were then successfully removed with a retrieval net and snare. The post-procedural course was uncomplicated and patient was discharged on post-procedure day 1.

Discussion

Endoscopic retrieval of a FB is an efficacious and safe procedure with a low morbidity rate.² Advancements in endoscopic techniques have limited the need for surgical intervention, which is currently reserved for cases of perforation or endoscopic failure.³

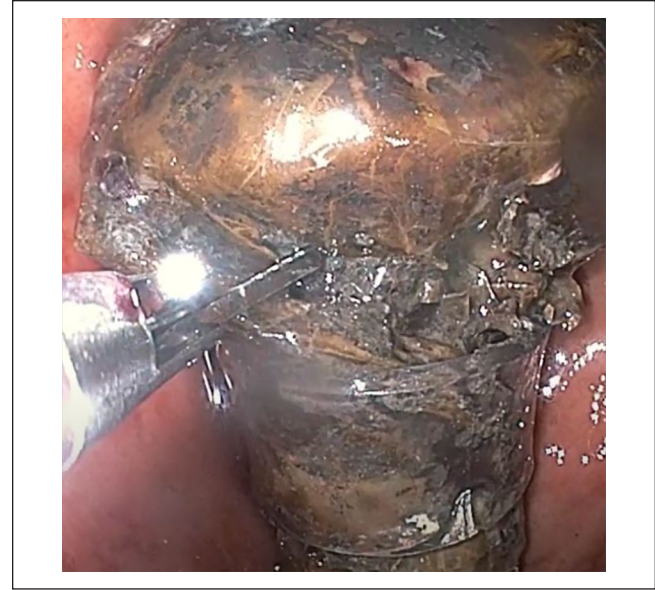

Figure 3. Endoscopic scissors being used to transect the foreign body.

Typically, a food bolus impaction can be retrieved in one piece using a snare. If necessary, a FB can be cut using a snare and removed in smaller pieces.² However, depending on the type of material ingested, this may not always be effective. In our patient, we were unsuccessful in removing the FB with a snare as it was too large to pass through the gastroesophageal junction. In addition, attempts to cut the FB with a cold and hot snare failed as well as the material had hardened and solidified, necessitating repeat endoscopy with the use of endoscopic scissors.

In a single-center retrospective study, 97.92% of 144 endoscopic FB removal procedures were successfully performed. The most commonly used endoscopic tools for FB removal included a snare (81 cases), rat tooth forceps (49 cases), and roth net (13 cases). FB removal was unsuccessful in 3 cases, with one requiring surgical intervention.¹ Endoscopic scissors were not used in any of the cases.

Endoscopic FB removal using endoscopic scissor forceps has been described in the literature. There have been multiple reports of the use of endoscissors in the removal of ingested chicken or fish bones from the esophagus.⁴⁻⁶ Barakat and colleagues⁷ described the use of endoscopic scissors to transect a migrated duodenal stent to facilitate removal. Similar to our case, Park and colleagues⁸ utilized endoscopic scissors to facilitate removal of a bundle of wires from the stomach of a patient with severe intellectual disability. The successful use of endoscopic scissors in our case allowed our patient to avoid the need for surgical FB removal. After an extensive review of the literature, this is one of the first reported cases of the use of endoscopic scissors to assist in FB removal from the stomach. This case highlights a novel approach to gastric FB removal, which should be considered in select

cases to further improve the efficacy of endoscopic FB removal and reduce the need for surgical intervention.

Authors' Note

This case report was initially presented as an abstract at the ACG Virtual Annual Meeting in October 2020.

Author Contributions

JC: Performed chart review, wrote initial draft, and contributed to editing.

SF: Performed chart review and contributed to writing and editing.

DS: Contributed to writing and editing.

ST: Performed chart review and contributed to writing and editing.

SH: Contributed to writing and editing, concept design, and article guarantor.

SHK: Contributed to writing and editing, and concept design.

All authors read and approved submission.

Declaration of Conflicting Interests

The author(s) declared no potential conflicts of interest with respect to the research, authorship, and/or publication of this article.

Funding

The author(s) received no financial support for the research, authorship, and/or publication of this article.

Ethics Approval

Our institution does not require ethical approval for reporting individual cases or case series.

Informed Consent

Informed consent for patient information to be published in this article was not obtained because all attempts were exhausted in trying to contact the decision maker/guardian.

References

1. Nassar E, Yacoub R, Raad D, Hallman J, Novak J. Foreign body endoscopy experience of a university based hospital. *Gastroenterol Res.* 2013;6:4-9.
2. Sugawa C, Ono H, Taleb M, Lucas CE. Endoscopic management of foreign bodies in the upper gastrointestinal tract: a review. *World J Gastrointest Endosc.* 2014;6:475-481.
3. Ambe P, Weber SA, Schauer M, Knoefel WT. Swallowed foreign bodies in adults. *Dtsch Arztebl Int.* 2012;109:869-875.
4. Kee WJ, Park CH, Chung KM, et al. Various applications of endoscopic scissors in difficult endoscopic interventions. *Endoscopy.* 2014;46:432-434.
5. Su X, He Q, Zhu Y, Zou P, Li M, Zou R. Utilization of endoscopy scissors for retrieval of esophageal embedded foreign body. *Am J Gastroenterol.* Published online February 18, 2021. doi:10.14309/ajg.0000000000001211
6. Farr CM, Pratt W. The scissors approach to a chicken bone lodged in the esophagus. *Gastrointest Endosc.* 1989;35:357.
7. Barakat MT, Kothari S, Banerjee S. Cut and paste: endoscopic management of a perforating biliary stent utilizing scissors and clips. *Dig Dis Sci.* 2018;63:2202-2205.
8. Park CK, Kim HD, Kim JY, et al. Endoscopic removal of tangled plastic wires in the stomach using an argon plasma coagulation and endoscopic scissors. *Korean J Helicobacter Upper Gastrointest Res.* 2015;15.