



# Cutaneous purpura of Sjögren syndrome successfully treated with hydroxychloroquine

Grace A. Hile, BS,<sup>a</sup> Lori Lowe, MD,<sup>b,c</sup> and J. Michelle Kahlenberg, MD, PhD<sup>d</sup>  
*Springfield, Illinois and Ann Arbor, Michigan*

**Key words:** Hydroxychloroquine; purpura; Sjögren syndrome.

## INTRODUCTION

Sjögren syndrome is a systemic autoimmune disease characterized by dry eyes (keratoconjunctivitis sicca) and dry mouth (xerostomia). Common cutaneous manifestations of Sjögren syndrome include xerosis, annular erythema, hypergammaglobulinemic purpura, and immunologic inflammatory conditions such as vasculitis (leukocytoclastic and urticarial).<sup>1</sup> The clinical manifestations of vasculitis depend on the degree of skin and blood vessel involvement and can range from petechiae to palpable purpura and widespread ecchymoses.<sup>2</sup> The findings often occur on the leg.<sup>3</sup> Here we present a case of Sjögren syndrome in which the primary cutaneous manifestations were ulcerated ecchymotic plaques that did not respond to high-dose prednisone but had an excellent response to hydroxychloroquine.

## CASE REPORT

We present a 58-year-old woman with a history significant for hypertension and hypothyroidism (status post thyroidectomy) who presented to the rheumatology clinic with a 9-month history of a rash on her lower extremities. Lesions began as pink macules that developed into nonhealing, ecchymotic, ulcerative plaques associated with pain and bleeding but no pruritus. The patient denied a history of xerosis or previous skin lesions. She reported years of intermittent alopecia, dry mouth with occasional painful sores, intermittent swollen

and painful lymph nodes, perpetual nausea, and fatigue. She reported no history of Raynaud phenomenon, ultraviolet light-induced skin changes, swollen or painful joints, shortness of breath, weakness, blood clots, or miscarriage.

On physical examination, the patient had a dry tongue. Schirmer testing found full wetting of the strips in 3 minutes. Skin examination found violaceous patches and plaques over her anterior legs in various stages of development. Her proximal thighs and knees had newer lesions composed of erythematous patches and ecchymoses. Other older lesions had central erosions with hemorrhagic crusting (Fig 1, A). The patient did not have lymphadenopathy or synovitis. A punch biopsy of the left shin found a superficial and deep perivascular lymphocytic infiltrate with dermal hemorrhage and scattered neutrophils. There was mild lymphohistiocytic inflammation in the subcutaneous fat. There was no leukocytoclastic vasculitis (Fig 1, B). Direct immunofluorescence results were normal, confirming the absence of immune complex-mediated vasculitis. Laboratory analysis was significant for positive anti-La antibody, ANA (1:160 speckled), normal platelets (418), and normal hemoglobin (14). Because of her history of dry mouth and anti-La antibody, a salivary gland biopsy was performed, which found focal lymphocytic sialadenitis (focus score of 1) confirming the diagnosis of Sjögren syndrome.

From Southern Illinois University School of Medicine<sup>a</sup> and the Departments of Dermatology,<sup>b</sup> Pathology,<sup>c</sup> and Internal Medicine, Division of Rheumatology,<sup>d</sup> University of Michigan.

Funding sources: Drs Kahlenberg and Lowe were partially supported by the National Institute of Arthritis and Musculoskeletal and Skin Diseases (NIAMS) of the National Institutes of Health under Award Numbers K08AR063668 and R03AR066337, respectively (both to Dr Kahlenberg), and Dr Hile was supported by a grant from the Rheumatology Research Foundation (to Dr Kahlenberg).

Conflicts of interest: None declared.

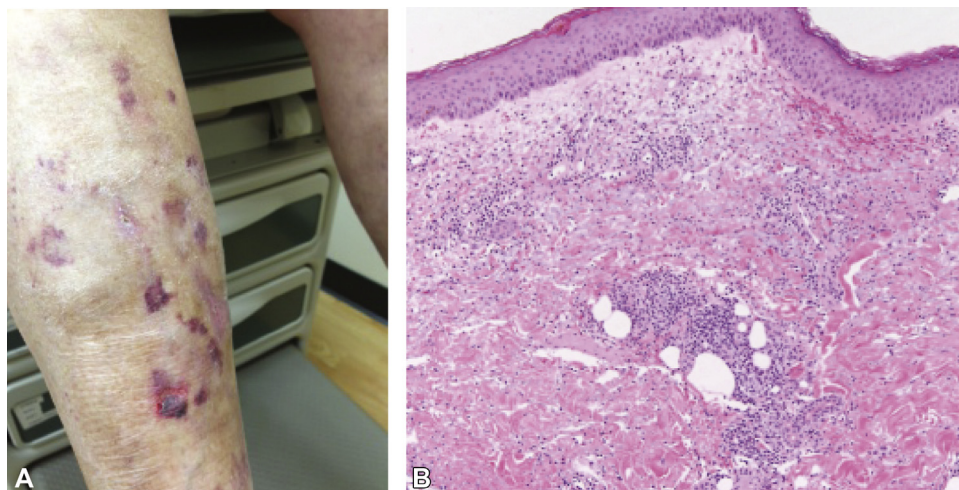
Correspondence to: J. Michelle Kahlenberg, MD, PhD, 5570A MSRB II 1150 E. Medical Center Drive, Ann Arbor, MI 48109-5678. E-mail: [mkahlenb@med.umich.edu](mailto:mkahlenb@med.umich.edu).

JAAD Case Reports 2017;3:326-8.

2352-5126

© 2017 by the American Academy of Dermatology, Inc. Published by Elsevier, Inc. This is an open access article under the CC BY-NC-ND license (<http://creativecommons.org/licenses/by-nc-nd/4.0/>).

<http://dx.doi.org/10.1016/j.jidcr.2017.04.011>



**Fig 1.** Cutaneous Sjögren syndrome. **A**, Right lower extremity shows edema, hyperpigmentation, ecchymoses, and denudation with hemorrhage. **B**, Skin biopsy section shows a superficial and deep, predominantly perivascular lymphocytic infiltrate with prominent dermal hemorrhage. (Hematoxylin-eosin stain; original magnification:  $\times 100$ .)

Because of the aggressive, ulcerative nature of the cutaneous lesions, the patient was initially treated with prednisone (60 mg daily followed by taper) and methotrexate (25 mg weekly) for 5.5 months. She tolerated methotrexate well. However, no improvement of her skin lesions was noted throughout this time. She continued to have ecchymoses and ulcerations on her lower extremities and also developed new lesions on her arms. Thus, methotrexate was discontinued, prednisone was gradually tapered, and the patient was placed on a trial of hydroxychloroquine (200 mg twice daily). After 5 months of treatment, the violaceous patches on the patient's extremities had faded and only postinflammatory hyperpigmentation remained. There were no areas of skin breakdown or crust. No new lesions were apparent. She continued taking hydroxychloroquine with no reported side effects.

## DISCUSSION

Autoimmune diseases can present with a wide range of cutaneous manifestations. Skin disease significantly increases morbidity for patients and increases cost of care. Skin manifestations are present in 16% to 50% of patients with Sjögren syndrome, most commonly xerosis, pruritus, annular erythema, or vasculitides.<sup>4-6</sup> Although half of those individuals with vasculitis have only a single episode, vasculitic involvement is associated with more severe disease<sup>7</sup> often requiring systemic treatment. Here we present a case of Sjögren syndrome in which the primary cutaneous manifestation was ulcerated ecchymoses without frank leukocytoclastic vasculitis. Our patient's skin lesions may best be

classified under the rubric of lymphocytic vasculitis, in which perivascular lymphocytic inflammation causes dermal hemorrhage, yet there is no fibrinoid necrosis of vessel walls, and the changes are not immune complex mediated. This may explain why our patient was unresponsive to high-dose prednisone but had an excellent response to hydroxychloroquine.

Although there are few reports that describe the efficacy of hydroxychloroquine for skin disease in Sjögren syndrome, hydroxychloroquine is widely used in the treatment of autoimmune skin diseases such as cutaneous lupus erythematosus. Both cutaneous lupus erythematosus and Sjögren syndrome are characterized by increased type I interferons and hyperactivation of B cells.<sup>8</sup> As hydroxychloroquine impacts generation of type I interferon responses through effects in the endolysosome<sup>9</sup> and through inhibition of stimulator of interferon gene activation, it is reasonable to assume that there would be an overlap in response to hydroxychloroquine between Sjögren syndrome and cutaneous lupus erythematosus hydroxychloroquine patients.<sup>10</sup> In systemic lupus erythematosus, there is evidence that hydroxychloroquine reduces flares and inhibits development of skin lesions.<sup>11</sup> Randomized, controlled trials in Sjögren syndrome have not found hydroxychloroquine to be beneficial for sicca symptoms,<sup>12</sup> but skin outcomes were not assessed. Certainly, some manifestations of Sjögren syndrome, such as annular erythema, are reported to respond positively to hydroxychloroquine.<sup>5</sup> For example, a patient with long-term primary Sjögren syndrome developed vasculitis after discontinuing hydroxychloroquine

because of retinal toxicity; the authors believed the skin lesions to be caused by interruption of the drug. A few reports suggest that hydroxychloroquine may be effective in treating systemic lupus erythematosus-related vasculitis. Kibune et al<sup>13</sup> described a patient with systemic lupus erythematosus who had purpura and recurrent cutaneous ulcers on the lower extremities diagnosed as leukocytoclastic and necrotizing vasculitis that responded favorably to hydroxychloroquine after developing toxicity to high-dose steroids. In Sjögren patients with various skin manifestations who are unresponsive or unable to tolerate high-dose steroids, hydroxychloroquine may be an effective option.

#### REFERENCES

1. Soy M, Piskin S. Cutaneous findings in patients with primary Sjogren's syndrome. *Clin Rheumatol*. 2007;26:1350-1352.
2. Roguedas AM, Misery L, Sassolas B, Le Masson G, Pennec YL, Youinou P. Cutaneous manifestations of primary Sjogren's syndrome are underestimated. *Clin Exp Rheumatol*. 2004;22:632-636.
3. Alexander EL, Provost TT. Cutaneous manifestations of primary Sjogren's syndrome: a reflection of vasculitis and association with anti-Ro(SSA) antibodies. *J Invest Dermatol*. 1983;80:386-391.
4. Rashtak S, Pittelkow MR. Skin involvement in systemic autoimmune diseases. *Curr Dir Autoimmun*. 2008;10:344-358.
5. Brito-Zeron P, Retamozo S, Akasbi M, et al. Annular erythema in primary Sjogren's syndrome: description of 43 non-Asian cases. *Lupus*. 2014;23:166-175.
6. Ramos-Casals M, Anaya JM, Garcia-Carrasco M, et al. Cutaneous vasculitis in primary Sjogren syndrome: classification and clinical significance of 52 patients. *Medicine*. 2004;83:96-106.
7. Scofield RH. Vasculitis in Sjogren's Syndrome. *Curr Rheumatol Rep*. 2011;13:482-488.
8. Nezos A, Gravani F, Tassidou A, et al. Type I and II interferon signatures in Sjogren's syndrome pathogenesis: Contributions in distinct clinical phenotypes and Sjogren's related lymphomagenesis. *J Autoimmun*. 2015;63:47-58.
9. Kuznik A, Bencina M, Svajger U, Jeras M, Rozman B, Jerala R. Mechanism of endosomal TLR inhibition by antimalarial drugs and imidazoquinolines. *J Immunol*. 2011;186:4794-4804.
10. An J, Minie M, Sasaki T, Woodward JJ, Elkon KB. Antimalarial drugs as immune modulators: new mechanisms for old drugs. *Annu Rev Med*. 2017;68:317-330.
11. The Canadian Hydroxychloroquine Study Group. A randomized study of the effect of withdrawing hydroxychloroquine sulfate in systemic lupus erythematosus. *N Engl J Med*. 1991;324:150-154.
12. Gottenberg JE, Ravaud P, Puechal X, et al. Effects of hydroxychloroquine on symptomatic improvement in primary Sjogren syndrome: the JOQUER randomized clinical trial. *JAMA*. 2014;312:249-258.
13. Kibune N, Shimomura Y, Hasegawa A, Saeki T, Umemori Y, Abe R. Beneficial effect of hydroxychloroquine on cutaneous vasculitis in a Japanese patient with systemic lupus erythematosus. *J Dermatol*. 2017;44:e52-e53.