

# Pulmonary arterial hypertension in interferonopathies: a case report and a review of the literature

A. Trombetta<sup>1</sup>, S. Ghirardo<sup>1</sup>, S. Pastore<sup>2</sup>, A. Tesser<sup>2</sup>, E. Piscianz<sup>2</sup>, A. Tommasini<sup>2</sup>, M. Bobbo<sup>2</sup> and A. Taddio<sup>1,2</sup>

<sup>1</sup>Department of Pediatrics, University of Trieste, Trieste, Italy; <sup>2</sup>Institute for Maternal and Child Health, "IRCCS Burlo Garofolo", Trieste, Italy

## Abstract

**Background:** Pulmonary arterial hypertension consists in an increase of mean pulmonary arterial pressure (PAPm  $\geq$  25 mmHg), and may lead to right ventricular failure. Pulmonary arterial hypertension can arise in several disorders, encompassing inflammatory conditions and connective tissue diseases. The occurrence of pulmonary arterial hypertension has recently been reported in monogenic interferonopathies and in systemic lupus erythematosus, highlighting the pathogenic role of type I interferons and paving the way to therapies aimed at inhibiting interferon signaling.

**Case:** We describe a 17-year-old boy with DNase II deficiency, presenting a clinical picture with significant overlap with systemic lupus erythematosus. During treatment with the Janus kinase inhibitor ruxolitinib, he developed pulmonary arterial hypertension, raising the question whether it could represent a sign of insufficient disease control or a drug-related adverse event. The disease even worsened after drug withdrawal, but rapidly improved after starting the drug again at higher dosage.

**Summary and conclusion:** Pulmonary arterial hypertension can complicate type I interferonopathies. We propose that ruxolitinib was beneficial in this case, but the wider role of Janus kinase inhibitors for the treatment of pulmonary arterial hypertension is not clear. For this reason, a strict cardiologic evaluation must be part of the standard care of subjects with interferonopathies, especially when Janus kinase inhibitors are prescribed.

## Keywords

DNase II deficiency, echocardiography, interferonopathies, Janus kinase inhibitors, pulmonary hypertension

Date received: 25 April 2019; accepted: 11 July 2019

Pulmonary Circulation 2019; 9(3) 1–4

DOI: 10.1177/2045894019869837

## Introduction

Interferonopathies are a group of disorders characterized by genetically determined imbalance in type-I interferon inflammation and by a significant clinical overlap with systemic lupus erythematosus.<sup>1</sup> Patients with interferonopathies (SLE), may develop complications in the lungs including pulmonary arterial hypertension (PAH).<sup>2</sup>

Pre-capillary pulmonary arterial hypertension is defined by the elevation of mean pulmonary arterial pressure at rest (mPAP  $\geq$  25 mmHg), with normal pulmonary arterial wedge pressure. Although a wide range of underlying causes can lead to this condition, in many cases, the pathogenesis remains unclear.<sup>3</sup>

We report a case of PAH in a 17-year-old boy with monogenic interferonopathy and systemic lupus erythematosus (SLE)-like features due to DNase II deficiency, treated with the Janus kinase inhibitor ruxolitinib to modulate interferon signaling.

## Case description

A 17-year-old boy was admitted to our hospital for weakness, palpitations and dyspnea. All symptoms were

Corresponding author:

A. Tommasini, Via dell'Istria 65/1, 34137 Trieste, Italy.

Email: [alberto.tommasini@burlo.trieste.it](mailto:alberto.tommasini@burlo.trieste.it)



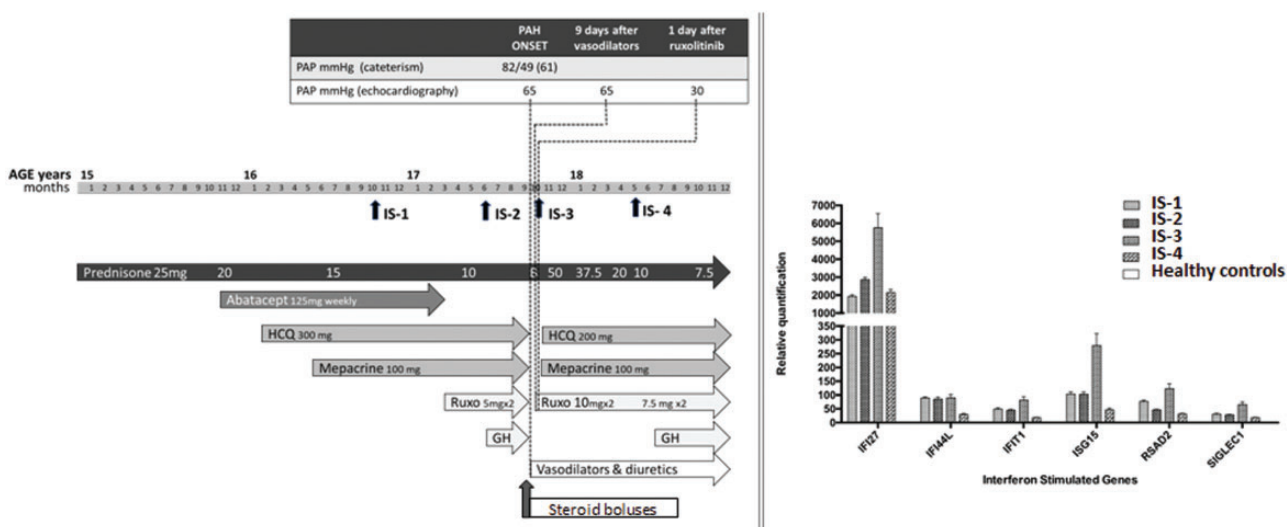
Creative Commons Non Commercial CC BY-NC: This article is distributed under the terms of the Creative Commons Attribution-NonCommercial 4.0 License (<http://www.creativecommons.org/licenses/by-nc/4.0/>) which permits non-commercial use, reproduction and distribution of the work without further permission provided the original work is attributed as specified on the SAGE and Open Access pages (<https://us.sagepub.com/en-us/nam/open-access-at-sage>).

© The Author(s) 2019.  
Article reuse guidelines:  
[sagepub.com/journals-permissions](http://sagepub.com/journals-permissions)  
[journals.sagepub.com/home/pul](http://journals.sagepub.com/home/pul)



exacerbated by minimal effort, and syncope was provoked by an argument with his father. Physical examination revealed paleness, cold extremities, accentuated second heart sound and a pansystolic heart murmur. The patient was in a follow-up program for DNase II deficiency syndrome,<sup>4</sup> a recently described auto-inflammatory disorder with significant overlap with SLE. One month before, he had a likely viral illness accompanied by tachycardia and general discomfort, self-improving in the following days. His medical history was characterized by the presence of neonatal hepatopathy, cytopenia, recurrent fever, polyarticular arthritis, chronic glomerulonephritis, lipodystrophy, lupus pernio and growth retardation. The suspicion of an interferonopathy was raised at the age of 14 years, based on the detection of an extremely high interferon signature score, and the diagnosis of DNase II deficiency was made by whole exome sequencing soon after. This clinical picture progressively worsened in the following years despite several therapeutic trials with glucocorticoids, immunosuppressant and biological agents. Considering recent data in support of a direct inhibitory effect of hydroxychloroquine and mepacrine on the signaling cascade of type I interferons,<sup>5</sup> we added these two antimalarials to therapy, noticing a partial improvement in the general assessment of the disease (Fig. 1). Due to concern about ongoing arthritis and given the poor response to anti-TNF biologics, we added abatacept. Despite significant improvements, the boy remained dependent on chronic glucocorticoids, complaining of joint stiffness and severe headache. We thus proposed an off-label use of ruxolitinib (7.5 mg twice a day), a Janus kinase inhibitor that had just been used with success in another interferonopathy<sup>6</sup> and discontinued abatacept. The introduction of ruxolitinib led to a dramatic improvement of the patient's clinical manifestations, allowing progressively reduce the dosage of glucocorticoids (Fig. 1).

At admission, five months after ruxolitinib introduction, echocardiography showed severe pulmonary hypertension with systolic PAP 77 mmHg and severe right ventricular dysfunction. Data were confirmed by cardiac catheterization that showed severe pre-capillary PAH with reduced cardiac index and a negative vasoreactivity test (PAP 82/49/61 mmHg, PAWP 11 mmHg, PVR 21.5 WU, CI 1.8 L/min/m<sup>2</sup>, data acquired under profound sedation). Pulmonary embolism was excluded by a normal CT pulmonary angiogram. Being the cardiologic evaluation with echocardiogram and electrocardiogram performed one year before completely normal, a drug-related serious adverse effect was considered, and all the treatments were discontinued. Conversely, assuming the possibility that PAH was instead an inflammatory manifestation of the underlying disease, similarly to what can sometimes occur in SLE, possibly triggered by a recent viral illness as occurred one month before in our patient, steroid boluses were administered, and a vasodilating therapy with epoprostenol, sildenafil and furosemide was started. However, during the hospital course, the boy developed a severe multilineal pancytopenia (Hb 10 g/dl, WBC 1020/mmc, PLT 20,000/mmc). Hemophagocytic Lymphohistiocytosis and malignancy were ruled out after performing a bone marrow aspiration that showed a hypocellular situation. Interferon signature score was higher than ever (Fig. 1). An active viral infection was also excluded. Given the poor response to corticosteroids and the raised interferon score, ruxolitinib was reintroduced at higher doses (10 mg twice daily), based on the previous benefits and on anecdotal evidence of efficacy in PAH.<sup>7</sup> A dramatic improvement of his pulmonary pressure recorded by echocardiogram was noted in just a day, being much more successful than expectable with vasodilating therapy only. The patient was discharged on inhaled iloprost 5 µg every 4 h, daily



**Fig. 1.** Interferon signature trend in the reported clinical case. IS-1: before starting Ruxolitinib; IS-2: in Ruxolitinib-before PAH; IS-3: during PAH. IS-4: after increasing ruxolitinib. The error bars reflect technical variability.

ambrisentan 5 mg, sildenafil 60 mg in three daily doses, and furosemide 12.5 mg every two days (Fig. 1), with an estimated systolic pulmonary pressure of 35 mmHg at echocardiography. His cardiologic follow-up showed a slow but progressive further improvement of symptoms and pulmonary pressure. Ruxolitinib was maintained at the dose of 7.5 mg BID. No further adverse event was noticed in the following two years, apart from asymptomatic BK-viruria and a transient herpes zoster infection, which rapidly healed with acyclovir therapy and slightly reducing ruxolitinib dose for one week.

## Discussion

Type I interferon inflammation can affect a wide range of organs and tissues. Pulmonary hypertension has been described in primary interferonopathies such as in STING associated vasculopathy with onset in infancy,<sup>8</sup> chronic atypical neutrophilic dermatosis with lipodystrophy and elevated temperature<sup>9</sup> and in Aicardi-Goutières syndrome.<sup>10</sup>

We report for the first time the presence of PAH in DNase II deficiency. The role that ruxolitinib played in our case is uncertain. On one hand, a previous report cautioned us about the possible worsening of ruxolitinib on PAH in a patient with myelofibrosis,<sup>11</sup> despite the evidence of efficacy of this drug in the treatment of myelofibrosis-associated PAH in larger series.<sup>7</sup>

On the other hand, the occurrence of PAH in our patient seemed unlikely to represent an adverse event caused by ruxolitinib, as we observed a rebound-inflammation with increased interferon score after stopping ruxolitinib, as previously reported in other interferonopathies,<sup>6</sup> without any improvement on mPAP, despite the start of vasodilators for a week. Conversely, a dramatic drop in mPAP was recorded the day after re-starting ruxolitinib at higher dosage, together with a reduction of the interferon score in the following days. Moreover, there are several evidence supporting a possible role of JAK inhibitors in the treatment of PAH.<sup>6</sup> First, JAK2-inhibitors can reduce the proliferation of pulmonary arterial endothelial cells in idiopathic PAH.<sup>12</sup> Second, the beneficial action of JAK2-inhibitors in PAH has been related to increased release of NO in animal models,<sup>7</sup> although it is uncertain if this was the mechanism in our clinical case, as the vasoreactivity test was negative.

Third, PAH has been associated to elevated interferon signature, in particular in the early phases of development<sup>13</sup> and can be induced by therapeutic administration of interferons in various disorders.<sup>14</sup>

We cannot be sure that the improvement noticed in our case was due to the addition of ruxolitinib; however, the rapid response to treatments supports a major role of inflammatory factors rather than vascular remodeling in our case.

In fact, it can be hard to disentangle between manifestations of the disease and the effects of treatments tailored to each patient without a consistent previous experience, as is

evident for orphan diseases. Moreover, JAK inhibitors may favor the development of viral illnesses that can contribute to trigger PAH in susceptible individuals. Even if we failed to detect specific viruses, we cannot exclude that a previous infection could have triggered the development of PAH one month before.

A recent study showed that subjects with monogenic interferonopathies can be treated with the JAK inhibitor baricitinib at twice-higher dosages than those used in rheumatoid arthritis, without complete suppression of the interferon signaling and with acceptable safety profile.<sup>10</sup> Similarly, even if our patient developed a herpes zoster during the ruxolitinib therapy, the outcome of the infection was favorable without the need of discontinuing the drug.

In conclusion, we highlight the necessity to refer patients with primary interferonopathy to a pediatric cardiologist for scheduled evaluations with echocardiography, in particular when prescribing new treatments.

## Authors' note

Written consent was obtained.

## Authors' contribution

A Trombetta and S Ghirardo drafted the article, S Pastore contributed to acquisition and interpretation of the data and drafted the article, A Tesser, E Piscianz and M Bobbo contributed to acquisition and interpretation of the data, A Tommasini drafted and critically revised the article, A Taddio critically revised the article and gave final approval. All authors approved the final version of the article as submitted.

## Conflict of interest

The author(s) declare that there is no conflict of interest.

## Funding

The study was funded by the IRCCS Burlo Garofolo Institute, grant RC24/17 and by the Telethon Foundation, grant GGPI5241.

## References

- Volpi S, Picco P, Caorsi R, et al. Type I interferonopathies in pediatric rheumatology. *Pediatr Rheumatol Online J* 2016; 14: 35.
- Dhala A. Pulmonary arterial hypertension in systemic lupus erythematosus: current status and future direction. *Clin Dev Immunol* 2012; 2012: 854941.
- Galiè N, Humbert M, Vachiery JL, et al. 2015 ESC/ERS Guidelines for the diagnosis and treatment of pulmonary hypertension: the Joint Task Force for the Diagnosis and Treatment of Pulmonary Hypertension of the European Society of Cardiology (ESC) and the European Respiratory Society (ERS): Endorsed by: Association for European Paediatric and Congenital Cardiology (AEPC), International Society for Heart and Lung Transplantation (ISHLT). *Eur Heart J* 2016; 37: 67–119.

4. Rodero MP, Tesser A, Bartok E, et al. Type I interferon-mediated autoinflammation due to DNase II deficiency. *Nat Commun* 2017; 8: 2176.
5. An J, Woodward JJ, Sasaki T, et al. Cutting edge: antimalarial drugs inhibit IFN- $\beta$  production through blockade of cyclic GMP-AMP synthase–DNA interaction. *J Immunol* 2015; 194: 4089–4093.
6. Frémond M-L, Rodero MP, Jeremiah N, et al. Efficacy of the Janus kinase 1/2 inhibitor ruxolitinib in the treatment of vasculopathy associated with TMEM173-activating mutations in 3 children. *J Allergy Clin Immunol* 2016; 138: 1752–1755.
7. Tabarrokhi A, Lindner DJ, Visconte V, et al. Ruxolitinib leads to improvement of pulmonary hypertension in patients with myelofibrosis. *Leukemia* 2014; 28: 1486–1493.
8. Kim H, Sanchez GA and Goldbach-Mansky R. Insights from Mendelian Interferonopathies: comparison of CANDLE, SAVI with AGS, Monogenic Lupus. *J Mol Med (Berl)* 2016; 94: 1111–1127.
9. Sanchez GAM, Reinhardt A, Ramsey S, et al. JAK1/2 inhibition with baricitinib in the treatment of autoinflammatory interferonopathies. *J Clin Invest* 2018; 128: 3041–3052.
10. Adang LA, Frank DB, Gilani A, et al. Aicardi Goutières syndrome is associated with pulmonary hypertension. *Mol Genet Metab* 2018; 125: 351–358.
11. Low AT, Howard L, Harrison C, et al. Pulmonary arterial hypertension exacerbated by ruxolitinib. *Haematologica* 2015; 100: e244–e245.
12. Masri FA, Xu W, Comhair SA, et al. Hyperproliferative apoptosis-resistant endothelial cells in idiopathic pulmonary arterial hypertension. *Am J Physiol Lung Cell Mol Physiol* 2007; 293: L548–L554.
13. George PM, Oliver E, Dorfmueller P, et al. Evidence for the involvement of type I interferon in pulmonary arterial hypertension. *Circ Res* 2013; 114: 677–688.
14. Savale L, Chaumais MC, Sitbon O, et al. Pulmonary arterial hypertension in patients treated with interferon. *Eur Respir J* 2015; 46: 1851–1853.