

Dysembryoplastic neuroepithelial tumor: A rare brain tumor not to be misdiagnosed

Deepti Sukheeja^{1,2}, Jayanti Mehta^{1,2}

¹Department of Pathology, Government Medical College and Associated Group of Hospitals, Kota, ²Department of Pathology, SMS Medical College, Jaipur, Rajasthan, India

ABSTRACT

Dysembryoplastic neuroepithelial tumor (DNET) is a recently described, morphologically unique, and surgically curable low-grade brain tumor which is included in the latest WHO classification as neuronal and mixed neuronal-glia tumor. It is usually seen in children and young adults. The importance of this particular entity is that it is a surgically curable neuroepithelial neoplasm. When recognized, the need for adjuvant radiotherapy and chemotherapy is obviated. We hereby present a case report of an 8-year-old male child who presented with intractable seizures and parieto-occipital space occupying lesion. Histologically, the tumor exhibited features of WHO grade I dysembryoplastic neuroepithelial tumor which was further confirmed by immunohistochemistry.

Key words: Child, dysembryoplastic neuroepithelial tumor, histopathology

Introduction

Dysembryoplastic neuroepithelial tumor (DNET) is a recently described, morphologically unique low-grade brain tumor of the pediatric group. It is included in WHO 2007 classification as neuronal and mixed neuronal-glia tumor. Incidence among all neuroepithelial tumors is 1.2% in patients under 20 years and 0.2% in age over 20 years. The importance of identifying this particular entity is that it is a surgically curable, nonrecurring tumor with an excellent prognosis.

Case Report

An 8-year-old male child presented with intractable seizures since 3 years which were refractory to antiepileptic drugs. There were no neurological deficits, and other systemic examination was normal. Magnetic resonance imaging showed a cystic space occupying lesion divided by multiple septa in the cortex (“pseudo-polycystic appearance”) of

the parieto-occipital region. There was no mass effect or peritumoral edema.

Craniotomy and removal of tumor tissue were done. Several tumor bits of dirty- gray color measuring 5-10 mm each were submitted for histopathology. Histopathology revealed fragmented tumor bits comprising cortical tissue showing large neurons and small oligodendroglial-like cells (OLCs), focal microcystic change along with mucinous matrix. The OLCs were arranged along the ramifying capillaries (perpendicular to the cortical surface) and separated by the mucinous matrix in which well-differentiated neurons appeared to float [Figure 1]. There was no mitosis. The background showed an architectural disorganization of the cortex. The diagnosis of DNET was made which was further confirmed on immunohistochemistry. Glial fibrillary acidic protein (GFAP) was positive showing stellate immunoreactive astrocytes and Neuronal cell processes were synaptophysin positive [Figure 2]. The patient was followed up for 2 years and was doing well.

Discussion

The term DNET was proposed by Daumas-Duport.^[1] Its first description dates back to 1988. Originally thought to have a

This is an open access article distributed under the terms of the Creative Commons Attribution-NonCommercial-ShareAlike 3.0 License, which allows others to remix, tweak, and build upon the work non-commercially, as long as the author is credited and the new creations are licensed under the identical terms.

For reprints contact: reprints@medknow.com

Access this article online	
Quick Response Code:	Website: www.asianjns.org
	DOI: 10.4103/1793-5482.175643

Address for correspondence:

Dr. Deepti Sukheeja, C/O Mr. O.P. Sukheeja,
1, Vigyan Nagar Special, Near P and T Colony,
Vigyan Nagar, Kota - 324 005, Rajasthan, India.
E-mail: deeptisukheeja2001@yahoo.co.in

How to cite this article: Sukheeja D, Mehta J. Dysembryoplastic neuroepithelial tumor: A rare brain tumor not to be misdiagnosed. Asian J Neurosurg 2016;11:174.

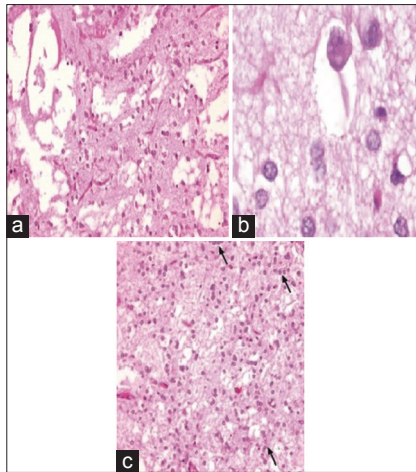


Figure 1: (a) Tissue section showing cystic spaces in cortical tissue. (b) Floating ganglion cells in microcystic spaces (c) Tissue section showing oligodendroglial like cells (OLCs) in fibrillary background arranged in columns at many places

dysembryogenetic origin, but debate still continues about their true nature. The tumor is characterized by supratentorial intracortical location, multinodular architecture, and heterogenous cellular composition occurring in young patients with medically intractable epileptic seizures. Although temporal lobe is the most common location, tumors in frontal and parietal locations, parieto-occipital location,^[2] and pontomesencephalic junction^[3] have been reported.

The principal differential diagnosis is oligodendrogliomas and gangliogliomas. Oligodendroglioma is located in cortex and white matter. The absence of floating neurons with GFAP and synaptophysin negativity can help in ruling out the oligodendroglioma. Gangliogliomas are, however, positive for GFAP and synaptophysin but radiologically present as a cystic mass with mural nodule. They show neoplastic ganglion cells and perivascular lymphocytic infiltrate. Although many cases of DNETs have been reported, only 2 of them until date have turned malignant, one of which occurred after radiation therapy.^[4]

Conclusion

DNETs are clinically benign, nonrecurring tumor of young adults. It may assume the guises of oligodendroglioma, oligoastrocytoma, pilocytic astrocytoma, and ganglioglioma.

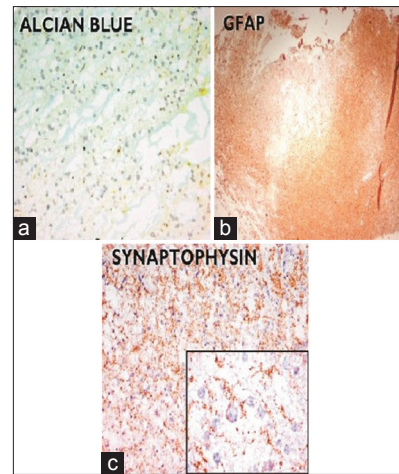


Figure 2: (a) Alcian blue stain showing mucinous material in cystic spaces. (b) Immunohistochemistry with glial fibrillary acidic protein showing glial nodules. (c) Synaptophysin positive neuronal cell processes

Surgery forms the mainstay of treatment. Careful observation of entire tissue sample is necessary before giving the diagnosis of its differentials, especially when the architecture is distorted due to inadvertent surgical aspiration or fragmentation due to fixation. When recognized the need for adjuvant radiotherapy and chemotherapy is obviated. Hence, identification of this tumor has therapeutic and prognostic implications because aggressive therapy can be avoided, sparing the young patients from deleterious long-term effects of radio and chemotherapy.

Financial support and sponsorship

Nil.

Conflicts of interest

There are no conflicts of interest.

References

1. Daumas-Duport C. Dysembryoplastic neuroepithelial tumours. *Brain Pathol* 1993;3:283-95.
2. Arbol D, Gandotra P, Maqbool M, Shah A, Ahmad S. Dysembryoplastic neuroepithelial tumor: A rare brain tumor presenting with atypical radiological findings. *JK Sci* 2007;9:145-7.
3. Hoehn D, Konoplev S, Yin C. Unusual presentation of a dysembryoplastic neuroepithelial tumor mimicking a pontomesencephalic cavernous hemangioma. *J Med Cases* 2012;3:375-8.
4. Hammond RR, Duggal N, Woulfe JM, Girvin JP. Malignant transformation of a dysembryoplastic neuroepithelial tumor. Case report. *J Neurosurg* 2000;92:722-5.