

Treatment of intracranial hemorrhage with neuroendoscopy guided by body surface projection

Shengli Qiu, MD*, Tao Liu, MD, Guanghui Cao, MD, Kun Wu, MD, Tingsheng Zhao, MD

Abstract

Background: We aimed to study the feasibility of body surface projection in neuroendoscopic treatment of intracranial hemorrhage (ICH), and to evaluate the prognosis of muscle strength using diffusion tensor imaging (DTI) technique.

Methods: We utilized 3D-SLICER software and adopted hematoma body surface projection orientation to eliminate ICH by using neuroendoscope for 69 cases of spontaneous intracerebral hemorrhage. The standard of correct location was determined by the direct view of hematoma at the first operation. Evacuation rate by comparing computed tomography (CT) before and after the surgery and Glasgow coma scale (GCS) was computed. DTI was used for pyramidal tract imaging 3 weeks after the operation, while the prognosis of muscle strength was assessed after 6 months. The control group included 69 patients with basal ganglia hemorrhage who received conservative treatment during the same period.

Results: The hematoma evacuation rate was 90.75% in average. The average GCS score rose by 4 points one week after the surgery. The shape of pyramidal tract affected the prognosis of body muscle strength, and the simple disruption type was the worst. There was no difference in mortality between the surgery group (10.1%) and the conservative group (4.3%). The muscle strength improvement value and modulate RANK score (MRS) in the surgery group were better than the control group.

Conclusion: It is convenient and feasible to use the surface projection to determine the target of operation, and the clearance rate of hematoma is high. Pyramidal tract imaging can predict the prognosis of muscle strength.

Abbreviations: ANOVA = A One-Way analysis of variance, CT = computed tomography, DTI = diffusion tensor imaging, FA = flip angle, FOV = field of view, FT = fiber tracking, GCS = Glasgow coma scale, HICH = hypertensive ICH, ICH = intracranial hemorrhage, LSD = least significant difference, MR = Magnetic resonance, MRS = modulate RANK score, ROI = regions of interest, SD = standard deviation, TE = echo times, TR = repetition time.

Keywords: body surface projection, cerebral hemorrhage, neuroendoscopy, pyramidal tract imaging

1. Introduction

Intracerebral hemorrhage (ICH) is a serious cerebrovascular disease with high mortality and disability rate, which accounts for about 10% to 20% of all stroke.^[1] Hypertension is the leading cause of ICH, which is responsible for more than 50% of cases of ICH.^[2] Hemorrhage of the basal ganglia region is common in hypertensive patients. Epidemiological data show that hypertensive ICH (HICH) frequently occurs in middle-aged

people aged 45 to 65 years, and the 1-year survival rate of patients with HICH is 50%, while the 5-year survival rate dropped to only 29.2%.^[3] Besides, most of the survivors have severe neurological dysfunction, which poses a huge burden on society and families.^[4] Therefore, it is necessary to deeply investigate therapeutic strategies.

Conservative treatment for ICH is the most basic therapeutic choice. However, evidence has demonstrated that patients with hemorrhage volume of more than 60 ml who underwent conservative treatment had a predicted 30-day mortality of 91%.^[5] At present, the pathophysiological mechanism of ICH still remains unclear. It is widely accepted that the hematoma caused by ICH can not only cause mechanical damage to the surrounding tissues, but also lead to secondary injury caused by free radical formation, peripheral brain tissue edema, inflammatory response, the clotting cascade, blood clots or blood degradation products.^[6,7] So far, multiple clinical trials have failed to find a clinical benefit of hemorrhage evacuation.^[8] Several lines of evidence suggest that the removal of intracranial hematoma is beneficial to reduce the space-occupying effects of hematoma, intracranial pressure and the toxic damage of hematoma degradation products to brain tissues, as well as ameliorate cerebral perfusion.^[7,9-11]

With the development of the concept of minimally invasive surgery, and the continuous update of surgical instruments, minimally invasive surgery has been receiving increasing

Editor: Xiaoxing Xiong.

The authors report no conflicts of interest.

Department of neurosurgery, The Second People's Hospital of Hefei, Hefei Hospital Affiliated to Medical University of Anhui, Hefei, China.

* Correspondence: Shengli Qiu, Department of neurosurgery, The Second People's Hospital of Hefei, Hefei Hospital Affiliated to Medical University of Anhui, Guangde Road, Yaohai District, Hefei 230011, China (e-mail: qiu_shli@163.com).

Copyright © 2019 the Author(s). Published by Wolters Kluwer Health, Inc. This is an open access article distributed under the terms of the Creative Commons Attribution-Non Commercial-No Derivatives License 4.0 (CCBY-NC-ND), where it is permissible to download and share the work provided it is properly cited. The work cannot be changed in any way or used commercially without permission from the journal.

Medicine (2019) 98:19(e15503)

Received: 8 November 2018 / Received in final form: 25 February 2019 / Accepted: 11 April 2019

<http://dx.doi.org/10.1097/MD.00000000000015503>

attentions of clinicians. This procedure avoids the surgical trauma associated with conventional craniotomy and achieves excellent therapeutic efficacy. Minimally invasive hematoma evacuation using a neuroendoscope might be an important and active therapeutic tool for treatment of ICH. Previously, a single-center trial by Auer et al^[12] published in 1989 demonstrating the safety and feasibility of endoscopic minimally invasive surgery for treatment of ICH, which achieved the desire for ICH evacuation, and opened up a new method of minimally invasive surgery for ICH evacuation. Investigators randomized 100 ICH patients, the results showed that most patients had a significant reduction of hematoma volume after endoscope-assisted evacuation and experienced lower mortality and morbidity rates. Neuroendoscope-assisted technique for evacuation of ICH is performed especially via the forehead approach, which is parallel to the pyramidal tract, decreasing the surgical injury to the greatest extent. The endoscopic evacuation avoids the injury of peripheral brain tissues and blood vessels caused by blind puncture and excessive suction, thereby reducing the risk of re-bleeding. A large quantity of evidence has revealed that endoscopic hematoma evacuation rate through endoscopic surgery ranged from 87.0% to 99.0%.^[13,14] Thus, endoscopic surgery has increasingly recognized as minimally invasive and safe surgery for ICH. However, little was known about the effect of endoscopic hematoma evacuation on the prognosis of muscle strength in patients with ICH.

Our study was designed to investigate the feasibility of neuroendoscopy guided by body surface projection for treatment of ICH, and the prognosis of muscle strength.

2. Materials and methods

2.1. General data

We consecutively enrolled 69 cases of cerebral hemorrhage patients admitted to the Department of neurosurgery at The Second People's Hospital of Hefei between March 2013 and February 2017 in accordance with China recommendations for diagnostic standard of HICH. There were 43 males aged 52.37 ± 12.53 years and 26 females aged 56.27 ± 9.34 years. Of the 69 participants, 16 patients with HICH breaking into lateral ventricles were included in this study. Volume of intracerebral hematoma was 33.12 ± 1.48 mL according to Tada Formula measurement. All patients had a history of hypertension. Preoperative neurological status was assessed using the Glasgow coma scale (GCS) score: 49 cases with GCS score of 8 to 12 and 20 cases with GCS score of 13 to 15. During the same period, 69 patients with cerebral hemorrhage who received conservative treatment were enrolled as the control group. Written informed consent was obtained from each subject and the study was approved by the Institutional Ethics Committee.

2.2. Technical device

The endoscope used for the surgery was zero-degree operating rigid endoscope (STORZ, Tuttlingen, Germany) with an outer diameter of 4 mm and a length of 180 mm, and a working channel was established using a disposable transparent tissue expander. In addition, high frequency unipolar or bipolar electrocoagulation probe, special digital camera system and self-made flush suction device and extended bipolar electrocoagulator were also used in this surgery.

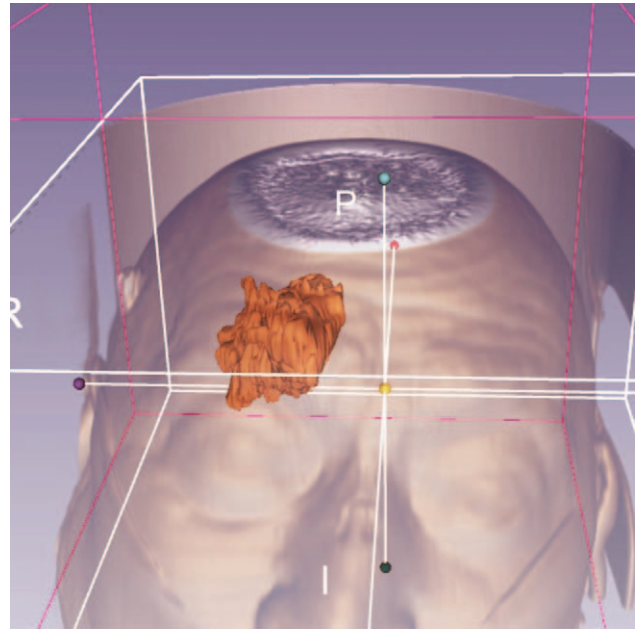


Figure 1. Images of body surface projection showing intracerebral hematoma.

2.3. Surgical procedures

3D Slicer software was used to visualize 3D reconstruction of the patients skull, and hematoma body surface projection was shown on the corresponding position of the patient's skull (Fig. 1). The lowest and deepest points of hematoma were selected as targets that determined the angle and depth of puncture. The surgical procedure was performed under general anesthesia with endotracheal intubation. A 3 cm coronal linear skin incision was made lateral to the midline over the frontal area. The burr hole was enlarged to 2.5 cm in diameter by small bone window craniotomy. The dura was cut open to avoid brain functional areas and cerebral cortical vessels. Hematoma puncture was performed along the long axis of the hematoma. The needles were pulled out till the hematoma is located. A disposable transparent tissue expander was slowly placed along the puncture path, reaching the posterior pole of the hematoma. Afterward, endoscope was put into the hematoma cavity, and then liquefied blood was sucked out with a self-made suction irrigator. The endoscope was rotated in the hematoma cavity, and tissue expander was moved along the long axis of hematoma. The endoscopic angle was adjusted to detect the blind angle of the hematoma and to clear the hematoma. A reliable hemostasis was also required. When the blood clot was removed and junctional regions with the "strawberry" shape were visible, the operation can be terminated (Fig. 2). After the operation, the hematoma cavity was equipped with a silicone catheter connected to a standard drainage bag. After anesthesia resuscitation, head computed tomography (CT) was routinely reviewed, and antihypertensive drugs were continuously pumped by micro-pump to control blood pressure below 120–169/70–90 mmHg. The head CT was reviewed before the extubation, and the drainage tube was removed after no recurrence of hematoma.

2.4. Assessment of muscle strength

Diffusion tensor imaging (DTI) were post-processed in GE ADW4.5 workstation with the following acquisition parameters:

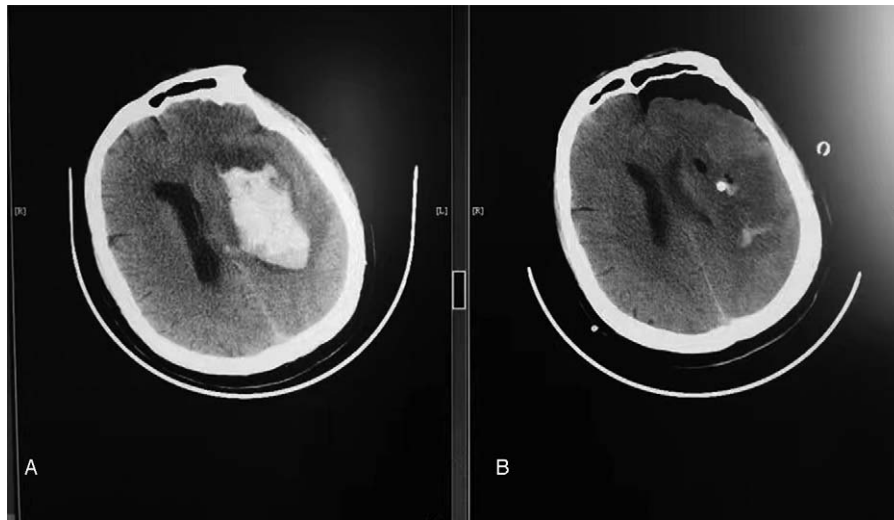


Figure 2. CT images showing the hematoma clearance rate before (A) and after (B) operation.

repetition time (TR) ≥ 8000 ms, echo times (TE) = 49 ms, slice thickness = 3.0 mm, field of view (FOV) = 2.4 cm^2 , data matrix = 128×128 , measurement time = 130 s [flip angle (FA) threshold = 0.20, angle threshold = 65°]. A logical AND operator was successively applied between brainstem and central frontal gyrus in both hemispheres as regions of interest (ROI). All patients were followed up for 6 months. The prognosis of muscle strength was obtained by subtracting preoperative muscle strength from the level of recovery of limb muscle strength. DTI classification was conducted according to the situation of pyramidal tracts damage: type I: simple displacement caused by lesions or hematoma occupying effect; type II: displacement with disruption caused by direct compression or infiltration of lesions or hematoma and type III: simple disruption caused by of lesion infiltration.^[15]

2.5. Statistical analysis

All statistical analyses were conducted using SPSS version 16.0 (SPSS Inc., Chicago, IL). Data were presented as the mean \pm standard deviation (SD). A One-Way analysis of variance (ANOVA) was used to analyze the difference between groups, while the least significant difference (LSD) test was used for pairwise comparison.

3. Results

3.1. Clinicopathological characteristics

As shown in Table 1, no difference was observed in gender between the 2 groups ($P > .05$). The average age of the surgical

group was younger than that of the control group (0.00). Emorrhage position was varied in the control and surgical group, showing significant differences ($P = .04$). Hematoma volume in the surgical group was more than that in the control group ($P = .01$). The values of GCS and muscle strength in the surgical group before operation were both lower than those in the control group ($P = .00$).

3.2. Hematoma evacuation

In all the 69 patients, the hematoma sites were accurately reached under the guidance of the body surface projection. The operation time of neuroendoscopic hematoma evacuation was 35 to 55 minutes. All the cases underwent CT scan reexamination 24 hours after the surgery. Postoperative rebleeding occurred in no patients. The hematoma clearance rate is 90.5% in average (Fig. 2). As shown in Table 2, the mean change in GCS score was +4.03 in post-operation as compared to pre-operation ($P = .00$).

3.3. Postoperative outcome

As shown in Table 3, 4 postoperative deaths occurred in the surgical group due to postoperative complication and rebleeding in non-operation area while 3 patients were discharged and were lost to follow-up. Three unexplained deaths occurred in the control group. Moreover, the post-operative GCS ($P = .00$) and muscle strength ($P = .01$) were significantly decreased in surgical group as compared to the control group. Besides, there

Table 1
Comparison of clinicopathological data.

Variables	Control group	Surgical group	t	P value
Sex (female/male)	25/44	26/43	0.03	.86
Age (yr)	63.01 \pm 12.8	53.84 \pm 11.52	-4.42	.00
emorrhage position (sheath nuclear/thalamus/ventricle)	48/13/8	36/26/7	6.11	.04
Hematoma volume (mL)	28.29 \pm 8.90	32.65 \pm 10.11	2.68	.01
GCS	10.62 \pm 3.05	6.00 \pm 1.98	-10.59	.000
Muscle strength	2.32 \pm 1.41	0.72 \pm 0.94	-7.825	.00

GCS = Glasgow coma scale.

Table 2
Comparison of preoperative and postoperative GCS in the surgical group.

Preoperative GCS	Postoperative GCS	t	P value
6.00 ± 1.98	10.03 ± 3.25	11.58	.00

GCS = Glasgow coma scale.

Table 3
Comparison of postoperative outcome.

Variables	Control group	Surgical group	t	P value
Death/survival	3/66	7/62	0.97	.33
Postoperative GCS	11.99 ± 3.74	10.03 ± 3.25	-3.21	.00
Postoperative muscle strength	2.57 ± 1.71	1.96 ± 1.13	-2.46	.01
Muscle strength improvement	0.25 ± 0.96	1.23 ± 1.20	5.31	.00
MRS (0/1/2/3/4/5)	0/0/4/14/14/18	0/0/3/14/37/8	13.56	.00

GCS = Glasgow coma scale, MRS = modulate RANK score.

Table 4
Pyramidal tract typing and prognosis of muscle strength.

DTI types	n	muscle strength	F-value	P value
compressive	9	1.78 ± 1.09	12.825	.000
infiltrate	42	1.76 ± 1.06		
destructive	11	-0.09 ± 0.54		

DTI = diffusion tensor imaging.

were significant differences in the modulate RANK score (MRS) between the 2 groups ($P = .00$).

3.4. DTI and muscle strength

Cone beam DTI imaging was performed in 62 patients. Magnetic resonance (MR) was carried out 3 weeks after surgery. Classification statistics were conducted according to the situation of pyramidal tracts damage (Fig. 3). The relationship between pyramidal tract typing and limb muscle strength was shown in Table 4. These patients with simple disruptive pyramidal tract

injury had a relatively poor prognosis. There was no difference in prognosis between simple displacement and displacement with disruption types.

4. Discussion

The diagnosis of cerebral hemorrhage is not difficult, the head CT scan can quickly determine the bleeding site and hematoma volume. Currently, there are no uniform opinions on conservative treatment or surgical treatment. In fact, it largely depends on patients' cognition of the prognosis. The data in this study showed that the patients selected for surgical treatment were younger, with an average age of 53.84 years. Surgical treatment could not reduce the mortality of cerebral hemorrhage. Improving the quality of life of patients with cerebral hemorrhage through minimally invasive surgery is the focus of current research. The results showed that mRS and muscle strength in the surgical group were better than those in the conservative group. The key of the surgery is to avoid secondary injury, especially to protect the nerve conduction tract.

To the best of our knowledge, endoscope-assisted evacuation has an advantage over conventional craniotomy in that it can be performed through a smaller sheath, and can use the same suction or combination tools used during other neurosurgery procedures.^[16] In this study, we used a tissue expander with 1.6 cm internal diameter. Another advantage is that endoscopic surgery spends shorter surgical time, which in turn reduce the damage caused by prolonged anesthesia. For example, Xu et al retrospectively compared outcomes of patients who underwent endoscope-assisted evacuation and craniotomy, and showed that the mean operative time was 1.6 hours in the endoscopy group and 5.2 hours in the craniotomy group.^[17] Additionally, the neuroendoscope, with its higher magnification, and additional illumination, can help us precisely distinguish the hematoma boundary during operation and can be convenient for intraoperative hemostasis.^[18,19] Ye et al demonstrated that ICH patients who underwent neuroendoscopy had a higher evacuation rate, lower risk of complications, and shorter operation time compared with those that underwent a craniotomy.^[20]

Neuroendoscopic surgery for ICH especially through supra-frontal approach which is parallel to the pyramidal tract minimizes surgical injury. Endoscope could remove hematoma

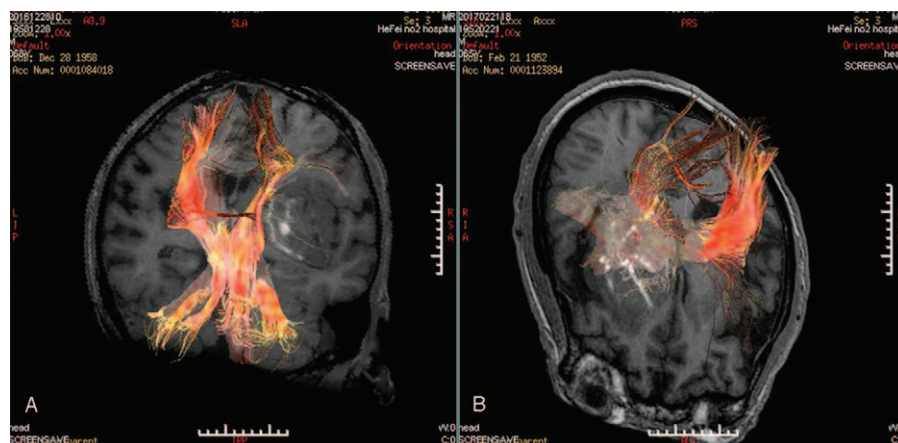


Figure 3. MR-DTI images showing pressurized (A) and disruptive (B) changes of pyramidal tracts.

under direct vision, avoid puncture track damage and the damage to the surrounding brain tissues and blood vessels caused by excessive suction, and reduce the risk of re-bleeding. Meanwhile, the bleeding points can be found in time during the operation to stop bleeding. Di Somma A et al^[21] indicated that neuroendoscopic intraoperative ultrasound-guided technique could reveal in a real-time fashion intracranial hemorrhages that may occur after tissue biopsy, therefore providing a useful tool to achieve valid and directed hemostasis when needed. On the other hand, the hematoma clearance rate under neuroendoscope for the first time is relatively high.^[19,22] In the present study, the hematoma evacuation rate was 90.75% overall. No patients had rebleeding events in the surgical group. In the surgical group, there was 1 case of postoperative re-bleeding in non-operative site, which was unrelated to the operation, and the rate of intraoperative re-bleeding was 0%, reflecting the advantages of neuroendoscope. The other 3 cases died of postoperative complications.

Neuroendoscope-assisted evacuation is performed using a tissue expander in a narrow surgical field, thus hematoma localization is very important. Stereotactic and neuronavigation procedures are not suitable for the clinical needs of acute cerebral hemorrhage surgery. In this study, the 3D software converted the 2-dimensional CT image into the 3-dimensional the body surface projection, to make the surgeons obtain direct information of hematoma location. Accurate hematoma localization was obtained in all 69 cases.

The integrity of pyramidal tract is the anatomical basis for maintaining limb function. The destruction of adjacent pyramidal tract by hematoma in basal ganglia is the cause of hemiplegia. DTI is a MR imaging technique that allows for the non-invasive in vivo assessment and microstructural changes of white matter tracts.^[23,24] This technology, together with fiber tracking (FT) technology can be used to display the main white matter fiber tracts in the brain, which is the only imaging method that can present the main white matter fiber tracts in the brain in living bodies. By visualizing the pyramidal tract with DTI technology, the invasion of the pyramidal tract can be observed intuitively.

Our data demonstrated that Basal ganglia hemorrhage was mainly invasive in the pyramidal tract (42/62, 72%), and different types of pyramidal tract damage were closely related to the prognosis of muscle strength ($P < .05$). Patients with simple disruption type had the worst muscle strength recovery. There was no significant difference in the prognosis of muscle strength between simple displacement and displacement with disruption types. These findings suggested that DTI can predict the prognosis of muscle strength.

Author contributions

Conceptualization: Shengli Qiu.

Data curation: Guanghui Cao.

Formal analysis: Guanghui Cao.

Investigation: Shengli Qiu, Tao Liu, Guanghui Cao.

Methodology: Shengli Qiu, Tao Liu.

Software: Kun Wu.

Supervision: Kun Wu.

Validation: Tingsheng Zhao.

Visualization: Tingsheng Zhao.

Writing – original draft: Shengli Qiu.

Writing – review & editing: Shengli Qiu.

References

- [1] Go AS, Mozaffarian D, Roger VL, et al. Executive summary: heart disease and stroke statistics—2013 update a report from the American Heart Association. *Circulation* 2013;127:143–52.
- [2] Shivane A, Chakrabarty A. Pathology of intracerebral haemorrhage. *Adv Clin Neurosci Rehabil* 2008;8:20.
- [3] Poon MT, Fonville AF, Al-Shahi SR. Long-term prognosis after intracerebral haemorrhage: systematic review and meta-analysis. *J Neurol Neurosurg Psychiatry* 2014;85:660–7.
- [4] Provencio JJ, Da SI, Manno EM. Intracerebral hemorrhage: new challenges and steps forward. *Neurosurg Clin N Am* 2013;24:349–59.
- [5] Broderick J, Brott T, Duldner J, et al. Volume of intracerebral hemorrhage. A powerful and easy-to-use predictor of 30-day mortality. *Stroke* 1993;24:987–93.
- [6] Daverat P, Castel JP, Dartigues JF, et al. Death and functional outcome after spontaneous intracerebral hemorrhage. A prospective study of 166 cases using multivariate analysis. *Stroke* 1991;22:1–6.
- [7] Mayer SA, Sacco RL, Shi T, et al. Neurologic deterioration in noncomatose patients with supratentorial intracerebral hemorrhage. *Neurology* 1994;44:1379–84.
- [8] Vespa PM, Martin N, Zuccarello M, et al. Surgical trials in intracerebral hemorrhage. *Stroke* 2013;44:79–82.
- [9] Wang WH, Hu LS, Lin H, et al. Risk factors for post-traumatic massive cerebral infarction secondary to space-occupying epidural hematoma. *J Neurotrauma* 2014;31:1444.
- [10] Tsuzuki N, Toyooka T, Kageyama H. Managing subdural hematomas associated with intracranial hypotension with intra-subdural hematoma cavity pressure monitoring: a case report. *Japanese J Neurosurg* 2016;25:765–71.
- [11] Li Y, Wang J, Li Z, et al. Computed tomography angiography spot sign as an indicator for ultra-early stereotactic aspiration of intracerebral hemorrhage. *World Neurosurg* 2018;109:e136–43.
- [12] Auer LM, Deinsberger W, Niederkorn K, et al. Endoscopic surgery versus medical treatment for spontaneous intracerebral hematoma: a randomized study. *J Neurosurg* 1989;70:530.
- [13] Nagasaka T, Tsugeno M, Ikeda H, et al. Early recovery and better evacuation rate in neuroendoscopic surgery for spontaneous intracerebral hemorrhage using a multifunctional cannula: preliminary study in comparison with craniotomy. *J Stroke Cerebrovasc Dis* 2011;20:208.
- [14] Ma L, Hou Y, Zhu R, et al. Endoscopic evacuation of basal ganglia hematoma: surgical technique, outcome, and learning curve. *World Neurosurg* 2017;101:57–68.
- [15] Yu CS, Li KC, Yun X, et al. Diffusion tensor tractography in patients with cerebral tumors: a helpful technique for neurosurgical planning and postoperative assessment. *Eur J Radiol* 2005;56:197.
- [16] Hersh EH, Gologorsky Y, Chartrain AG, et al. Minimally invasive surgery for intracerebral hemorrhage. *Curr Neurol Neurosci Rep* 2018;18:34.
- [17] Xu X, Chen X, Li F, et al. Effectiveness of endoscopic surgery for supratentorial hypertensive intracerebral hemorrhage: a comparison with craniotomy. *J Neurosurg* 2018;128:553–9.
- [18] Wang GQ, Li SQ, Huang YH, et al. Can minimally invasive puncture and drainage for hypertensive spontaneous Basal Ganglia intracerebral hemorrhage improve patient outcome: a prospective non-randomized comparative study. *Mil Med Res* 2014;1:1–2.
- [19] Ochalski P, Chivukula S, Shin S, et al. Outcomes after endoscopic port surgery for spontaneous intracerebral hematomas. *J Neurol Surg A Cent Eur Neurosurg* 2014;75:195–205. discussion 206.
- [20] Ye Z, Ai X, Hu X, et al. Comparison of neuroendoscopic surgery and craniotomy for supratentorial hypertensive intracerebral hemorrhage: a meta-analysis. *Medicine (Baltimore)* 2017;96:e7876.
- [21] Di Somma A, Narros Gimenez JL, Almarca Bethencourt JM, et al. Neuroendoscopic intraoperative ultrasound-guided technique for biopsy of paraventricular tumors. *World Neurosurg* 2019;122:441–50.
- [22] Kuo LT, Chen CM, Li CH, et al. Early endoscope-assisted hematoma evacuation in patients with supratentorial intracerebral hemorrhage: case selection, surgical technique, and long-term results. *Neurosurg Focus* 2011;30:E9.
- [23] Chen HJ, Gao YQ, Che CH, et al. Diffusion tensor imaging with tract-based spatial statistics reveals white matter abnormalities in patients with vascular cognitive impairment. *Front Neuroanat* 2018;12:53.
- [24] Benson RR, Gattu R, Cacace AT. Left hemisphere fractional anisotropy increase in noise-induced tinnitus: a diffusion tensor imaging (DTI) study of white matter tracts in the brain. *Hear Res* 2014;309:8–16.