

# Osseous Tissue Engineering in the Management of Mandibular Osteoradionecrosis – An Evaluative Study

Manimaran Kanakaraj, Marudhamani Chinnannan, Anbu Elangovan Nagarathinam<sup>1</sup>, Ravi Velamor Rangarajan<sup>2</sup>, Avinash Gandhi Devadas<sup>2</sup>, Madhan Jeyaraman<sup>3,4</sup>

Department of Oral and Maxillofacial Surgery, KSR Institute of Dental Sciences and Research, Tiruchengode, <sup>1</sup>Department of Oral Pathology, SRM Dental College, Chennai, <sup>2</sup>Department of Regenerative Medicine, Mother Cell Regenerative Center, Trichy, <sup>3</sup>Department of Orthopaedics, ACS Medical College and Hospital, Dr. MGR Educational and Research Institute, Chennai, Tamil Nadu, <sup>4</sup>Department of Biotechnology, School of Engineering and Technology, Sharda University, Greater Noida, Uttar Pradesh, India

## Abstract

**Introduction:** Osteoradionecrosis (ORN), a non-infectious, necrotic condition of the bone, occurs as a major complication of radiotherapy to the irradiated site. Simple irrigation of the involved bone to partial or complete resection of the involved bones is being employed in its conventional management. Osseous tissue engineering (OTE) provides a new strategy by regenerating bone cells along with biocompatible scaffolds and micromolecules to produce an engineered osseous tissue. **Materials and Methods:** In this study, mandibular ORN following radiation secondary to oropharyngeal squamous cell carcinoma was included. OTE with composite engineered tissue containing a mixture of autologous culture expanded dental pulp stem cells (DPSCs), autologous uncultured bone marrow aspiration concentrate (BMAC) and autologous platelet-rich plasma (PRP) loaded in  $\beta$ -tricalcium phosphate ( $\beta$ -TCP) or hydroxyapatite (HA) sponge scaffold was used in the mandibular defect and the surrounding tissues. An assessment of clinical, radiological and functional attributes was done. **Results:** A total of six cases with a mean age of 58.6 years were included in the study. We noted significant improvement in the mean post-operative score for pain and mouth opening; functional improvement in eating solid/liquid food, tongue movement, speech and deglutition were observed. The aesthetics was measured with Vancouver score and revealed a significance at  $P < 0.05$ ; also lip competency and occlusion were noted in all the patients. No major complications were noticed until a mean follow-up of 28 months. **Discussion:** Tissue engineering with a regenerative cocktail of autologous culture expanded DPSCs, autologous uncultured BMAC and autologous PRP loaded in HA or  $\beta$ -TCP utilised in the surgical reconstruction of the mandible is an effective treatment modality in the management of mandibular ORN following irradiation.

**Keywords:** Bone marrow aspirate concentrate, dental pulp stem cells, hydroxyapatite, osteoradionecrosis, platelet-rich plasma

## INTRODUCTION

In 1922, Regaud published the first report on osteoradionecrosis (ORN) of the jaw after radiotherapy (RT).<sup>[1]</sup> Despite varied postulates that have been hypothesised for its causation, the triad of hypoxia, hypovascularity and hypocellularity proposed by Marx has been widely accepted for the development of ORN.<sup>[2]</sup> ORN of the jaw is defined as a persistent non-healing ulcer for at least three months with bony exposure and aseptic necrosis due to the breach in the oral mucosa that has undergone prior radiation therapy.<sup>[3]</sup> Radiation-induced osteonecrosis occurs when radiation doses are  $>70$  Gy.<sup>[4]</sup> Loss of the mucosal aspect of the bone following RT, the necrotic portion of the bone becomes exposed to the intraoral environment. Hence, the necrotic bone becomes more susceptible to producing pathological fractures.<sup>[5]</sup>

ORN of the jaw is a dire complication of radiation therapy for head-and-neck cancer.<sup>[6]</sup> ORN of jaws leads to significant loss of bone, surrounding soft tissue, tooth and significant facial disfigurement.<sup>[7]</sup> Such an unfortunate outcome results in the diminished quality of life. Pathologically, ORN is characterised

**Address for correspondence:** Dr. Madhan Jeyaraman, Department of Orthopaedics, ACS Medical College and Hospital, Dr. MGR Educational and Research Institute, Chennai, Tamil Nadu, India. E-mail: madhanjeyaraman@gmail.com

Received: 28-08-2022

Last Revised: 02-02-2023

Accepted: 07-02-2023

Published: 27-03-2023

This is an open access journal, and articles are distributed under the terms of the Creative Commons Attribution-NonCommercial-ShareAlike 4.0 License, which allows others to remix, tweak, and build upon the work non-commercially, as long as appropriate credit is given and the new creations are licensed under the identical terms.

For reprints contact: WKHLRPMedknow\_reprints@wolterskluwer.com

**How to cite this article:** Kanakaraj M, Chinnannan M, Nagarathinam AE, Rangarajan RV, Devadas AG, Jeyaraman M. Osseous tissue engineering in the management of mandibular osteoradionecrosis – An evaluative study. *Ann Maxillofac Surg* 2023;13:19-25.

### Access this article online

#### Quick Response Code:



Website:  
<https://journals.lww.com/aoms>

DOI:  
10.4103/ams.ams\_164\_22

by osseous dehiscence, osseous devitalisation, diminished cellularity and profound osteitis and osteolysis.<sup>[8]</sup> Once ORN is recognised, it is irreversible and extremely difficult to treat.

Orthobiologics provides the administration of osteoinductive and osteoconductive micromolecules to enhance the regeneration of degenerated tissues, tendons, bones and cartilage. With the technological advances in the field of regenerative and translational medicine, the usage of mesenchymal stem cells (MSCs) to treat diseases has been of prime importance. Cytotherapy offers the transplantation of either autologous or allogenic cells or modified cells to replace and regenerate the damaged tissues in a given area of interest. Tissue engineering restores tissue function and maintains tissue homeostasis and improves the biomechanical strength of the tissues. Osseous tissue engineering (OTE) provides a new strategy by regenerating bone cells along with biocompatible scaffolds and micromolecules to produce an engineered osseous tissue.<sup>[9]</sup> We aim to analyse the effectiveness of OTE in the management of mandibular ORN following irradiation for squamous cell carcinoma after the failure of conventional treatment methods.

## MATERIALS AND METHODS

We performed this study after obtaining institutional ethical committee approval dated January 30, 2013 (046/KSRIDSR/EC/2013) and April 25, 2016 (127/KSRIDSR/EC/2016). In KSR Dental College and Mother Cell Regenerative Centre, from 2016 to 2019, a total of six cases of mandibular ORN following radiation secondary to oropharyngeal squamous cell carcinoma were included. Following thorough debridement of the lesion with sequestrectomy, alveolectomy and curettage of the necrotic bone tissue, a composite OTE substrate containing a mixture of autologous culture expanded dental pulp stem cells (DPSCs), autologous uncultured bone marrow aspiration concentrate (BMAC) and autologous platelet-rich plasma (PRP) loaded in  $\beta$ -tricalcium phosphate ( $\beta$ -TCP) or hydroxyapatite (HA) sponge scaffold was used in the mandibular defect and the surrounding tissues. Following the sequestrectomy of the necrotic tissue, if the defect of the mandible was unstable, a mandibular reconstruction plate was used to stabilise the ends of the mandible.

The products of cellular therapy have been prepared in a good manufacturing practice certified laboratory. Autologous culture-expanded DPSCs were harvested from extracted teeth and culture-expanded cells were obtained. Passage 5 DPSC cells were used for all the cases in this study which were characterised by CD-34 and-90 IHC markers. Autologous uncultured BMAC was obtained from differential centrifugation of bone marrow obtained from the bilateral iliac crest. Autologous PRP was prepared from differential centrifugation of peripheral venous blood. OTE product had a mixture of 1.5 million autologous culture expanded DPSCs per kg body weight, 3–4 ml of autologous uncultured

BMAC and 4–6 ml of autologous PRP loaded in  $\beta$ -TCP or HA sponge scaffold in the defect region of the mandible and the surrounding tissues. The amount of the individual components of the OTE mixture was decided based on the final defect after surgical debridement of the necrotic region.

Clinical attributes such as pain, mouth opening, lip competency and occlusion were assessed;<sup>[10,11]</sup> radiographic assessment with orthopantomogram was done to assess the improvement in defect size. All the patients were followed up with the serial orthopantomogram at regular intervals of 1, 2, 6, 12 and 24 months post-procedure to assess the union of the bony defect in the mandible. Functional attributes such as eating solid/liquid food, tongue movement, speech and deglutition were also observed.<sup>[11]</sup> Aesthetic outcome was based on the Vancouver assessment scale and clinical and radiological assessment.<sup>[12]</sup>

The outcome parameters were recorded in a pilot-tested pro forma made for the study. Statistical analysis was performed with SPSS software version 25 (IBM, Chicago, Illinois, USA). Student's *t*-test was done to compare the improvement in the pain pre- and post-intervention at serial intervals; mouth opening was assessed using Paired sample *t*-test, and Fisher's exact analysis was done for scar assessment. We assigned a significance level with a  $P < 0.05$ .

## RESULTS

A total of six cases with a mean age of 58.6 years were included in the study. The included patient population had an M: F ratio of 2:1. The characteristics of the patients included in the study are given in Table 1a and b. Only two cases required mandibular stabilisation with reconstruction plating.

Clinical, radiological, functional and aesthetic assessments were performed to measure the immediate and long-term outcomes. Comparative analysis of pre-operative pain (mean  $\pm$  standard deviation [SD]  $-6.17 \pm 0.75$ ) and pain on day 1, day 7 and day 14 revealed significant improvement in post-operative pain score at day 14 (mean  $\pm$  SD  $-0.67 \pm 0.52$ ) and showed a statistical significance at  $P < 0.001$  [Tables 2 and 3]. Patients did not report any significant increase in pain at the end of one year and the final follow-up. Pre-operative and post-operative (Day 14) analysis of mouth opening revealed a statistical significance at  $P < 0.001$  [Tables 2 and 4]. During this period, other clinical attributes such as lip competency, occlusion and tongue movement were found to be normal and the intra-oral healing was found to be uneventful and satisfactory. Extraorally, aesthetic outcomes of scar measured using the Vancouver scale revealed a statistical significance at  $P < 0.05$  at the end of week 24 [Tables 2 and 5].

Figures 1 and 2 illustrate the clinical and radiological improvements in the included cases with the OTE regimen. Radiographic observation showed a consistent decrease in the defect size at regular intervals and at the end of 24 months. No major complications were noticed until a mean follow-up of

**Table 1a: Carcinoma, staging and radiotherapy details of study participants**

Age and sex	Primary lesion	Type of cancer	Staging of cancer	Type of radiotherapy	Total radiation dose (Gy)*	Duration and dosage**
77/male	Carcinoma right tonsil	Poorly differentiated carcinoma	T2N1M0	EBRT	70	30 divided doses over 7 weeks
46/female	Carcinoma left cheek	Poorly differentiated squamous cell carcinoma	T2N1M0	EBRT	70	10 divided doses over 5 weeks
52/female	Carcinoma pharynx	Poorly differentiated carcinoma	T3N1M0	EBRT	80	20 divided doses over 7 weeks
59/male	Carcinoma larynx	Poorly differentiated squamous cell carcinoma	T2N1M0	EBRT	60	25 divided doses over 7 weeks
63/male	Carcinoma larynx	Moderately differentiated squamous cell carcinoma	T3N1M0	EBRT	80	20 divided doses over 7 weeks
55/male	Carcinoma right tonsil	Basaloid squamous cell carcinoma	T2N1M0	EBRT	60	30 divided doses over 6 weeks

\*Radiation dosage was determined based on the TNM staging of the tumour - Site, size and extent of the tumor, \*\*Duration and the interval was a standard of 5-7 weeks in divided dosage based on TNM staging. Hyperfractional dosages were personalized for each patient to be given over period of maximum 7 weeks and was decided done based on tumour size, nodal involvement, disease control probability, foreseen functional and esthetic outcome, tumour resectability, patient general condition and compliance. EBRT: External beam radiation therapy, TNM: Tumor node metastasis

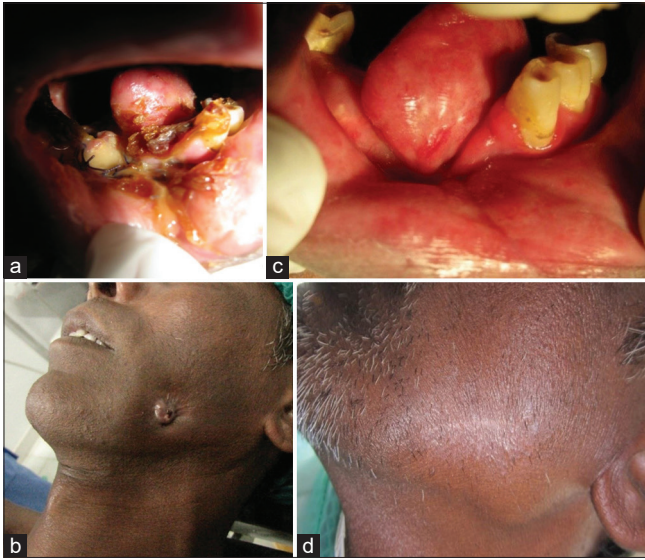**Table 1b: Characteristics of the individual cases included in the study**

Age	Sex	Primary lesion	Radiation dose (Gy)	Site and size of mandibular ORN	Surgical procedure	OTE regimen	Successful functional outcome at the end of 2 years follow up	Results
77	Male	Carcinoma right tonsil	70 Gy in 30 divided doses	Ramus of the right mandible; 3 cm × 2 cm approximately	Surgical removal of the necrotic region along with alveolectomy + sequestrectomy + curettage and mandibular reconstruction with recon plating	1.5 million DPSC per kg body weight + 2 ml BMAC + 4 ml of PRP loaded with β-TCP	Lip competency Malocclusion Speech Deglutition Tongue movement	Sinus tract revitalized with adequate closure obtained by the end of 3 months Osseous regeneration was observed at the end of 12 months
46	Female	Carcinoma left cheek	70 Gy in 10 divided doses	Ramus of the left mandible; 3 cm × 3 cm approximately	Surgical removal of the necrotic region along with alveolectomy + sequestrectomy	1.5 million DPSC per kg body weight + 2.5 ml BMAC + 5 ml of PRP loaded with β-TCP	Lip competency Malocclusion Speech Deglutition Tongue	Complete resolution of symptoms along with the complete union of the mandibular defect by 6 months
52	Female	Carcinoma pharynx	80 Gy in 20 divided doses	Ramus of the right mandible; 2 cm × 1 cm approximately	Sequestrectomy + curettage and mandibular reconstruction with recon plating	1.5 million DPSC per kg body weight + 5 ml of PRP loaded with HA	Lip competency Malocclusion Speech Deglutition Tongue	Complete mandibular union observed by the end of 4 months
59	Male	Carcinoma larynx	60 Gy in 25 divided doses	Ramus of the right mandible; 2 cm × 2 cm approximately	Surgical removal of the necrotic region along with sequestrectomy and curettage	1.5 million DPSC per kg body weight + 6 ml of PRP loaded with HA	Lip competency Malocclusion Speech Deglutition Tongue	Union of the mandibular defect by the end of 5 months along with the regeneration of surrounding soft tissues
63	Male	Carcinoma larynx	80 Gy in 20 divided doses	Ramus and body of the left mandible; 4 cm × 2 cm approximately	Alveolectomy + sequestrectomy and curettage	6 ml BMAC + 5 ml of PRP loaded with HA and β-TCP	Lip competency Malocclusion Speech Deglutition Tongue	Complete osseous healing and return of normal function of TM joint within 6 months follow-up
55	Male	Carcinoma right tonsil	60 Gy in 30 divided doses	Ramus and body of the right mandible; 2 cm × 2 cm approximately	Sequestrectomy and curettage	1.5 million DPSC per kg body weight + 4 ml BMAC + 4 ml of PRP loaded with HA and β-TCP	Lip competency Malocclusion Speech Deglutition Tongue	Mandibular regeneration was observed at the end of 3 <sup>rd</sup> month after which the patient lost our follow-up

OTE: Osseous tissue engineering, DPSCs: Dental pulp stem cells, BMAC: Bone marrow aspirate concentrate, PRP: Platelet-rich plasma, β-TCP: β-Tricalcium phosphate, HA: Hydroxyapatite, ORN: Osteoradionecrosis

**Table 2: Pre- and post-operative assessment attributes - pain score, mouth opening, and scar score**

Patient S.No	Pain score				Mouth opening (mm)				Scar score		
	Preoperative	Day 1	Day 7	Day 14	Preoperative	Day 1	Day 7	Day 14	Day 1	Week 4	Week 24
Patient 1	7	5	3	1	24.00	24.00	30.00	34.00	2	1	0
Patient 2	6	4	3	1	27.00	28.00	33.00	37.00	2	1	0
Patient 3	5	3	3	0	24.00	26.00	30.00	33.00	2	1	0
Patient 4	6	5	5	1	27.00	27.00	30.00	35.00	2	1	0
Patient 5	7	4	4	0	30.00	31.00	36.00	40.00	2	1	0
Patient 6	6	5	3	1	28.00	28.00	30.00	35.00	2	1	0

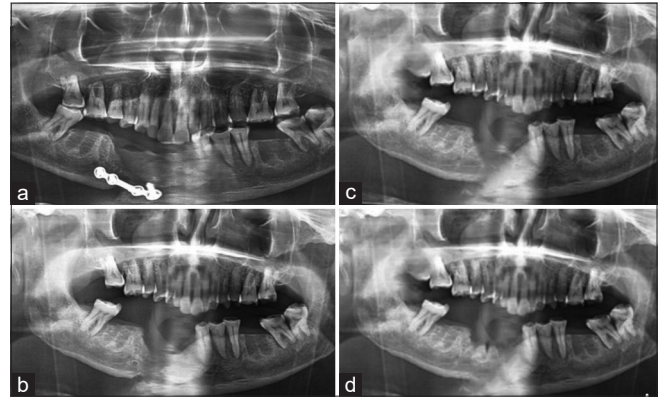


**Figure 1:** Illustrative clinical outcome of one of the included cases. (a) Pre-operative clinical image of necrosis of the mandible post-irradiation, (b) Pre-operative presence of extraoral sinus tract, (c) Post-operative outcome at 6 months of OTE regimen; and, (d) Post-operative healed extraoral sinus tract by 6 months

24 months. All the cases reported an enhanced epithelisation of intra- and extra-oral lesions following radiation. Out of six cases, four cases were treated with DPSCs + BMAC + PRP with  $\beta$ -TCP and two cases were treated with DPSCs + BMAC + PRP with HA and we found no statistical difference in both the cocktail used for the management of ORN. The details of carcinoma and dose of radiation given for each case are depicted in Table 1a. The final clinical outcome observed at the end of long-term follow-up is described in Table 1b.

## DISCUSSION

ORN, called radiation osteitis, radio-osteonecrosis, radiation osteomyelitis, radio-osteomyelitis, and post-RT osteonecrosis, is a dreadful complication of high-dose RT for head and neck cancers.<sup>[7]</sup> ORN occurs in 5%–10% of head and neck cancer patients, who receive radiation of more than 70 Gy.<sup>[4]</sup> Recent guidelines defined ORN as the clinical entity, where the bone is exposed through underlying skin or mucosa without healing for three consecutive months in the absence of recurrent tumour, resulting in cellular and molecular death of the exposed bone.



**Figure 2:** Illustrative radiological outcome of one of the included case (a) No secondary complications were observed radiographically postoperatively at the end of 3 months with evidence of bone formation in the site; (b and c) Evidence of bony reunion, progressive bone formation and remodelling was evident at the end of 6 months and 12 months follow-up periods; (d) Postoperatively, 2-year period showed well-defined bone remodelling in the lower anterior surgical region when compared to 6 months and 12 months follow-up

The such necrotic bone is most prone to pathological fracture.<sup>[5]</sup> Mandible (2%–22%) is the most common bone prone for ORN followed by the maxilla.<sup>[2]</sup>

Various researchers postulated the possible mechanisms for the development of ORN followed by RT. The triad of ORN constitutes hypoxia, hypocellularity and hypovascularity, as proposed by Marx in 1983.<sup>[2]</sup> The aetiopathogenesis of radiation-induced osseous injury is not fully understood. The interval between RT to the onset of ORN varies, but most often occurs between four months and two years.<sup>[2,13]</sup> ORN develops during the first year after RT; however, the risk remains for life although to a lesser degree. The risk factors involved in the development of ORN are site, size and shape of the tumour, cellular biology of the tumour, invasiveness, type, and dose of radiation therapy received and involvement of dental extraction.<sup>[3,14,15]</sup> Epidemiologically reported incidence of ORN followed by dental extraction is 0-7% approximately.<sup>[5,16]</sup> In the early stages, ORN remains asymptomatic but the exposed devitalised bone is visible through the ulcerated skin or mucosa. The patient presents with intractable pain, dysesthesia, halitosis, dysgeusia and food impaction.<sup>[17]</sup> In severe cases of ORN, the patients present with oral mucosal fistula, complete osseous devitalisation and pathological fractures of the underlying mandible.<sup>[17]</sup>

**Table 3: Assessment of pre- and post-operative pain by visual analog scale score (n=6)**

Variable	Mean±SD	95% CI	P	Significance
Preoperative	6.17±0.75	-	-	-
Day 1	4.33±0.82	0.537-3.130	0.01	Significant at P<0.05
Day 7	3.50±0.84	0.888-4.446	0.009	Significant at P<0.05
Day 14	0.67±0.52	4.059-6.941	<0.001	Significant at P<0.05

Inference: Assessment of mouth opening at preoperative versus postoperative day 7 and day 14 was found to be statistically significant at P<0.05.  
SD: Standard deviation, CI: Confidence interval

**Table 4: Assessment of pre- and post-operative mouth opening**

Mean	Paired differences		t	P	Significance
	Mean difference	SD			
Pre-operative versus post-operative day 1 26.66 27.33	-0.66667	0.81650	-2.000	0.102	Not significant at P<0.05
Pre-operative versus post-operative day 7 26.66 31.50	-4.83	1.83	-6.45	0.001	Significant at P<0.05
Pre-operative versus post-operative day 14 26.66 35.66	-9.00	1.26	-17.42	0.000	Significant at P<0.05

Inference: Assessment of mouth opening at pre-operative versus post-operative day 7 and day 14 was found to be statistically significant at P<0.05.  
SD: Standard deviation

**Table 5: Post-operative scar assessment**

Scar assessment	Scar	No scar	Fisher's exact test value (P)	Significance
Operative	6	0	0.0022	Significant at P<0.05
Post-operative (week 24)	0	6		

The Fisher's exact test statistic value is 0.0022. The result is significant at P<0.05

Once ORN is developed, it follows a vicious cycle in the form of aseptic osteonecrosis which further hampers the regenerative potential of the underlying bone and the surrounding soft tissues secondary to the radiation injury.<sup>[18]</sup> Jacobson *et al.* hypothesised that radiational damage to osteoclasts leads to diminished osteoclast-related bone turnover and causes aseptic bone necrosis.<sup>[19]</sup> Management of ORN depends on the stage of the disease and follows a personalised protocol. Mild cases of ORN can be managed conservatively with pentoxifylline,  $\alpha$ -tocopherol, bisphosphonates, maintenance of hygienic oral practices and avoidance of risk factors of ORN,<sup>[20]</sup> whereas moderate cases require the usage of hyperbaric oxygen (HBO) treatment.<sup>[21]</sup> Severe cases of ORN are managed by surgical resection, flap coverage, and reconstruction of the mandible by plating with or without HBO.<sup>[22]</sup> The successful management of ORN is difficult as they recur even after the treatment is completed.

The concept of "Tissue Engineering" plays a major role in regenerative and translational medicine. OTE is defined as the *in vitro* or *in vivo* regeneration of osseous tissues for repairing and replacing the diseased tissue or organ to enhance and

restore function and maintain homeostasis and improve the biomechanical strength of the tissues.<sup>[23]</sup> The combination of stem cells, growth factors and scaffolds forms an integral part of OTE.<sup>[24,25]</sup> Various pre-clinical and clinical reports in tissue engineering for the management of ORN are tabulated in Table 6.

Due to the paracrine effects of MSCs, the regenerative potential of the residual stem cells is potentiated which leads to the regeneration of tissues. Dental pulp-MSCs (DP-MSCs) possess a similar regenerative potential to BM-MSCs but DP-MSCs act as a non-invasive source for extraction of MSCs for therapeutic usage in various diseases.<sup>[26]</sup> Like BM-MSCs, upon the addition of appropriate growth factors, DP-MSCs differentiate into multilineages namely adipogenesis, chondrogenesis, osteogenesis, neurogenesis and dentinogenesis.<sup>[27,28]</sup> Transcription factors such as collagen 1, osteopontin, alkaline phosphatase (ALP), bone sialoprotein and osteocalcin induce MSC-driven osteogenesis.<sup>[29]</sup> At the molecular level, the upregulation of Bone Morphogenic Protein-2, ALP, Runt-related transcription factor 2 (Runx-2), Secreted Phosphoprotein 1 (Spp-1), Distal-Less Homeobox-5 (Dlx-5) induce MSC bound osteogenesis.<sup>[30]</sup> ALP and Runx-2 regulate osteoblastogenesis whereas Bglap and Spp-1 regulate the differentiation of osteoblasts.<sup>[31,32]</sup> Downregulation of Micro-RNA-31 (miR-31), miR-106a and miR-148a regulates MSC-bound osteogenesis.<sup>[33]</sup> Enhancement of angiogenesis, anti-apoptosis, antifibrosis and immunomodulation renders MSC the candidate of choice for the management of ORN.<sup>[34]</sup> With the robust release of growth factors, PRP stimulates the locally available stem cells and induces tissue regeneration. Evidence is available on the role of PRP in the union of fractures and osseous integration.

**Table 6: Preclinical and clinical evidence of usage of osseous tissue engineering regimen in osteoradionecrosis**

Author (year)	Study design	Participants	Method of ORN	OTE regimen	Results
<b>Preclinical evidence</b>					
Xu <i>et al.</i> (2012) <sup>[34]</sup>	Randomized controlled trial	7-8 months old inbred miniature pigs ( <i>n</i> =5)	Mandibular body irradiated with a single dose of 25 Gy to induce ORN	BM-MSCs along with HA/ $\beta$ -TCP (autograft)	Active bone tissue regeneration and revitalization are enhanced once BM-MSCs are administered with HA/TCP scaffolds by the end of 6 months
Jin <i>et al.</i> (2015) <sup>[35]</sup>	Controlled trial	7 weeks old male Sprague Dawley rats ( <i>n</i> =10)	Right mandibular body irradiated with a single dose of 30 Gy to induce ORN	Hydrogel loaded with cultured BM-MSCs from rat tibias and BMP-2 (allograft)	By end of 4 weeks after application, enhanced osseous healing in ORN observed when BM-MSCs are loaded along with hydrogel and BMP-2
Park <i>et al.</i> (2017) <sup>[36]</sup>	Controlled trial	Adult male Sprague - Dawley rats ( <i>n</i> =8)	Left mandibular body irradiated with a single dose of 20 Gy to induce ORN	T-MSCs obtained from the tonsillectomy specimen of a 5-year-old boy (xenograft)	Effective for bone regeneration in ORN after 8 weeks when T-MSCs are applied immediately after dentoalveolar surgery
Janus <i>et al.</i> (2017) <sup>[37]</sup>	Controlled trial	7 weeks old Athymic Nude rats ( <i>n</i> =5)	Left mandibular body irradiated with a single dose of 20 Gy to induce ORN	Human AD-MSCs with PRP and collagen (xenograft)	Preservation of radiological and histological bone tissue in ORN demonstrated by the end of 8 weeks when AD-MSCs are administered along with PRP and collagen scaffold
<b>Clinical evidence</b>					
Mendonca <i>et al.</i> (2010) <sup>[38]</sup>	Case report	63-year-old male	Carcinoma tonsil	BM-MSCs along with fibrin-rich and platelet-rich clots and $\beta$ -TCP + HA (autograft)	Osseous regeneration along with nerve recovery observed with the cocktail of BM-MSCs along with PRP and $\beta$ -TCP + HA by the end of 20 months
Manimaran <i>et al.</i> (2014) <sup>[39]</sup>	Case reports	48-year-old male	Carcinoma soft palate	BMAC (autograft)	Radiological osseous union was observed at the end of 12 months of follow-up. The patient remains disease-free
		47-year-old male	Carcinoma left tonsil	DPSCs with PRP + TCP (allograft)	Osseous regeneration was observed at the end of the 6-month follow-up

MSCs: Mesenchymal stem cells, AD-MSCs: Adipose tissue-derived MSCs, BM-MSCs: Bone marrow-derived MSCs, HA: Hydroxyapatite,  $\beta$ -TCP:  $\beta$ -Tricalcium phosphate, BMP: Bone morphogenetic protein, T-MSCs: Tonsil-derived MSCs, DPSCs: Dental pulp stem cells, BMAC: Bone marrow aspirate concentrate, DP-MSCs: Dental pulpal-MSCs. OTE: Osseous tissue engineering, ORN: Osteoradionecrosis, PRP: Platelet-rich plasma

Scaffolds act as a medium to cater to the stem cells, growth factors and biomolecules to integrate with the native tissue with equivalent biomechanical strength. These scaffolds augment osteogenesis and osseous regeneration through osteoinduction, osteoconduction and osteointegration.

Pre-clinical studies of ORN of mandible managed with MSCs (allograft/autograft/xenograft) along with PRP and scaffolds have demonstrated increased bone volume and bone mineral density-enhanced epithelisation and healing of soft tissues and soft tissue and osseous regeneration at the mandibular defect. However, these studies failed to quantitate the effect of MSCs in osseous regeneration.<sup>[34,35]</sup> Xu *et al.*, Park *et al.*, Janus *et al.* and Mendonca *et al.* demonstrated a profound increase in the density of neoangiogenesis following post-irradiation mandibular ORN.<sup>[34,36-38]</sup> Manimaran *et al.* used a combination of allogenic culture-expanded DPSCs and autologous uncultured BMAC along with PRP, HA and/or  $\beta$ -TCP to regenerate the mandibular defect in ORN cases.<sup>[39]</sup> A systematic review by Gundestrup *et al.* in 2020 reported that MSCs are a safe and promising agent for bone and soft tissue regeneration in mandibular ORN.<sup>[40]</sup> We noted successful regeneration of all the patients with utilisation of all the elements of regenerative modality in the OTE regimen followed. Further randomised controlled trials must be taken

up to prove the efficacy of MSCs in the management of the mandibular ORN.

The limitations of the study are small sample size, lack of histological testing after final follow-up, short follow-up time frame and lack of controls to validate the efficacy of the OTE regimen used in ORN of the mandible. Randomised controlled trials with longer follow-up periods are needed to validate the efficacy of the OTE regimen used in mandibular ORN.

## CONCLUSION

Tissue engineering with a regenerative cocktail of autologous culture expanded DPSCs, autologous uncultured BMAC and autologous PRP loaded in HA or  $\beta$ -TCP utilised in the surgical reconstruction of the mandible is an effective treatment modality in the management of mandibular ORN following irradiation. Regenerative treatment modality such as OTE significantly improves the quality of life of such patients postoperatively.

## Declaration of patient consent

The authors certify that they have obtained all appropriate patient consent forms. In the form, the patient(s) has/have given his/her/their consent for his/her/their images and other clinical information to be reported in the journal. The patients understand that their names and initials will not be published

and due efforts will be made to conceal their identity, but anonymity cannot be guaranteed.

### Financial support and sponsorship

Nil.

### Conflicts of interest

There are no conflicts of interest.

## REFERENCES

- Manzano BR, Santaella NG, Oliveira MA, Rubira CM, Santos PS. Retrospective study of osteoradionecrosis in the jaws of patients with head and neck cancer. *J Korean Assoc Oral Maxillofac Surg* 2019;45:21-8.
- Kumar S, Chandran C, Chacko R, Jesija JS, Paul A. Osteoradionecrosis of jaw: An institutional experience. *Contemp Clin Dent* 2018;9:242-8.
- Kubota H, Miyawaki D, Mukumoto N, Ishihara T, Matsumura M, Hasegawa T, *et al.* Risk factors for osteoradionecrosis of the jaw in patients with head and neck squamous cell carcinoma. *Radiat Oncol* 2021;16:1.
- Dhanda J, Pasquier D, Newman L, Shaw R. Current concepts in osteoradionecrosis after head and neck radiotherapy. *Clin Oncol (R Coll Radiol)* 2016;28:459-66.
- Chronopoulos A, Zarra T, Ehrenfeld M, Otto S. Osteoradionecrosis of the jaws: Definition, epidemiology, staging and clinical and radiological findings. A concise review. *Int Dent J* 2018;68:22-30.
- Singh A, Hury JM, Kronstadt KL, Yom SK, Randazzo JR, Estilo CL. Osteoradionecrosis of the jaw: A mini review. *Front Oral Health* 2022;3:980786.
- Mallya SM, Tetradis S. Imaging of radiation – And medication-related osteonecrosis. *Radiol Clin North Am* 2018;56:77-89.
- Frankart AJ, Frankart MJ, Cervenkova B, Tang AL, Krishnan DG, Takiar V. Osteoradionecrosis: Exposing the evidence not the bone. *Int J Radiat Oncol Biol Phys* 2021;109:1206-18.
- Wu V, Helder MN, Bravenboer N, Ten Bruggenkate CM, Jin J, Klein-Nulend J, *et al.* Bone tissue regeneration in the oral and maxillofacial region: A review on the application of stem cells and new strategies to improve vascularization. *Stem Cells Int* 2019;2019:e6279721.
- Naini FB. Lip seals. *Br Dent J* 2010;209:106.
- Nicoletti G, Soutar DS, Jackson MS, Wrench AA, Robertson G. Chewing and swallowing after surgical treatment for oral cancer: Functional evaluation in 196 selected cases. *Plast Reconstr Surg* 2004;114:329-38.
- Draaijers LJ, Tempelman FR, Botman YA, Tuinebreijer WE, Middelkoop E, Kreis RW, *et al.* The patient and observer scar assessment scale: A reliable and feasible tool for scar evaluation. *Plast Reconstr Surg* 2004;113:1960-5.
- Marx RE. Osteoradionecrosis: A new concept of its pathophysiology. *J Oral Maxillofac Surg* 1983;41:283-8.
- O'Dell K, Sinha U. Osteoradionecrosis. *Oral Maxillofac Surg Clin North Am* 2011;23:455-64.
- Rosenfeld E, Eid B, Masri D, Popovtzer A, Mizrahi A, Chaushu G. Is the risk to develop osteoradionecrosis of the jaws following IMRT for head and neck cancer related to co-factors? *Medicina (Kaunas)* 2021;57:468.
- Khoo SC, Nabil S, Fauzi AA, Yunus SS, Ngeow WC, Ramli R. Predictors of osteoradionecrosis following irradiated tooth extraction. *Radiat Oncol* 2021;16:130.
- Nadella KR, Kodali RM, Guttikonda LK, Jonnalagadda A. Osteoradionecrosis of the jaws: Clinico-therapeutic management: A literature review and update. *J Maxillofac Oral Surg* 2015;14:891-901.
- Rivero JA, Shamji O, Kolokythas A. Osteoradionecrosis: A review of pathophysiology, prevention and pharmacologic management using pentoxifylline,  $\alpha$ -tocopherol, and clodronate. *Oral Surg Oral Med Oral Pathol Oral Radiol* 2017;124:464-71.
- Jacobson AS, Buchbinder D, Hu K, Urken ML. Paradigm shifts in the management of osteoradionecrosis of the mandible. *Oral Oncol* 2010;46:795-801.
- Aggarwal K, Goutam M, Singh M, Kharat N, Singh V, Vyas S, *et al.* Prophylactic use of pentoxifylline and tocopherol in patients undergoing dental extractions following radiotherapy for head and neck cancer. *Niger J Surg* 2017;23:130-3.
- Sultan A, Hanna GJ, Margalit DN, Chau N, Goguen LA, Marty FM, *et al.* The use of hyperbaric oxygen for the prevention and management of osteoradionecrosis of the jaw: A Dana-Farber/Brigham and Women's Cancer Center multidisciplinary guideline. *Oncologist* 2017;22:343-50.
- Rommel N, Kesting MR, Rohleder NH, Wolff KD, Weitz J. Surgical management of severe osteoradionecrosis of the mandibular bone by using double free flap reconstruction. *J Craniomaxillofac Surg* 2018;46:148-54.
- Meng Bao CL, Y.L. E, S.K. M, Liu Y, Choolani M, K.Y. J. Advances in Bone Tissue Engineering. *Regenerative Medicine and Tissue Engineering*. 2013. Available from: <http://dx.doi.org/10.5772/55916>.
- Perez JR, Kouroupis D, Li DJ, Best TM, Kaplan L, Correa D. Tissue engineering and cell-based therapies for fractures and bone defects. *Front Bioeng Biotechnol* 2018;6:105.
- Ghassemi T, Shahroodi A, Ebrahimzadeh MH, Mousavian A, Movaffagh J, Moradi A. Current concepts in scaffolding for bone tissue engineering. *Arch Bone Jt Surg* 2018;6:90-9.
- Gl SP, Ramalingam S, Udhayakumar Y. Human dental pulp stem cells and its applications in regenerative medicine – A literature review. *J Glob Oral Health* 2019;2:59-67.
- Mortada I, Mortada R. Dental pulp stem cells and osteogenesis: An update. *Cytotechnology* 2018;70:1479-86.
- Yasui T, Mabuchi Y, Morikawa S, Onizawa K, Akazawa C, Nakagawa T, *et al.* Isolation of dental pulp stem cells with high osteogenic potential. *Inflamm Regen* 2017;37:8.
- Fakhry M, Hamade E, Badran B, Buchet R, Magne D. Molecular mechanisms of mesenchymal stem cell differentiation towards osteoblasts. *World J Stem Cells* 2013;5:136-48.
- Huang W, Yang S, Shao J, Li YP. Signaling and transcriptional regulation in osteoblast commitment and differentiation. *Front Biosci* 2007;12:3068-92.
- Komori T. Regulation of bone development and extracellular matrix protein genes by RUNX2. *Cell Tissue Res* 2010;339:189-95.
- Kaur G, Valarmathi MT, Potts JD, Jabbari E, Sabo-Attwood T, Wang Q. Regulation of osteogenic differentiation of rat bone marrow stromal cells on 2D nanorod substrates. *Biomaterials* 2010;31:1732-41.
- Manochantr S, Marupanthorn K, Tantrawatpan C, Kheolamai P, Tantikanlayaporn D, Sanguanjit P. The effects of BMP-2, miR-31, miR-106a, and miR-148a on osteogenic differentiation of MSCs derived from amnion in comparison with MSCs derived from the bone marrow. *Stem Cells Int* 2017;2017:7257628.
- Xu J, Zheng Z, Fang D, *et al.* Mesenchymal Stromal Cell-Based Treatment of Jaw Osteoradionecrosis in Swine. *Cell Transplant*. 2012; 21:1679-86.
- Jin IG, Kim JH, Wu H-G, Kim SK, Park Y, Hwang SJ. Effect of bone marrow-derived stem cells and bone morphogenetic protein-2 on treatment of osteoradionecrosis in a rat model. *Journal of Cranio-Maxillofacial Surgery* 2015;43:1478-86.
- Park HS, Lee J, Kim J-W, *et al.* Preventive effects of tonsil-derived mesenchymal stem cells on osteoradionecrosis in a rat model. *Head & Neck* 2018;40:526-35.
- Janus JR, Jackson RS, Lees KA, *et al.* Human Adipose-Derived Mesenchymal Stem Cells for Osseous Rehabilitation of Induced Osteoradionecrosis: A Rodent Model. *Otolaryngol Head Neck Surg*. 2017;156:616-21.
- Mendonça JJ, Juiz-Lopez P. Regenerative Facial Reconstruction of Terminal Stage Osteoradionecrosis and Other Advanced Craniofacial Diseases with Adult Cultured Stem and Progenitor Cells. *Plastic and Reconstructive Surgery* 2010;126:1699-1709.
- Manimaran K, Sankaranarayanan S, Ravi VR, Elangovan S, Chandramohan M, Perumal SM. Treatment of osteoradionecrosis of mandible with bone marrow concentrate and with dental pulp stem cells. *Ann Maxillofac Surg* 2014;4:189-92.
- Gundestrup AK, Lynggaard CD, Forner L, *et al.* Mesenchymal Stem Cell Therapy for Osteoradionecrosis of the Mandible: a Systematic Review of Preclinical and Human Studies. *Stem Cell Rev and Rep*. 2020;16: 1208-21.