



ELSEVIER

Contents lists available at ScienceDirect

## Data in Brief

journal homepage: [www.elsevier.com/locate/dib](http://www.elsevier.com/locate/dib)

## Data Article

# Retinal layer parcellation of optical coherence tomography images: Data resource for multiple sclerosis and healthy controls



Yufan He<sup>a,\*</sup>, Aaron Carass<sup>a</sup>, Sharon D. Solomon<sup>c</sup>, Shiv Saidha<sup>b</sup>,  
Peter A. Calabresi<sup>b</sup>, Jerry L. Prince<sup>a</sup>

<sup>a</sup> Dept. of Electrical and Computer Engineering, The Johns Hopkins University, Baltimore, MD 21218, USA

<sup>b</sup> Dept. of Neurology, The Johns Hopkins School of Medicine, Baltimore, MD 21287, USA

<sup>c</sup> Wilmer Eye Institute, The Johns Hopkins School of Medicine, Baltimore, MD 21287, USA

## ARTICLE INFO

## Article history:

Received 30 June 2018

Received in revised form

14 December 2018

Accepted 20 December 2018

Available online 28 December 2018

## ABSTRACT

This paper presents optical coherence tomography (OCT) images of the human retina and manual delineations of eight retinal layers. The data includes 35 human retina scans acquired on a Spectralis OCT system (Heidelberg Engineering, Heidelberg, Germany), 14 of which are healthy controls (HC) and 21 have a diagnosis of multiple sclerosis (MS). The provided data includes manually delineation of eight retina layers, which were independently reviewed and edited. The data presented in this article was used to validate automatic segmentation algorithms (Lang et al., 2013).

© 2019 Published by Elsevier Inc. This is an open access article under the CC BY-NC-ND license

(<http://creativecommons.org/licenses/by-nc-nd/4.0/>).

## Specifications table

Subject area	<i>Ophthalmology</i>
More specific subject area	<i>Human retina, Multiple sclerosis</i>
Type of data	<i>Optical coherence tomography</i>
How data was acquired	<i>Spectral Domain OCT using Spectralis OCT system</i>
Data format	<i>Raw and Processed</i>

\* Corresponding author

E-mail address: [yhe35@jhu.edu](mailto:yhe35@jhu.edu) (Y. He).

<https://doi.org/10.1016/j.dib.2018.12.073>

2352-3409/© 2019 Published by Elsevier Inc. This is an open access article under the CC BY-NC-ND license (<http://creativecommons.org/licenses/by-nc-nd/4.0/>).

Experimental factors	<i>Human retina without pretreatment</i>
Experimental features	<i>The structure of the human retina was examined with SD-OCT</i>
Data source location	<i>The Johns Hopkins Hospital, Baltimore, MD 21287 USA</i>
Data accessibility	<i>Public download</i>
Related research article	<i>A. Lang, A. Carass, M. Hauser, E.S. Sotirchos, P.A. Calabresi, H.S. Ying, and J. L. Prince, "Retinal layer segmentation of macular OCT images using boundary classification", Biomedical Optics Express, 4(7):1133–1152.</i>

## Value of the data

- This is currently the largest public data set of manually delineated layers of the human retina from OCT scans.
- The data are fully delineated so thickness analysis and algorithm comparison can be performed.
- The data can also be used for training and validation of segmentation algorithms.

## 1. Data

The data presented in this article was used to validate automatic segmentation algorithms [1–3]. The data comprise scans of the right eye of 35 subjects scanned on a Spectralis OCT system (Heidelberg Engineering, Heidelberg, Germany). The cohort comprises 14 healthy controls (HC) and 21 patients with multiple sclerosis (MS); complete demographic information is included in Table 1. All the scans were manually delineated once using internally developed software. For each subject, we provide a retinal OCT image consisting of 49 B-scans and 9 layer boundaries delineated in every B-scan. An example B-scan and the manual delineation is shown in Fig. 1. The provided layers are listed in Table 2. The data is available for download from: <http://iacl.jhu.edu/Resources>.

## 2. Experimental design, materials, and methods

The Spectralis scanner's automatic real-time function is used to acquire the scans. Each B-scan was averaged at least 12 images at the same location and the signal-to-noise ratio of the final averaged scans was at least 20 dB. A macular cube scan ( $20^\circ \times 20^\circ$ ) was acquired with 49 B-scans, each B-scan consists of 1024 A-scans, and each A-scan has 496 pixels. The B-scan resolution varied slightly between subjects, the lateral resolution (between A-scans) has a mean over all the subjects of  $5.8 \mu\text{m}$  ( $\pm 0.2$ ) and the axial resolution (between two pixels in an A-scan) is  $3.9 \mu\text{m}$  ( $\pm 0.0$ ). The through-plane distance (slice separation) has a mean of  $123.6 \mu\text{m}$  ( $\pm 3.6$ ) between images, resulting in an imaging area of approximately  $6 \times 6 \text{ mm}^2$ . The volume data was exported from the scanner using the.vol file format. To facilitate data use, we also provide scripts for reading the.vol files into Matlab. The manual delineations are saved in the.mat file which can be directly imported into Matlab.

Automatic segmentation methods evaluated using this dataset can be found in Refs. [1–6] and other works using this data, in whole or part, include [7–12].

**Table 1**

Demographic details for the data. The top line is the information of the entire data set, subsequent lines are specific to that category. *N* (M/F) denotes the number of patients and the male/female ratio, respectively. Age is the mean age (and standard deviation) in years at scan time. The key for the table is: HC – Healthy Controls; MS – Multiple Sclerosis.

Dataset	<i>N</i> (M/F)	Age Mean (SD)
ALL	35 (6/29)	39.49 (10.94)
HC	14 (2/12)	35.77 (13.03)
MS	21 (4/17)	41.97 (8.77)

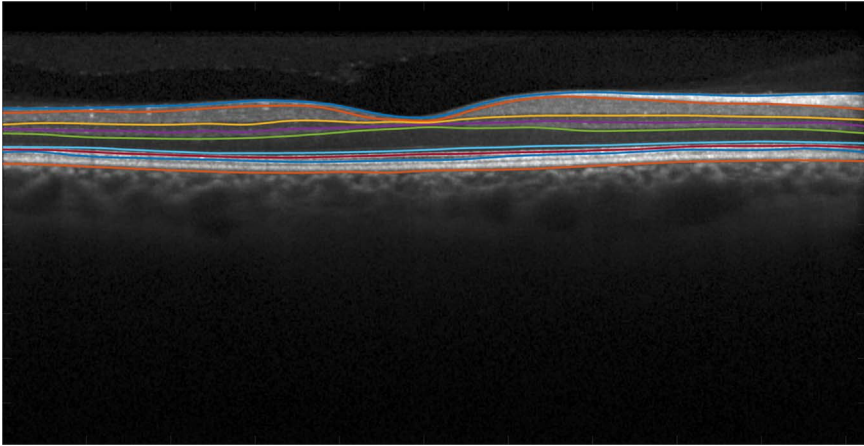


Fig. 1. An example B-scan images, showing the included manual delineations.

**Table 2**

Manually delineated retina layers.

Layer name	Abbreviation
Retina nerve fiber layer	RNFL
Ganglion cell layer and inner plexiform layer	GCL+IPL
Inner nuclear layer	INL
Outer plexiform layer	OPL
Outer nuclear layer	ONL
Inner photoreceptor segments	IS
Outer photoreceptor segments	OS
Retinal pigment epithelium	RPE

## Acknowledgments

This work was supported by the NIH under NEI grant R01-EY024655 (PI: J.L. Prince) and NINDS grant R01-NS082347 (PI: P.A. Calabresi).

## Transparency document. Supporting information

Transparency data associated with this article can be found in the online version at <https://doi.org/10.1016/j.dib.2018.12.073>.

## References

- [1] A. Lang, A. Carass, M. Hauser, E.S. Sotirchos, P.A. Calabresi, H.S. Ying, J.L. Prince, Retinal layer segmentation of macular OCT images using boundary classification, *Biomed. Opt. Express* 4 (7) (2013) 1133–1152.
- [2] A. Carass, A. Lang, M. Hauser, P.A. Calabresi, H.S. Ying, J.L. Prince, Multiple-object geometric deformable model for segmentation of Macular. OCT, *Biomed. Opt. Express* 5 (4) (2014) 1062–1074.
- [3] Y. He, A. Carass, Y. Yun, C. Zhao, B.M. Jedynek, S.D. Solomon, S. Saidha, P.A. Calabresi, J.L. Prince, Towards topological correct segmentation of macular OCT from cascaded FCNs, *Fetal, Infant and Ophthalmic Medical Image Analysis*, Springer (2017) 202–209.
- [4] Y. He, A. Carass, Y. Yun, C. Zhao, B.M. Jedynek, S.D. Solomon, P.A. Calabresi, J.L. Prince, Topology Guaranteed Segmentation of the Human Retina from OCT Using Convolutional Neural Networks. *arXiv preprint (arXiv:1803.05120)* (2018).
- [5] Y. Liu, A. Carass, S.D. Solomon, S. Saidha, P.A. Calabresi, J.L. Prince, Multi-layer fast level set segmentation for macular OCT, in: *Proceedings of the IEEE 15th International Symposium on Biomedical Imaging (ISBI 2018)*, 2018, pp. 1445–1448.

- [6] A. Lang, A. Carass, A.K. Bittner, H.S. Ying, J.L. Prince, Improving graph based segmentation for severe pathology in Retinitis Pigmentosa patients, *Proc. SPIE Med. Imaging (SPIE-MI 2017)* (2017) (pp. 10137-10137-8).
- [7] A. Lang, A. Carass, A.K. Bittner, H.S. Ying, J.L. Prince, Intensity inhomogeneity correction of macular OCT using N3 and retinal flatspace, in: *Proceedings of the IEEE 13th International Symposium on Biomedical Imaging (ISBI 2016)*, 2016, pp. 197–200.
- [8] A. Lang, A. Carass, B.M. Jedynek, S.D. Solomon, S. Saidha, P.A. Calabresi, J.L. Prince, Intensity inhomogeneity correction of SD-OCT data using macular flatspace, *Med. Image Anal.* 43 (2018) 85–97.
- [9] P. Bhargava, A. Lang, O. Al-Louzi, A. Carass, J.L. Prince, P.A. Calabresi, S. Saidha, Applying an open-source segmentation algorithm to different OCT devices in multiple sclerosis patients and healthy controls, *Mult. Scler. Int.* (2015) (Article ID 136295).
- [10] M. Chen, A. Lang, H.S. Ying, P.A. Calabresi, J.L. Prince, A. Carass, Analysis of Macular OCT images using deformable registration, *OCT. Biomed. Opt. Express* 5 (7) (2014) 2184–2195.
- [11] M. Chen, A. Lang, E. Sotirchos, H.S. Ying, P.A. Calabresi, J.L. Prince, A. Carass, Deformable registration of Macular OCT using A-mode scan similarity, in: *Proceedings of the IEEE 10th International Symposium on Biomedical Imaging (ISBI 2013)*, 2013, pp. 476–479.
- [12] S. Reaungamornrat, A. Carass, Y. He, S. Saidha, P.A. Calabresi, J.L. Prince, Inter-scanner variation independent descriptors for constrained diffeomorphic registration of retinal OCT, *Proc. SPIE Med. Imaging (SPIE-MI 2018)* (2018) (pp. 10574-10574-9).