

Loss of Contralateral Upper Limb Motor Evoked Potential Due to Occlusion of the Internal Carotid Artery in Microsurgical Clipping of Basilar Tip Aneurysm

Abstract

The motor evoked potential (MEP) monitoring is routinely used as an adjunct in the microsurgical clipping of anterior circulation. We describe a case of unruptured basilar tip aneurysm treated with microsurgical clipping developed loss in MEP recording of the left abductor pollicis brevis (APB) following clipping of basilar tip aneurysm. A 58-year-old man was referred to the Fujita Health University Banbuntane-Hotokukai Hospital, Nagoya, Aichi, Japan, with incidental finding of unruptured 6.5 mm basilar tip saccular aneurysm. He underwent right anterior temporal approach of basilar tip aneurysm clipping. The internal carotid artery (ICA) was mobilized laterally to allow direct visualization of the neck of the basilar tip aneurysm. Following the application of temporary clip and subsequently permanent clip at the neck of the aneurysm, the MEP signal was lost in the left APB. The temporary clip was immediately removed. Dual-image videoangiography (DIVA) showed a filling defect in the right ICA and a branch of middle cerebral artery (MCA). The MEP was absent for about 23 minutes and the amplitude improved to only 75% of the baseline recording at 38 minutes till the end of the surgery. A repeat DIVA showed good flow within the right ICA and MCA. Glasgow coma score was 15/15 on postoperative day 1 and there was no gross motor or sensory deficit except right oculomotor nerve palsy with complete recovery at 6 months follow-up. This is the first reported ICA occlusion due to its mobilization in microsurgical clipping of basilar tip aneurysm. The use of neuromonitoring especially MEP is essential even in the posterior circulation aneurysm surgery especially when excessive manipulation of the ICA is unavoidable. When performing intraoperative angiography for aneurysm surgery, it is prudent to detect any filling defect within the surrounding vessels.

Keywords: Basilar tip aneurysm, internal carotid artery, motor evoked potential, posterior circulation

Introduction

Posterior circulation aneurysms represent 10% of all intracranial aneurysm.^[1] Basilar tip aneurysm is the most common aneurysm in the vertebrobasilar system. The motor evoked potential (MEP) monitoring is routinely used as an adjunct in the microsurgical clipping of anterior circulation. We describe a case of unruptured basilar tip aneurysm treated with microsurgical clipping developed loss in MEP recording of the left abductor pollicis brevis (APB) following clipping of basilar tip aneurysm.

Case Report

A 58-year-old man was referred to the Fujita Health University Banbuntane-Hotokukai

Hospital, Nagoya, Aichi, Japan, with incidental finding of unruptured basilar tip aneurysm. He has been suffering from hypertension. He is a chronic smoker. There was no family history of any vascular diseases in his family. He underwent magnetic resonance imaging (MRI) and magnetic resonance angiography (MRA) of the brain on April 12, 2017 as part of the “Japanese Brain Dock” program. Incidentally, a 6.5 mm basilar tip saccular aneurysm was found [Figure 1].

Subsequently, he was referred to our institution. A two-dimensional and three-dimensional computed tomography angiography of the brain and a computational fluid dynamics study were performed on May 2, 2017, before the surgery [Figure 2].

Liew Boon Seng,
Yamada Yasuhiro¹,
Niranjana
Rajagopal²,
Ameen Abdul
Mohammad³,
Teranishi Takao¹,
Miyatani Kyosuke¹,
Kawase Tsukasa¹,
Yoko Kato¹

Department of Neurosurgery,
Hospital Sungai Buloh, Sungai
Buloh, Selangor, Malaysia,
¹Department of Neurosurgery,
Banbuntane Hotokukai Hospital,
Fujita Health University,
Nagoya, Japan, ²Department
of Neurosurgery, Sathya Sai
Institute of Higher Medical
Sciences, Bengaluru, Karnataka,
³Department of Neurosurgery,
Aayush Hospital, Vijayawada,
Andhra Pradesh, India

Address for correspondence:

Dr. Liew Boon Seng,
Department of Neurosurgery,
Hospital Sungai Buloh,
Jalan Hospital, 47000 Sungai
Buloh, Selangor, Malaysia.
E-mail: liew_bs@yahoo.com

Access this article online

Website: www.asianjns.org

DOI: 10.4103/ajns.AJNS_157_18

Quick Response Code:



How to cite this article: Seng LB, Yasuhiro Y, Rajagopal N, Mohammad AA, Takao T, Kyosuke M, et al. Loss of contralateral upper limb motor evoked potential due to occlusion of the internal carotid artery in microsurgical clipping of basilar tip aneurysm. Asian J Neurosurg 2019;14:295-9.

This is an open access journal, and articles are distributed under the terms of the Creative Commons Attribution-NonCommercial-ShareAlike 4.0 License, which allows others to remix, tweak, and build upon the work non-commercially, as long as appropriate credit is given and the new creations are licensed under the identical terms.

For reprints contact: reprints@medknow.com

He underwent right anterior temporal approach of basilar tip aneurysm clipping on May 31, 2017. MEP neuromonitoring was used during the surgery. Anterior clinoidectomy and opening of the dura ring was performed to mobilize the internal carotid artery (ICA) laterally. Posterior clinoidectomy was performed to allow direct visualization of the neck of the basilar tip aneurysm. Dual-image videoangiography (DIVA) was performed by injection of indocyanine green (ICG) intravenously. The video showed a small intraluminal filling defect in the cisternal segment of the ICA which was not recognized earlier during surgery [Figure 3a]. MEP recordings were similar to baseline at 13:50H. At 14:06H, the temporary clip was placed at the basilar trunk, followed by the application of the permanent clip at the neck of aneurysm.

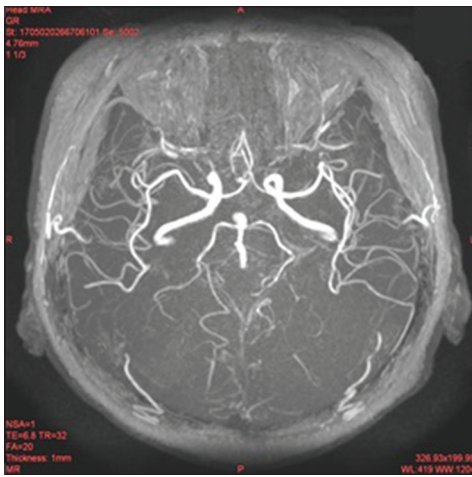


Figure 1: Magnetic resonance imaging angiography of the brain on April 12, 2017, showing a basilar tip saccular aneurysm

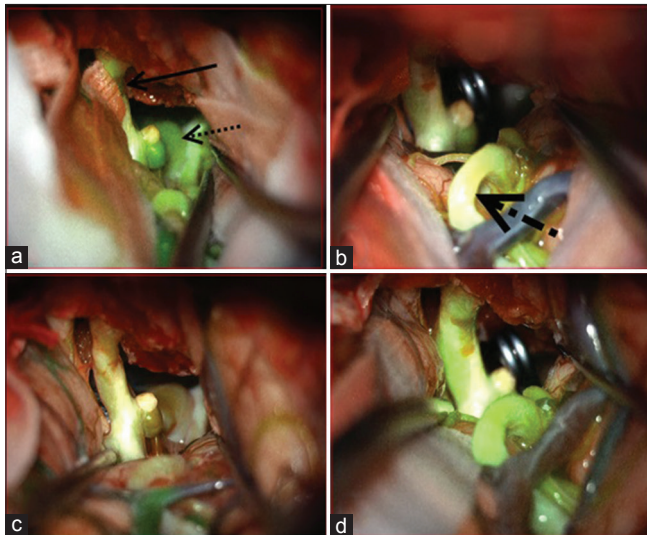


Figure 3: Intraoperative dual-image videoangiography. (a) Initial unnoticed filling defect (solid arrow) in the internal carotid artery when the motor evoked potential recording was normal (dotted arrow showing basilar tip aneurysm); (b) Occlusion also noted within a branch of middle cerebral artery (dotted-dash arrow); (c) Obvious filling defect within ICA when the signal of the motor evoked potential recording was lost; (d) Good flow within both internal carotid artery and a branch of the middle cerebral artery

At 1411H, there was a sudden loss of MEP recording at the left APB [Figure 4]. The temporary clip was immediately removed. The total duration of temporary clip was 5 minutes. DIVA was performed which showing filling defect in the right ICA and a branch of middle cerebral artery

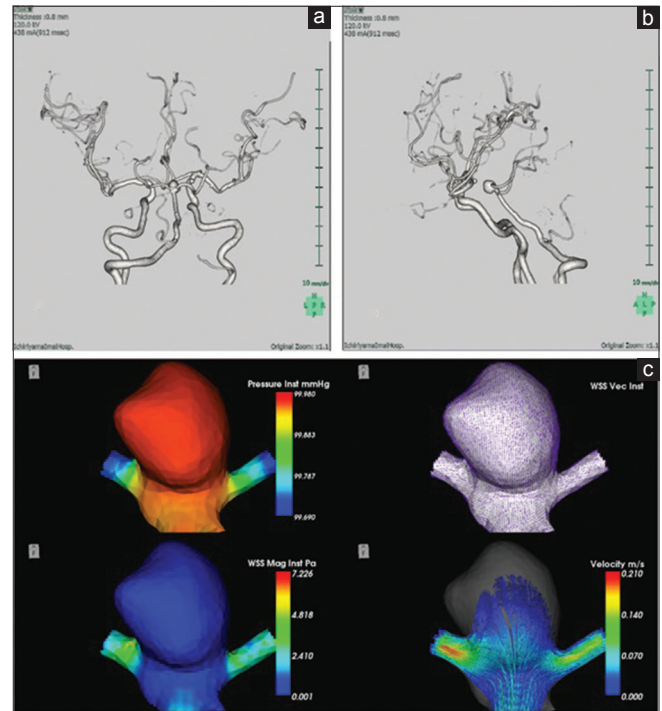


Figure 2: Three-dimensional computed tomography angiography of the brain and a computational fluid dynamics study on May 2, 2017. (a) Posterior view of three-dimensional computed tomography angiography of the brain; (b) Left view of three-dimensional computed tomography angiography of the brain; (c) Computational fluid dynamic study showing high wall pressure with low WSS pressure and WSS vector and the streamline within the basilar tip aneurysm sac. WSS: Wall stream stress

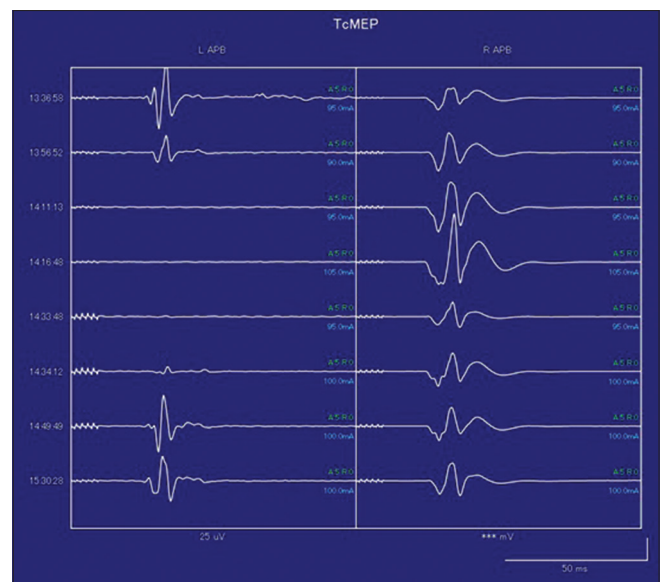


Figure 4: Motor evoked potential recordings. Loss of motor evokes potential recordings from the abductor pollicis brevis using transcranial motor evoke potential from 14:11H, signal returned at 14:49H

(MCA) [Figure 3b and c]. Intravenous edaravone was administered. The MEP was absent for about 23 minutes with initial recordings at 15% of the baseline amplitude. The amplitude improved to only 75% of the baseline recording at 38 minutes till the end of the surgery. A repeat DIVA was performed which demonstrating good blood flow in the ICA [Figure 3d].

He was extubated immediately after the surgery with Glasgow Coma Scale of Eye 3 Verbal 5 and Motor 6 (14/15) which improved to full the following day. There was no gross motor or sensory deficit except complete ptosis in the right eye with anisocoria, consistent with a right oculomotor nerve palsy. The extraocular movements were intact. MRI and MRA of the brain were performed the same day of surgery showed no ischemic changes and good flow in all major intracranial

arteries [Figure 5a-f]. He was discharged on postoperative day 10. The improvement of the right oculomotor nerve palsy was noted on 3 months and completely recovery at 6 months follow-up. He was readmitted on October 10, 2017, with a complaint of a mild headache and CT scan of the brain showed right frontoparietal chronic subdural hematoma [Figure 5g]. He underwent burr hole and subdural drainage. The surgery was uneventful, and a repeat CT scan brain showed no residual hematoma [Figure 5h]. He was then discharged well. He was asymptomatic during his recent outpatient clinic visit on January 10, 2018.

Discussion

Microsurgical clipping of basilar tip aneurysm is challenging due to narrow corridor and deep surgical field.^[2]

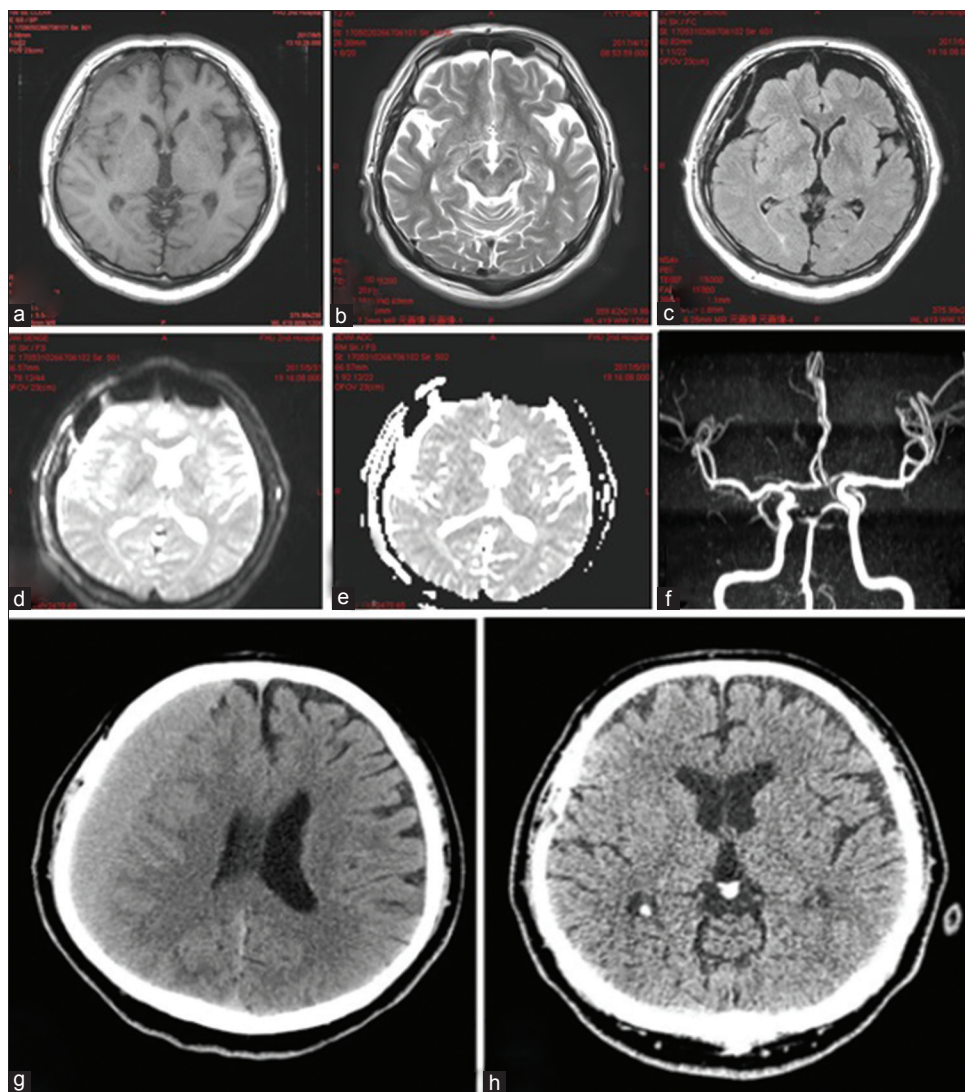


Figure 5: (a-e) Magnetic resonance imaging done on May 31, 2017; (f) Magnetic resonance angiography done on May 31, 2017; (g): Computed tomography scan of the brain done on October 10, 2017; (h) Computed tomography scan of the brain done on October 11, 2017. (a) T1-weighted; (b) T2-weighted, (c) fluid-attenuated inversion recovery; (d) Diffusion weighted Imaging; (e) Apparent diffusion coefficient – No other all the different sequences of magnetic resonance imaging of the brain suggestive of any acute ischemic changes; (f) Magnetic resonance imaging showing no residual aneurysm at the basilar tip with both right internal carotid artery and middle cerebral artery are well seen; (g) Computed tomography scan of the brain (plain) showing right frontoparietal hypo- to isodense subdural collection suggestive of chronic subdural hematoma; (h) Computed tomography scan of the brain showing no residual subdural collection

Few approaches for microsurgical clipping of basilar tip aneurysm are pterional, fronto-orbitozygomatic, anterior temporal, subtemporal, and posterior temporal with anterior petrosectomy. The selection of the surgical approach is depending on few factors. First and foremost is the position of the basilar trunk. It may deviates to one particular position. The position and configuration of the aneurysm sac is another consideration. Commonly anterior pointing aneurysm is more favored for microsurgical clipping than those pointing posteriorly. The knowledge of the position of the posterior communicating artery and posterior cerebral artery (PCA) in relation to the basilar artery are also essential in deciding either left or right approach. Findings related to the position of basilar tip aneurysm, clivus (dorsum sella), anterior and posterior clinoid processes along the surgical corridor are used to decide if microsurgical clipping is ever feasible in any particular case.

Classically, the basilar artery is divided into fifths. The upper two-fifths, all these three bony structures can obscure the neck of the basilar tip aneurysm. Usually, fronto-orbital or anterior temporal can reach the aneurysm. However, if the neck is lower than the floor of sella and higher than the petrous apex, then subtemporal approach may be indicated.^[1] Posterior clinoidectomy can be performed if it allows additional window to visualize the neck of the aneurysm. A systematic historical review of different surgical approaches in a published literature found that the outcome were considered similar for anterior temporal, subtemporal, or transsylvian approached if the aneurysm is located between -1 and +7 mm in relation to the posterior clinoid process. According to the same author, the pretemporal approach is suitable for large and giant basilar tip aneurysm.^[3]

One important vessel which may obscure the direct visualization of the basilar tip aneurysm is the ICA. Anterior clinoidectomy and opening of the dura ring may allow mobilization of the carotid artery. It may be displaced more laterally or medially. Care must be taken with such maneuver by identifying and preserving all the perforators from the ICA. Besides that, the anterior cerebral artery, MCA, optic nerve, and temporal lobe may obscure the straight pathway toward basilar tip.^[2] However, if the basilar tip is obscured by the PCA, and PCA cannot be mobilized due to its attachment to posterior communicating artery (PCOM), the ligation and division of the PCOM is an option in subtemporal approach.^[4]

Opening the sylvian fissure is necessary to displace the temporal lobe laterally and allow it to fall off the skull base position with gravity. This will create more room for the surgery with minimal or no brain retraction. A thorough inspection of the dome and the neck of the aneurysm are important. This process can be assisted by using the neuroendoscope, intraoperative ICG, and DIVA.

In this case, the mobilization of the ICA has resulted dissection or thromboembolus formation within it. As

precaution, the patency of the vessels can be checked intermittently by using the carotid Doppler device. Indirect monitoring techniques include MEP and somatosensory evoked potential (SSEP) monitoring and brainstem auditory evoked potential. Some authors have been advocating the use of MEP monitoring only in the microsurgical clipping of the anterior circulation aneurysm but not posterior circulation aneurysm. However, due to the need to mobilize the ICA, and possibility of compression of the branch of MCA due to inadequate arachnoid of the sylvian fissure, MEP, and SSEP are important adjuncts in the surgery of posterior circulation aneurysm.

Alternative to intraoperative neuromonitoring is to perform the surgery in awake. This is an important consideration if the application of a temporary clip cannot be avoided. Awake surgery offers a solution to the delay in MEP signals change during cerebral ischemia.^[5] Nevertheless, the application of temporary clip may not be necessary in most cases. In this case, a temporary clip was applied due to the high risk of premature rupture of the aneurysm during the application of a permanent aneurysm clip. Edaravone (Radicava, Mitsubishi Tanabe Pharma America), a novel neuroprotective agent which has been approved by the Food and Drug Administration for the treatment of amyotrophic lateral sclerosis, is used in Japan to treat stroke. It works as cytoprotection in ischemic stroke. It is a low molecular weight antioxidant drug. In 2001, it has been approved in Japan to be used to treat acute phase of cerebral infarction.^[6]

There have been few publications related the relationship between spontaneous ICA occlusion due to dissection with formation intracranial aneurysms.^[7,8] This is the first reported case of ICA dissection with spontaneous resolution of dissection due to surgical manipulation of the vessel.

Conclusion

This is the first reported ICA occlusion due to its mobilization in microsurgical clipping of basilar tip aneurysm. The use of neuromonitoring especially MEP is essential even in the posterior circulation aneurysm surgeries especially when excessive manipulation of the ICA is unavoidable. When performing intraoperative angiography for aneurysm surgery, it is prudent to detect any filling defect within the surrounding vessels especially those mobilized during surgery. Performing an intraoperative angiography and the ability to recognize this abnormal signal before the application of a retractor or temporary clip in neurovascular surgery is the crucial point learned in this case.

Declaration of patient consent

The authors certify that they have obtained all appropriate patient consent forms. In the form the patient(s) has/have given his/her/their consent for his/her/their images and other clinical information to be reported in the journal. The

patients understand that their names and initials will not be published and due efforts will be made to conceal their identity, but anonymity cannot be guaranteed.

Acknowledgment

We would like to thank the Hospital Director of Fujita Health University Banbuntane Hotokukai Hospital, Nagoya, Japan, for the permission to publish this paper.

Financial support and sponsorship

Nil.

Conflicts of interest

There are no conflicts of interest.

References

1. Gonzalez LF, Amin-Hanjani S, Bambakidis NC, Spetzler RF. Skull base approaches to the basilar artery. *Neurosurg Focus* 2005;19:E3.
2. Matsuyama T, Shimomura T, Okumura Y, Sakaki T. Mobilization of the internal carotid artery for basilar artery aneurysm surgery. Technical note. *J Neurosurg* 1997;86:294-6.
3. Spiessberger A, Strange F, Fandino J, Marbacher S. Microsurgical clipping of basilar apex aneurysms: A systematic historical review of approaches and their results. *World Neurosurg* 2018;114:305-16.
4. Kakino S, Ogasawara K, Kubo Y, Nishimoto H, Ogawa A. Subtemporal approach to basilar tip aneurysm with division of posterior communicating artery: Technical note. *Vasc Health Risk Manag* 2008;4:931-5.
5. Suzuki K, Mikami T, Sugino T, Wanibuchi M, Miyamoto S, Hashimoto N, *et al.* Discrepancy between voluntary movement and motor-evoked potentials in evaluation of motor function during clipping of anterior circulation aneurysms. *World Neurosurg* 2014;82:e739-45.
6. Watanabe K, Tanaka M, Yuki S, Hirai M, Yamamoto Y. How is edaravone effective against acute ischemic stroke and amyotrophic lateral sclerosis? *J Clin Biochem Nutr* 2018;62:20-38.
7. Sastri SB, Sadasiva N, Pandey P. Giant cavernous carotid aneurysm with spontaneous ipsilateral ICA occlusion: Report of 2 cases and review of literature. *J Neurosci Rural Pract* 2013;4:S113-6.
8. See AP, Gross BA, Penn DL, Du R, Frerichs KU. Hemodynamic impact of a spontaneous cervical dissection on an ipsilateral saccular aneurysm. *J Cerebrovasc Endovasc Neurosurg* 2016;18:110-4.