

A new modified bone grafting technique for periodontally accelerated osteogenic orthodontics

Zhigui Ma, PhD^a, Jisi Zheng, MS^a, Chi Yang, PhD^{a,*}, Qianyang Xie, MS^a, Xiaohan Liu, MS^a, Ahmed Abdelrehem, PhD^b

Abstract

The aim of this study was to introduce an improved surgical technique using a pouch design and tension-free wound closure for periodontally accelerated osteogenic orthodontics (PAOO) in the anterior alveolar region of the mandible.

Patients with bone dehiscence and fenestrations on the buccal surfaces of the anterior mandible region underwent the modified PAOO technique (using a pouch design and tension-free closure). Postoperative symptoms were evaluated at 1 and 2 weeks intervals following the procedure. Probing depth (PD), gingival recession depth (GRD), and clinical attachment level (CAL) were assessed at the gingival recession sites at baseline, postoperative 6 and 12 months. Cone-beam computerized tomography (CBCT) was used for quantitative radiographic analyses at baseline, 1 week and 12 months after bone-augmentation procedure.

The sample was composed of a total of 12 patients (2 males and 10 females; mean age, 21.9 years) with 72 teeth showing dehiscence/fenestrations and 17 sites presenting with gingival recessions. Clinical evaluations revealed a statistically significant reduction in swelling, pain, and clinical appearance from postoperative week 1 to week 2 ($P < .05$). Moreover, gingival recession sites exhibited a significant reduction in the GRD and an increase in CAL after surgery with mean root coverage of 69.8% at the end of observation period ($P < .01$). Both alveolar bone height and width increased after surgery ($P < .01$) and decreased during the 12-month follow-up ($P < .01$). However, compared with the baseline records, there was still a significant increase in alveolar bone volume ($P < .01$).

This modified PAOO technique may have advantages in terms of soft and hard tissue augmentation, facilitating extensive bone augmentation and allowing the simultaneous correction of vertical and horizontal defects in the labial aspect of the mandibular anterior area.

Abbreviations: AHBT = horizontal bone thickness at the middle level of the apical third, BL = baseline, CAL = clinical attachment level, CBCT = cone-beam computerized tomography, CEJ = the cemento-enamel junction, CHBT = horizontal bone thickness at the middle level of the coronal third, GM = gingival recession, GRD = gingival recession depth, MHBT = horizontal bone thickness at the middle level of the middle third, PAOO = periodontally accelerated osteogenic orthodontics, PD = probing depth, VAS = visual analog scale, VBL = vertical alveolar bone level.

Keywords: corticotomy-assisted orthodontic treatment, gingival recession, guided bone regeneration, lateral ridge augmentation, vertical ridge augmentation

Editor: Li Wu Zheng.

ZM and JZ contributed equally to this work and should be considered co-first authors.

Funding: The study was supported by Shanghai Summit & Plateau Disciplines, Science and Technology Commission of Shanghai Municipality Science Research Project (14DZ2294300), Project of outstanding youth backbone of the 9th hospital (jyyq08201601) and the interdisciplinary Program of Shanghai Jiao Tong University (YG2016QN04).

The authors have no conflicts of interest to disclose.

^a Department of Oral Surgery, Shanghai Ninth People's Hospital Affiliated to Shanghai Jiaotong University, School of Medicine, Shanghai Key Laboratory of Stomatology, Shanghai, PR China, ^b Department of Craniomaxillofacial and Plastic Surgery, Faculty of Dentistry, Alexandria University, Alexandria, Egypt.

* Correspondence: Chi Yang, Department of Oral Surgery, Shanghai Ninth People's Hospital Affiliated to Shanghai Jiaotong University, School of Medicine, 639 Zhi Zao Ju Road, Shanghai, 200011, PR China (e-mail: yangchi1963@hotmail.com).

Copyright © 2018 the Author(s). Published by Wolters Kluwer Health, Inc. This is an open access article distributed under the terms of the Creative Commons Attribution-Non Commercial-No Derivatives License 4.0 (CCBY-NC-ND), where it is permissible to download and share the work provided it is properly cited. The work cannot be changed in any way or used commercially without permission from the journal.

Medicine (2018) 97:37(e12047)

Received: 16 January 2018 / Accepted: 1 August 2018

<http://dx.doi.org/10.1097/MD.00000000000012047>

1. Introduction

The anatomic limits set by the dense cortical plates of the alveolus during anterior teeth movement could be regarded as “orthodontic walls.”^[1] It seems that the pre-existing alveolar bone loss involving fenestration or dehiscence is common in the anterior mandibular teeth.^[2] A fenestration is a window of bone loss that places the exposed root surface directly in contact with the gingiva or alveolar mucosa.^[3] Dehiscence is a vertical root-exposed defect where the denuded areas involve the alveolar bone margin.^[4] When the anterior roots are about to challenge the “orthodontic walls,” the reduced volume of the alveolar bone during orthodontic treatment may have deleterious effects on the periodontal support, such as an exacerbated alveolar bone loss, root resorption, and gingival recession.^[5–8] Therefore, it is clearly beneficial for the clinician to prevent iatrogenic sequelae during orthodontic treatment.

Lateral ridge augmentation procedures are necessary when the width of the alveolar ridge does not correlate with the adequate measurements for tooth movement. Accordingly, periodontally accelerated osteogenic orthodontics (PAOO) has been proposed as an alternative therapeutic approach for narrow alveolar ridge to facilitate tooth movement by a combination of selective alveolar bone decortication and bone augmentation with

particulate grafting material.^[9–12] It expands the range of possible tooth movement with an increased alveolar bone volume and a more structurally intact/periodontium. Compared with the conventional orthodontic treatment, PAOO reduces the risk of periodontal defects and has been used to overcome the typical limitations of progressive bone loss.^[13,14]

Attention must be paid to the deficiency of the vertical ridge regeneration following the traditional PAOO. Although an increase in the alveolar bone width of 2.4 mm near the apex of the anterior teeth, alveolar augmentation was mainly attached at the level of the middle thirds and an insufficient regeneration involving the vertical alveolar defect was also observed.^[15] For patients with severe Class III malocclusion, the vertical alveolar bone level of the lower incisors reduced during decompensation after PAOO operation.^[16] Thus, vertical alveolus regeneration remains a great challenge with the traditional PAOO technique.

The purpose of this study was to describe a modified PAOO to effectively augment the bone volume in anterior lower alveolar ridge. In this technique, a pouch was generated by suture fixation of membranes with the surrounding periosteum apically and laterally, which could be filled with bone grafting material. This technique may have more advantages than the traditional PAOO in being tension-free design and having adequate membrane coverage and dealing with limitations attributable to the augmented grafting material displacement and leakage. Clinical and radiographic outcomes of this procedure were evaluated to confirm the effects for the modified technique in this study.

2. Patients and methods

2.1. Study participants

The primary researcher (M.Z.G.) recruited the patients who were enrolled from the Department of Oral Surgery, Shanghai Ninth People's Hospital, Shanghai Jiao Tong University, School of Medicine (Shanghai, China). Approval was obtained from the institutional review board of the Ninth People's Hospital (Shanghai, China). All participants signed an informed consent agreement for this study.

From April 2015 to August 2015, consecutive patients were included in this study based on the following criteria: aged 18 years or older; orthodontic camouflage for dental Class II or decompensation for skeletal Class III malocclusions; cone-beam computerized tomography (CBCT) showing alveolar bone loss involving dehiscences or fenestrations on the labial surface of the lower anterior alveolar region before treatment; good oral hygiene; moderate crowding of the lower anterior teeth. Patients were excluded, if one or more of the following criteria were present: administration of any medication that affects bone metabolism, such as prolonged use of corticosteroids, bisphosphonates, or nonsteroidal anti-inflammatory drugs; previous orthodontic or orthognathic treatment; endodontic therapies or restoration of the lower anterior teeth; morphologic tooth anomalies; systemic diseases; smoking; and pregnancy or lactation.

2.2. Orthodontic treatment

All patients were treated with 0.022- × 0.028-inch preadjusted appliances 1 week before surgery. Orthodontic tooth movement was activated 2 weeks after the surgical procedure; the interval allowed between the routine orthodontic adjustments was 2 weeks, which is in accordance with the previous reports.^[16,17] During orthodontic treatment, the mandibular arch was initially

aligned and levelled using nickel titanium arch wires of an increasing size (0.014", 0.018", 0.014 × 0.025" and 0.018" × 0.025"). Stainless steel arch wires were placed (0.019" × 0.025") for completion of the treatment. During the active tooth movement phase, patients were assessed by the periodontist with a 1-month interval.

2.3. Surgical technique

2.3.1. Flap reflection. This modified technique in the current study was performed under local anesthesia with 2% lidocaine and 1:100,000 epinephrine by the same surgeon (YC). A full-thickness mucoperiosteal flap was elevated using sulcular incision at the interdental papillae and 2 vertical releasing incisions positioned at 1 tooth beyond the "bone activation" region, enabling an adequate exposure of the surgical field and avoiding any tension (Fig. 1A). During this procedure, care was taken not to jeopardize the mental nerve and blood vessels when reflecting the flap. Local anesthesia was again injected at the base of the elevated flap, which could reduce bleeding for the following periosteal releasing incision. A split-thickness flap separating the periosteum flap from the overlying mucosal layer apically for 3 to 4 mm was made using surgical scissors (Fig. 1B). Two segments were created, including "coronal" and "apical" segments of the periosteal flap.

2.3.2. Corticotomy. Selective alveolar decortications were performed using a piezoelectric surgical device (Piezosurgery, Silfragent, Italy) after flap reflection just like the original PAOO. Vertical osteotomies were placed in the inter-radicular space, which extended 2 to 3 mm below the crest of the alveolar bone and connected with horizontal grooves located 2 to 3 mm beyond the apices of the roots (Fig. 1B).

2.3.3. Grafting. Deproteinized bovine bone material (Bio-Oss, Geistlich Biomaterials AG, Wolhusen, Switzerland) was positioned in the prepared pouch with light pressure. Our preference was to place the graft material also at the cemento-enamel junction (CEJ) level, which facilitated vertical ridge regeneration (Fig. 1C).

2.3.4. Pouch formation. Two collagen membranes (Bio-Guide, 25 × 25 mm Geistlich Biomaterials AG) were sutured together to prevent mutual shifting by 5-0 absorbable sutures (Fig. 1D). At the bottom, membranes were secured to the "apical" segment of the periosteal layer elevating from the mucoperiosteal flap by periosteum-releasing incision. In addition, membranes were connected to the periosteum dissected from vertical releasing incisions laterally. Consequently, a well-defined pouch was created by suture fixation of membranes with the surrounding periosteum apically and laterally (Fig. 1E). Finally, the membrane was placed extending 2 to 3 mm beyond the CEJ for complete coverage the grafting material at coronal aspect.

2.3.5. Closure techniques. Flap tissues were advanced and positioned to cover the membrane exhibiting partial membrane exposure in the oral environment. The flap was coronally advanced to cover the grafting site, and allow for a tension-free adaptation of the wound margins. Single interrupted sutures were used with 4-0 absorbable polyester, which connected the lingual tissue, the labial flap and the membrane together (Fig. 1F). The tissue at the midline was sutured first to ensure the correct alignment of the papillae. It seems that membrane exposure would be better for a tight closure of the wound margins without

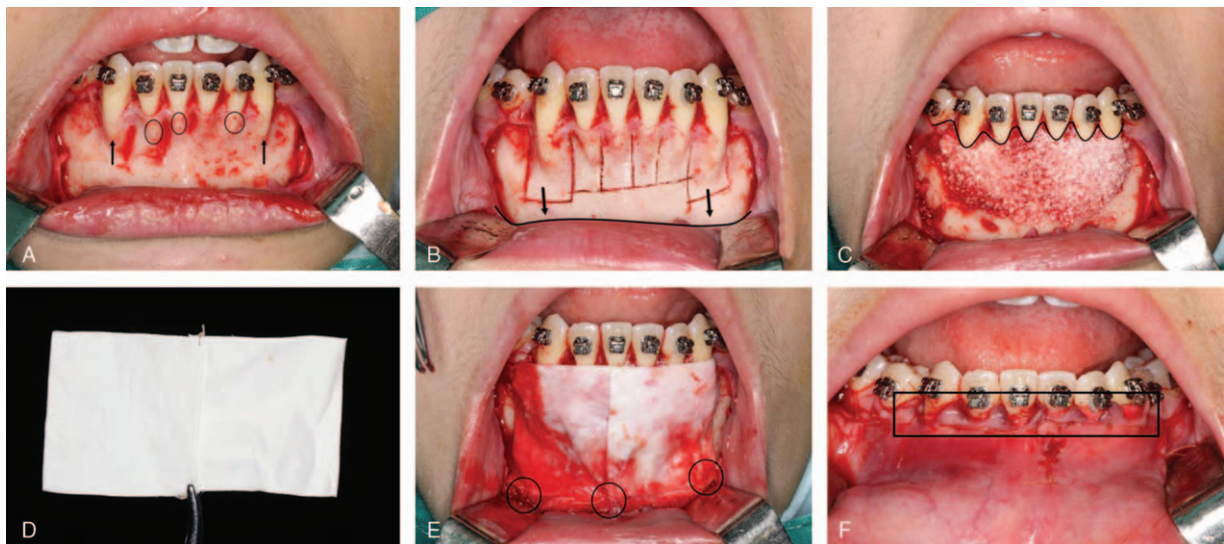


Figure 1. The modified periodontally accelerated osteogenic orthodontics (PAOO) augmented corticotomy in the lower anterior alveolar region. (A) Full-thickness mucoperiosteal flap reflection. Black circles and arrows show root fenestrations and dehiscences, respectively; (B) performing circumferential corticotomy cuts and periosteal releasing incision at the bottom as a black line shown; (C) placing grafting materials along the cemento-enamel junction (CEJ) at the coronal aspect (wavy line); (D) suturing two barrier membranes together; (E) a well-defined pouch created by suture fixation (black circles) of membranes to the surrounding periosteum apically and laterally; (F) black box shows membrane exposure after flap repositioning. CEJ=the cemento-enamel junction, PAOO=periodontally accelerated osteogenic orthodontics.

graft containment. Figure 2 shows the flap design for this modified PAOO technique.

2.3.6. Postoperative management. The patient was instructed to apply extraoral cold packs to the surgical area immediately

after surgery to decrease postoperative swelling and edema. The patient was advised to refrain from mechanical cleansing of the surgical site. Cephalosporin antibiotics combined with metronidazole were routinely prescribed for at least 3 days and 0.12% chlorhexidine gluconate oral rinses were used twice daily for plaque control.

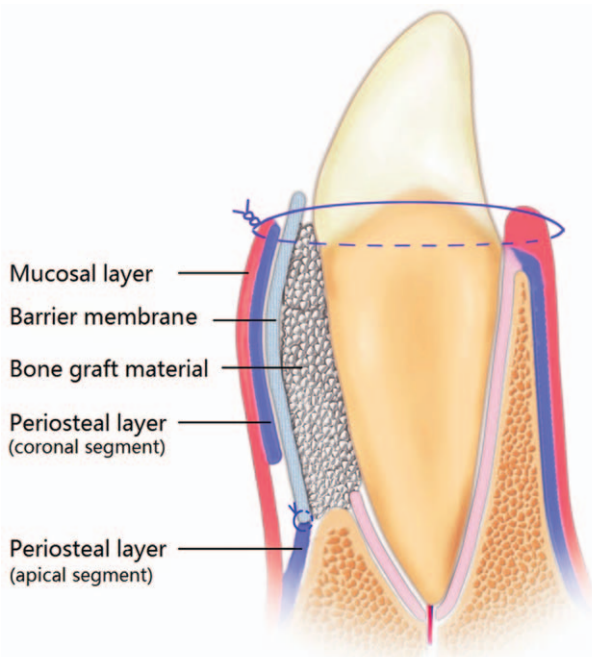


Figure 2. Schematic diagram of modified PAOO. Suture fixation of membranes to the “apical” segment of the periosteal layer elevating from the mucoperiosteal flap by periosteum-releasing incision. PAOO=periodontally accelerated osteogenic orthodontics.

2.4. Outcome evaluations

All patients were examined by 1 independent examiner (ZJS) who has 3-year experience as an oral and maxillofacial surgeon and was well calibrated before the study.

2.4.1. Clinical assessments. Postoperative symptoms including limitation of mouth opening, facial swelling, pain and clinical appearance were evaluated at 1st and 2nd postoperative weeks, respectively. Trismus was evaluated by the difference of maximal interincisal opening between preoperative and each postoperative measurements. Facial swelling was the difference of linear distance from the tragus to the pogonion between pre and postoperative values, and pain was evaluated using a visual analog scale (VAS) that ranged from 0 (no pain) and 10 (very severe pain). Clinical appearance was scored according to the color, presence of edema and bleeding of soft tissue (0, normally pink, not edematous; 1, pink-red, slightly edematous; 2, red, edematous; and 3, red, extremely edematous, easily bleed).^[18] Infection and neurological injury were also examined for each patient.

The following clinical parameters were measured on the mid-buccal aspect of teeth with gingival recession (GM) measuring $\geq 2\text{mm}$ at baseline, 6 and 12 months after surgery: gingival recession depth (GRD): the distance from the CEJ to the gingival margin. The mean percentage of root coverage was calculated as follows: $\% \text{root coverage} = 100 \times (\text{baseline recession} - \text{postoperative recession}) /$

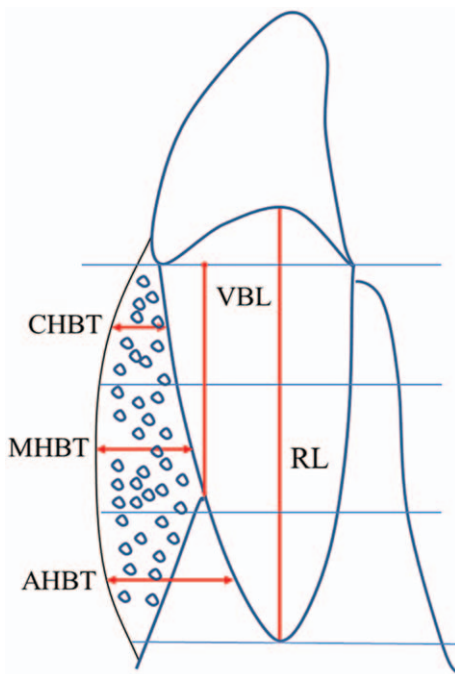


Figure 3. Schematic diagram of radiographic assessments. VBL, buccal vertical bone level, that is, distance between the labial aspect of the CEJ and the most coronal level of the alveolar bone at the labial cortical surface; CHBT, MHBT, and AHBT, buccal horizontal bone thickness at the middle level of the coronal, middle and apical thirds. AHBT=horizontal bone thickness at the middle level of the apical third, BL=baseline, CHBT=horizontal bone thickness at the middle level of the coronal third, MHBT=horizontal bone thickness at the middle level of the middle third, VBL=vertical alveolar bone level.

Table 1
Postoperative symptoms over time.

	1 week	2 weeks	P*
Trismus, mm	2.89 (1.36)	2.67 (1.41)	.608
Swelling, mm	8.89 (3.70)	5.56 (3.50)	.006
VAS for pain	4.11 (1.27)	2.44 (0.77)	.007
Clinical appearance	2.33 (0.71)	1.33 (0.50)	.030

Note: Data are presented as mean (standard deviation).
VAS=visual analog scale, VBL=vertical alveolar bone level.
* Wilcoxon nonparametric test.

baseline recession; probing depth (PD): the distance from the GM to the bottom of the gingival sulcus; clinical attachment level (CAL): the distance from the CEJ to the bottom of the sulcus.

2.4.2. Radiographic measurements. To collect the CBCT data, each patient was scanned using a commercially available CBCT scanner (VG; NewTom, Verona, Italy) before operation and at 1 week and 12 months after surgery. The patient’s head was oriented by locating the Frankfort plane parallel to the horizontal plane and in centric occlusion. The scanning parameters for imaging were 110kV, 0 to 20mA, exposure time of 5.4seconds, and a 12-in field of view. These settings produced a voxel size of 0.125 mm.

CBCT images were reconstituted using image software (Dolphin 11.7, Chatsworth, CA) for biometric measurements on sagittal section images. The 3D reconstruction and registration of longitudinal scans taken at different time points was performed using Mimics 18.0 software (Materialise, Leuven, Belgium). The definitions of all measurements and reference points used in this study are presented as the method we have reported.^[19] Vertical alveolar bone level (VBL) of the lower anterior teeth was performed by measuring the distance between the coronal crest and the CEJ at the labial surface, parallel to the long axis of the tooth. Horizontal bone thickness were made from the midpoint of the coronal third (CHBT), middle third (MHBT), and apical third (AHBT) to the limit of the labial cortical surface, respectively, perpendicular to the long axis of the tooth (Fig. 3).

2.5. Statistical analysis

All analyses were performed with statistical software package (SPSS, version 17.0, Chicago, IL). Postoperative symptoms (1 week vs 2 weeks) were compared using the nonparametric Wilcoxon test. A Friedman test was used for comparisons among the 3 time points (baseline, 6 and 12 months for periodontal parameters and baseline, 1 week and 12 months for radiographic parameters), followed by the LSD multiple-comparison post hoc test (when significant differences were found). All statistical hypothesis tests were 2 sided, with probability of type I error of 0.05.

3. Results

Around 12 adult patients (2 males, 10 females) with 72 teeth were operated with the modified PAOO procedure. No patient lost to follow-up during the whole period of this study. The mean age was 21.9 years old, ranging from 18 to 28 years old.

3.1. Clinical evaluations

Table 1 shows no significant differences in the amount of trismus between the 1st and 2nd weeks after operation. Facial swelling was severe 1 week after surgery and began to resolve by the 2nd

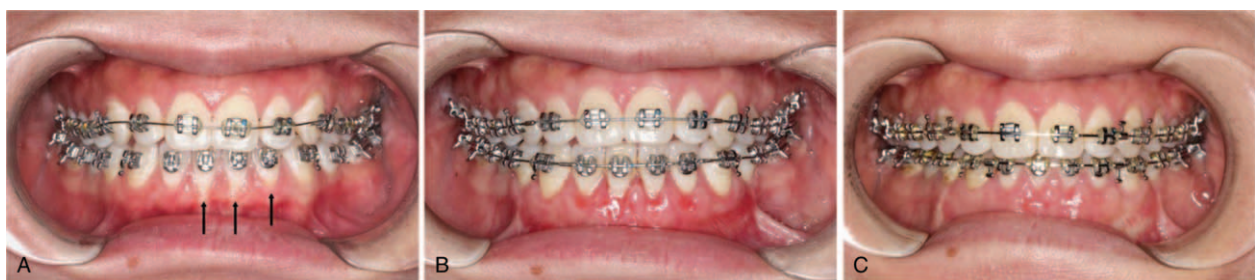

Figure 4. Buccal gingival recession in the lower alveolar region at baseline as black arrows shown (A) and effective root coverage during 6-month (B) and 12-month follow ups (C), respectively.

Table 2
Periodontal parameters over time (mm).

	BL	6m	12m	P*	Multiple comparison†		
					BL-6m	6m-12m	BL-12m
PD	0.77 (0.61–0.93)	0.73 (0.57–0.89)	0.81 (0.66–0.96)	.589			
GRD	2.88 (2.54–3.21)	0.79 (0.63–0.95)	0.87 (0.69–1.05)	.000	0.000	1	0.000
CAL	3.65 (3.26–4.03)	2.91 (2.68–3.14)	2.80 (2.58–3.02)	.006	0.002	1	0.003

Note: Data are presented as mean (95% CI)

12m=12 months after surgery, 6m=6 months after surgery, BL=baseline, PD=probing depth, CAL=clinical attachment level, GRD=gingival recession depth.

*Friedman test.

†LSD multiple-comparison post hoc test.

Table 3
Radiographic parameters over time (mm).

	BL	1 w	12m	P*	Multiple comparisons†		
					BL-1w	1w-12m	BL-12m
VBL	5.48 (4.70–6.26)	0.86 (0.67–1.05)	1.27 (1.12–1.41)	.000	0.000	0.001	0.000
CHBT	0.24 (0.14–0.34)	1.35 (1.22–1.48)	0.96 (0.85–1.07)	.000	0.000	0.000	0.001
MHBT	0.08 (0.01–0.14)	2.94 (2.71–3.18)	2.50 (2.27–2.74)	.000	0.000	0.001	0.000
AHBT	1.63 (1.42–1.83)	3.96 (3.63–4.28)	3.40 (3.10–3.70)	.000	0.000	0.000	0.000
Root length	11.04 (10.62–11.46)	10.94 (10.53–11.34)	10.81 (10.39–11.23)	.784			

Note: Data are presented as mean (95% CI).

12m=12 months after surgery, 1w=1 week after surgery, AHBT=horizontal bone thickness at the middle level of the apical third, BL=baseline, CHBT=horizontal bone thickness at the middle level of the coronal third, MHBT=horizontal bone thickness at the middle level of the middle third, PAOO=periodontally accelerated osteogenic orthodontics, PD=probing depth, VBL=vertical alveolar bone level

*Friedman test.

†LSD multiple-comparison post hoc test.

week postoperatively with significant difference ($P < .01$). With respect to pain values, we noted a significant reduction from the 1st week to the 2nd week after surgery ($P < .01$). Clinical appearance presented a similar pattern of behavior, showing a significant improvement between the 2 follow-up visits ($P < .01$). No patient exhibited any infectious consequences. Two cases fully recovered from temporary paresthesia within 4 weeks.

No soft tissue dehiscence or fenestration occurred associated with improved esthetics of soft tissue contour. A total of 17 sites with gingival recession ranging from 2 to 4 mm were performed. As compared with the baseline, there was a significant reduction in the mean GRD (Fig. 4) and an increase in the mean CAL after surgery ($P < .01$). PD did not change over time ($P > .05$). At the end of the observation period, GRD decreased by 2.01 mm,

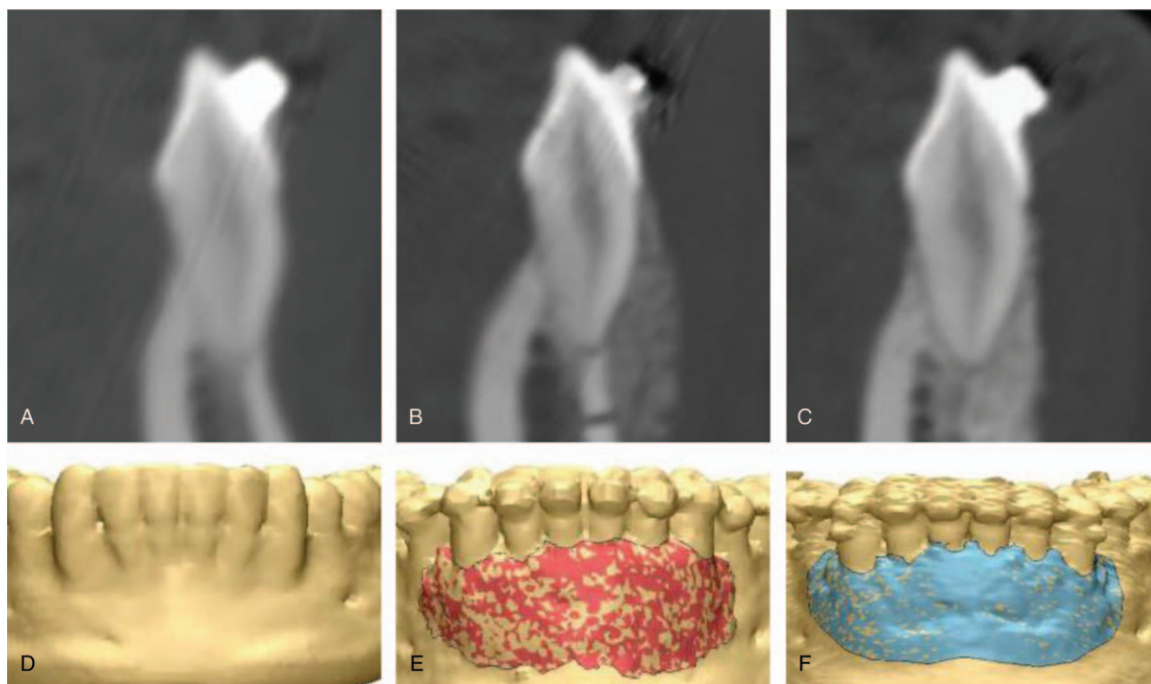


Figure 5. Cone-beam computed tomography images and image-based 3-dimensional reconstruction. Bone defect on the labial cortical bone at baseline (A, D) and increased alveolar volume during 6-month (B, E) and 12-month follow ups (C, F), respectively.

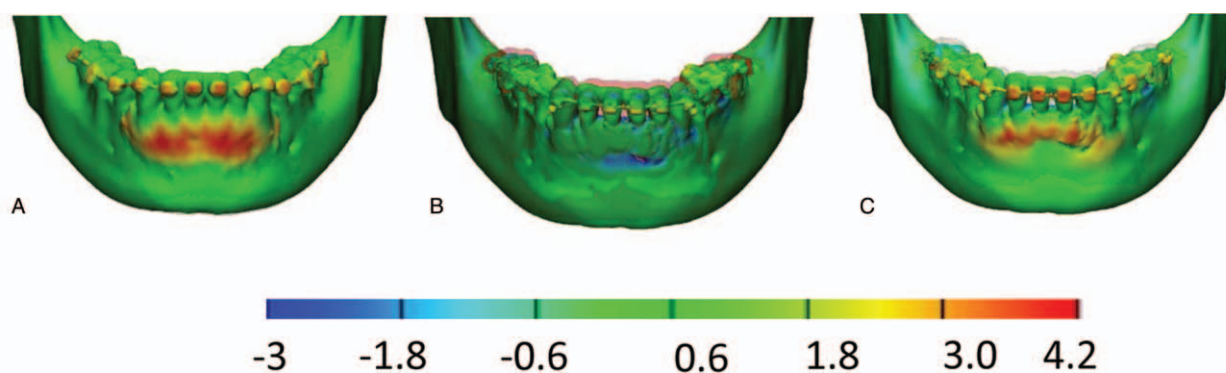


Figure 6. Longitudinal registration of the lower anterior alveolar region of a patient treated with modified PAOO. Closest point surface distances colour-coded maps showing obvious alveolar augmentation 1 week after surgery and marked resorption after 12-month follow-up. (A) 1 week postsurgery vs baseline; (B) 12 months vs 1 week after surgery; (C) 12 months postsurgery vs baseline. PAOO=periodontally accelerated osteogenic orthodontics.

representing mean root coverage of 69.8%; a CAL gain of 0.85 mm was measured (Table 2). However, these differences were not significant during the follow-ups.

3.2. Radiographic evaluations

The biometric measurements calculated at each different time point were reported in Table 3. The mean VBL on the labial side of anterior teeth was 5.48 mm at baseline, 0.86 mm and 1.27 mm at 1-week and 12-months after surgery, respectively. The mean amount of vertical bone significantly increased immediately after this PAOO procedure and then significantly reduced ($P < .001$). However, if we consider the bone level before treatment as the baseline, statistically significant vertical augmentation was also found at the end of the observation period ($P < .001$). Similar results were detected for CHBT, MHBT and AHBT measurements and significant differences were found at each follow-up visit ($P < .001$). These statistically significant results showed modified regenerative procedure could help in enlargement of the alveolar crest and prevent any bony dehiscence, as well as the horizontal bone thickness (Fig. 5). Figure 6 illustrates the results of the longitudinal registration for one of the patients treated with this modified PAOO technique, where marked changes in the grafting area were found between 3 time points. Root length did not present any statistically significant difference at each follow up.

4. Discussion

Though resorbable membrane has been widely used in the conventional PAOO to increase the stability of the graft material and the resulting bone volume, it is still a great challenge for sufficient ridge augmentation.^[20–22] This would be usually associated with its limited ability in space maintenance at the desired site to prevent the bone graft material from slumping during healing. The skeletal anchorage device membrane barrier was allowed to be formed into an adequate shape and maintain the primary augmented bone morphology, which was reported in the original PAOO technique.^[14] However, the need for an additional surgical procedure and the risk of infection were the 2 main clinical disadvantages with this nonresorbable membrane.^[23,24]

Coscia et al^[17] reported that traditional PAOO increased the horizontal ridge thickness at the midroot and apex level of lower

anterior teeth, with no statistical vertical alveolar bone change. Similar to the results by Wang et al,^[16] the apical level had a larger amount of alveolus augmentation compared with the coronal level. The most possible reason that may be associated with the traditional procedures involved. It is difficult to prevent particulate bones substitutes from displacement and leakage. Additionally, flap was fixed with soft tissue tension at the incision site would press bone graft material around the coronal alveolar crest, leading vertical alveolar bone loss. To overcome these drawbacks, a pouch design was applied allowing filling of bone-grafting material while facilitating primary tension-free soft tissue closure by the periosteal releasing incision. This protocol included the elevation of a periosteal layer apically from a releasing incision followed by suturing the collagen membrane and a periosteal membrane together at the bottom and on both sides. Thus, the flap gives stability to the augmented volume within the pouch. Compared with the previously published literatures, this approach with tension-free flap closure design has the ability of correcting vertically deficient alveolar ridges and maintaining the vertical bone gain over time from radiographic results.

As dehiscences were seen with a greater frequency in the mandibular incisors, bone augmentation in the coronal portion might be considered essential.^[25,26] In our previous study, a bone grafting material fixed with the periosteum was introduced as an alternative PAOO^[19] to increase the vertical bone level of 3.63 mm on average in 6-months observation. The dissected periosteum was used to cover the grafting material in a dumpling-like fashion, which could also protect the grafting material from displacement. However, it seems that the vertical augmentation may be yield to the coronal attachment level of periosteum from clinical observations. In addition, the technique of bone grafting with the periosteum coverage and fixation increased surgery complexity and required a high level of skills. This modified PAOO with a pouch design could provide a better view for corticotomy and graft procedure with less time consuming. Moreover, the vertical bone gain could reach about 4.2 mm at 12-month observation. Further comparison of these 2 techniques will be reported in subsequent articles.

In the current approach, postoperative symptoms were greatly alleviated with time. Clinical evidences showed safety of this technique for bone regeneration procedures. Chen et al^[27] reported that more wound dehiscence would be expected in dental implant surgery owing to lack of the tensile strength of the

soft tissue flap. However, no one suffered wound dehiscence in the presented tension free closure procedure and no graft contamination occurred. This study is unlike the previous studies reporting the negative influence of collagen membrane exposures.^[28,29] It was reported that the inflammatory reaction may be observed with membrane exposure.^[23,30] Machtei^[31] investigated the effect of membrane exposure on the regenerative outcome in the regeneration of intrabony defects by meta-analysis and found the mean gain of vertical attachment was 4.22 mm for the exposed group and 4.69 mm for the submerged group. These differences were also statistically significant.

More favorable results, 12-month postoperative observations suggest that root coverage following this approach in GRD amounts to 69.8% and remains stable over time. This is higher than those reported by Shieh et al,^[32] who found the root averaged 51.6% and the predictable amounts of CAL gain at 6-month postoperatively using a bioresorbable membrane for treating periodontal recession. Though mucogingival surgeries such as the connective tissue graft or the advanced flap procedure has been widely used for treating recession defects, histologic studies showed a long junctional epithelium between the root surface and the covering tissues and only limited amounts of new connective tissue attachment in the apical aspect of the covered root surface.^[33] In a human biopsy, Vincenzi et al^[34] histologically revealed the newly formed tissue was composed of a coronal area of connective tissue attachment and an apical area of bone fibers and cementum in gingival recession-type defects using a resorbable membrane. Fibroblasts as well as bone-forming cells are able to attach to, proliferate on and migrate over collagen membranes,^[35] which would help to achieve better functional periodontal regeneration. This modified technique could be a good therapeutic option in the treatment of buccal recession defects without adverse clinical effect under conditions of membrane exposures.

Although this study revealed favorable results in 1-year evaluation, the conclusion was not adequate for potential referral bias. A prospective randomized controlled trial is still being undertaken to compare the effects of this modified and conventional PAOO techniques (Registry Number: ChiCTR- INR-17012749). Moreover, the long-term outcome of augmented bone and the optimal amount of bone required for stable results remains unknown today. Only human histology can determine the real nature of the newly formed tissue interface. Based on these results, we will expand the data pool with histologic analysis and prolong the observation time in the upcoming research.

5. Conclusions

The pouch design in ridge augmentation for corticotomy-assisted surgical orthodontics has the advantages in terms of soft and hard tissue augmentation, allowing the correction of the vertical and horizontal defects simultaneously. Given the widespread incidence of dehiscences in the lower anterior alveolar region, this modified surgical technique may be valuable in case of a combination of vertical and horizontal defects by bone grafting with collagen membranes fixed to the surrounding periosteum in a pouch design and tension-free wound closure for PAOO.

Author contributions

Conceptualization: Chi Yang, Zhigui Ma.

Data curation: Chi Yang, Zhigui Ma, Xiaohan Liu.

Formal analysis: Jisi Zheng.

Methodology: Chi Yang, Zhigui Ma, Jisi Zheng, Qianyang Xie.

Project administration: Zhigui Ma.

Software: Qianyang Xie, Ahmed Abdelrehem.

Supervision: Chi Yang.

Validation: Chi Yang.

Writing – original draft: Zhigui Ma, Jisi Zheng.

Writing – review & editing: Ahmed Abdelrehem.

References

- Handelman CS. The anterior alveolus: its importance in limiting orthodontic treatment and its influence on the occurrence of iatrogenic sequelae. *Angle Orthod* 1996;66:95–109. discussion 109–110.
- Evangelista K, Vasconcelos Kde F, Bumann A, et al. Dehiscence and fenestration in patients with Class I and Class II Division 1 malocclusion assessed with cone-beam computed tomography. *Am J Orthod Dentofacial Orthop* 2010;138:133.e131–7.e131. discussion 133–135.
- Koke U, Sander C, Heinecke A, et al. A possible influence of gingival dimensions on attachment loss and gingival recession following placement of artificial crowns. *Int J Periodontics Restorative Dent* 2003;23:439–45.
- Leung CC, Palomo L, Griffith R, et al. Accuracy and reliability of cone-beam computed tomography for measuring alveolar bone height and detecting bony dehiscences and fenestrations. *Am J Orthod Dentofacial Orthop* 2010;137(4 suppl):S109–19.
- Thilander BL. Complications of orthodontic treatment. *Curr Opin Dent* 1992;2:28–37.
- Fuhrmann R. Three-dimensional interpretation of alveolar bone dehiscences. An anatomical-radiological study—Part I. *J Orofac Orthop* 1996;57:62–74.
- Wehrbein H, Bauer W, Diedrich P. Mandibular incisors, alveolar bone, and symphysis after orthodontic treatment. A retrospective study. *Am J Orthod Dentofacial Orthop* 1996;110:239–46.
- Artun J, Urbye KS. The effect of orthodontic treatment on periodontal bone support in patients with advanced loss of marginal periodontium. *Am J Orthod Dentofacial Orthop* 1988;93:143–8.
- Wilcko WM, Wilcko T, Bouquot JE, et al. Rapid orthodontics with alveolar reshaping: two case reports of decrowding. *Int J Periodontics Restorative Dent* 2001;21:9–19.
- Murphy KG, Wilcko MT, Wilcko WM, et al. Periodontal accelerated osteogenic orthodontics: a description of the surgical technique. *J Oral Maxillofac Surg* 2009;67:2160–6.
- Amit G, Jps K, Pankaj B, et al. Periodontally accelerated osteogenic orthodontics (PAOO)—a review. *J Clin Exp Dent* 2012;4:e292–6.
- Nowzari H, Yorita FK, Chang HC. Periodontally accelerated osteogenic orthodontics combined with autogenous bone grafting. *Compend Contin Educ Dent* 2008;29:200–6. quiz 207, 218.
- Ahn HW, Lee DY, Park YG, et al. Accelerated decompensation of mandibular incisors in surgical skeletal class III patients by using augmented corticotomy: a preliminary study. *Am J Orthod Dentofacial Orthop* 2012;142:199–206.
- Kim SH, Kim I, Jeong DM, et al. Corticotomy-assisted decompensation for augmentation of the mandibular anterior ridge. *Am J Orthod Dentofacial Orthop* 2011;140:720–31.
- Wilcko MT, Wilcko WM, Pulver JJ, et al. Accelerated osteogenic orthodontics technique: a 1-stage surgically facilitated rapid orthodontic technique with alveolar augmentation. *J Oral Maxillofac Surg* 2009;67: 2149–59.
- Wang B, Shen G, Fang B, et al. Augmented corticotomy-assisted surgical orthodontics decompensates lower incisors in Class III malocclusion patients. *J Oral Maxillofac Surg* 2014;72:596–602.
- Coscia G, Coscia V, Peluso V, et al. Augmented corticotomy combined with accelerated orthodontic forces in class III orthognathic patients: morphologic aspects of the mandibular anterior ridge with cone-beam computed tomography. *J Oral Maxillofac Surg* 2013;71:1760.e1761–9.
- Sivolella S, Berengo M, Bressan E, et al. Osteotomy for lower third molar germectomy: randomized prospective crossover clinical study comparing piezosurgery and conventional rotatory osteotomy. *J Oral Maxillofac Surg* 2011;69:e15–23.
- Ma ZG, Yang C, Xi QY, et al. A novel surgical technique for augmented corticotomy-assisted orthodontics: bone grafting with periosteum. *J Oral Maxillofac Surg* 2016;74:170–80.
- Friedmann A, Gissel K, Soudan M, et al. Randomized controlled trial on lateral augmentation using two collagen membranes: morphometric results on mineralized tissue compound. *J Clin Periodontol* 2011;38: 677–85.

- [21] Oh TJ, Meraw SJ, Lee EJ, et al. Comparative analysis of collagen membranes for the treatment of implant dehiscence defects. *Clin Oral Implants Res* 2003;14:80–90.
- [22] Owens KW, Yukna RA. Collagen membrane resorption in dogs: a comparative study. *Implant Dent* 2001;10:49–58.
- [23] Naenni N, Schneider D, Jung RE, et al. Randomized clinical study assessing two membranes for guided bone regeneration of peri-implant bone defects: clinical and histological outcomes at 6 months. *Clin Oral Implants Res* 2016;28:1309–17.
- [24] Becker W, Dahlin C, Becker BE, et al. The use of e-PTFE barrier membranes for bone promotion around titanium implants placed into extraction sockets: a prospective multicenter study. *Int J Oral Maxillofac Implants* 1994;9:31–40.
- [25] Yagci A, Veli I, Uysal T, et al. Dehiscence and fenestration in skeletal Class I, II, and III malocclusions assessed with cone-beam computed tomography. *Angle Orthod* 2012;82:67–74.
- [26] Enhos S, Uysal T, Yagci A, et al. Dehiscence and fenestration in patients with different vertical growth patterns assessed with cone-beam computed tomography. *Angle Orthod* 2012;82:868–74.
- [27] Chen ST, Wilson TGJr, Hammerle CH. Immediate or early placement of implants following tooth extraction: review of biologic basis, clinical procedures, and outcomes. *Int J Oral Maxillofac Implants* 2004;19:12–25.
- [28] Wessing B, Lettner S, Zechner W. Guided bone regeneration with collagen membranes and particulate graft materials: a systematic review and meta-analysis. *Int J Oral Maxillofac Implants* 2017;33:87–100.
- [29] Becker J, Al-Nawas B, Klein MO, et al. Use of a new cross-linked collagen membrane for the treatment of dehiscence-type defects at titanium implants: a prospective, randomized-controlled double-blinded clinical multicenter study. *Clin Oral Implants Res* 2009;20:742–9.
- [30] Schneider D, Weber FE, Grunder U, et al. A randomized controlled clinical multicenter trial comparing the clinical and histological performance of a new, modified polylactide-co-glycolide acid membrane to an expanded polytetrafluorethylene membrane in guided bone regeneration procedures. *Clin Oral Implants Res* 2014;25:150–8.
- [31] Machtei EE. The effect of membrane exposure on the outcome of regenerative procedures in humans: a meta-analysis. *J Periodontol* 2001;72:512–6.
- [32] Shieh AT, Wang HL, O'Neal R, et al. Development and clinical evaluation of a root coverage procedure using a collagen barrier membrane. *J Periodontol* 1997;68:770–8.
- [33] Cortellini P, Clauser C, Prato GP. Histologic assessment of new attachment following the treatment of a human buccal recession by means of a guided tissue regeneration procedure. *J Periodontol* 1993;64:387–91.
- [34] Vincenzi G, De Chiesa A, Trisi P. Guided tissue regeneration using a resorbable membrane in gingival recession-type defects: a histologic case report in humans. *Int J Periodontics Restorative Dent* 1998;18:24–33.
- [35] Behring J, Junker R, Walboomers XF, et al. Toward guided tissue and bone regeneration: morphology, attachment, proliferation, and migration of cells cultured on collagen barrier membranes. A systematic review. *Odontology* 2008;96:1–1.