



Contents lists available at ScienceDirect

International Journal of Surgery Case Reports

journal homepage: www.casereports.com

Treatment of lumbar discitis using silicon nitride spinal spacers: A case series and literature review

William M. Rambo Jr.

Midlands Orthopaedics & Neurosurgery, 1910 Blanding St, Columbia, SC 29201, USA

ARTICLE INFO

Article history:

Received 17 January 2018

Accepted 7 February 2018

Available online 10 February 2018

Keywords:

Silicon nitride

Discitis

Lumbar discectomy and fusion

Antibacterial

ABSTRACT

INTRODUCTION: Septic infection of a lumbar intervertebral disc is a serious disorder which is often difficult to diagnose and appropriately treat because of the rarity of the disease, the varied presentation of symptoms, and the frequency of low-back pain within the overall population. Its etiology can be pyogenic, granulomatous, fungal, or parasitic; its incidence is rising due to increased patient susceptibility and improved diagnostic tools. Conservative treatments involve antibiotics, physical therapy, and/or immobilization. More aggressive management requires discectomy, debridement, and spinal fusion in combination with local and systemic antibiotic administration.

PRESENTATION OF CASES: Presented here are two case studies of lumbar pyogenic discitis associated with *Escherichia coli* and *Candida albicans* infections. Both required single-level anterior discectomy followed by spinal fusion using an antimicrobial silicon nitride (Si_3N_4) spacer for stabilization without instrumentation. Localized antibiotics were used for only one of the patients. Follow-up CT and MRI scans showed that the infections had been resolved with no recurrence of symptoms.

DISCUSSION: Si_3N_4 is a relatively new spinal spacer material. It was utilized in these two cases because it reportedly provides a local environment which promotes rapid arthrodesis while resisting bacterial adhesion and biofilm formation. It is also highly compatible with X-ray, MRI, and CT imaging modalities. These properties were particularly attractive for these two cases given the patients' histories, presentation of symptoms, and the decision to forego instrumentation.

CONCLUSION: The use of Si_3N_4 as an antimicrobial spacer may lead to improved outcomes for patients with pyogenic discitis of the lumbar spine.

© 2018 The Author(s). Published by Elsevier Ltd on behalf of IJS Publishing Group Ltd. This is an open access article under the CC BY-NC-ND license (<http://creativecommons.org/licenses/by-nc-nd/4.0/>).

1. Introduction

Infections of the spine are persistent global problems [1]. Historically, they were predominantly associated with tuberculosis (Pott's disease), and this pathology remains a common cause in today's world [2]. However, their overall etiological roots can either be bacterial, mycobacterial, fungal, or parasitic. The incidence of spine infections has been steadily increasing in developed countries and ranges up to 6.5 cases per 100,000 [3,4]. It currently accounts for $\approx 5\%$ of all bone lesions in people over 50 years of age [3]. Spinal infections can be classified as osteomyelitis, facet joint septic arthritis, epidural bacterial abscesses, and septic discitis or spondylodiscitis [5]. Most arise from a remote haematogenous source with *Staphylococcus aureus* being the dominant pathogen accounting for over 28% of reported cases or about half of non-tuberculous causes [4]. An increasing number of these cases are, in fact, due to methicillin-resistant *Staphylococcus aureus* (MRSA), particularly in the elderly. Nevertheless, there are a number of both gram-positive and gram-negative bacteria that have been found

as infection sources. These pathogens can also infect the spine by external inoculation or from contiguous tissues (*i.e.*, vascular catheters, epidural injections, previous surgical interventions, diabetic wounds, and bed pressure sores, *etc.*) [3]. Fungal infections are less common and are generally associated with compromised immune systems due to neutropenia, granulomatous disease, and chronic steroid or drug use. *Candida albicans* reportedly is the source for 1–2% of all discitis cases [6].

The diagnosis of spinal infections is problematic because its presentation can be varied. Often, there are long incubation periods prior to the onset of significant symptoms. Back pain is common, but it may range from mild to severe, sometimes worsening with the supine position [2]. Most symptoms are similar to common degenerative spinal disorders such as disc herniation, stenosis, and spondylolisthesis. Chest, abdominal, or radiating pain in the extremities are not unusual which may further complicate or delay a correct diagnosis. The presence of febrile symptoms is an indicator of a contagion; however fevers are only present in about half of the reported cases [6]. The infection is rarely polymicrobial so blood cultures and a microbiological analysis for the causative pathogen are essential diagnostic tools. Routine radiographs are ineffective in early detection of the disease because it takes up to 6 weeks for

E-mail address: William.Rambo@midorthoneuro.com

<https://doi.org/10.1016/j.ijscr.2018.02.009>

2210-2612/© 2018 The Author(s). Published by Elsevier Ltd on behalf of IJS Publishing Group Ltd. This is an open access article under the CC BY-NC-ND license (<http://creativecommons.org/licenses/by-nc-nd/4.0/>).

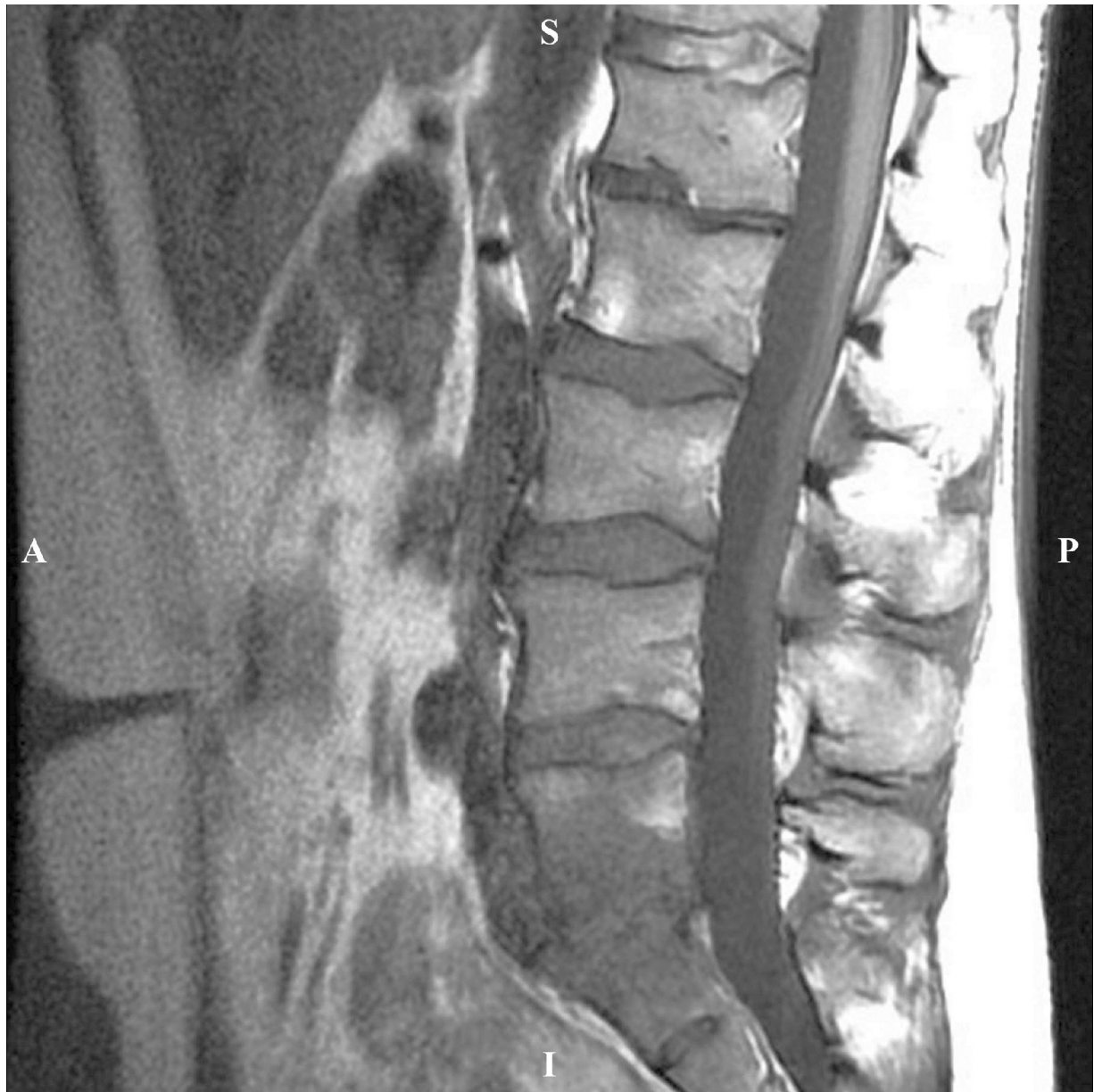

Fig. 1. Case 1: Non-contrasted pre-op MRI showed marked disc degeneration and adjacent vertebral body inflammation at L5-S1, consistent with discitis.

significant abscesses to form [3]. Conversely, magnetic resonance imaging (MRI) is the preferred modality for early radiological diagnosis [2]. It is the most sensitive (93–96%) and specific (92.5–97%) secondary imaging method for detection of discitis [4]. Without an appropriate MRI diagnosis and subsequent treatments, serious complications can ensue including vertebral abscess, osteomyelitis, meningitis, disabling deformities, neurological defects, and death [7].

While the optimal treatment remains unsettled [4], typical conservative management includes extended parenteral and antibiotic therapy – 6 weeks is sufficient in most cases [3] – coupled with orthotic immobilization if minor spinal instability is observed, or limited physical therapy if it is indicated [2]. Surgical intervention is required where there is significant pyogenic damage of osseous tissues, epidural abscess, severe spinal instability, kyphosis, or where conservative management has failed [2].

This paper reports on the successful outcomes of two patients with lumbar spinal infections, both of whom underwent single-level anterior discectomy, debridement, and arthrodesis using

a silicon nitride (Si_3N_4) spinal spacer. Successful resolution of the sepsis, arthrodesis without instrumentation, and significant improvements in their clinical status were achieved in both cases. Pre- and post-operative MRIs and/or CT images were found to be essential in the diagnosis and recovery monitoring of their respective conditions. Furthermore, the novelty of these cases relates to the use of a ceramic interbody material that possesses both antibacterial and osteoconductive properties. The case series was retrospective in design on non-consecutive patients. All surgeries were performed at a single private practice center by the same surgeon (WMR), and the reported studies are in line with the PROCESS criteria [8].

2. Case history 1

A 56 year-old male developed acute severe lumbosacral pain one month after receiving antibiotic treatment for systemic *Escherichia coli* (*E. coli*) sepsis arising from a urinary tract infection. Both blood and urine cultures tested positive for *E. coli* prior to treatment.

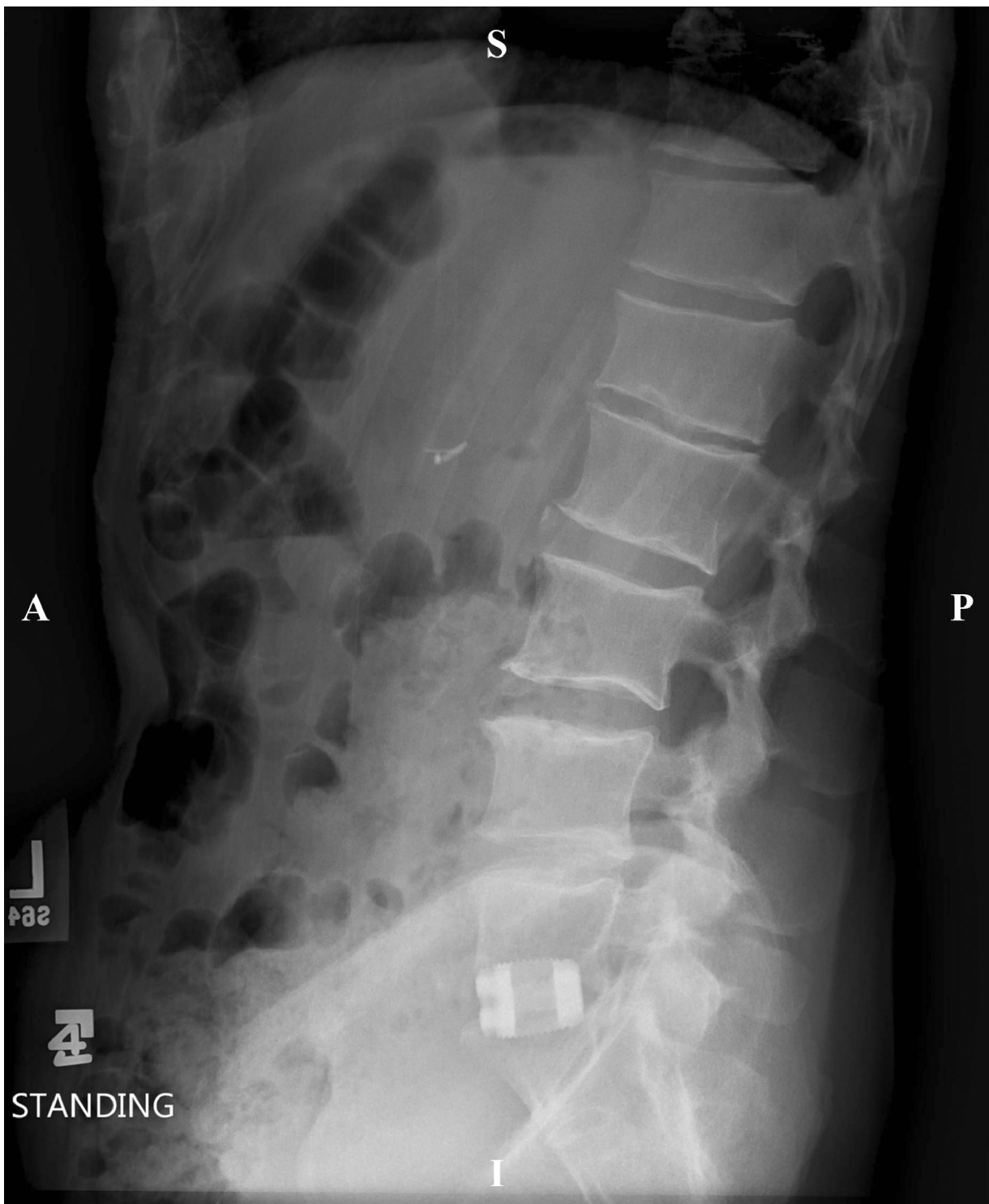

Fig. 2. Case 1: Seven-month post-operative lateral X-ray image showed stabilization of the fused segments obtained by the Si_3N_4 interbody spacer without instrumentation. Note the radiographic visibility of the implant on this view.

Plain X-rays were unremarkable, but an MRI scan showed discitis at L5-S1 without abscess formation (cf., Fig. 1). In addition to appropriate antibiotic therapy, the patient underwent anterior disc space debridement, with press-fit insertion of a silicon nitride spinal spacer (Valeo™-AL, 17 mm height 4° lordosis, Amedica Corporation, Salt Lake City, UT, USA). Morselized allograft was packed into the spacer lumen with one gram of vancomycin powder added to the graft material and placed directly in the disc space. While intra-

operative cultures were negative, the MRI and other intraoperative observations were consistent with disc space infection. Despite marginal bone quality in the adjacent vertebral bodies, the silicon nitride implant achieved stable mechanical fixation. No spinal instrumentation was utilized due to abnormally soft bone in the vertebral bodies adjacent to the infection. It was reasoned that posterior instrumentation could be added later if necessary, once the septic condition had been resolved. The patient was mobilized with

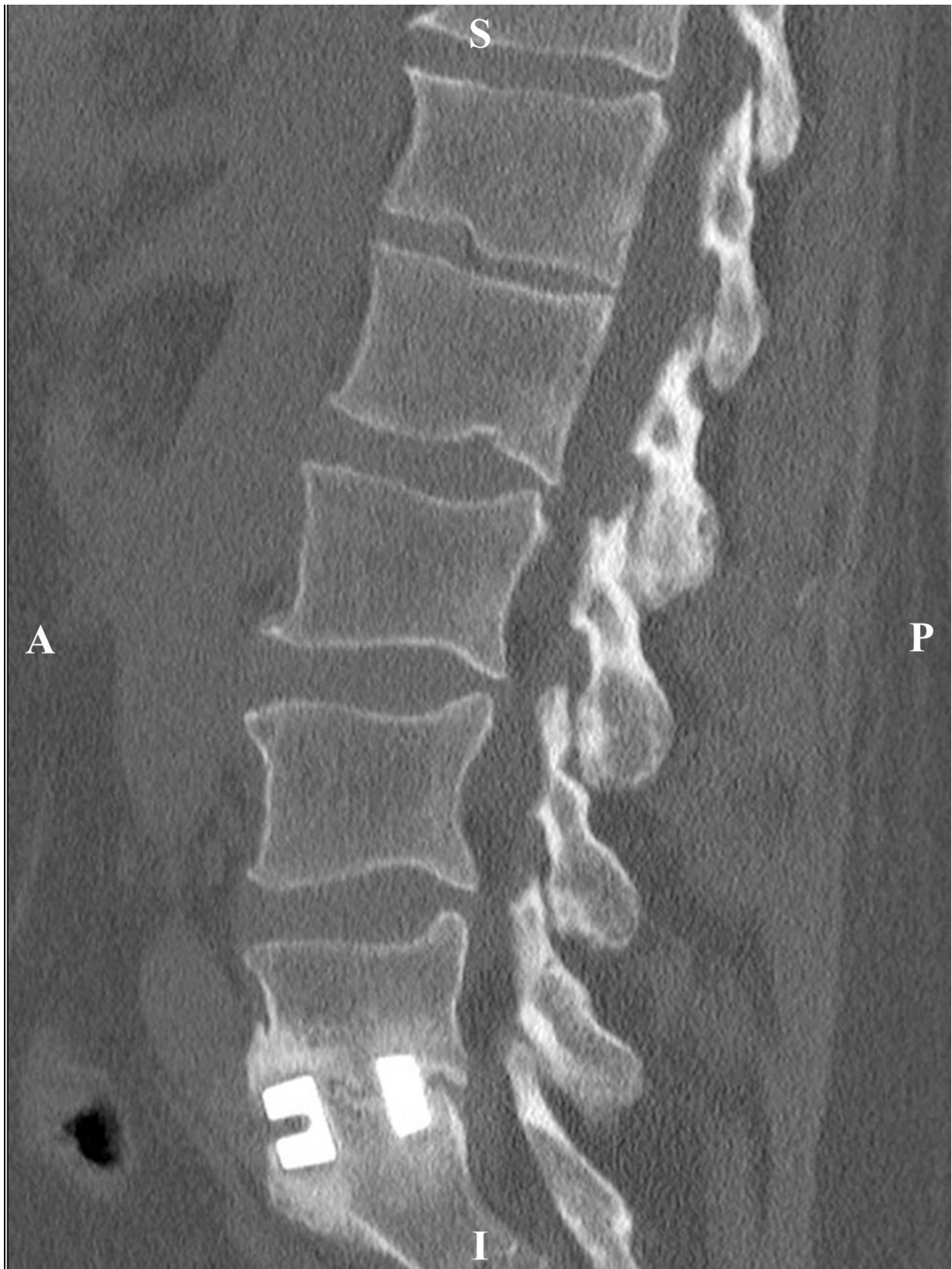

Fig. 3. Case 1: Contrasted nine-month post-op CT image showed successful fusion without migration of the Si_3N_4 interbody spacer.

a brace immediately after surgery and completed intravenous and oral antibiotic therapy at home. At five months after surgery, he had returned to work with relief of pain, and was also free of any analgesic medications. Lumbar X-rays were taken at seven months

after surgery when the patient presented with pain after a motor vehicle accident; these showed stable implant position (cf., Fig. 2). At the patient's final follow-up, nine months after surgery, he was pain-free and absent of any evidence of the recurrent infection. A

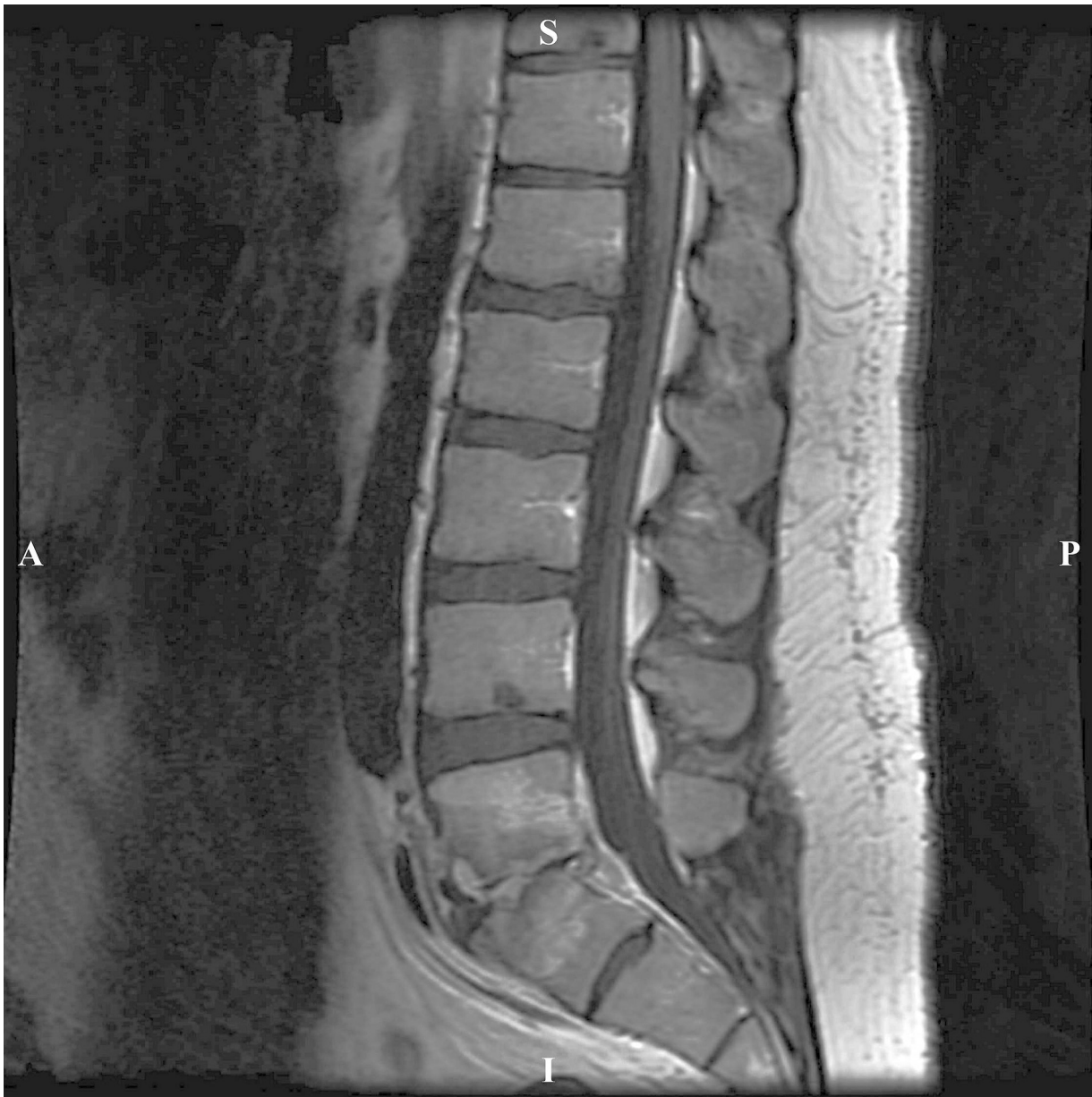

Fig. 4. Case 2: Contrasted pre-op MRI showed contrast enhancement within the L5-S1 disc space, with advanced disc space collapse and vertebral body edema, consistent with discitis.

CT scan evaluation confirmed successful interbody fusion without implant migration (cf., Fig. 3).

3. Case history 2

A 34 year-old male had acute worsening of chronic low back pain. The patient's history indicated intravenous drug abuse and prior partial discectomy at L5-S1 for rupture. An MRI scan confirmed lumbar spine discitis at L5-S1 (cf., Fig. 4). The offending pathogen was identified as *Candida albicans*. In addition to anti-fungal therapy, the patient underwent anterior debridement of the infected disc space with implantation of a silicon nitride spacer (Valeo™-AL spacer, 12 mm height, 12° lordosis). The spacer lumen was filled with morselized allograft without antibiotic powder. No spinal instrumentation was utilized because the patient had a low aortic bifurcation; it was difficult to mobilize tissues inflamed and scarred by the disc space infection. Mechanical stability of the spacer was achieved by a tight fit between adjacent vertebral

bodies. An orthotic brace was used during the patient's initial recovery period of eight weeks, at which time he returned to baseline functions with a resumption of analgesic therapy for chronic low back pain. Serial X-rays showed progressive incorporation of the interbody spacer as arthrodesis occurred. An additional follow-up occurred at 15 months post-operatively when the patient reported low-back pain after a fall. A contrast MRI scan at that time showed no evidence of the recurrent infection and successful arthrodesis without spacer subsidence (cf., Fig. 5).

4. Discussion

In the foregoing cases, follow-up X-ray, MRI, and CT scans of the spine were performed because of the unusual patient histories along with patient-specific variables that precluded the use of spinal instrumentation at the time of surgery. MRI and CT imaging provided improved visualization over X-ray radiography, particularly in diagnosing their conditions and assessing successful fusion

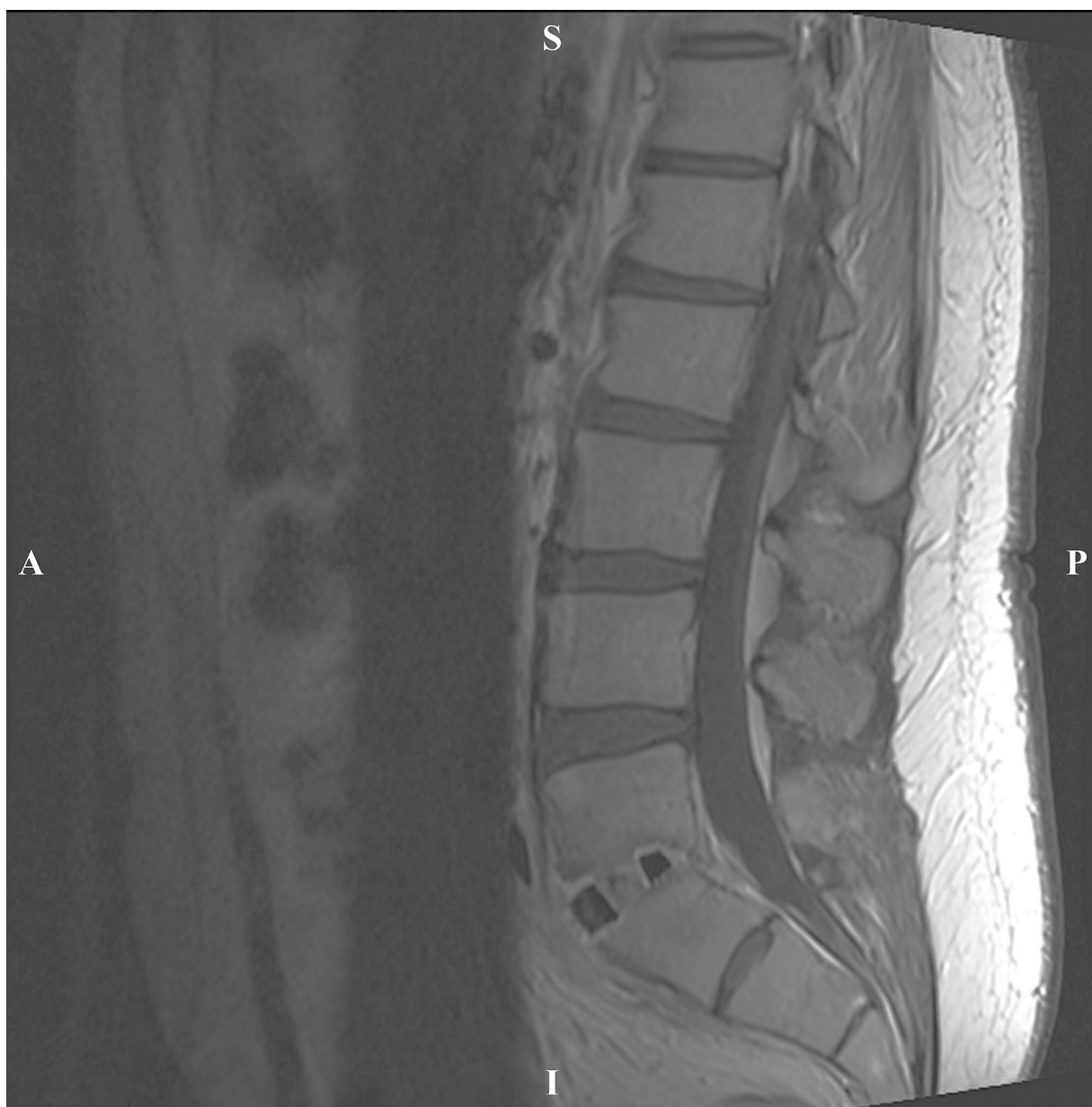


Fig. 5. Case 2: Contrasted MRI performed 15 months post-op showed good positioning of the Si_3N_4 interbody spacer, successful arthrodesis, and no recurrence of the infection.

across the affected lumbar segments [9]. Si_3N_4 spacers were chosen because of the surgeon's familiarity with these devices and because other investigators have reported that this material is inherently resistant to bacterial adhesion and biofilm formation [10–14]. In contrast to oxide ceramics (e.g., alumina and zirconia) that are extensively used as articulation materials in hip and knee replacements [15,16], Si_3N_4 is a non-oxide ceramic that was first used for lumbar fusion by Australian investigators. They reported successful arthrodesis outcomes after 15-years follow-up [17]. Subsequent studies have shown effective bone ingrowth into porous silicon nitride even without added autograft [18,19]. Spine spacers made from Si_3N_4 are commercially available in a variety of sizes and configurations; and their use in infectious discitis may be particularly attractive in light of previously published data that demonstrate the material's resistance to several bacterial species [10–14].

The enhanced fusion characteristics of Si_3N_4 spacers result from the material's surface chemistry. In its final form, the ceramic consists of ~90 vol.% polycrystalline Si_3N_4 grains intermixed with ~10 vol.% of a silicon-aluminum-yttrium-oxy-nitride intergranu-

lar glass (SiYAION). Aluminum oxide (Al_2O_3) and yttrium oxide (Y_2O_3) are utilized as sintering additives to aid densification of the ceramic. The presence of this glass phase has been found to promote osteoprogenitor cell differentiation and enhance osteoblastic activity *in vitro* [20–22]. This occurs because of the release of minute amounts of silicic acid ($\text{Si}(\text{OH})_4$) and ammonia (NH_3) into the local biological environment. While it is well-known that silicon in a bioavailable form (i.e., silicic acid) is essential and effective in bone remodeling and reformation [23–25], it was only recently shown that nitrogen may also play an important role in the rapid mineralization of reforming bone [22]. Using *in situ* Raman spectroscopy and *ex situ* laser microscopy, *in vitro* assays measuring bone formation have shown an increase of ~80% in hydroxyapatite formation in comparison to a biomedical titanium alloy [20]. Detailed analyses of human retrievals have also shown that Si_3N_4 surfaces promotes endocytotic uptake of bioavailable silicon and nitrogen resulting in enhanced appositional formation of ion-substituted hydroxyapatite at the implant's surface [22].

Both of the present case studies involved septic discitis. Yet, it is interesting to note that the second study was due to a fungal infection (*i.e.*, *Candida albicans*). While the effectiveness of Si₃N₄ against various fungal species is unknown, several recent reports suggest that its antimicrobial behavior may be the result of multivariate mechanisms [12–14]. For example, contact with polished Si₃N₄ surfaces resulted in the lysis of a gram-negative phylum, *Porphyromonas gingivalis* during a six-days of *in situ* exposure. The reported mechanism included the conversion of ammonia (NH₃) to peroxydinitrite (ONOO⁻), a powerful oxidative agent, which was able to permeate the bacteria's extracellular membranes. Once inside, it reduced lipid concentration, disrupted cellular functions, and damaged nucleic acids resulting in eventual death [12]. As another example, Ishikawa et al. utilized a murine model to show that the surface topography of Si₃N₄ played a role in resisting the adhesion of MRSA. In their study, the as-fired surfaces of Si₃N₄ consisted of protruding acicular needle-like grains that had nano-topographical features. This surface structure apparently prevented attachment of the gram-positive bacillus, which allowed the animal's immunological defenses to eventually clear it from the wound [14]. In a third study, Bock et al., examined multiple forms of Si₃N₄ in comparison to medical grades of polyetheretherketone (PEEK) and titanium using gram-positive *Staphylococcus epidermidis* and gram-negative *Escherichia coli*. All Si₃N₄ variants proved to be superior to PEEK and titanium in resisting bacterial adhesion and biofilm formation [13]. Their results suggested that the favorable antibacterial mechanisms of Si₃N₄ were indeed multivariate, and included submicron-topography, negative charging, chemical interactions, hydrophilicity, and protein adsorption. One or more of these mechanisms may have played important roles in the clearance of the pathogens in the two cited case studies.

In addition to enhanced bone ingrowth and bacterial resistance, the third property of Si₃N₄ that favored its use in the two case studies is its unique radiographic imaging ability. Because of its non-ferrous and non-magnetic nature, Si₃N₄ is visible and remains undistorted on X-rays, MRI, and CT [26]. In contrast, radiographic imaging of PEEK and metal implants is limited by radiolucency, or radiopacity and image scattering, respectively [27,28]. Si₃N₄ implants may be the preferred interbody material for confirming spine fusion and assessing adjacent soft tissues without artifacts or distortion.

5. Conclusion

The results provided in these two clinical case studies are obviously constrained because of their inherent observational nature. For example, since there were no control patients with alternative materials, the contributions of Si₃N₄ in resolving the infections and in supporting the observed clinical fusions cannot be comparatively validated. However, when viewed in light of the cited literature which attests to the unique advantages of Si₃N₄ spinal spacers, the results suggest that this material may be particularly suitable in the treatment of pyogenic infectious discitis. Further data are needed to corroborate these encouraging findings.

Conflicts of interest

The author declares no conflicts of interest in the publication of this case series.

Funding

This research did not receive any specific grant from funding agencies in the public, commercial, or not-for-profit sectors.

Ethical approval

As my institution's IRB policy states that studies of less than four subjects (my paper has two) are not considered Human Research, my submission is exempt from IRB and Ethics approval.

Consent

The medical treatments reported herein were consistent with the standard-of-care for these types of cases. They did not involve more than minimal risk to the patients and all patient information and data remain completely anonymous. Written informed consent was obtained from all of the patients for publication of this case series and accompanying images. Copies of their written consent are available for review by the Editor-in-Chief of this journal upon request.

Author contributions

The corresponding author is the sole contributor to this case series.

Guarantor

The corresponding author accepts full responsibility for this work.

Acknowledgement

Drs. B. Sonny Bal and Bryan J. McEntire of Amedica Corporation are gratefully acknowledged for helpful discussions and for their assistance in reviewing the draft manuscript.

References

- [1] L. Lopez-Duran Stern, C. Leon Serrano, Infections of the spine are still a great problem, *Int. Orthop.* 36 (2012) 217–219, <http://dx.doi.org/10.1007/s00264-012-1504-y>.
- [2] T. Gouliouris, S.H. Aliyu, N.M. Brown, Spondylodiscitis update on diagnosis and management, *J. Antimicrob. Chemother.* 65 (2010) 11–24, <http://dx.doi.org/10.1093/jac/dkq303>.
- [3] J.G. Consciência, R. Pinto, T. Saldanha, Infections of the spine, *Infect. Dis. Clin. North Am.* 31 (2017) 279–297, <http://dx.doi.org/10.1016/j.idc.2017.01.003>.
- [4] J.L. Cebrián Parra, A. Saez-Arenillas Martín, A.L. Urda Martínez-Aedo, I. Soler Ivañez, E. Agreda, L. Lopez-Duran Stern, Management of infectious discitis. Outcome in one hundred and eight patients in a university hospital, *Int. Orthop.* 36 (2012) 239–244, <http://dx.doi.org/10.1007/s00264-011-1445-x>.
- [5] S. Amadoru, K. Lim, M. Tacey, C. Aboltins, Spinal infections in older people: an analysis of demographics, presenting features, microbiology and outcomes, *Intern. Med. J.* 47 (2017) 182–188, <http://dx.doi.org/10.1111/imj.13300>.
- [6] M. Fantoni, E.M. Trecarichi, B. Rossi, V. Mazzotta, G. Di Giacomo, L.A. Nasto, E. Di Meco, E. Pola, Epidemiological and clinical features of pyogenic spondylodiscitis, *Eur. Rev. Med. Pharmacol. Sci.* 16 (2012) 2–7.
- [7] S. Koirala, S. Lamichhane, N. Kara, A case of acute discitis following spinal anesthesia: a rarity or a tip of the iceberg? *J. Soc. Anesthesiol. Nepal* 4 (2017) 4–7, <http://dx.doi.org/10.3126/jсан.v4i1.17478> (Corresponding).
- [8] R.A. Agha, A.J. Fowler, S. Rajmohan, I. Barai, D.P. Orgill, R. Afifi, R. Alahmadi, J. Albrecht, A. Alsawadi, J.K. Aronson, M. Hammad Ather, M. Bashashati, S. Basu, P. Bradley, M. Chalkoo, B. Challacombe, L. Derbyshire, N. Farooq, J. Hoffman, H. Kadioglu, V. Kasivisvanathan, B. Kirshtein, R. Klappenbach, D. Laskin, D. Miguel, J. Milburn, O. Muensterer, J. Ngu, I. Nixon, A. Noureldin, B. Perakath, N. Raison, K. Raveendran, T. Sullivan, A. Thoma, M.A. Thorat, A. Petroianu, A. Rao, M. Valmasoni, S. Massarut, A. D'cruz, B. Vasudevan, S. Giordano, D. Healy, D. Machado-Aranda, F.H. Millham, B. Carroll, I. Mukherjee, P. McCulloch, Y. Sugawara, D. Rosin, Preferred reporting of case series in surgery: the PROCESS guidelines, *Int. J. Surg.* 36 (2016) 319–323, <http://dx.doi.org/10.1016/j.ijsu.2016.10.025>.
- [9] N. Hopkinson, J. Stevenson, S. Benjamin, A case ascertainment study of septic discitis: clinical, microbiological and radiological features, *Mon. J. Assoc. Physicians* (1992) 465–470.
- [10] D.J. Gorth, S. Puckett, B. Ercan, T.J. Webster, M. Rahaman, B.S. Bal, Decreased bacteria activity on Si₃N₄ surfaces compared with PEEK or titanium, *Int. J. Nanomed.* 7 (2012) 4829–4840, <http://dx.doi.org/10.2147/IJN.S35190>.
- [11] T.J. Webster, A.A. Patel, M.N. Rahaman, B.S. Bal, Anti-infective and osteointegration properties of silicon nitride, poly (Ether ether ketone), and

- titanium implants, *Acta Biomater.* 8 (2012) 4447–4454 (<http://www.sciencedirect.com/science/article/pii/S1742706112003571>) (Accessed April 16, 2014).
- [12] G. Pezzotti, R.M. Bock, B.J. McEntire, E. Jones, M. Boffelli, W. Zhu, G. Baggio, F. Boschetto, L. Puppulin, T. Adachi, T. Yamamoto, N. Kanamura, Y. Marunaka, B.S. Bal, Silicon nitride bioceramics induce chemically driven Lysis in *Porphyromonas Gingivalis*, *Langmuir* 32 (2016) 3024–3035, <http://dx.doi.org/10.1021/acs.langmuir.6b00393>.
- [13] R.M. Bock, E.N. Jones, D.A. Ray, B.S. Bal, G. Pezzotti, B.J. McEntire, Bacteriostatic behavior of surface-modulated silicon nitride in comparison to polyethereetherketone and titanium, *J. Biomed. Mater. Res. Part A* 105 (2017) 1521–1534, <http://dx.doi.org/10.1002/jbm.a.35987>.
- [14] M. Ishikawa, Bentley K.L.D.M, B.J. McEntire, B.S. Bal, E.M. Schwarz, C. Xie, E. Avenue, Surface topography of silicon nitride affects antimicrobial and osseointegrative properties of tibial implants in a murine model, *J. Biomed. Mater. Res. A* 105 (2017) 3413–3421, <http://dx.doi.org/10.1002/jbm.a.36189>.
- [15] B.S. Bal, M.N. Rahaman, Orthopedic applications of silicon nitride ceramics, *Acta Biomater.* 8 (2012) 2889–2898, <http://dx.doi.org/10.1016/j.actbio.2012.04.031>.
- [16] N. Kumar, G.N.C. Arora, B. Datta, Bearing surfaces in hip replacement – evolution and likely future, *Med. J. Armed Forces India* 70 (2014) 371–376, <http://dx.doi.org/10.1016/j.mjafi.2014.04.015>.
- [17] P.H. Sorrell, R.K. Druitt, C.R. Howlett, E.R. McCartney, Results of 15-Year clinical study of reaction bonded silicon nitride intervertebral spacers, *Proc. 7th World Biomater. Conf. (2004)* 1872.
- [18] M.C. Anderson, R. Olsen, Bone ingrowth into porous silicon nitride, *J. Biomed. Mater. Res.* 92A (2010) 1598–1605, <http://dx.doi.org/10.1002/jbm.a.32498>.
- [19] M.P. Arts, J.F.C. Wolfs, T.P. Corbin, Porous silicon nitride spacers versus PEEK cages for anterior cervical discectomy and fusion: clinical and radiological results of a single-blinded randomized controlled trial, *Eur. Spine J.* (2017) 1–8, <http://dx.doi.org/10.1007/s00586-017-5079-6>.
- [20] G. Pezzotti, R.M. Bock, T. Adachi, A. Rondinella, F. Boschetto, W. Zhu, E. Marin, B. McEntire, B.S. Bal, O. Mazda, Silicon nitride surface chemistry: a potent regulator of mesenchymal progenitor cell activity in bone formation, *Appl. Mater. Today* 9 (2017) 82–95, <http://dx.doi.org/10.1016/j.apmt.2017.05.005>.
- [21] G. Pezzotti, E. Marin, T. Adachi, A. Rondinella, F. Boschetto, W.-L. Zhu, N. Sugano, R.M. Bock, B.J. McEntire, B.S. Bal, Bioactive silicon nitride: a new therapeutic material for osteoarthropathy, *Sci. Rep.* 7 (2017) 44848.
- [22] G. Pezzotti, N. Oba, W. Zhu, E. Marin, A. Rondinella, F. Boschetto, B.J. McEntire, K. Yamamoto, B.S. Bal, Human osteoblasts grow transitional Si/N apatite in quickly osteo-integrated Si₃N₄ cervical insert, *Acta Biomater.* 64 (2017) 411–420.
- [23] L.M. Jurkić, I. Cepanec, S.K. Pavelić, K. Pavelić, Biological and therapeutic effects of ortho-silicic acid and some ortho-silicic acid-releasing compounds: new perspectives for therapy, *Nutr. Metab. (Lond.)* 10 (2013) 2, <http://dx.doi.org/10.1186/1743-7075-10-2>.
- [24] T.D. Spector, M.R. Calomme, S.H. Anderson, G. Clement, L. Bevan, N. Demeester, R. Swaminathan, R. Jugdaohsingh, D.A. Berghe, J.J. Powell, Choline-stabilized orthosilicic acid supplementation as an adjunct to calcium/vitamin D3 stimulates markers of bone formation in osteopenic females: a randomized, placebo-controlled trial, *BMC Musculoskelet Disord.* 9 (2008) 85, <http://dx.doi.org/10.1186/1471-2474-9-85>.
- [25] R. Jugdaohsingh, Silicon and bone health, *J. Nutr. Heal. Aging* 11 (2007) 99–110.
- [26] M. Anderson, J. Bernero, D. Brodke, Medical imaging characteristics of silicon nitride ceramic a new material for spinal arthroplasty implants, in: 8th Annu. Spine Arthroplast. Soc. Glob. Symp. Motion Preserv. Technol., Miami, FL, 2008, p. 547.
- [27] A. Malhotra, V.B. Kalra, X. Wu, R. Grant, R.A. Bronen, K.M. Abbed, Imaging of lumbar spinal surgery complications, *Insights Imaging* 6 (2015) 579–590, <http://dx.doi.org/10.1007/s13244-015-0435-8>.
- [28] A. Rudisch, C. Kremser, S. Peer, A. Kathrein, W. Judmaier, H. Daniaux, Metallic artifacts in magnetic resonance imaging of patients with spinal fusion: a comparison of implant materials and imaging sequences, *Spine (Phila. Pa. 1976)* 23 (1998) http://journals.lww.com/spinejournal/Fulltext/1998/03150/Metallic_Artifacts_in_Magnetic_Resonance_Imaging.9.aspx.

Open Access

This article is published Open Access at [sciencedirect.com](http://www.sciencedirect.com). It is distributed under the [IJSCR Supplemental terms and conditions](#), which permits unrestricted non commercial use, distribution, and reproduction in any medium, provided the original authors and source are credited.