



## Conduction disorder and primary cardiac tumor: a fatal case of multiple lipomas of the right atrium

Stefano D'Errico<sup>1</sup>, Andrea Mazzanti<sup>2</sup>, Paola Frati<sup>3</sup>, Vittorio Fineschi<sup>3,\*</sup>

<sup>1</sup>Department of Legal Medicine, Azienda Ospedaliera Universitaria Sant'Andrea, via di Grottarossa, Roma, Italy

<sup>2</sup>Molecular Cardiology, Istituti Clinici Scientifici Maugeri, Istituto di Ricovero e Cura a Carattere Scientifico, Pavia, Italy; Department of Molecular Medicine, University of Pavia, Pavia, Italy

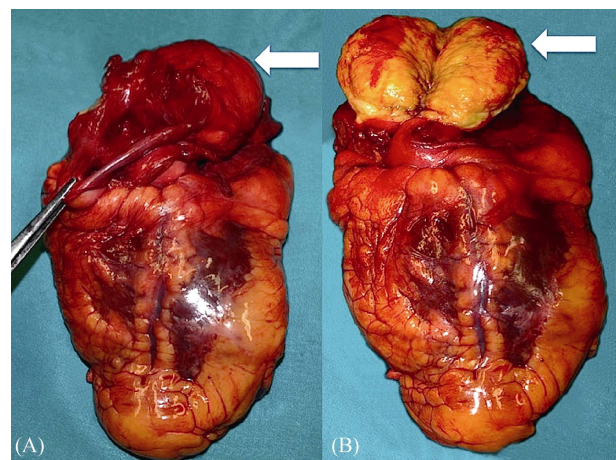
<sup>3</sup>Department SAIMLAL, Sapienza University of Roma, Viale Regina Elena, Roma, Italy

*J Geriatr Cardiol* 2019; 16: 431–433. doi:10.11909/j.issn.1671-5411.2019.05.003

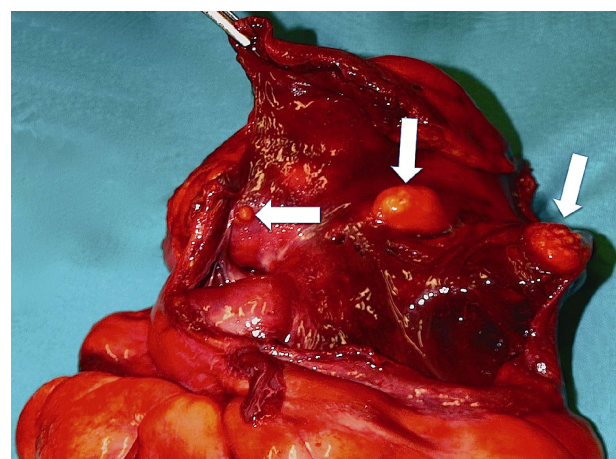
**Keywords:** Autopsy; Lipoma; Primary cardiac tumor; Sudden cardiac death

Cardiac primary tumors are uncommon with an estimated prevalence between 0.17% and 0.19%.<sup>[1,2]</sup> Cardiac lipoma are extremely rare representing only 10%–19% of primary cardiac tumors and only few are symptomatic, depending on their location within the heart.<sup>[3,4]</sup> They originate from the subendocardium (50%), subepicardium (25%) or myocardium (25%) and with different sizes and locations.<sup>[5]</sup> Few cases of sudden death due to primary cardiac tumors are reported in literature (0.0025%); in these cases, conductive and haemodynamic abnormalities have been indicated as the cause of death.<sup>[6]</sup>

A 67-year-old man was found unconscious at home and immediately transported to Emergency Department of the local hospital. Medical history was negative. One hour after rescue, clinical conditions started get better; normal cardiac action was recorded at ECG and neurological examination was normal. Two hours after recovery, he died suddenly and unexpectedly. Hospital autopsy was performed the day after death. The cadaver was 185 cm tall and weighed 89 kg. External examination was negative. Heart was normal in size and shape, the weight was 420 g; coronary arteries examination was performed with cross-sectional cuts and excluded significant lumen obstruction. Gross examination of the heart revealed an encapsulated subepicardial lipomatous mass (40 × 30 × 30 mm) of the right atrium infiltrating the interatrial septum (Figure 1A & 1B). Heart examination was performed according to the inflow-outflow method; in the subendocardial wall of the right atrium, three yellowish nodules (maximum diameter 1 cm) were detected (Figure 2). No further pathological findings were attributable to the heart and other organs. Mild pulmonary oedema was also recorded with white foam on the main bronchi. The his-

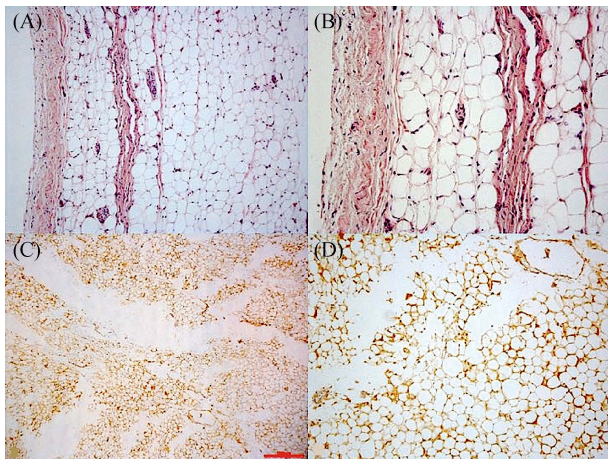


**Figure 1.** (A): Large encapsulated tumor (40 × 30 × 30 mm) of the free wall of the right atrium (arrow); (B): Yellowish and adipous aspect of the mass after section (arrow).



**Figure 2.** Yellowish fatty nodules (maximum diameter 1 cm, arrows) in the subendocardial wall of the right atrium.

\*Correspondence to: vittorio.fineschi@uniroma1.it



**Figure 3.** (A&B): Striated cardiac muscle with adjacent solid population of adipocytes (H & O, 10 $\times$ , 20 $\times$ ); (C & D): Positive at S100 immuno-histochemical staining of tumor samples (4 $\times$ , 10 $\times$ ).

tologic study was completed using formalin-fixed paraffin embedded tissue sectioned at 4 mm and stained with haematoxylin–eosin. The diagnosis of benign multiple lipomas of the right atrium infiltrating myocardium was confirmed by immunostaining that revealed immunopositivity for S100 protein (Figure 3A–D). Histological examination of the brain revealed a mild edema. The pathological myocardial picture included fragmentation of the whole myocell in pathological band with intense hyperosinophilia of the hyper-contracted myocardial cells, extremely short sarcomeres, highly thickened Z lines, and rexis of the myofibrillar apparatus into cross-fibre, anomalous and irregular. Histological examination of other organs was unremarkable. Toxicological analysis on blood and urine specimens were negative.

Primary tumors of the heart are rare, and the incidence varies between 0.0017% and 0.19% in unselected autopsy studies.<sup>[7,8]</sup> Among these, more than 70% are benign and include myxomas (mainly), fibroma, papillary fibroelastoma, rhabdomyoma and lipoma.<sup>[9–12]</sup> Cardiac lipoma is extremely rare with a reported incidence of about 10%–19% among primary tumors of heart and pericardium with a prevalence between ages 40–60 years.<sup>[5,13–17]</sup> Approximately 50% of cardiac lipomas arise subendocardially with a particular predilection for the right atrium and the left ventricle, 25% subepicardially, and 25% from the myocardium and are extremely variable in size.<sup>[18]</sup> Histopathologically, cardiac lipoma can be classified into two types: lipomatous hypertrophy of the interatrial septum and true lipoma; the former one is a non-encapsulated mass of adipose tissue which is usually in continuity with the epicardial fat. The true lipoma is a neoplasm, constituted of encapsulated masses of adipose tissue, typically mature adipocytes. Patients with cardiac lipoma are usually asymptomatic or paucisymptomatic

for fatigue or dyspnea. In few cases, lipomas can cause angina if they compress the coronary arteries or they can reduce systolic function by compressing on the left ventricle.<sup>[19–25]</sup> Embolization is a rare phenomenon because lipomas are typically encapsulated. Cases of sudden unexpected death attributed to myocardial tumors have been poorly described in forensic and clinical literature; in these cases cardiac neoplasms cause atrioventricular or intraventricular conduction disorders, which are manifested by arrhythmias, interfering in the cardiac dynamic and leading to sudden death.<sup>[6,9,26–29]</sup> It has been calculated that 0.0025% of all cardiovascular deaths may be sudden death caused by primary cardiac lesions and 0.01%–0.005% of all sudden death could be due to primary cardiac tumors and 0.06% of cardiovascular death among 0–34 year old population may be the result of sudden death caused by a primary intracardiac tumor. These data indicate that primary cardiac lesions are uncommon, yet potentially lethal. It is also expected that several primary cardiac tumor causing sudden death will be missed each year because an autopsy is not performed.<sup>[6,30]</sup> In the case presented, sudden and fatal cardiac rhythm disturbance caused by subendocardial lipoma infiltrating atrial myocardium was hypothesized as pathogenetic mechanism of death; a complete autoptic examination, with histologic and immunohistochemical study of cardiac lesion, confirmed that the neoplasms was primary and benign.

## Acknowledgements

This study and submission were approved from local ethical committee. Consent to hospital autopsy was recorded from relatives.

## References

- 1 D'Souza J, Shah R, Abbas A, *et al.* Invasive cardiac lipoma: a case report and review of literature. *BMC Cardiovascular Disorders* 2017; 17–28.
- 2 Wu S, Teng P, Zhou Y, *et al.* A rare case report of giant epicardial lipoma compressing the right atrium with septal enhancement. *J Cardiothoracic Surg* 2015; 10: 150.
- 3 Li D, Wang W, Zhu Z, *et al.* Cardiac lipoma in the interventricular septum: a case report. *J Cardiothoracic Surg* 2015; 10: 69.
- 4 Girschbach F, Mohr FW, Misfeld M. Epicardial lipoma—a rare differential diagnosis in cardiovascular medicine. *Eur J Cardiothoracic Surg* 2012; 41: 699–701.
- 5 Ismail I, Al-Khafaji K, Mutyala M, *et al.* Cardiac Lipoma. *J Community Hosp Intern Med Perspect* 2015; 5: 28449.
- 6 Cina SJ, Smialek J, Burke AP, *et al.* Primary cardiac tumors causing sudden death: a review of the literature. *Am J Forensic Med Pathol* 1996; 17: 271–281.

- 7 Zhu J, Liu Y, Xi EP, *et al.* A giant symptomatic cardiac lipoma recurring at the fifth year. *Int J Clin Exp Med* 2015; 8: 14173–14175.
- 8 Andersen RE, Kristensen BW, Gill S. Cardiac leiomyosarcoma, a case report. *Int J Clin Exp Pathol* 2013; 6: 1197–1199.
- 9 Ventura F, Landolfi MC, Leoncini A, *et al.* Sudden death due to primary atrial neoplasms: two cases and review of literature. *For Sci Int* 2012; 214: e30–e33.
- 10 Centofanti P, Di Rosa E, Deorsola L, *et al.* Primary cardiac neoplasms: early and late results of surgical treatment in 91 patients. *Ann Thorac Surg* 1999; 68: 1236–1241.
- 11 Chiappini B, Gregorini R, Vecchio L, *et al.* Cardiac hemangioma of the left atrial appendage: a case report and discussion. *J Card Surg* 2009; 24: 522–523.
- 12 Marina K, Vasiliki KE, George S, *et al.* Recurrent cardiac myxoma in a 25 year old male: a DNA study. *World J Surg Oncol* 2013;11: 95.
- 13 Zhu SB, Zhu J, Liu Y *et al.* Surgical treatment of a giant symptomatic cardiac lipoma. *J Thorac Oncol* 2013; 8: 1341–1342.
- 14 Ganame J, Wright J, Bogaert J. Cardiac lipoma diagnosed by cardiac magnetic resonance imaging. *Eur Heart J* 2008; 29: 697.
- 15 Rainer WG, Bailey DJ, Hollis HW. Giant cardiac lipoma: refined hypothesis proposes invagination from extracardiac to intracardiac sites. *Tex Heart Inst J* 2016; 43: 461–464.
- 16 Ragland MM, Tak T. The role of echocardiography in diagnosing space-occupying lesions of the heart. *Clin Med Res* 2006; 4: 22–32.
- 17 Matebele MP, Peters P, Mundy J, *et al.* Cardiac tumors in adults: surgical management and follow up of 19 patients in an Australian tertiary hospital. *Interact Cardiovasc Thorac Surg* 2010; 10: 892–895.
- 18 Censi S, Squeri A, Baldelli M, *et al.* Ischemic stroke and incidental finding of a right atrial lipoma. *J Cardiovasc Med (Hagerstown)* 2013; 14: 905–906.
- 19 Khalili A, Ghaffari S, Jodati A, *et al.* Giant right atrial lipoma mimicking tamponade. *Asian Cardiovasc Thorac Ann* 2015; 23: 317–319.
- 20 Mongal LS, Salat R, Anis A, *et al.* Enormous right atrial hemangioma in an asymptomatic patient: a case report and literature review. *Echocardiography* 2009; 26: 973–976.
- 21 Butany J, Nair V, Naseemuddin A, *et al.* Cardiac tumours: diagnosis and management. *Lancet Oncol* 2005; 6: 219–228.
- 22 Venturini E, Magni L, Franchini C *et al.* Right atrial hemangioma. *J Cardiovasc Med* 2008; 9: 1260–1262.
- 23 Wang H, Hu J, Sun X *et al.* An asymptomatic right atrial intramyocardial lipoma: a management dilemma. *World J Surg Oncol* 2015; 13: 20.
- 24 Wang Y, Wang X, Xiao Y. Surgical treatment of primary cardiac valve tumor: early and late results in eight patients. *J Cardiothorac Surg* 2016; 11: 31.
- 25 Battellini R, Bossert T, Areta M, *et al.* Successful surgical treatment of a right atrial myxoma complicated by pulmonary embolism. *Interact Cardiovasc Thorac Surg* 2003; 2: 555–557.
- 26 Calamida R, Dessalvi F, Pistis L, *et al.* Sudden death in cardiac lipomatous hamartoma. *G Ital Cardiol* 1996; 26: 1421–1424.
- 27 Bagwan IN, Sheppard MN. Cardiac lipoma causing sudden cardiac death. *Eur J Cardiothorac Surg* 2009; 35: 727.
- 28 Crespo Marcos D, Arias Castro S, Alvarez Martin T, *et al.* Right atrial lipoma in a 14 year old patient. *Ann Pediatr (Barc)* 2009; 71: 84–86.
- 29 Li J, Ho SY, Becker AE, *et al.* Multiple cardiac lipomas and sudden death: a case report and literature review. *Cardiovasc Pathol* 1998; 7: 51–55.
- 30 De Filippo M, Corradi D, Nicolini F, *et al.* Hemangioma of the right atrium: imaging and pathology. *Cardiovasc Pathol* 2010; 19: 121–124.