



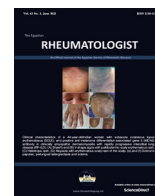
Since January 2020 Elsevier has created a COVID-19 resource centre with free information in English and Mandarin on the novel coronavirus COVID-19. The COVID-19 resource centre is hosted on Elsevier Connect, the company's public news and information website.

Elsevier hereby grants permission to make all its COVID-19-related research that is available on the COVID-19 resource centre - including this research content - immediately available in PubMed Central and other publicly funded repositories, such as the WHO COVID database with rights for unrestricted research re-use and analyses in any form or by any means with acknowledgement of the original source. These permissions are granted for free by Elsevier for as long as the COVID-19 resource centre remains active.



Contents lists available at ScienceDirect

The Egyptian Rheumatologist

journal homepage: www.elsevier.com/locate/ejr

Case reports

Microscopic polyangiitis associated with coronavirus disease-2019 (COVID-19) infection in an elderly male



Shirin Assar*, Mehran Pournazari, Parviz Soufivand, Dena Mohamadzadeh, Simindokht Sanaee

Rheumatology Department, Clinical Research Development Center, Imam Reza Hospital, Kermanshah University of Medical Sciences, Kermanshah, Iran

ARTICLE INFO

Article history:

Received 1 March 2021

Accepted 2 March 2021

Available online 9 March 2021

Keywords:

Microscopic polyangiitis

Vasculitis

Mononeuritis multiplex

Covid-19

ABSTRACT

Background: Microscopic polyangiitis (MPA) is an antineutrophil cytoplasmic antibody (ANCA)-associated vasculitis (AAV) that affects predominantly small- sized vessels. A causal relationship between viral infections and vasculitis has been postulated.

Aim of the work

To present the concomitant association of coronavirus disease 2019 (COVID-19) infection with MPA in an elderly Iranian male.

Case presentation: A 67 year old Iranian man with the history of COVID-19 infection and a positive polymerized chain reaction (PCR) test four weeks before admission to the neurology department with acute onset pain, numbness and progressive weakness in both hands grip, sudden left foot drop and paresthesia. Erythrocyte sedimentation rate (ESR) was 95 mm/hr, ferritin 912 ng/ml and C-reactive protein (CRP) positive, proteinuria 1.1 g/24 h and markedly elevated perinuclear (P-ANCA): 526 IU/ml. Diagnosis of MPA was held presenting with mononeuritis multiplex, glomerulonephritis followed by diffuse alveolar hemorrhage and infiltration of lymphocytes in muscle fibers and vessels wall in sural nerve biopsy. He was successfully treated by methylprednisolone (1 g/day for 3 days) followed by 1 mg/kg with gradual tapering along with cyclophosphamide (CYC) (2 mg/kg). Intravenous immunoglobulin (IVIG, 2 g/kg in four divided doses) started for the management of inflammatory mononeuritis multiplex with gradual improvement. During hospitalization, plasmapheresis was performed due to alveolar hemorrhage for 5 day. The patient returned home on day 32 and followed-up in the rheumatology clinic with improvement of muscle power and handgrip strength.

Conclusion: Vasculitis is potentially one of COVID-19's presenting symptoms and prompt diagnosis and treatment is crucial in improving outcome of patients.

© 2021 Egyptian Society of Rheumatic Diseases. Publishing services provided by Elsevier B.V. This is an open access article under the CC BY-NC-ND license (<http://creativecommons.org/licenses/by-nc-nd/4.0/>).

1. Introduction

At the end of 2019 several cases of atypical pneumonia emerged in the Chinese province of Hubei and, in January 2020, severe acute respiratory virus 2 (SARS-CoV-2) was identified as the causative agent of the novel coronavirus disease 2019 (COVID-19) [1]. Signs and symptoms of COVID-19 extending beyond the respiratory tract, The finding can be explained, at least in part, by the ubiquitous expression and tissue distribution of angiotensin-converting enzyme 2 (ACE2), the major SARS-CoV-2 entry receptor [2]. ACE-2 receptor is found also in bowel, endothelium of small vessels, smooth muscle, skeletal muscle and even synovial tissue [3]. It is therefore not unexpected that, some of the symptoms caused by

COVID-19 are commonly described in other diseases, for instance, also in patients with rheumatic conditions. Interestingly, the association between viral infections and rheumatic diseases is already well-recognized. In fact during the pandemic, rheumatic disease patients faced remarkable difficulty to obtain their medications with subsequent change in their disease status [4] with a negative impact on their quality of life [5]. There is an agreement to the key emerging frontline role of rheumatologists in treating COVID-19. During the pandemic, RD cases requiring admission are dealt with by modified strategies [6]. Viruses can be direct etiologic agents of acute and chronic arthritis [7], and of different forms of vasculitis, both in children and adults [8].

Microscopic polyangiitis (MPA) is a member of the family of antineutrophil cytoplasmic antibody (ANCA)-associated vasculitides (AAV). Its characteristic histology shows a necrotizing small vessel vasculitis with little or absent immune deposits (pauci-immune vasculitis). It affects more men than women and com-

Peer review under responsibility of Egyptian Society of Rheumatic Diseases.

* Corresponding author.

E-mail address: sh-assar@kums.ac.ir (S. Assar).<https://doi.org/10.1016/j.ejr.2021.03.001>

1110-1164/© 2021 Egyptian Society of Rheumatic Diseases. Publishing services provided by Elsevier B.V.

This is an open access article under the CC BY-NC-ND license (<http://creativecommons.org/licenses/by-nc-nd/4.0/>).

mences at the age of ≥ 50 years. The two organs most typically involved and often defining prognosis are the kidneys and the lungs. MPA may concomitantly or sequentially involve other organs such as the nervous system, the skin, the musculoskeletal system, but also the heart, the eye and the intestines [9]. Neurologic involvement in MPA is common, and affects between 37 and 72% of patients [10]. Peripheral neuropathy occurs more frequently than central nervous system involvement, with mononeuritis multiplex and distal symmetrical polyneuropathy as the predominant peripheral nervous system manifestations. Necrotizing vasculitis can be seen on sural nerve biopsy in up to 80% of patients, and nerve conduction studies typically show acute axonopathy [11].

The aim of this case report is to present the concomitant association of COVID-19 infection with MPA in an elderly Iranian male.

2. Case presentation

On November 18th, 2020, a 67 year old man was admitted to the neurology department at Kermanshah University, Iran. He complained of acute onset pain, numbness and progressive weakness in both hands grip for one week prior to admission and a sudden left foot drop on the day of admission preceded by paresthesia of the left foot. His past medical history included hypothyroidism, on thyroxin supplementation for 3 years and a recent COVID19 infection which was proved by a positive polymerized chain reaction (PCR) test four weeks prior to admission. At that time, his symptoms were fever, malaise and dry cough, and he received naproxen 250 mg twice daily, azithromycin 500 mg daily and diphenhydramine syrup four times a day orally in an outpatient setting. His familial history was unremarkable for autoimmune diseases. The management of the case was approved by the ethical committee of the university and in agreement to the declaration of Helsinki. An informed consent was obtained from the patient for the publication of this case report.

On general examination, the vital signs were stable and on admission he was afebrile with pallor. Examination of the respiratory and cardiovascular systems was within normal limits. Neurological examination revealed a conscious and alert patient with normal cranial nerves. On motor examination, hypotonia was noted in both lower limbs. The rest of examination showed distal motor deficit of the left leg with muscle strength evaluated as 1/5 in left foot dorsiflexors and as 2/5 in plantar flexors on the Medical Research Council (MRC) scale. Mild weakness in the upper limbs with distal dominant distribution (MRC 3/5) was detected. There was hypoesthesia of the hands in the median and radial distribution, in the lateral aspect of the left leg and in the dorsum and the sole of the foot. All deep tendon jerks were normal, except for the absence of left knee reflex. Gait was unsteady and typically stepping.

On the day of admission laboratory studies showed hemoglobin of 8.6 mg/dl, white blood cell count (WBC) $17.3 \times 10^3/\text{mm}^3$ (differential count: neutrophils 48%, lymphocytes 47%, eosinophils 1% and monocytes 4%), platelet count $188 \times 10^3/\text{mm}^3$, creatinine 1 mg/dl, International normalized ratio (INR) 1.1, partial thromboplastin time (PTT) 38 s, lactate dehydrogenase (LDH) 1122 IU/ml (normal: 225–500 IU/ml), erythrocyte sedimentation rate (ESR) 95 mm/hr, ferritin 912 ng/ml (normal: 3–400 ng/ml) and C-reactive protein (CRP) was positive. Liver function tests and creatine phosphokinase (CPK) were normal. Reticulocyte production index was 1.7 and schistocyte was not detected in peripheral blood smear. Microscopic hematuria with dysmorphic RBC was detected in urine analysis. There was proteinuria 1.112 g/24 h. Blood and urine cultures were sterile. Serum protein electrophoresis was normal. Thyroid function profile revealed hypothyroidism: thyroid

stimulating hormone (TSH) was 17.68 uIU/ml (normal: 0.27–4.2 uIU/ml), T4 was 8.05 ug/dl (normal: 5.13–14.06 ug/dl), T3 was 0.75 ng/ml (normal: 0.8–2 ng/ml). Immunological blood tests revealed negative results for antinuclear antibody, anti-ds DNA antibody, cryoglobulins, antiphospholipid antibodies, anti-Ro, anti-La, anti-Sm and cytoplasmic ANCA (C-ANCA), but there was a markedly elevated titer of perinuclear (P-ANCA): 526 IU/ml (normal: <12 IU/ml), serologic tests for hepatitis B and C viruses, human immunodeficiency virus and tumor markers were negative. anti-SARS-CoV-2 IgG and IgM antibodies and COVID-19 PCR test were positive.

Electromyography and nerve conduction velocity studies (EMG/NCV) was performed and findings were compatible with a marked asymmetrical sensory-motor axonal polyradiculoneuropathy consistent with mononeuritis multiplex, affecting both radial and left peroneal nerves. Chest x-ray was unremarkable and chest computerized tomography (CT) scan revealed bilateral patchy ground glass opacities (Fig. 1a). Paranasal sinus CT scan was normal. Magnetic resonance imaging (MRI) of the brain and spine did not show any ischemic, hemorrhagic or inflammatory lesion.

Multiorgan involvement and elevated P-ANCA suggested a systemic inflammation most likely vasculitis. To confirm a left sural nerve biopsy was performed and lymphocytic infiltration of muscle fibers and vessel wall along with edema and atrophy of muscle fibers were observed (Fig. 2). Diagnosis of MPA was confirmed and treatment started with methylprednisolone (1 g/day for 3 days) followed by 1 mg/kg with gradual tapering along with cyclophosphamide (CYC) (2 mg/kg). Intravenous immunoglobulin (IVIg, 2 g/kg in four divided doses) started for the management of inflammatory mononeuritis multiplex. Gradual improvement in upper limb symptoms and ankle dorsiflexors occurred.

On the 17th day of admission, the patient started to suffer from shortness of breath, cough and hemoptysis. Lung physical examination revealed bilateral basal crepitus. He developed hypoxia needing supplemental oxygen. His hemoglobin decreased gradually despite packed cell infusion. Echocardiography was normal with ejection fraction of 55%. Chest x-ray images revealed diffuse airspace opacities and chest CT scan findings were consistent with diffuse bilateral ground glass alveolar opacity casting the pulmonary lobules together with confluent areas of consolidation opacities and bilateral plural effusion (Fig. 1b). He did not consent to undergo bronchoscopy at this time, but the overall clinical picture was consistent with an alveolar hemorrhage, although COVID-19 pneumonitis was in differential diagnosis. Plasmapheresis was performed for 5 days for suspected alveolar hemorrhage after which he symptomatically improved. The patient returned home on day 32 with slight improvement of peroneal paralysis and handgrip strength. He was followed up in the rheumatology clinic 4 weeks after discharge and his muscle forces and hand grip strength were slightly improved. ESR level and 24 h urine protein decreased to 22 mm/h and 635 mg/24hrs respectively. He was maintained on oral CYC 2 mg/kg daily and oral steroids. The patient's laboratory data on different days is summarized in Table 1.

3. Discussion

Microscopic polyangiitis (MPA) is pathologically characterized by inflammation and fibrinoid necrosis of small vessel walls, leading to multiple organ involvement, including of the kidneys, lung, skin, digestive system, and nervous system. The etiology of ANCA-associated vasculitis (AAV) is considered to involve genetic and environmental factors, such as silica exposure, infections, and drugs [12]. In the current case, vasculitis developed following

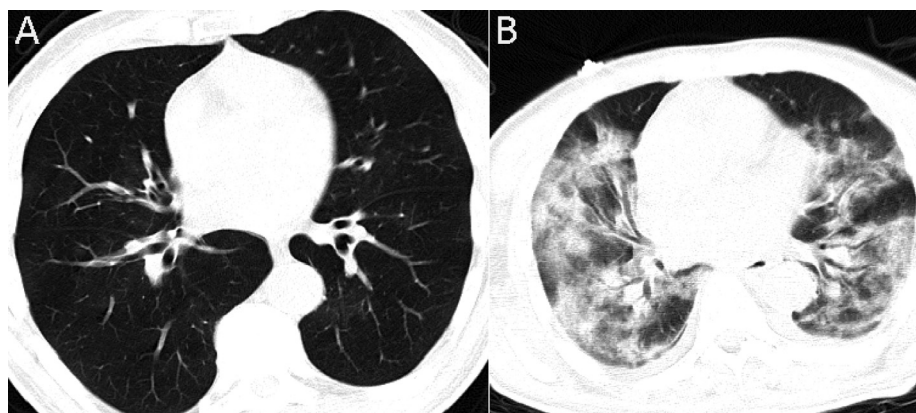


Fig. 1. Chest computerized tomography (CT) scan of a 67 year old man (A) on admission day showing patchy ground glass opacities and (B) on the 17th day diffuse bilateral ground glass alveolar opacity casting the pulmonary lobules together with confluent areas of consolidation opacities and bilateral pleural effusion.

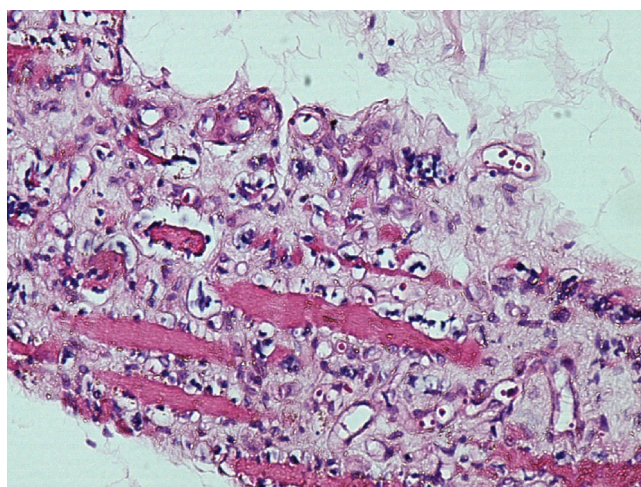


Fig. 2. Left sural nerve biopsy specimen showing lymphocytic infiltration of muscle fibers and vessel wall along with edema and atrophy of muscle fibers in a 67 year old man.

COVID-19 infection, and this virus may be the etiological factor of the disease.

New data suggests that COVID19 infection can present differently and it does not necessarily affect the respiratory system [13]. Therefore, SARS2 could be a misnomer for this disease. There are some speculations that the virus could be a direct invader of endothelial cells [14]. In this case vasculitis was probably the consequence of an immuno-inflammatory process, as suggested by the

4-week delay between first symptoms and the development of multiorgan involvement and the positive COVID-19 IgG serological test at the time of admission. Vasculitis can affect a wide variety of organs, including the lungs, kidneys, skin, brain, and peripheral nerve. There is an alteration of the immune system in which it produces autoantibodies; many of them directed against multiple antigens located in the basement membrane of blood vessels. Primary autoantibodies produced are ANCA; their role is essential for the diagnostic orientation of this pathology [15].

It could be postulated that the patient’s infection with COVID-19 and its subsequent increased inflammatory state led to his developing of MPA with subsequent peripheral nervous system, pulmonary and renal involvement. His clinical and serologic pictures were consistent with a diagnosis of MPA. Biopsy of sural nerve revealed much more lymphocytic infiltration in muscle fibers than vessels wall. MPA diagnosed by muscle specimen has been reported [16].

It is unclear whether the patient had a smoldering vasculitis that was accelerated by the inflammatory state of COVID-19 or whether this virus caused a vasculitis by itself. Although he did not have any respiratory symptoms on admission, lung involvement might have existed, because the ground glass shadows in his lungs gradually progressed over 2 weeks.

As far as we know, this case is the first to describe the presence of MPA due to COVID19 infection. *Estévez-Rivera and his colleagues*, described a 63-year-old woman who developed mononeuritis multiplex, kidney failure and necrotic lesions in the pulp of the knuckles, with positive serum IgG against SARS-CoV-2 but negative serum IgM and oropharyngeal swab PCR and they suggested the possibility of an underlying vasculitis process, but they didn’t mention anything about ANCAs or biopsy of affected tissues [17].

Table 1

Laboratory findings of the patient on admission, during his stay, on discharge and on follow up.

Parameters (units)	Day 1	Day 17	Day32 (discharge)	4 weeks after discharged
Hb (g/dl)	8.6	6.2	10.5	11.7
WBC (K/ul)	17.3	3.4	5	7.4
Platelet (K/ul)	188	364	145	184
PTT (second)	35	40	34	33
INR	1.1	1.1	1.1	1.1
Serum urea (mg/dl)	67	114	65	89.8
Serum creatinine (mg/dl)	1	1.7	1.3	1.1
ESR (mm/1 st hr)	95		37	22
LDH (IU/ml)	1122		435	265
CPK (IU/L)	245		190	155

Hb: hemoglobin, WBC: white blood cells, PTT: partial thromboplastin time, INR: International normalized Ratio, ESR: erythrocyte sedimentation rate, LDH: lactate dehydrogenase, CPK: Creatine phosphokinase.

This could indicate that vasculitis develops as a late-onset manifestation of COVID-19 infection. SARS-CoV-2 antigens may promote the development of antibodies, forming antigen–antibody complexes that target the vascular endothelium and provoking the appearance of vasculitis. However, there is no solid evidence about the role of COVID-19 in the etiopathogenic mechanism of the vascular lesions. A recent work from *Colmenero et al* considered the presence of viral particles in the endothelium from patients with chilblains and the histological evidence of vascular damage support a causal relation of the lesions with SARS-CoV2 [18]. This finding supports a relationship between vasculitis and coronavirus. Further works are needed to clarify if virus particles are detected by PCR in affected tissues, specifically in endothelial cells of small vessels, or it is merely leukocytic infiltration and immune complexes.

In conclusion, although there is no conclusive evidence that COVID-19 can develop vasculitis, this case of MPA was associated with high serum coronavirus IgM and IgG levels and positive PCR test, therefore MPA can potentially be a manifestation of COVID-19 infection, and prompt diagnosis and treatment is very important to improve outcome.

Funding

This research did not receive any specific grant from funding agencies in the public, commercial, or not-for-profit sectors.

Declaration of Competing Interest

The authors declare that they have no known competing financial interests or personal relationships that could have appeared to influence the work reported in this paper.

References

- [1] Phelan AL, Katz R, Gostin LO. The novel coronavirus originating in Wuhan, China: challenges for global health governance. *JAMA* 2020;323(8):709–10.
- [2] Verdecchia P, Cavallini C, Spanevello A, Angeli F. The pivotal link between ACE2 deficiency and SARS-CoV-2 infection. *Eur J Intern Med* 2020;76:14–20.
- [3] Li MY, Li L, Zhang Y, Wang XS. Expression of the SARS-CoV-2 cell receptor gene ACE2 in a wide variety of human tissues. *Infect Dis Poverty* 2020;9(1):45.
- [4] Abualfadl E, Ismail F, Shereef RRE, Hassan E, Tharwat S. ECR COVID19-Study Group. Impact of COVID-19 pandemic on rheumatoid arthritis from a Multi-Centre patient-reported questionnaire survey: influence of gender, rural-urban gap and north-south gradient. *Rheumatol Int* 2021;41(2):345–53.
- [5] Zomalheto Z, Assogba C, Dossou-yovo H. Impact of the severe acute respiratory syndrome coronavirus 2 (SARS-CoV2) infection and disease-2019 (COVID-19) on the quality of life of rheumatoid arthritis patients in Benin. *Egypt Rheumatol* 2021;43(1):23–7.
- [6] Gheita TA, Salem MN, Eesa NN, Khalil NM, Gamal NM. ECR COVID19-Study Group. Rheumatologists' practice during the Coronavirus disease 2019 (COVID-19) pandemic: a survey in Egypt. *Rheumatol Int* 2020;40(10):1599–611.
- [7] Marks M, Marks JL. Viral arthritis. *Clin Med (Lond)* 2016;16(2):129–34.
- [8] Hoang MP, Park J. Vasculitis. In: Hospital based dermatopathology: an illustrated diagnostic guide. Hoang MP, Selim MA, editors. Springer International Publishing; 2020, pp. 245–96.
- [9] Villiger PM, Guillemin L. Microscopic polyangiitis: clinical presentation. *Autoimmun Rev* 2010;9(12):812–9.
- [10] Zhang W, Zhou G, Shi Q, Zhang X, Zeng XF, Zhang FC. Clinical analysis of nervous system involvement in ANCA-associated systemic vasculitides. *Clin Exp Rheumatol* 2009;27(1 Suppl 52):S65–9.
- [11] Hattori N, Mori K, Mitsu K, Koike H, Ichimura M, Sobue G. Mortality and morbidity in peripheral neuropathy associated Churg-Strauss syndrome and microscopic polyangiitis. *J Rheumatol* 2002;29(7):1408–14.
- [12] Chen M, Kallenberg GM. ANCA-associated vasculitides—advances in pathogenesis and treatment. *Nature Rev Rheumatol* 2010;6(11):653–64.
- [13] Rodríguez-Jiménez P, Chicharro P, De Argila D, Muñoz Hernandez P, et al. Urticaria-like lesions in COVID-19 patients are not really urticaria – a case with clinicopathologic correlation. *J Eur Acad Dermatol Venereol* 2020;34(9):e459–60.
- [14] Varga Z, Flammer AJ, Steiger P, Haberecker M, Andermatt R, Zinkernagel AS, et al. Endothelial cell infection and endotheliitis in COVID-19. *Lancet* 2020;395:1417–8.
- [15] Pérez-Beltrán CF, Garza-Zúñiga MJ, Isaías-Camacho JO, Andrade-Carmona V, Díaz-Greene EJ, Rodríguez-Weber FL. Vasculitis and its neurological manifestations. *Med Interna de México* 2015;31(3):324–36.
- [16] Murata O, Izumi K, Kaneko Y, Yasouka H, Suzuki K, Matsubara S, et al. Microscopic polyangiitis diagnosed by muscle specimen: a case report and literature review. *Modern Rheumatol Case Rep* 2018;2:181–4.
- [17] Estévez-Rivera E, Benavides-Hinestroza J, Rubiano H, García-Perdomo HA. Mononeuritis multiplex associated with Sars-Cov2-Covid-19 infection: case report. *Int J Neurol Neurother* 2020;7(102):1–4.
- [18] Colmenero I, Santonja C, Alonso-Riaño M, Noguera-Morel L, Hernández-Martín A, Andina D, et al. SARS-CoV2 endothelial infection causes COVID-19 chilblains: histopathological, immunohistochemical and ultrastructural study of seven paediatric cases. *Br J Dermatol* 2020;183(4):729–37.