

Open Access

Blind Spot of Enteral Stenting for Malignant Duodenal Obstruction due to Colon Cancer: A Rare Case of Duodenocolonic Fistula

Takashi Sasaki, Takafumi Mie and Naoki Sasahira

Department of Hepato-Biliary Pancreatic Medicine, Cancer Institute Hospital of Japanese Foundation for Cancer Research, Tokyo, Japan

A 57-year-old woman had undergone right hemicolectomy, partial pancreatic head resection, and partial duodenectomy for advanced ascending colon cancer. Owing to a local recurrence, she was referred to our hospital. Percutaneous transhepatic biliary drainage was performed for a malignant biliary obstruction, and the local recurrence was treated with radiotherapy. Systemic chemotherapy was then started, but the patient had a complication of malignant duodenal obstruction 1 year after the recurrence. Only non-contrast-enhanced abdominal computed tomography could be obtained because of the patient's allergy to the contrast medium (Fig. 1). The size of the recurrence site was estimated to be approximately 5 cm. However, detailed information on the occlusion site was difficult to obtain before the endoscopic treatment. A forward-viewing endoscope was inserted in the duodenum, and the guidewire was advanced through the stenosis (Fig. 2A). Subsequent contrast imaging revealed a dilated intestinal tract (Fig. 2B). However, contrast imaging at the stenosis revealed another lumen, and the first lumen was clarified to be the colon, and the guidewire was passed through the duodenocolonic fistula (Fig. 2C). The guidewire was turned to enter another lumen, a true duodenal lumen (Fig. 2D). As the enteral stent was placed at the papilla of Vater, an uncovered enteral stent

(NEXENT Duodenal Pyloric Stent 22 mm × 12 cm; Next Biomedical, Incheon, Korea) was placed at the duodenal obstruction. After the procedure, the patient could take a normal diet (Fig. 3A, B).

Duodenocolonic fistula is a rare complication. It is sometimes caused by benign diseases such as chronic inflammation, a foreign body, and iatrogenic diseases (e.g., those induced by radiotherapy).¹⁻³ Duodenocolonic fistula due to malignancy is rare.⁴ Furthermore, malignant duodenal obstruction due to colon cancer is unusual. When inserting an enteral stent, the stenosis is passed through using the guidewire under fluoroscopy. The guidewire is confirmed to be inside the intestinal tract based on the contrast image and course of the guidewire. In the case of a duodenocolonic fistula, the obstruction usually occurs at the infraduodenal angle. As the guidewire needs to be advanced to the third portion of duodenum, its course is quite similar to that of the transverse colon. Misplacement of an enteral stent is one of the most critical complications. To avoid this complication, clinicians should be aware that the distal bowel tract below the stenosis is usually collapsed and that no residue-like material is visible. Understanding that the guidewire may go through a lumen different from the assumed duodenum when the fistula is formed is also necessary. The present case of a duodenocolonic fistula was a blind spot in the placement of a duodenal stent. Information on such a case is useful for clinicians who perform enteral stenting.

Received: May 25, 2020 Revised: July 4, 2020

Accepted: July 6, 2020

Correspondence: Takashi Sasaki

Department of Hepato-Biliary Pancreatic Medicine, Cancer Institute Hospital of Japanese Foundation for Cancer Research, 3-8-31 Ariake, Koto, Tokyo 135-8550, Japan

Tel: +81-3-3520-0111, Fax: +81-3-3520-0141, E-mail: sasakit-tyk@umin.ac.jp

ORCID: <https://orcid.org/0000-0001-7109-9835>

© This is an Open Access article distributed under the terms of the Creative Commons Attribution Non-Commercial License (<http://creativecommons.org/licenses/by-nc/3.0>) which permits unrestricted non-commercial use, distribution, and reproduction in any medium, provided the original work is properly cited.

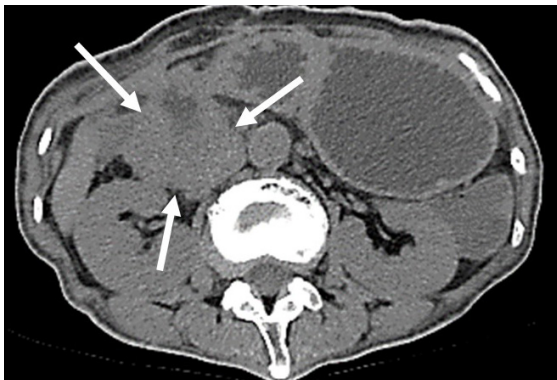


Fig. 1. Non-contrast-enhanced abdominal computed tomography image showing a local recurrence at the duodenum, which caused a malignant gastric outlet obstruction. The arrow indicates the local recurrence of the colon cancer.

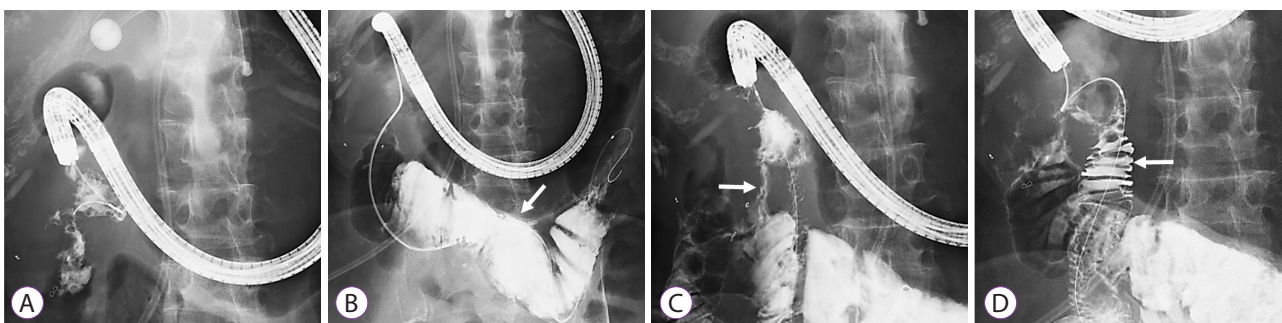


Fig. 2. (A) An endoscope is inserted in the duodenum, and the guidewire is advanced through the stenosis. (B) The contrast image shows a dilated intestinal tract. The arrow indicates the lumen of the transverse colon. (C) The contrast image of the stenosis shows another lumen. The first lumen is confirmed to be a duodenocolonic fistula, which is indicated by the arrow. (D) The guidewire is then advanced to another lumen, and the contrast image shows the duodenum. The lumen indicated by the arrow is the true duodenal lumen.

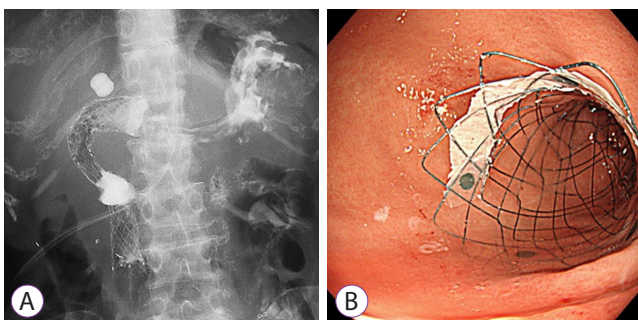


Fig. 3. An uncovered enteral stent at the duodenal obstruction. (A) Abdominal radiograph. (B) Endoscopic view.

Conflicts of Interest

The authors have no potential conflicts of interest.

Funding

None.

Author Contributions

Data curation: Takashi Sasaki, Takafumi Mie, Naoki Sasahira
 Writing-original draft: TS
 Writing-review&editing: TM, NS

ORCID

Takashi Sasaki: <https://orcid.org/0000-0001-7109-9835>
 Takafumi Mie: <https://orcid.org/0000-0002-7561-5558>
 Naoki Sasahira: <https://orcid.org/0000-0002-0672-7214>

REFERENCES

1. Liu S, de Blacam C, Lim FY, Mattei P, Mamula P. Magnetic foreign body ingestions leading to duodenocolonic fistula. *J Pediatr Gastroenterol Nutr* 2005;41:670-672.
2. Park MS, Kim WJ, Huh JH, et al. Crohn's duodeno-colonic fistula pre-operatively closed using a detachable endoloop and hemoclips: a case report. *Korean J Gastroenterol* 2013;61:97-102.
3. Javia SB, Patel R, Singhal S. Endoscopic closure with an over-the-scope clip of a duodenocolonic fistula caused by a migrated biliary stent. *Gastrointest Endosc* 2016;83:845-846; discussion 846-847.
4. Okuda KV, Laass M, Schuchardt K, et al. Duodenocolonic fistula as a rare complication of intestinal Burkitt lymphoma in a three-year-old boy. *Klin Padiatr* 2018;230:138-141.