

# Intraperitoneal Cerebrospinal Fluid Pseudocyst with Ventriculoperitoneal Shunt

Mohammad Sadegh Masoudi, Marziye Rasafian<sup>1</sup>, Zahra Naghmehsanj<sup>1</sup>, Fariborz Ghaffarpassand<sup>2</sup>

Department of Neurosurgery, Shiraz University of Medical Sciences, Shiraz, <sup>1</sup>Department of Neurosurgery, AJA University of Medical Sciences, Tehran, <sup>2</sup>Department of Neurosurgery, Student Research Committee, Shiraz University of Medical Sciences, Shiraz, Iran

## Abstract

Ventriculoperitoneal (VP) shunting is mostly used in the treatment of hydrocephalus and many complications have been reported with this method. Abdominal Pseudocyst (APC) are relatively uncommon but important complications in patients with VP shunts. We herein report the case of a 9-year-old boy with VP shunt who presented with abdominal distension, abdominal pain, malaise, and decrease of appetite. Abdominal pelvic computed tomography confirmed a diagnosis of APC. Laparotomy was done and VP shunt was placed into the other side of peritoneal cavity again. Also here, etiology, presentation, diagnosis, and treatment of APC were reviewed.

**Keywords:** Abdominal pseudocyst, cerebrospinal fluid, complication, ventriculoperitoneal shunt

## INTRODUCTION

Hydrocephalus is a common disease characterized by cerebrospinal fluid (CSF) secretion, circulation, and absorption abnormalities, which results in ventriculomegaly.<sup>[1]</sup> Ventriculoperitoneal (VP) shunting is the most frequent operative procedure for the management of hydrocephalus and the peritoneal cavity is the best site for CSF absorption.<sup>[2]</sup> The other distal diversion sites for CSF include the right atrium of the heart, ureter, gall bladder, and pleural space.<sup>[3,4]</sup> An abdominal pelvic pseudocyst is a rare, important complication of VP shunts.<sup>[4-6]</sup> Cyst is surrounded by a wall of nonepithelial tissue, so it is classified as pseudocysts.<sup>[3,7]</sup> Typical clinical presentation includes abdominal pain and/or distention, nausea, vomiting, decreased appetite, fever, and shunt malfunction signs such as headache and lethargy.<sup>[6]</sup> Abdominal signs such as abdominal pain/distension and palpable abdominal mass are predominant in adults and shunt malfunction symptoms such as headache, nausea, and vomiting are common in podiatrists.<sup>[4]</sup> This article describes a 9-year-old boy, a case of APC after VP shunt insertion and reviewed the etiology, clinical picture, diagnosis, radiological findings, and surgical treatment of APC.

## CASE REPORT

The patient was a 9-year-old boy, a known case of seizure since birth on clobazam and sodium valproate who had a VP shunt

for congenital hydrocephalus when he was 3 months old. He underwent three times' shunt revision, the last of which was performed when he was 3.5 years old due to shunt infection. The patient was admitted here with the chief complaint of abdominal distension and malaise. On examination, the patient was lethargic with slight fever. The abdomen was markedly distended without tenderness and normal bowel sound. Ultrasonography revealed severe free fluid in the abdominal pelvic cavity. Abdominal pelvic computed tomography (CT) showed an enlarged loculated cyst in the abdominal cavity with pressure effect on the bowel loops and displacement of them to the posterior part [Figures 1-3]. The tip of the VP shunt is noted in the peritoneal cavity. Shunt tap and CSF analysis was done. The CSF was clear with protein: 10 mg/dL and glucose 57 mg/dL. CSF Gram stain revealed no organism and the culture was negative. The leukocyte and erythrocyte counts were 0 and 150, respectively. The patient underwent laparotomy and cyst drainage was done with removal of the cyst wall; then, the VP shunt was placed into

**Address for correspondence:** Dr. Mohammad Sadegh Masoudi, Department of Neurosurgery Office, Namazi Hospital, Namazi Square, Shiraz, Iran. E-mail: masoodims@gmail.com

This is an open access journal, and articles are distributed under the terms of the Creative Commons Attribution-NonCommercial-ShareAlike 4.0 License, which allows others to remix, tweak, and build upon the work non-commercially, as long as appropriate credit is given and the new creations are licensed under the identical terms.

**For reprints contact:** reprints@medknow.com

**How to cite this article:** Masoudi MS, Rasafian M, Naghmehsanj Z, Ghaffarpassand F. Intraperitoneal cerebrospinal fluid pseudocyst with ventriculoperitoneal shunt. Afr J Paediatr Surg 2017;14:56-8.

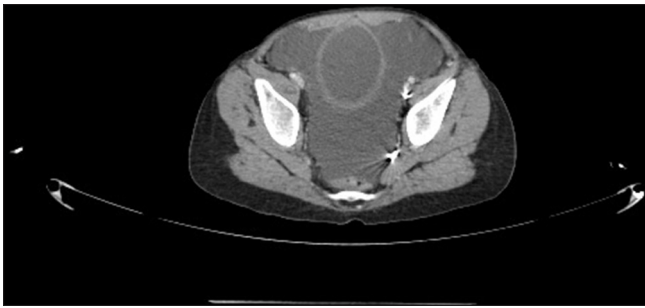
### Access this article online

#### Quick Response Code:

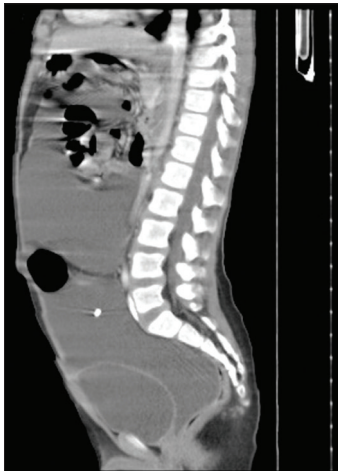

**Website:**  
www.afripaedurg.org

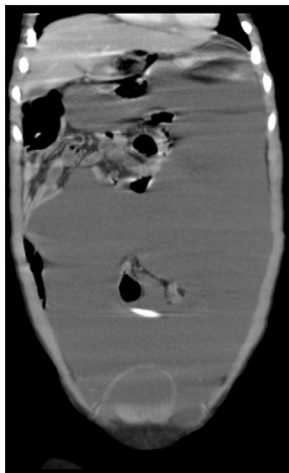
**DOI:**  
10.4103/ajps.AJPS\_94\_16



**Figure 1:** Axial section of abdominopelvic computed tomography scan with intravenous and oral contrast showing nonenhanced simple cyst



**Figure 2:** Sagittal section of abdominopelvic region showing a large simple cyst that filled whole of the abdominopelvic cavity and causing abdominal distension



**Figure 3:** Coronal section of abdominopelvic computed tomography scan that filled with a large simple cyst and with the tip of shunt catheter in it

the other side of the peritoneal cavity. Abdominal fluid was clear with leukocyte 3, segment: 2, lymphocyte: 1, protein: 1.2, glucose: 99, and negative culture on Gram stain. We observed recollection of the APC, two months after open marsupialization of the cyst by the paediatric surgeon. Thus the site of the catheter was changed from the peritoneal cavity

to the pleural cavity. No more symptoms were recorded and the patient was symptom-free at 6-month follow-up.

## DISCUSSION

VP shunting may result in many complications such as mechanical VP shunt failure, infection, and abdominal complications. Abdominal complications include bowel obstruction and perforation, peritonitis, volvulus, ileus, and APC.<sup>[8,9]</sup> APC is an uncommon complication of VP shunt.<sup>[10]</sup> The pathogenesis of CSF pseudocysts is still controversial. Low-grade shunt infections, chronic inflammation, multiple shunt revision, peritoneal adhesion, increased CSF protein content, malabsorption of CSF secondary to subclinical peritonitis, silicon allergy, etc., are the predisposing factors for CSF pseudocyst formation, but the pathophysiology is still unknown.<sup>[11]</sup>

The diagnosis of APC depends on the detailed history taking and a high index of suspicion. Ultrasonography and CT scan are the principal diagnostic imaging techniques that help the physicians reach a definite diagnosis. Sonography is an easy way for rapid and reliable diagnosis of APC. Sonographic findings may show a sonolucent mass without septation, the so-called railroad sign. CT scan indicates a definitive diagnosis of abdominal CSF pseudocysts, especially when abdominal pseudocysts are not defined by ultrasonography. The imaging criteria for the diagnosis of APC include a large fluid-filled collection delimited by a thin wall adjacent to the catheter tip and without septation.<sup>[1,7,12]</sup> The most common differential diagnoses of abdominal cystic mass are abdominal abscess, mesenteric cyst, benign cystic lymphangioma, cystic spindle cell tumor, pancreatic pseudocysts, and duplication cyst.<sup>[7,13]</sup> Surgical treatment options include laparotomic or laparoscopic-assisted fluid drainage with or without wide excision of the APC walls, removal of shunt/shunt externalization and placement of shunt catheter in different abdominal quadrants, or conversion to either a ventriculoatrial or ventriculopleural system.<sup>[13]</sup>

## CONCLUSION

Abdominal CSF pseudocysts are an uncommon but important complication of VP shunt, so early diagnosis and treatment of APC would improve the clinical outcome. Close clinical and radiographic follow-up for recurrent APC or shunt malfunction is recommended.

### Informed patient consent

The patient's guardians have consented to submission of this case report to the journal.

### Declaration of patient consent

The authors certify that they have obtained all appropriate patient consent forms. In the form, the patient has given his consent for his images and other clinical information to be reported in the journal. The patient understand that name and initials will not be published and due efforts will be made to conceal identity, but anonymity cannot be guaranteed.

## Acknowledgment

The authors would like to thank Shiraz University of Medical Sciences, Shiraz, Iran and also Center for Development of Clinical Research of Nemazee Hospital and Dr. Nasrin Shokrpour for editorial assistance.

## Financial support and sponsorship

Nil.

## Conflicts of interest

There are no conflicts of interest.

## REFERENCES

1. Xu H. New concept of the pathogenesis and therapeutic orientation of acquired communicating hydrocephalus. *Neurol Sci* 2016;37:1387-91.
2. Stagno V, Navarrete EA, Mirone G, Esposito F. Management of hydrocephalus around the world. *World Neurosurg* 2013;79:S23.e17-20.
3. Chung JJ, Yu JS, Kim JH, Nam SJ, Kim MJ. Intraabdominal complications secondary to ventriculoperitoneal shunts: CT findings and review of the literature. *AJR Am J Roentgenol* 2009;193:1311-7.
4. Dabdoub CB, Dabdoub CF, Chavez M, Villarreal J, Ferrufino JL, Coimbra A, *et al.* Abdominal cerebrospinal fluid pseudocyst: A comparative analysis between children and adults. *Childs Nerv Syst* 2014;30:579-89.
5. Rainov N, Schobess A, Heidecke V, Burkert W. Abdominal CSF pseudocysts in patients with ventriculo-peritoneal shunts. Report of fourteen cases and review of the literature. *Acta Neurochir (Wien)* 1994;127:73-8.
6. Salomão JF, Leibinger RD. Abdominal pseudocysts complicating CSF shunting in infants and children. Report of 18 cases. *Pediatr Neurosurg* 1999;31:274-8.
7. Wang B, Hasadsri L, Wang H. Abdominal cerebrospinal fluid pseudocyst mimicking full-term pregnancy. *J Surg Case Rep* 2012;2012:6.
8. Gomutbutra T. Large lower abdominal cerebrospinal fluid pseudocyst 6 years after a ventriculoperitoneal shunt: Clinical features and surgical management. *Chiang Mai Med J* 2010;43:169-73.
9. Leung GK. Abdominal cerebrospinal fluid (CSF) pseudocyst presented with inferior vena caval obstruction and hydronephrosis. *Childs Nerv Syst* 2010;26:1243-5.
10. Tamura A, Shida D, Tsutsumi K. Abdominal cerebrospinal fluid pseudocyst occurring 21 years after ventriculoperitoneal shunt placement: A case report. *BMC Surg* 2013;13:27.
11. Ohba S, Kinoshita Y, Tsutsui M, Nakagawa T, Shimizu K, Takahashi T, *et al.* Formation of abdominal cerebrospinal fluid pseudocyst. *Neurol Med Chir (Tokyo)* 2012;52:838-42.
12. Sena FG, Sousa RM, Meguins LC. Abdominal cerebrospinal fluid pseudocyst: A complication of ventriculoperitoneal shunt in a Brazilian Amazon woman. Case report. *G Chir* 2010;31:371-3.
13. Yuh SJ, Vassilyadi M. Management of abdominal pseudocyst in shunt-dependent hydrocephalus. *Surg Neurol Int* 2012;3:146.