



Case Report

External sinus lifting using calcium sulphate as a bone grafting in an adult male patient: Case report



Mohey Aldeen Amam^a, Anas Abdo^b, Amirah Alnour^{c,*}, Ammam Ammam^d, Majd Mohrez^a, Mohamad Hassan Jafo^a

^a Oral and Maxillofacial Surgery Department, Damascus University, Faculty of Dentistry, Syria

^b Endodontic Department, Damascus University, Faculty of Dentistry, Syria

^c Oral Pathology, Head Department of Oral Pathology Department in Damascus University, Faculty of Dentistry, Syria

^d Periodontology Department, Damascus University, Faculty of Dentistry, Syria

ARTICLE INFO

Keywords:

Sinus lifting
Calcium sulphate
Bone graft
Implantology
Case report

ABSTRACT

Introduction: and importance: Nowadays, dental implant is considered as a revolutionary method in teeth replacement. Occasionally, missing bone is seen in the area of missing teeth. Oral surgeons need to rebuild this are before implantology, which could be supported by using bone grafts. The practitioners face a problem in the maxilla because of its anatomy and the presence of maxillary sinus. In some cases, and after losing the bone, maxillary sinus needs to be lift before the implant is placed. Calcium sulphate (CS) is one of the promising methods as one of the biocompatible bone grafts.

Case presentation: A 30-year-old male patient was reported to the oral and maxillofacial surgery in Faculty of Dentistry, Damascus University. The main complaint was to replace missing teeth (teeth no: 26,27). The patient had no contraindication for surgery.

Clinical Findings and Investigations: intra-oral examination revealed a good oral hygiene with no other diseases either in bone or in the oral mucosa. Cone-beam computed tomography systems (CBCT) scan was done to determine the thickness of the remaining bone and the treatment plan was discussed with the patient.

Interventions and outcome: the treatment plan was to do external sinus lifting for the posterior left maxilla, using calcium sulphate as a graft and placing the implants after six months. Each procedure during surgical work was documented and monitored using CBCT. The follow-up and results were made by clinical measures as well CBCT to evaluate radiological bone-gain and bone reduction (two-year follow-up)

Relevance and impact: the use of calcium sulphate has tremendous benefit as biocompatible bone grafts in sinus lifting in order to gain bone before dental implantation. It may increase the bone gain which will improve the surgical site of the implant.

1. Introduction

Maxillary sinus pneumatization after teeth extraction may led to insufficient bone height in the posterior edentulous maxilla. Consequently, maxillary sinus grafting is considered as a unique methods to prepare the surgical set for implantation in this area [1]. External sinus lift, as well as internal sinus lift, can be used to increase the bone height in the posterior maxilla [2]. Calcium sulphate has been proposed as a biocompatible bone substitute that promotes a resorbable scaffold for bone growth. It undergoes complete resorption without inflammatory response, play as membrane due to the hardening and slow absorption

properties [2]. In this case report, we present a successful radiographic outcome (bone height gain) of external sinus lifting using calcium sulphate as a bone substitute in a young-male patient.

1.1. Importance

The importance of this case is that it highlights the tremendous benefit of using biocompatible bone grafts mainly the calcium sulphate in sinus lifting in order to gain bone before dental implantation. Moreover, in this case we clarified:

* Corresponding author.

E-mail address: dr.amieranour@gmail.com (A. Alnour).

<https://doi.org/10.1016/j.amsu.2022.104951>

Received 9 September 2022; Received in revised form 27 October 2022; Accepted 13 November 2022

Available online 17 November 2022

2049-0801/© 2022 The Authors. Published by Elsevier Ltd on behalf of IJS Publishing Group Ltd. This is an open access article under the CC BY-NC-ND license (<http://creativecommons.org/licenses/by-nc-nd/4.0/>).

- 1 Using this graft after sinus lifting enhanced the amount of bone gain without using any collagen membrane.
- 2 Using this graft as well, ensured the consistency of the sinus floor elevation and bone gain after 30 months of following up after lifting.
- 3 This bone graft is cheap and gives us more stability after the surgical intervention.

1.2. Case presentation

1.2.1. Clinical history and patient information

A non-smoker 30-year-old male patient was reported to the oral and maxillofacial surgery in Faculty of Dentistry, Damascus University. The main complaint was to replace missing teeth (teeth no: 26,27) with a fixed prosthesis. Intraoral examination revealed presence of two units fixed zirconia crowns restoration on teeth no: 15, 16 and amalgam restoration on tooth no 17. The patient had no contraindication for surgery. Thorough presurgical intraoral assessment for gingival health, interocclusal space and bone tomography was done. Cone-beam computed tomography systems (CBCT) scan was done and it revealed

the residual bone height and width was (4.1) mm and (5.1) mm in 26; (3.9) mm and (8.7) mm in 27 regions respectively (Fig. 1A and B). Treatment plan was discussed with the patients. It included external sinus lifting for the posterior left maxilla (area of missing teeth) using calcium sulphate and placing the implants after six months. The patient was scheduled for the surgical procedures; grafting in the first appointment and the dental implants were placed six months later. Each procedure during surgical work was documented and monitored using CBCT. The follow-up and results were made by clinical measures as well CBCT to evaluate radiological bone-gain and bone reduction. Patient had no history of any systemic disease and he had not undergone any surgical intervention before. No allergic contact was reported. Family history revealed no systemic or inherited disease.

We got ethical approval from the scientific committee in Faculty of Dentistry in Damascus University to accomplish this case (No: 092022135). A written informed consent was obtained from the patient for publication of this case report and accompanying images. This case has been performed in line with SCARE 2020 criteria [13].

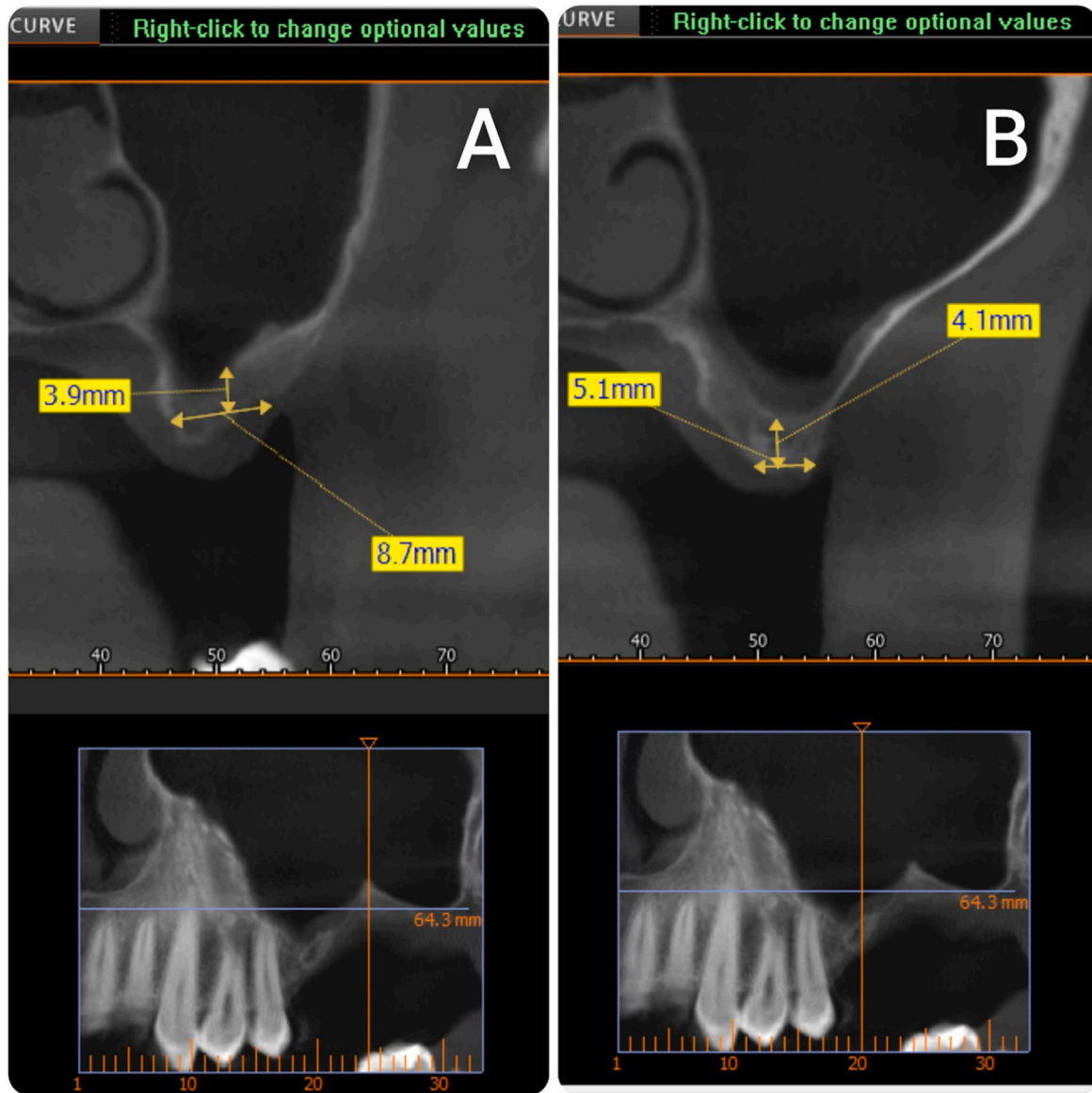


Fig. 1. Preoperative Alveolar Bone Height and Width (A) in 26 region (B) in 27 region.

1.2.2. Surgical procedures

First stage:

A cone-beam computed tomography (CBCT) radiograph was done before the surgical procedure (T0).

Dental scaling was performed two or three days' prior the surgery.

Livofloxacin 750 mg tab was prescribed 24 hours' prior the surgery and 9 days' post-surgery.

Second stage:

The mouth was disinfected with 0.12% chlorhexidine rinses, the skin around the mouth was disinfected with polyvidone iodine solution, and the surgical area was isolated using sterile surgical scrubs.

Local (buccal and palatal) anesthesia was performed using Lidocaine HCL 2% + Epinephrine 1:80,000.

A trapezoid-shaped, full-thickness mucoperiosteal buccal flap was performed (Fig. 2).

A bony window with rounded corners was performed (to reduce the occurrence of perforation during lifting) with dimensions of 13 mm in length and 10 mm in height according to the dimensions of the area to be grafted. And it was done by a piezo-surgery device with appropriate irrigation with saline (the CBCT radiograph helps to know the thickness of the bony window and thus facilitates the process of its preparation), So that its lower edge rises 2–3 mm above the bottom of the maxillary sinus, and a sufficient window facilitates vision, work and reduces the tension of the sinus membrane in the initial lifting, but the window should not be enlarged much because the surrounding walls help in bone healing (Fig. 2).

Elevating the sinus membrane was done by sinus lift tools (DASK kit) (Fig. 3).

Grafting of the maxillary sinus by CS graft (Fig. 4), without using membranes at all, as we add the catalyst to the CS graft to fast harden [3].

Interrupted Suturing was done with Proline sutures with reverse cutting needle (0/4) (Fig. 5).

The patient had post-surgery instructions and a medical prescription. Then he was scheduled to remove the sutures 10 days after surgery.

CBCT (radiograph was performed for the patient immediately post-

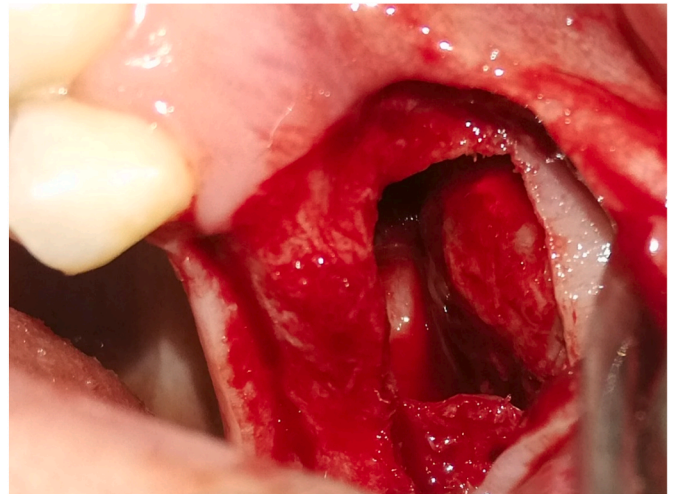


Fig. 3. Elevating the sinus membrane

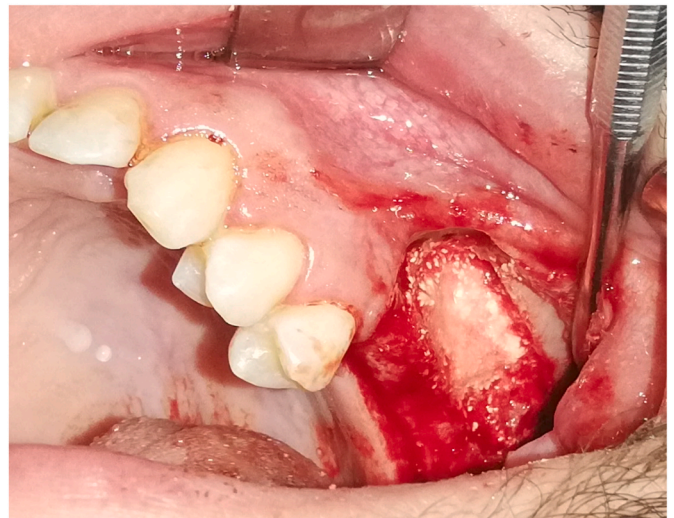


Fig. 4. Filling the space created by raising the maxillary sinus with CS grafts.

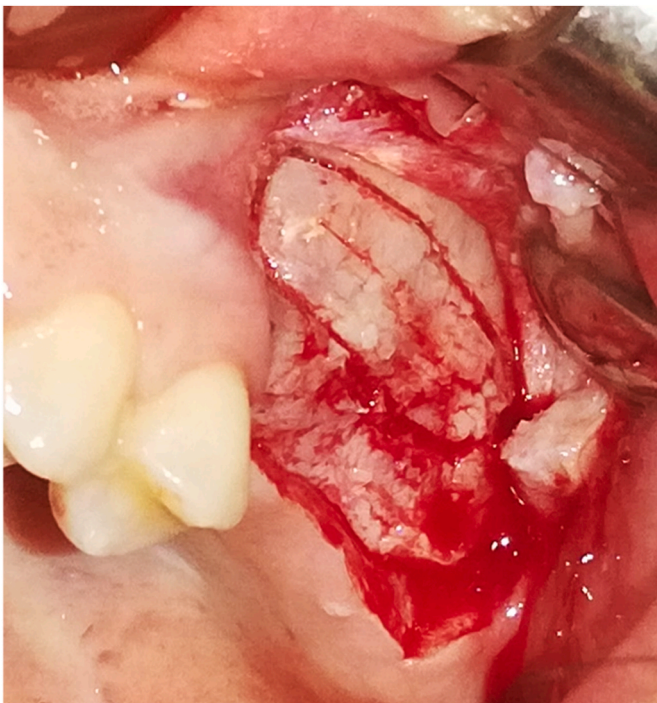


Fig. 2. Image showing the elevation of the full-thickness flap and the bony window prepared with the appropriate dimensions.

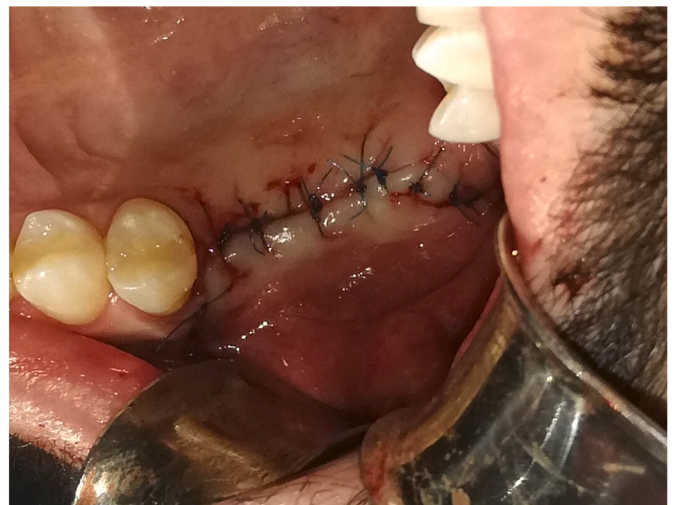

Fig. 5. Wound closure using Proline sutures.

surgery(T1) to evaluate the bone height and six months post-op (T2) that is, before the second surgical operation (implantation) (Fig. 7).

To ensure that we are studying the same points we use (ondemand3d) program, which allows setting the same points on the merged images (Fig. 6).

The following measurements were calculated: the bone height immediately after surgery, bone gain and the bone reduction after 6 months, where we have two equations:

1. Bone gain = bone height after six months(T2) - bone height before lifting (T0).
2. Bone reduction represents the height of the bone and the graft immediately after lifting (T1) - the height of the bone after six months(T2).

2. Results

The average bone height before surgery was (3.61 ± 1.63)mm [T0], then the bone height became with the size of the graft Immediately after work (17.74 ± 2.54) mm [T1], and decreased after 6 months to (15.29 ± 1.44) mm [T2], which is the mean and the rate of bone gain was (11.67) mm, 82.63% respectively, and the mean and the rate of reduction was (2.45) mm, 17.36% respectively. Another follow-up CBCT was required to ensure the healing and the success of the bone grafting and the dental implant as well. So two years later after the implantation, other measures were obtained on CBCT, that revealed no more graft materials and full tissue healing (Fig. 8).

3. Clinical Discussion

The maxillary sinus lifting is a good evolving procedure and is well required nowadays to increase the bone height for dental implants [4]. Several studies have investigated the efficacy of many bone grafts in sinus lifting, although Autogenous bone grafts are considered the gold standard for other types of bone grafts, however, the additional surgical site which created to obtain the autograft increases the time of the procedure and cause more pain to the patient [2]. This has led to increasing interest in the search for alternative biocompatible materials for these grafts [5]. The (CS) graft is available, easy to use and helps to reduce surgical costs compared with other bone substitutes. It can be used without absorbable and non-absorbable membranes [2].

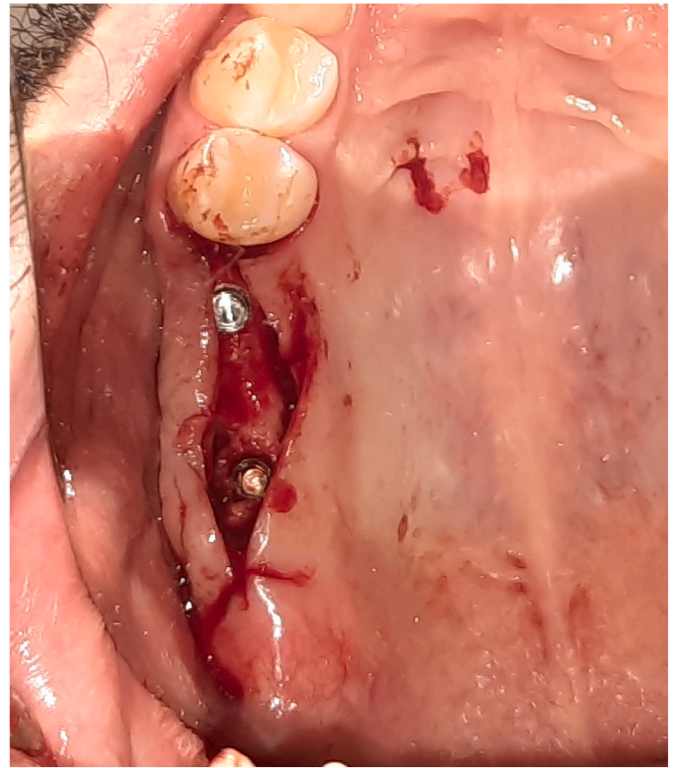

Fig. 7. Placement of implants in 26 and 27 region months after the sinus lift (T2).

In this case, the patient 30-year-old male had left posterior edentulous in maxillary, did not suffer from systemic diseases affecting the surgical procedure, and did not suffer from health problems in the nose and sinuses, which are considered a contraindication for sinus lifting.

The lateral approach technique to lift the maxillary sinus was followed because this method is indicated in cases of elevating the maxillary sinus of class SA4 [6], in addition to the fact that the success rate of implants in the two-stage method is higher than in the One-stage technique in cases of SA4 class [7].

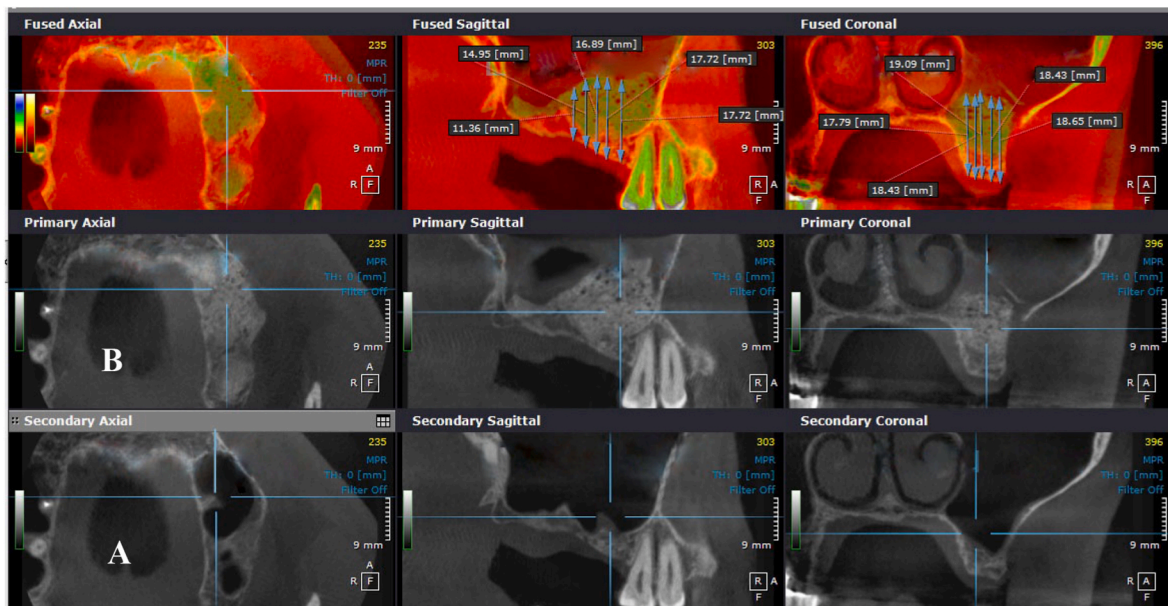


Fig. 6. Shows merged images using (ondemand3d) program A, pre-surgery (T0); B, 6.

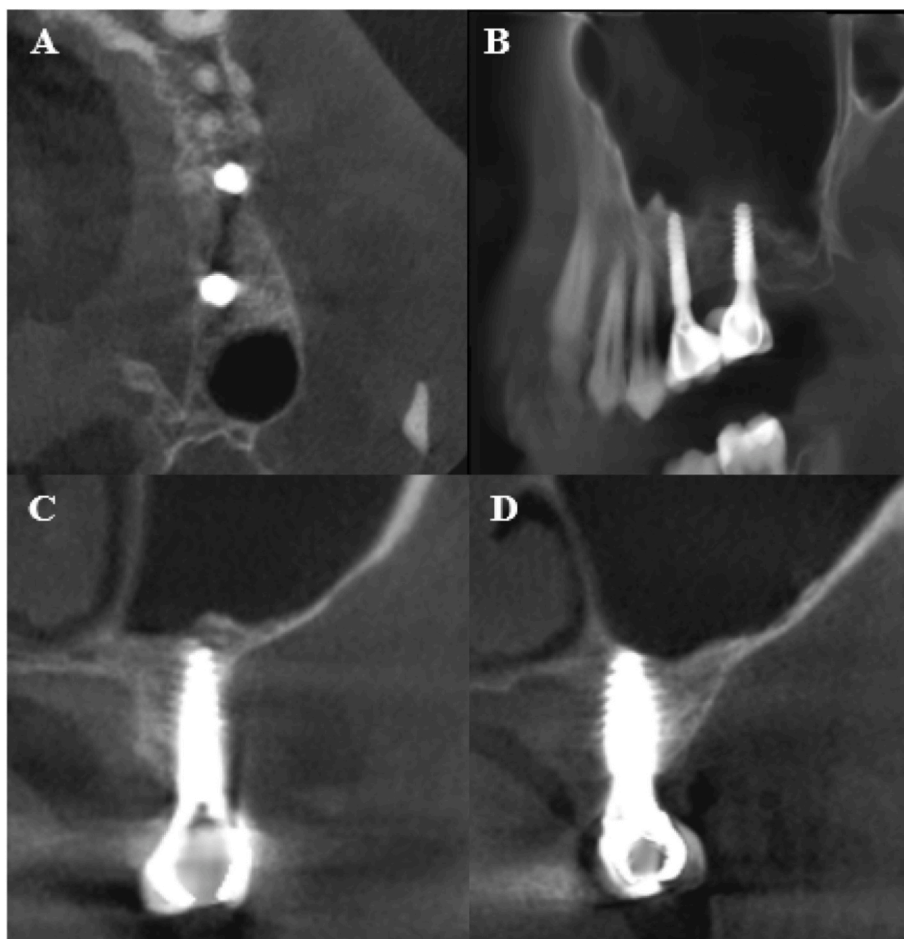


Fig. 8. Shows bone height 2.5 years after lifting and implant 2 years after implantation in 26 and 27 regions in CBCT images, C, and D, respectively. The graft material is no longer detectable and the new sinus floor is visible.

Ultrasonic was used in window preparation in our study and other studies [8], which reduces the incidence of perforation of the maxillary sinus membrane from 25% in rotary instruments to 7%, and reduces pain, discomfort and edema after surgery, and in general it helps to protect soft tissues [9].

The radiological study was done by using CBCT images, the first pre-op (T0) and the second immediate post-op (T1), and the third six months post-op (T2), to study the bone gain and bone reduction that occurs in the grafted area [10].

The use of CS is useful and safe in the procedures of external maxillary sinus lifting in two stages, as sufficient amount of bone was obtained to place dental implants after 6 months, where the average bone height before surgery (3.61 ± 1.63) [T0], then the bone height became with the size of the graft immediately after work (17.74 ± 2.54) [T1], and decreased after 6 months to (15.29 ± 1.44) [T2], which is the amount of gain (11.67) and the reduction amount was (2.45).

This was reported in other studies [2,11], and the study of Guarnieri et al. reported that the CS graft promotes the stability of implants and the formation of new bone around them after its absorption. However, the mean value for T0 was (6.5 ± 1.2) mm, the mean value for T1 was (16.5 ± 0.5) mm, and the mean value for T2 was (14.5 ± 1.0) mm. The volume of grafted material showed an average reduction of 2 mm² (range, 1.0–3.5 mm²) [3].

In 2012, Dasmah et al. evaluated CS as bone graft substitute in sinus floor augmentation for 10 patients received maxillary sinus elevation using CS as a grafting material and the grafted site was covered with resorbable membrane. Radiographs were taken at the time of sinus augmentation and after 4 months of graft healing. The findings of this

study revealed that the rate of reduction was 26.5% of the augmented area [12].

4. Conclusions

The use of calcium sulphate (CS) is useful and safe in two-stage-maxillary sinus lifting procedure. A sufficient amount of bone was obtained within dental implantation.

Statements

- We prepared this case report in accordance with SCARE 2020 [13].
- Written informed consent was obtained from the patient for publication of this case report and accompanying images. A copy of the written consent is available for review by the Editor-in-Chief of this journal on request.
- We got ethical approval from the scientific committee in Faculty of Dentistry in Damascus University to accomplish this case (No: 092022135).
- The guarantor of is work is the corresponding author (dr. Amirah Alnour)
- This work is not commissioned and externally peer-reviewed.

Ethical approval

We got the ethical approval from the scientific committee in faculty of dentistry, Damascus University.

Sources of funding

This research was done under supervision of Damascus University.

Author contribution

Mohey Aldean Ammam: doing the surgery, writing the manuscript.
Anas Abdo: assist in the surgery and monitoring the radiologic images.

Amirah Alnour: critical review to the manuscript.

Ammam Amma: assist in the writing the manuscript.

Majd Mohrez: assist in the surgery.

Hassan Jaffo: supervising the surgical and clinical steps.

Conflicts of interest

The authors declare that they have no conflict of interest.

Registration of research studies

1. Name of the registry:
2. Unique Identifying number or registration ID:
3. Hyperlink to your specific registration (must be publicly accessible and will be checked):

Guarantor

Amirah Alnour.

Consent

We got a written consent from the patient to publish this case.

Appendix A. Supplementary data

Supplementary data related to this article can be found at <https://doi.org/10.1016/j.amsu.2022.104951>.

References

- [1] M. Sorni, J. Guarinos, O. García, M. Peñarocha, Implant rehabilitation of the atrophic upper jaw: a review of the literature since 1999, *Med. Oral, Patol. Oral Cirugía Bucal* 10 (2005) E45–E56.
- [2] A.S. Almutairi, Calcium sulfate as a bone grafting material in sinus lift augmentation—A literature review, *Journal homepage: www.nacd.in Indian J. Dent. Adv.* 12 (2) (2021) 53–60.
- [3] R. Guarnieri, R. Grassi, M. Ripari, G. Pecora, Maxillary sinus augmentation using granular calcium sulfate (surgiplaster sinus): radiographic and histologic study at 2 years, *Int. J. Periodontics Restor. Dent.* 26 (1) (2006).
- [4] S.C. Bathla, R.R. Fry, K. Majumdar, Maxillary sinus augmentation, *J. Indian Soc. Periodontol.* 22 (6) (2018) 468.
- [5] W. Bouwman, N. Bravenboer, J. Frenken, C. Ten Bruggenkate, E. Schulten, The use of a biphasic calcium phosphate in a maxillary sinus floor elevation procedure: a clinical, radiological, histological, and histomorphometric evaluation with 9-and 12-month healing times, *Int. J. Clin. Implant Dent.* 3 (1) (2017) 1–9.
- [6] C.E. Misch, M.L. Perel, H.-L. Wang, et al., Implant success, survival, and failure: the International Congress of Oral Implantologists (ICOI) pisa consensus conference, *Implant Dent.* 17 (1) (2008) 5–15.
- [7] K. Wannfors, B. Johansson, M. Hallman, T. Strandkvist, A prospective randomized study of 1-and 2-stage sinus inlay bone grafts: 1-year follow-up, *Int. J. Oral Maxillofac. Implants* 15 (5) (2000).
- [8] N.V. Doan, T.Q. Huynh, S. Tran, et al., Multidisciplinary approach to maximize angiogenesis and wound healing using piezoelectric surgery, concentrated growth factors and photobiomodulation for dental implant placement surgery involving lateral wall sinus lift: two case reports, *Vascular* 12 (1) (2020) 2.
- [9] M. Al-Dajani, Recent trends in sinus lift surgery and their clinical implications, *Clin. Implant Dent. Relat. Res.* 18 (1) (2016) 204–212.
- [10] Y. Oba, N. Tachikawa, M. Munakata, T. Okada, S. Kasugai, Evaluation of maxillary sinus floor augmentation with the crestal approach and beta-tricalcium phosphate: a cone-beam computed tomography 3-to 9-year follow-up, *Int. J. Clin. Implant Dent.* 6 (1) (2020) 1–10.
- [11] L. Laino, G. Troiano, G. Giannatempo, et al., Sinus lift augmentation by using calcium sulphate. A retrospective 12 months radiographic evaluation over 25 treated Italian patients, *Open Dent. J.* 9 (2015) 414.
- [12] A. Dasmah, M. Hallman, L. Sennerby, L. Rasmusson, A clinical and histological case series study on calcium sulfate for maxillary sinus floor augmentation and delayed placement of dental implants, *Clin. Implant Dent. Relat. Res.* 14 (2) (2012) 259–265.
- [13] R.A. Agha, T. Franchi, C. Sohrabi, et al., The SCARE 2020 guideline: updating consensus surgical CAsE REport (SCARE) guidelines, *Int. J. Surg.* 84 (2020) 226–230.