



ELSEVIER

Contents lists available at [ScienceDirect](https://www.sciencedirect.com)

## Trauma Case Reports

journal homepage: [www.elsevier.com/locate/tcr](http://www.elsevier.com/locate/tcr)

## Case Report

## Laparoscopic treatment for colonic injuries following penetrating trauma: A feasible option in a surgical department of Sub-Saharan Africa

Abdourahmane Ndong<sup>a,\*</sup>, Adja Coumba Diallo<sup>a</sup>, Mohamed Lamine Diao<sup>a</sup>, Jacques Noel Tendeng<sup>a</sup>, Ndiame Sarr<sup>b</sup>, Ismael Bayo Racine<sup>a</sup>, Jacques Diounda Diatta<sup>a</sup>, Saer Diop<sup>a</sup>, Modou Gaye<sup>a</sup>, Moustapha Diedhiou<sup>b</sup>, Philippe Manyacka Ma Nyemb<sup>a</sup>, Ibrahima Konaté<sup>a</sup>

<sup>a</sup> Department of Surgery, Saint-Louis Regional Hospital, Gaston Berger University, Senegal

<sup>b</sup> Department of Anesthesiology, Saint-Louis Regional Hospital, Gaston Berger University, Senegal

## ARTICLE INFO

**Keywords:**  
Laparoscopy  
Trauma  
Abdomen  
colon

## ABSTRACT

**Introduction:** The management of abdominal penetrating trauma remains complex. Between the risk of negative laparotomy and missed visceral injury, laparoscopy is a good alternative. We report 2 cases of abdominal penetrating trauma with colonic injury diagnosed and treated with laparoscopic approach.

**Observations:** The first patient was 15 years old, with no medical history and received at 3 h of a penetrating trauma by stabbing. Hemodynamic status was normal. An exploratory laparoscopy was performed. It objectified a penetration of the peritoneum on the left flank with an injury of the anti-mesenteric edge of the descending colon that was sutured. The second patient was 20 years old, with no history, who had a penetrating trauma of the left iliac fossa by stabbing. Arterial pressure was normal. He was received 6 h after the trauma. An exploratory laparoscopy objectified an injury of 2 cm located at the sigmoid colon which was sutured with a good evolution.

**Conclusion:** Laparoscopy in abdominal wounds is a good option in selected patients. It has a diagnostic and therapeutic importance in colonic injuries. The limits are represented by the possibility of unrecognized visceral lesions that can lead to additional morbidity.

## Introduction

The management of abdominal penetrating trauma remains complex. Between the risk of negative laparotomy and missed visceral injury, laparoscopy is a good alternative [1]. Laparoscopy evaluates the existence of peritoneal breach and the need for surgery in therapeutic purposes. It can treat intestinal lesions when they are non-destructive. Colonic lesions account for nearly half of intestinal lesions in penetrating abdominal wounds [2]. In low resources setting, laparoscopy can help to optimize the diagnostic and therapeutic management of surgical emergencies [3]. We report 2 cases of abdominal penetrating trauma with colonic injury diagnosed and

\* Corresponding author at: BP: 234, Nationale 2, Route de Ngallele, Department of Surgery, Gaston Berger University, Saint-Louis, Senegal.  
E-mail address: [abdourahmane.ndong@ugb.edu.sn](mailto:abdourahmane.ndong@ugb.edu.sn) (A. Ndong).

<https://doi.org/10.1016/j.tcr.2022.100708>

Accepted 2 October 2022

2352-6440/© 2022 The Authors. Published by Elsevier Ltd. This is an open access article under the CC BY-NC-ND license (<http://creativecommons.org/licenses/by-nc-nd/4.0/>).

treated with laparoscopic approach.

## Observations

### Case 1

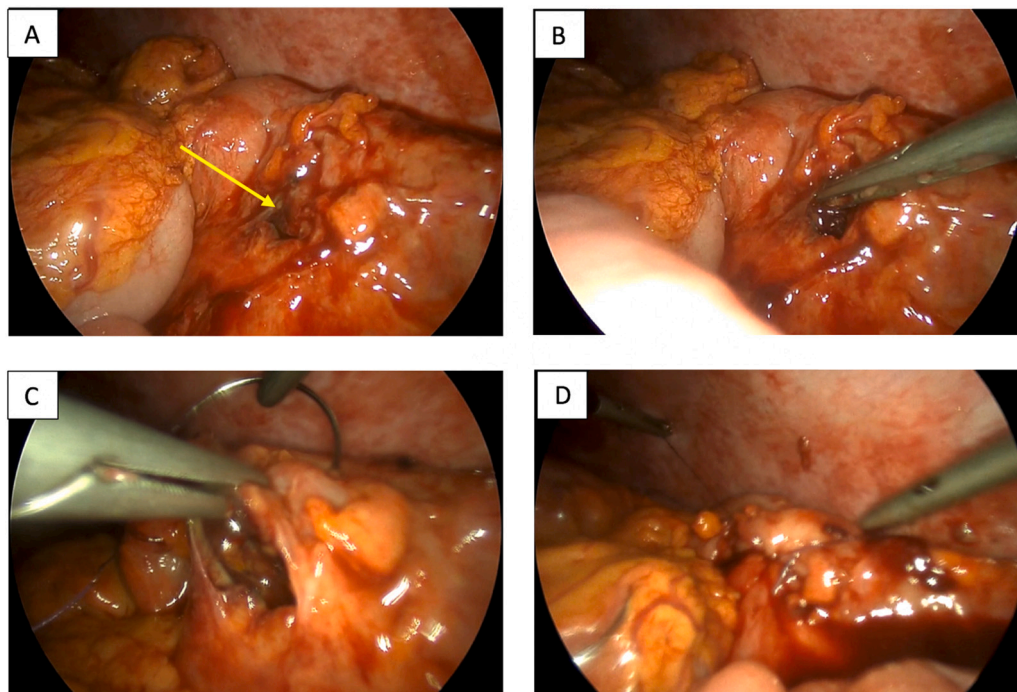
It was 15 years old, with no medical history and received at 3 h of a penetrating trauma by stabbing. Hemodynamic status was normal. The physical examination showed 2 wounds located at the left flank without evisceration. There was a periumbilical and supra pubic tenderness. Biology showed a leukocytosis at 12,000 elements/mm<sup>3</sup> and a hemoglobin rate at 11.2 g/dl. During the monitoring in hospital, the patient presented a persistent abdominal tenderness and the occurrence of vomiting. An exploratory laparoscopy was performed. It objectified a penetration of the peritoneum on the left flank with an injury of the anti-mesenteric edge of the descending colon with a moderate hemoperitoneum. This lesion was classified as Grade II according to Moore classification (Laceration of less than 50 % of the circumference). The hemoperitoneum was aspirated. The wound was sutured with 2 separate stitches with absorbable suture, followed by drainage (Fig. 1). The postoperative course was marked by a low-output fistula that evolved well after 72 h. The length of hospital stay was 5 days.

### Case 2

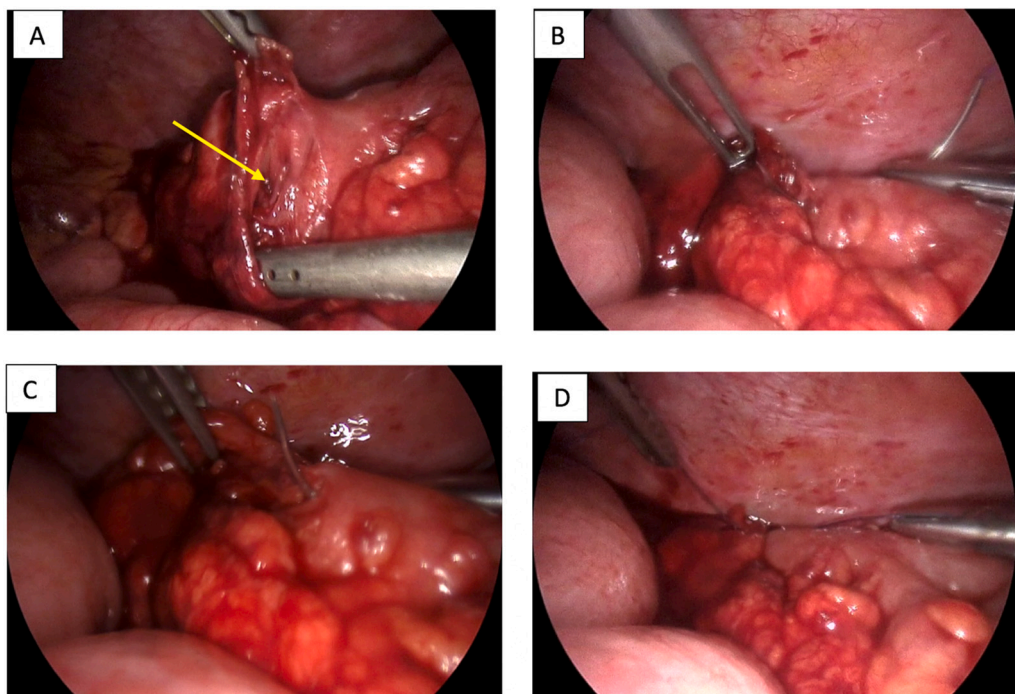
It was a 20-year-old patient, with no medical history and received at 3 h of a penetrating trauma by stabbing. Arterial pressure was normal. He was received 6 h after the trauma. The examination found a 2 cm wound without evisceration associated with hypogastric tenderness and 2 episodes of vomiting. Biology found leukocytosis at 13,000 elements/mm<sup>3</sup>. An exploratory laparoscopy revealed an injury of 2 cm in the sigmoid colon with a small amount of hemoperitoneum classified as Grade II according to Moore classification (laceration of less than 50 % of the circumference). A suture with 2 stitches after aspiration was performed (Fig. 2). The postoperative course was uneventful, and the length hospital stay as 6 days.

## Discussion

Laparoscopy is superior to laparotomy in terms of reduction of postoperative pain, length of hospital stay, surgical site infections and peritoneal adhesions [4,5]. A study comparing the two approaches for the treatment of hollow viscus injuries in abdominal



**Fig. 1.** Intraoperative images of a colonic injury (patient 1).  
A: Laceration of the descending colon at the anti-mesenteric border with less than 50 % of the circumference (Grade II) (arrow).  
B: Laceration of the descending colon at the anti-mesenteric edge.  
C: Beginning of wound suturing with absorbable suture.  
D: Finalization of the suture.



**Fig. 2.** Intraoperative images of a colonic injury (patient 2).  
 A: Laceration of the sigmoid colon at the anti-mesenteric border with less than 50 % of the circumference (Grade II) (arrow).  
 B: Beginning of wound suturing with absorbable suture (1).  
 C: Beginning of wound suturing with absorbable suture (2).  
 D: Finalization of the suture.

trauma, on nearly 4000 patients, concluded that laparoscopy was superior in terms of postoperative complications [6].

In addition to the diagnostic importance, it allows to suture the intestinal lesions.

However, it must respect strict rules such as the exhaustive exploration of the peritoneal cavity, particularly the need to examine the entire small intestine to look for injuries [2]. When colonic lesions are suspected, mobilizing the colon is recommended to exclude a posterior extraperitoneal perforation. Indeed, a recent systematic review showed a 3.2 % rate of unrecognized intestinal lesions during penetrating trauma explored by laparoscopy [7].

In addition, laparoscopy should be reserved for selected patients, without hemodynamic disorders or associated cranio encephalic trauma, in order not to increase the rate of complications [8]. Besides, in the context of trauma, pneumoperitoneum can have a negative effect that can maintain Moore's triad [9]. When the expertise exists without hemodynamic instability, therapeutic laparoscopy is an acceptable option for penetrating abdominal trauma.

We used laparoscopy in our patients because they were young, without any comorbidity and hemodynamically stable.

Recommendations suggest that laparoscopy in abdominal penetrating trauma when the initial evaluation (clinical and imaging) is borderline. Laparoscopy can help to look for a peritoneal breach in order to adequately choose surgical or non-operative treatment [10].

The treatment of colonic perforations during abdominal trauma is essentially based on the degree of the colon circumference injured [11,12]. Hence, 2 groups of colonic lesions have been defined. Firstly, there are non-destructive lesions (interesting less than 50 % of the circumference without meso vascular lesion); and secondly, destructive lesions involving more than 50 % of the circumference with meso vascular lesion [2]. Non-destructive lesions are treated by primary suture and destructive ones by resection followed by anastomosis or stoma [2,13]. In our patients, since lesions were classified Grade II, the primary suture was performed with good evolution. A recent Cochrane review showed that primary suture is superior to colostomy in small traumatic colonic lesions [14].

## Conclusion

Laparoscopy in abdominal penetrating trauma is a good option in selected patients. It has a diagnostic and therapeutic importance in colonic injuries. The limits are represented by the possibility of unrecognized visceral lesions that can lead to additional morbidity. The decision to perform a laparoscopy considers the experience of the teams and the available resources.

## Sources of funding

The authors declare they have received no funding for the preparation of this document.

## Ethical approval

The ethical committee of the hospital gave the agreement to report this Case.

## Consent

Written informed consent was obtained from the patient for publication of this Case report and accompanying images.

## CRediT authorship contribution statement

Conception and design of the study: A Ndong, A C Diallo, M Gaye, JN Diatta,  
Drafting the article: A Ndong, A C Diallo, N Sarr, I B Racine, S Diop, M Diedhiou,  
Final approval: M L Diao, J N Tendeng, P M Ma Nyemb, Ibrahima Konaté.

## Declaration of competing interest

The authors declare no conflict of interest.

## Acknowledgements

None.

## References

- [1] S. Uranues, D.E. Popa, B. Diaconescu, R. Schrittwieser, Laparoscopy in penetrating abdominal trauma, *World J. Surg.* 39 (2015) 1381–1388, <https://doi.org/10.1007/s00268-014-2904-5>.
- [2] R. Yamamoto, A.J. Logue, M.T. Muir, Colon trauma: evidence-based practices, *Clin. Colon Rectal Surg.* 31 (2018) 11–16, <https://doi.org/10.1055/s-0037-1602175>.
- [3] A. Ndong, M. Diao, J. Tendeng, O. Thiam, A. Diallo, A. Diouf, et al., Limitations and challenges of laparoscopic surgery in a low-income country: example of the Gaston Berger Teaching Hospital of Saint-Louis (Senegal), *J. Surg. Simul.* (2021) 14–17, <https://doi.org/10.1102/2051-7726.2021.0002>.
- [4] J. Wang, L. Cheng, J. Liu, B. Zhang, W. Wang, W. Zhu, et al., Laparoscopy vs. laparotomy for the management of abdominal trauma: a systematic review and meta-analysis, *Front. Surg.* 9 (2022), 817134, <https://doi.org/10.3389/fsurg.2022.817134>.
- [5] M.L. Cissé, A.O. Touré, J.N. Tendeng, M. Seck, M. Thiam, M.L. Guèye, et al., Apport de la laparoscopie devant les urgences abdominales au CHU A Le Dantec de Dakar, à propos de 144 cas, *J Coelio-chirurgie* 95 (2015) 1–4, n.d.
- [6] A. Litwin, A.P. Coulter, J. Romanelli, M. Tirabassi, Use of minimally invasive surgery for the management of hollow viscus traumatic injuries, *Surg. Endosc.* (2022), <https://doi.org/10.1007/s00464-022-09102-3>.
- [7] E. O'Malley, E. Boyle, A. O'Callaghan, J.C. Coffey, S.R. Walsh, Role of laparoscopy in penetrating abdominal trauma: a systematic review, *World J. Surg.* 37 (2013) 113–122, <https://doi.org/10.1007/s00268-012-1790-y>.
- [8] J.P. Sharpe, L.J. Magnotti, T.C. Fabian, M.A. Croce, Evolution of the operative management of colon trauma, *Trauma Surg. Acute Care Open* 2 (2017), e000092, <https://doi.org/10.1136/tsaco-2017-000092>.
- [9] L.F. Cabrera-Vargas, M. Pedraza, F.A. Rincon, J.A. Pulido-Segura, A. Mendoza-Zuchini, D. Gómez, et al., Fully therapeutic laparoscopy for penetrating abdominal trauma in stable patients, 2022, <https://doi.org/10.1016/j.amjsurg.2021.07.008>.
- [10] L. Smyth, C. Bendinelli, N. Lee, M.G. Reeds, E.J. Loh, F. Amico, et al., WSES guidelines on blunt and penetrating bowel injury: diagnosis, investigations, and treatment, *World J. Emerg. Surg.* 17 (2022) 13, <https://doi.org/10.1186/s13017-022-00418-y>.
- [11] E.E. Moore, T.H. Cogbill, M.A. Malangoni, G.J. Jurkovich, H.R. Champion, T.A. Gennarelli, et al., Organ injury scaling, II: pancreas, duodenum, small bowel, colon, and rectum, *J. Trauma* 30 (1990) 1427–1429.
- [12] W.J. Choi, Management of colorectal trauma, *J. Korean Soc. Coloproctol.* 27 (2011) 166–172, <https://doi.org/10.3393/jksc.2011.27.4.166>.
- [13] M.D. Trust, C.V.R. Brown, Penetrating injuries to the colon and rectum, *Curr. Trauma Rep.* 1 (2015) 113–118, <https://doi.org/10.1007/s40719-015-0013-z>.
- [14] R. Nelson, M. Singer, Primary repair for penetrating colon injuries, *Cochrane Database Syst. Rev.* (2003), CD002247, <https://doi.org/10.1002/14651858.CD002247>.