



Case report

Rapidly progressive organizing pneumonia associated with COVID-19

Hiroshi Horii^a, Keisuke Kamada^{a,*}, Sho Nakakubo^a, Yu Yamashita^a, Junichi Nakamura^a, Yasuyuki Nasuhara^b, Satoshi Konno^a

^a Department of Respiratory Medicine, Faculty of Medicine and Graduate School of Medicine, Hokkaido University, North 15 West 7, Kita-ku, Sapporo, Hokkaido, 060-8638, Japan

^b Division of Hospital Safety Management, Hokkaido University Hospital, North 15 West 7, Kita-ku, Sapporo, Hokkaido, 060-8638, Japan



ARTICLE INFO

Keywords:

SARS-CoV-2

COVID-19

Organizing pneumonia

Corticosteroids

Krebs von den lungen 6 (KL-6)

Surfactant protein (SP-D)

ABSTRACT

We report a case of clinically diagnosed secondary organizing pneumonia (SOP) associated with coronavirus disease 2019 (COVID-19). A 70-year-old woman who had been diagnosed with COVID-19 was admitted to Hokkaido University Hospital. Although her fever, cough, dyspnea, and serum C-reactive protein levels improved, she developed rapidly progressive respiratory failure and computed tomography revealed the development of bilateral lung consolidation. Her dyspnea was relieved, and her oxygenation levels and radiological findings improved after commencing corticosteroid treatment. Blood biomarkers for interstitial lung disease, Krebs von den Lungen-6 (KL-6) and surfactant protein D (SP-D), showed different responses during the clinical course of her disease. Evaluation of serial changes in levels of KL-6 and SP-D may help diagnose and monitor COVID-19-associated organizing pneumonia (OP). Clinicians should be aware that SOP can develop in response to COVID-19 and that these patients may benefit from the use of steroids.

1. Introduction

Organizing pneumonia (OP) is a pulmonary inflammatory condition that occurs in certain clinical settings and may be associated with connective tissue disorders, infectious diseases, or organ transplantations, or it could be drug-related [1]. The clinical and radiographic findings, treatment response, and prognosis in patients with both cryptogenic OP and secondary OP (SOP) are similar and nonspecific [2]. Cytomegalovirus, influenza virus, parainfluenza virus, human immunodeficiency virus and herpesvirus infections have been reported to cause SOP [1]. There have been no reports of SOP triggered by severe acute respiratory syndrome coronavirus 2 (SARS-CoV-2) infection. The primary computed tomography (CT) finding in early-stage coronavirus disease 2019 (COVID-19) is ground-glass opacities (GGOs) in the lungs, that may change to consolidations in approximately 9 days [3], making it challenging to differentiate COVID-19 pneumonia from SOP based on the imaging findings alone.

Here we report a case of COVID-19-associated SOP in which

corticosteroid treatment was effective at relieving the dyspnea and improving oxygenation. Among the blood biomarkers for interstitial lung disease, Krebs von den Lungen-6 (KL-6) and surfactant protein D (SP-D) were assessed, which have been widely used in clinical practice [4]. Assessment of serial changes in serum biomarkers, including KL-6 and SP-D, is useful in the diagnosis of SOP.

2. Case report

A 70-year-old woman, who had been diagnosed with COVID-19 by polymerase chain reaction (PCR) testing of nasopharyngeal swab samples for SARS-CoV-2, was admitted to Hokkaido University Hospital for further treatment. She had never smoked and had an unremarkable medical history. She presented with a one-week history of cough, dyspnea, loss of appetite, and a high fever. On admission, her body temperature was 37.9 °C, blood pressure was 136/67 mmHg, heart rate was 88 beats/min, respiratory rate was 29 breaths/min, and her percutaneous oxygen saturation (SpO₂) was 95% while breathing 5 L/min of

Abbreviations: COVID-19, coronavirus disease 2019; KL-6, Krebs von den Lungen 6; OP, organizing pneumonia; SARS-CoV-2, severe acute respiratory syndrome coronavirus 2; SOP, secondary organizing pneumonia; SP, surfactant protein.

* Corresponding author.

E-mail addresses: h.holy724@gmail.com (H. Horii), keisukekmd@gmail.com (K. Kamada), shonakakubo@pop.med.hokudai.ac.jp (S. Nakakubo), yuyama@pop.med.hokudai.ac.jp (Y. Yamashita), junnaka.3n3.11@gmail.com (J. Nakamura), nasuhara@med.hokudai.ac.jp (Y. Nasuhara), satkonno@med.hokudai.ac.jp (S. Konno).

<https://doi.org/10.1016/j.rmcr.2020.101295>

Received 6 October 2020; Received in revised form 12 November 2020; Accepted 12 November 2020

Available online 18 November 2020

2213-0071/© 2020 The Author(s).

Published by Elsevier Ltd.

This is an open access article under the CC BY-NC-ND license

(<http://creativecommons.org/licenses/by-nc-nd/4.0/>).

Table 1
Clinical laboratory results.

Measure	Reference Range	On admission	Hospital day 10	Hospital day 15	Hospital day 36
Hemoglobin (g/dL)	11.6–14.8	12.4	13.3	12.5	13.8
White cells (/μL)	3300–8600	9500	13900	11300	10400
Differential count					
Neutrophils (/μL)		8683	12288	9481	8445
Lymphocytes (/μL)		580	1029	915	1466
Monocytes (/μL)		219	445	655	447
Eosinophils (/μL)		10	125	226	31
Platelets (× 1000/μL)	158–348	168	378	274	160
Prothrombin time (s)	10.2–12.6	12.3	13.1	11.8	NA
Prothrombin-time international normalized ration	0.85–1.25	1.03	1.1	0.98	NA
Activated partial-thromboplastin time (s)	26.2–41.5	30.8	30.7	27.3	NA
Na (mEq/L)	138–145	140	136	141	142
K (mEq/L)	3.6–4.8	2.8	4.7	3.9	3.6
Cl (mEq/L)	101–108	101	101	102	105
Urea nitrogen (mg/dL)	8–20	9	19	14	16
Creatinine (mg/dL)	0.46–0.79	0.52	0.63	0.56	0.6
D-dimer (μg/mL)	<1.00	0.36	2.3	1.1	NA
Ferritin (ng/mL)	5–179	283	401	440	NA
Lactate dehydrogenase (U/L)	124–222	366	307	215	180
C-reactive protein (mg/dL)	0.00–0.14	15.8	2.9	0.5	0.02
Creatine kinase (U/L)	41–153	61	14	17	12
KL-6 (U/mL)	105.3–401.2	162	354	337	259
SP-D (ng/mL)	0.0–109.9	21.2	146.7	99.7	15.6
SP-A (ng/mL)	0.0–43.7	NA	65.5	44.1	20.5
Procalcitonine (ng/mL)	<0.50	0.09	0.02	NA	NA

NA: not available.

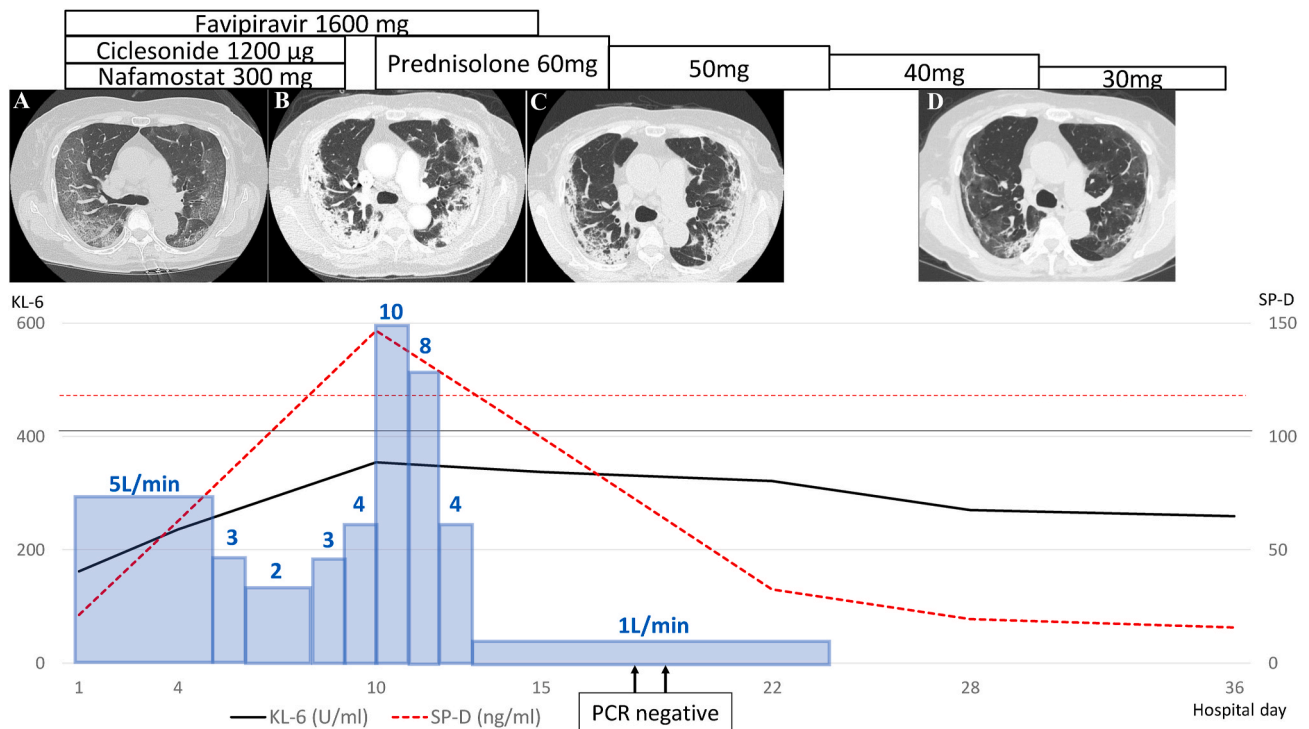


Fig. 1. Transition of therapeutic agents and interstitial lung disease markers and CT images.

Linear line indicates the upper limit of normal for KL-6 and linear dotted line indicates it for SP-D. Each CT image shows the following, A: On admission, B: Hospital day 10, C: Hospital day 17, D: Hospital day 32. Bar graphs represent oxygen doses (L/min). SARS-CoV-2 PCR was performed at Hospital day 18 and 19.

oxygen with an oxygen mask. The laboratory findings included elevated levels of serum C-reactive protein, lactate dehydrogenase, and ferritin; normal levels of procalcitonin, D-dimer, KL-6, and SP-D; and reduced levels of eosinophils and lymphocytes (Table 1). CT imaging revealed bilateral GGOs with superimposed intralobular reticulations in a crazy-paving pattern in both lung fields (Fig. 1A). There were no findings suggesting pulmonary embolism, purulent sputum or infiltrative

shadows, and no findings suggesting bacterial infection. Therefore, no antibiotics were administered, and no blood or sputum culture was performed. Additionally, the patient had no lower leg edema or any signs of congestive heart failure. Based on these findings, we commenced treatment with favipiravir (1600 mg/day), ciclesonide (1200 μg/day), and nafamostat (300 mg/day), as a for SARS-CoV-2 infection.

The patient's fever, cough, dyspnea, and serum C-reactive protein levels improved after starting the treatment, and on Day 8 of hospitalization, her SpO₂ was 95% while breathing 2 L/min of oxygen with a nasal cannula. However, on Day 10, she developed rapidly progressive respiratory failure, and her SpO₂ dropped to 94% while breathing 10 L/min oxygen using a reservoir mask. CT imaging revealed that the bilateral GGOs observed earlier had progressed to lung consolidation, and there were no new GGOs (Fig. 1B). Furthermore, her serum SP-D level was higher than the level on admission. Clinically, COVID-19-associated SOP was suspected, and systemic corticosteroid therapy (prednisolone 1 mg/kg/day) was initiated. Three days after starting corticosteroid therapy (day 13), her oxygenation level improved dramatically, and SpO₂ was 94% while breathing 1 L/min oxygen with a nasal cannula. CT imaging performed on day 7 after starting corticosteroid therapy (day 17) revealed less intense lung lesions than previous evaluated (Fig. 1C). Her serum levels of SP-D and surfactant protein A (SP-A) had also decreased to within the normal range. On day 18 and 19 after hospitalization, a PCR test of a nasopharyngeal swab sample was negative for SARS-CoV-2. Serial changes in serum biomarkers evaluated throughout her hospital stay are shown in Table 1 and Fig. 1. Prednisolone was tapered down to 30 mg, and she was discharged day 38 after admission. After discharge, prednisolone was tapered down to 20 mg for 20 days, 10 mg for 14 days and 5 mg for 14 days, and discontinued thereafter. In subsequent follow-up visits, no increase in KL-6 or SP-D, and no shadows exacerbations were observed.

3. Discussion

To the best of our knowledge, this is the first report to document serial changes in radiologic findings and laboratory biomarkers in a patient with COVID-19-associated SOP. The patient showed clinical improvement on commencing treatment with favipiravir, ciclesonide, and nafamostat for SARS-CoV-2 infection, but subsequently developed rapidly progressive hypoxemia and required a high dose of oxygen. There were no signs of a secondary bacterial infection or pulmonary embolism or heart failure, and her general condition was good relative to her oxygen demand. She improved clinically soon after starting steroid treatment.

Chest CT performed on day 7 of hospitalization revealed a notable reduction in lung volume and increased intensity of the diffuse bilateral GGOs, observed on admission, but no new GGOs in other lung fields; consistent with previous reports of serial CT findings in COVID-19 patients [3]. Lung tissue biopsy is necessary for accurate diagnosis of OP, but bronchoscopy is a high-risk procedure associated with a high level of aerosol generation and is challenging to perform in COVID-19 patients. Although we did not obtain definitive pathological confirmation in this case, we based our diagnosis of SOP on the clinical observations (bimodal clinical course of the apparent re-exacerbation of oxygen demand once improved, which is atypical for COVID-19 alone), elevated SP-D levels, radiological findings, and the effectiveness of systemic corticosteroids in promoting clinical and radiographic resolution. There was no discrepancy with the clinical and radiographic findings of SOP presented in previous reports [2].

Dexamethasone and other steroids have been reported to be effective for the treatment of COVID-19 [5,6], but it is not known which cases benefit the most. Although it was difficult to distinguish SOP from the natural history of COVID-19 in this patient, her initial improvement followed by worsening of her clinical condition, was atypical of the usual course of COVID-19. Steroid therapy is known to worsen the prognosis in influenza virus pneumonia [7], but the cause of the variable therapeutic response in different types of viral infection is unknown. Future cases demonstrating SOP as more common in COVID-19 than in other viral infections may explain the effectiveness of steroids in treating COVID-19.

The serial changes in several important serum biomarkers for interstitial lung disease are of relevance in this case. OP with elevated serum

KL-6 may be more severe and unstable [8]; require treatment with prednisolone [9], and has a higher frequency of relapse [10] compared to OP with normal serum KL-6. Patients with OP and elevated serum levels of SP-D had significantly increased serum KL-6 level and a significantly higher relapse rate than those with a normal level of SP-D [11]. Our patient had elevated SP-D levels, but her KL-6 levels were within the reference range, and her SP-D level rapidly decreased after initiating steroid administration. There are several possible explanations for this paradoxical dissociation, which is related to the functional differences between these proteins. Both serum SP-A and SP-D levels are associated with the extent of alveolitis (a reversible change) [12]. On the other hand, increased serum levels of KL-6 might be related to irreversible alveolar cell damage [13]. Discordant serum levels of these biomarkers has also been observed in cases of multifocal micronodular pneumocyte hyperplasia, which is characterized by type II alveolar cell proliferation, but not with alveolar cell damage [14]. Further evaluation of serial levels of each of these three biomarkers may be helpful for identifying and monitoring the activity of COVID-19-associated SOP.

4. Conclusion

In summary, we report a case of COVID-19-associated SOP with serial changes in radiographic and laboratory findings. Physicians should be aware that patients with COVID-19 can develop SOP in response to SARS-CoV-2 infection and that they may benefit from the use of steroids.

Funding sources

This research did not receive any specific grant from funding agencies in the public, commercial, or not-for-profit sectors.

Author contributions

KK, SN, YY, JN, YN, and SK contributed to the management of this patient. KK was the leader of the clinical team. KK and SK conducted the literature review and wrote the manuscript. SK revised the article. All authors read and approved the final manuscript.

Declaration of competing interest

The authors have no conflicts of interest to declare.

Acknowledgements

Consent for publication.

Written informed consent was obtained from the patient.

References

- [1] F. Drakopanagiotakis, V. Polychronopoulos, M.A. Judson, Organizing pneumonia, *Am. J. Med. Sci.* 335 (2008) 34–39, <https://doi.org/10.1097/MAJ.0b013e31815d829d>.
- [2] F. Drakopanagiotakis, K. Paschalaki, M. Abu-Hijleh, B. Aswad, N. Karagianidis, E. Kastanakis, S.S. Braman, V. Polychronopoulos, Cryptogenic and secondary organizing pneumonia: clinical presentation, radiographic findings, treatment response, and prognosis, *Chest* 139 (2011) 893–900, <https://doi.org/10.1378/chest.10-0883>.
- [3] F. Pan, T. Ye, P. Sun, S. Gui, B. Liang, L. Li, D. Zheng, J. Wang, R.L. Hesketh, L. Yang, C. Zheng, Time Course of lung changes at chest CT during recovery from Coronavirus Disease 2019 (COVID-19), *Radiology* 295 (2020) 715–721, <https://doi.org/10.1148/radiol.2020200370>.
- [4] N. Ishikawa N, N. Hattori, A. Yokoyama, N. Kohno, Utility of KL-6/MUC1 in the clinical management of interstitial lung diseases, *Respir. Investig.* 50 (2012) 3–13, <https://doi.org/10.1016/j.resinv.2012.02.001>.
- [5] P. Horby, W.S. Lim, J.R. Emberson, M. Mafham, J.L. Bell, L. Linsell, N. Staplin, C. Brightling, A. Ustianowski, E. Elmahi, B. Prudon, C. Green, T. Felton, D. Chadwick, K. Rege, C. Fegan, L.C. Chappell, S.N. Faust, T. Jaki, K. Jeffery, A. Montgomery, K. Rowan, E. Juszczak, J.K. Baillie, R. Haynes, M.J. Landray, Dexamethasone in hospitalized patients with Covid-19 - preliminary report, *N. Engl. J. Med.* (2020), <https://doi.org/10.1056/NEJMoa2021436>. NEJMoa2021436.

- [6] C.M.P. Jeronimo, M.E.L. Farias, F.F.A. Val, V.S. Sampaio, M.A.A. Alexandre, G. C. Melo, I.P. Safe, M.G.S. Borba, R.L. Abreu-Netto, A.B.S. Maciel, J.R.S. Neto, L. B. Oliveira, E.F.G. Figueiredo, K.M.O. Dinelly, M.G.A. Rodrigues, M. Brito, M.P. G. Mourão, G.A. Pivoto João, L.A. Hajjar, Q. Bassat, G.A.S. Romero, F.G. Naveca, H. L. Vasconcelos, M.A. Tavares, J.D. Brito-Sousa, F.T.M. Costa, M.L. Nogueira, D. Baía-da-Silva, M.S. Xavier, W.M. Monteiro, M.V.G. Lacerda, for the Metcovid Team, Methylprednisolone as adjunctive therapy for patients hospitalized with COVID-19 (metcovid): a randomised, double-blind, phase IIb, placebo-controlled trial, *Clin. Infect. Dis.* ciaa1177 (2020), <https://doi.org/10.1093/cid/ciaa1177>.
- [7] L. Lansbury, C. Rodrigo, J. Leonardi-Bee, V.T.J. Nguyen, W.S. Lim, Corticosteroids as adjunctive therapy in the treatment of influenza, *Cochrane Database Syst. Rev.* 2 (2019), CD010406, <https://doi.org/10.1002/14651858.CD010406.pub3>.
- [8] Y. Hara, S. Kanoh, Y. Fujikaru, S. Kawano, Y. Kozaki, K. Misawa, M. Shinkai, A. Kawana, Clinical significance of serum KL-6 levels in organizing pneumonia proven by lung biopsy, *J. Jap. Soc. Respir. End.* 36 (2014) 348–352, <https://doi.org/10.18907/jjsre.36.4.348>.
- [9] K. Yamaguchi, K. Tsushima, N. Kurita, A. Fujiwara, S. Soeda, A. Yamaguchi, S. Sugiyama, Y. Togashi, Y. Kono, S. Kasagi, Y. Setoguchi, Clinical characteristics classified by the serum KL-6 level in patients with organizing pneumonia, *Sarcoidosis, Vasc. Diffuse. Lung. Dis.* 30 (2013) 43–51.
- [10] F. Okada, Y. Ando, K. Honda, S. Tanoue, S. Matsumoto, H. Mori, Comparison of pulmonary CT findings and serum KL-6 levels in patients with cryptogenic organizing pneumonia, *Br. J. Radiol.* 82 (2009) 212–218, <https://doi.org/10.1259/bjr/72775434>.
- [11] T. Yamagishi, N. Kodaka, K. Watanabe, C. Nakano, T. Oshio, K. Niitsuma, N. Shimada, H. Matsuse, A retrospective clinical research of relapsed organizing pneumonia, *Ann. Thorac. Med.* 15 (2020) 15–20, <https://doi.org/10.4103/atm.ATM.311.19>.
- [12] H. Takahashi, T. Fujishima, H. Koba, S. Murakami, K. Kurokawa, Y. Shibuya, M. Shiratori, Y. Kuroki, S. Abe, Serum surfactant proteins A and D as prognostic factors in idiopathic pulmonary fibrosis and their relationship to disease extent, *Am. J. Respir. Crit. Care Med.* 162 (2000) 1109–1114, <https://doi.org/10.1164/ajrccm.162.3.9910080>.
- [13] N. Kohno, Y. Awaya, T. Oyama, M. Yamakido, M. Akiyama, Y. Inoue, A. Yokoyama, H. Hamada, S. Fujioka, K. Hiwada, KL-6, a mucin-like glycoprotein, in bronchoalveolar lavage fluid from patients with interstitial lung disease, *Am. Rev. Respir. Dis.* 148 (1993) 637–642, <https://doi.org/10.1164/ajrccm/148.3.637>.
- [14] S. Konno, M. Shigemura, T. Ogi, K. Shimizu, M. Suzuki, K. Kaga, Y. Hida, Y. Matsuno, M. Nishimura, Clinical course of histologically proven multifocal micronodular pneumocyte hyperplasia in tuberous sclerosis complex: a case series and comparison with lymphangiomyomatosis, *respiration*, *Int. Rev. Thoracic Dis.* 95 (2018) 310–316, <https://doi.org/10.1159/000486101>.