



Since January 2020 Elsevier has created a COVID-19 resource centre with free information in English and Mandarin on the novel coronavirus COVID-19. The COVID-19 resource centre is hosted on Elsevier Connect, the company's public news and information website.

Elsevier hereby grants permission to make all its COVID-19-related research that is available on the COVID-19 resource centre - including this research content - immediately available in PubMed Central and other publicly funded repositories, such as the WHO COVID database with rights for unrestricted research re-use and analyses in any form or by any means with acknowledgement of the original source. These permissions are granted for free by Elsevier for as long as the COVID-19 resource centre remains active.

could also explain the lower COVID-19 mortality among patients living at high altitudes. In France, poor clinical and virological outcomes in COVID-19 patients treated with hydroxychloroquine-azithromycin were associated with the use of AT1 blockers.¹¹ COVID-19-related mortality among men could be higher because ACE2 receptor expression is lower among women.¹²

One of the limitations of this study is that individual data were not used for analysis because they were not freely accessible. More complex research including variables such as age, symptoms, severity, and time-space patterns of infection is needed to determine whether COVID-19 severity varies with altitude.

Although this paper has the limitation that individual data were not used for the analysis because they were not freely accessible, we believe that the pathophysiological mechanisms we describe could explain why in Pasco, the region with the highest capital in Peru (4338 masl), the COVID-19 infection rate is 174/100 000, while in Callao, the lowest capital (7 masl) in the country, it is 1106 (6.4 times higher). We agree with Soliz and Zubieta³ who previously proposed that the lower expression of ACE2 receptors was associated with the reduction of COVID-19 cases among high-altitude residents.

References

1. Roberts P, Amano N. Plastic pioneers: hominin biogeography east of the Movius Line during the Pleistocene. *Archaeol Res Asia*. 2019;17:181–92.
2. Rijssenbeek-Nouwens LH, Bel EH. High-altitude treatment: a therapeutic option for patients with severe, refractory asthma? *Clin Exp Allergy*. 2011;41:775–82.
3. Arias-Reyes C, Zubieta-DeUrioste N, Poma-Machicao L, Aliaga-Raudan F, Carvajal-Rodríguez F, Dutschmann M, et al. Does the pathogenesis of SARS-CoV-2 virus decrease at high-altitude? *Respir Physiol Neurobiol*. 2020;277:103443.
4. Tinoco YO, Azziz-Baumgartner E, Uyeki TM, Rázuri HR, Kasper MR, Romero C, et al. Burden of influenza in 4 ecologically distinct regions of Peru: household active surveillance of a community cohort, 2009–2015. *Clin Infect Dis*. 2017;65:1532–41.
5. Kalter SS, Tepperman J. Influenza virus proliferation in hypoxic mice. *Science*. 1952;621–2.
6. Berry LJ, Mitchell RB, Rubenstein D. Effect of acclimatization to altitude on susceptibility of mice to influenza A virus infection. *Proc Soc Exp Biol Med*. 1955;88:543–8.
7. Hoffmann M, Kleine-Weber H, Schroeder S, Krüger N, Herrler T, Erichsen S, et al. SARS-CoV-2 cell entry depends on ACE2 and TMPRSS2 and is blocked by a clinically proven protease inhibitor. *Cell*. 2020;181:271–80.e8.
8. Zhang R, Wu Y, Zhao M, Liu C, Zhou L, Shen S, et al. Role of HIF-1 α in the regulation ACE and ACE2 expression in hypoxic human pulmonary artery smooth muscle cells. *Am J Physiol Lung Cell Mol Physiol*. 2009;297:L631–40.
9. Chu CM, Poon LL, Cheng VC, Chan KS, Hung IF, Wong MM, et al. Initial viral load and the outcomes of SARS. *CMAJ*. 2004;171:1349–52.
10. Stoyanoff TR, Rodríguez JP, Todaro JS, Colavita JP, Torres AM, Aguirre MV. Erythropoietin attenuates LPS-induced microvascular damage in a murine model of septic acute kidney injury. *Biomed Pharmacother*. 2018;107:1046–55.
11. Gautret P, Lagier JC, Parola P, Meddeb L, Mailhe M, Doudier B, et al. Hydroxychloroquine and azithromycin as a treatment of COVID-19: results of an open-label non-randomized clinical trial. *Int J Antimicrob Agents*. 2020;105949.
12. Stelzig KE, Canepa F, Schilliro M, Berdnikovs S, Prakash YS, Chiarella SE. Estrogen regulates the expression of SARS-CoV-2 receptor ACE2 in differentiated airway epithelial cells. *Am J Physiol Lung Cell Mol Physiol*. 2020;318:L1280–1.

Roberto Alfonso Accinelli^{a,b,*}, Juan Alonso Leon-Abarca^a

^a Instituto de Investigaciones de la Altura, Universidad Peruana Cayetano Heredia, Lima, Peru

^b Hospital Cayetano Heredia, Lima, Peru

* Corresponding author.

E-mail address: roberto.accinelli@upch.pe (R.A. Accinelli).

Digital Tomosynthesis and COVID-19: An improvement in the assessment of pulmonary opacities[☆]



Tomografía Digital y COVID-19: un avance en la valoración de opacidades pulmonares

To the Editor:

The outbreak of coronavirus disease (COVID-19) caused by severe acute respiratory syndrome-coronavirus-2 (SARS-CoV-2), emerged in China in late 2019 and was declared a pandemic by the World Health Organization on March 11, 2020. By May 4, 215 countries had already been affected, and more than 3 million cases had been confirmed worldwide.¹ This virus, a member of the Coronaviridae family, uses a spike protein to enter into the cell by binding to the angiotensin-converting enzyme 2 expressed in nasal, oral, lung, and colon cells, amongst other tissues.²

To address this global emergency and facilitate the overall management of this pandemic, the scientific community and health professionals are working on the development of new treatments and technologies to enable early diagnosis. The role of chest imaging, specifically radiography (X-ray) and computed tomography (CT), in the management of patients with suspected COVID-19 should be established taking into account factors such as respi-

ratory disease severity, pretest probability of the disease, and the availability of resources.³

Currently, neither X-ray nor CT are recommended diagnostic criteria for COVID-19. The only accepted diagnostic method is viral screening, with the limitation that quantitative PCR results are only available after 6–48 h. Therefore, although viral testing is still required even when radiological findings are consistent with the disease, radiological imaging findings should be taken into consideration to establish a suspected diagnosis aimed at providing a more efficient triage not only involves screening of patients but also decision like quarantine the patients, admit them etc.^{3,4}

Most publications support the accuracy of CT in detecting viral pneumonia, even in asymptomatic patients.⁵ In patients with a high clinical probability of COVID-19 who are positive on CT but with a negative PCR test, this imaging technique can be viewed as a screening tool, and a repeat PCR is indicated.⁶ The characteristic radiological findings of COVID-19 on CT include multiple peripheral pulmonary opacities, with frequent bilateral involvement, distributed predominantly in basal and posterior regions. X-ray reveals similar characteristics, but the sensitivity of CT is superior.^{7–10}

No uniform criteria are available to guide the radiological evaluation of viral pneumonia in the context of a pandemic. The choice of imaging techniques is based not only on the properties of imaging techniques themselves, but also on the resources of the hospital, the availability of viral testing, expertise, and ultimately depends on the judgement of the team of professionals directly involved in the management of these patients.³

[☆] Please cite this article as: Calvo I, SantaCruz-Calvo S, Aranzana MG, Mármol P, Luque JA, Ramos F, et al. Tomografía Digital y COVID-19: un avance en la valoración de opacidades pulmonares. *Arch Bronconeumol*. 2020;56:761–763.

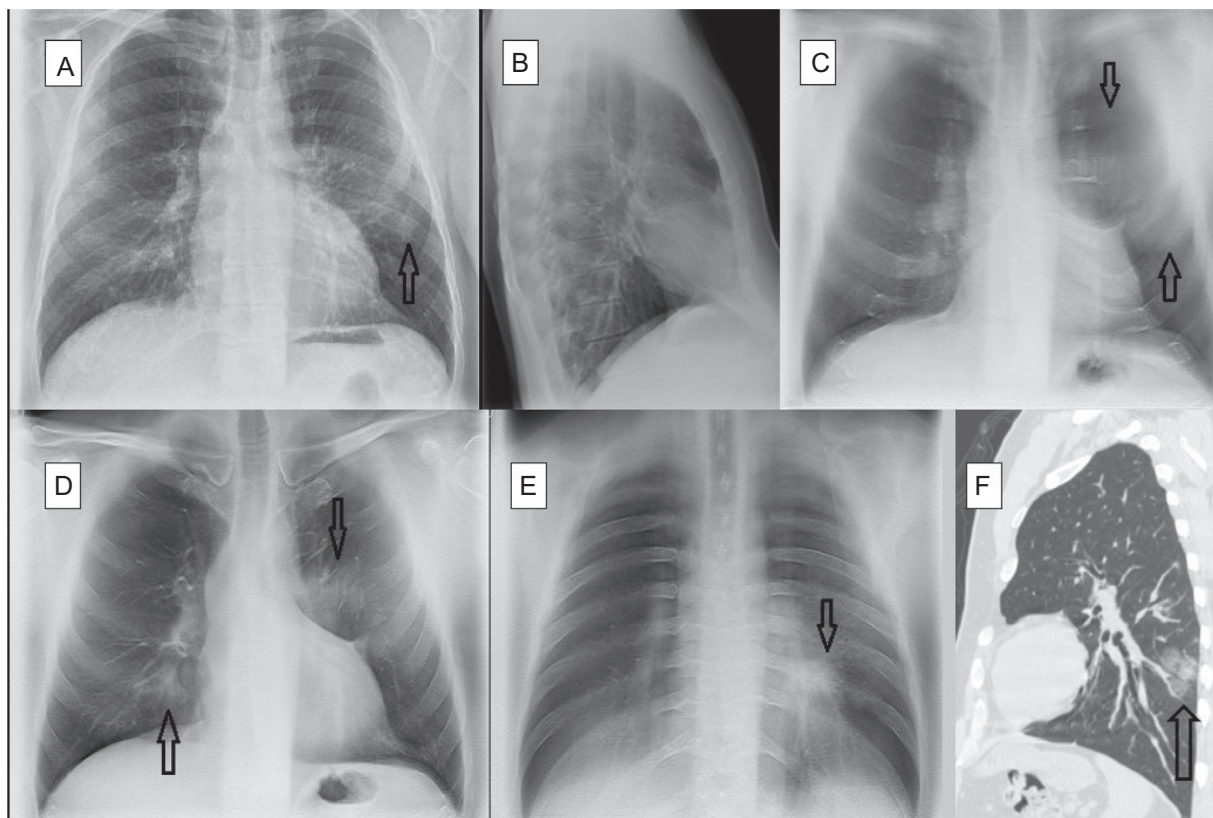


Figure 1. Bilateral COVID-19 pneumonia. A 52-year-old man, family doctor by profession, presented with a 10-day history of cough and myalgia. Dyspnea and fever on examination. Laboratory tests: normal white cell count, ferritin 545.7 ng/mL (>322), and erythrocyte sedimentation rate 53 m/n (0–20). PCR positive for SARS-CoV-2. A—Posterior-anterior chest X-ray: slight opacity in the periphery of the left hemitorax, middle field. B—Lateral chest X-ray with no obvious findings. C—DTS: Image no. 8 (anterior). Extensive opacity in anterior region of left hemitorax (arrows). D—DTS: Image no. 14 (central). Bilateral pulmonary opacities, in the left suprahilar region (arrow) and right lower lobe (arrow). E—DTS: Image no. 36 (posterior). Oval opacity in retro-cardiac region (arrow). F—Non-contrast chest CT scan, sagittal reconstruction. Oval opacity in the periphery of the left lower lobe (arrow).

Digital tomosynthesis (DTS) of the chest is a technique that provides multiple anatomical images in a single scan. DTS shares some CT advantages and, although less sensitive, requires a lower dose of radiation (CT vs. DTS, 49×), and reduces costs. Additionally, it also has several advantages over chest X-ray: 1) it improves lesion detection by reducing artifacts caused by overlapping anatomical structures; 2) it facilitates 3-dimensional localization; 3) it offers improved contrast resolution; and 4) it is more sensitive.^{11–15}

DTS consists of a conventional X-ray tube, the movements of which are controlled from the console, a detector panel and reconstruction algorithms that produce tomographic images.

Up to 60 low-dose exposures are obtained during each pass. The data acquired are reconstructed in a group of coronal images of the chest, parallel to the detector plane, which can be reviewed sequentially in DICOM format on any standard workstation connected to the PACS. All DTS include a conventional PA projection in addition to the tomograms.

The role of digital tomography in the assessment of infectious lung disease is not yet established, although its efficacy in detecting pulmonary nodules and screening for breast cancer has been described.^{12,13}

In our radiology department, DTS has been proposed as a preferred initial imaging technique for evaluating acute respiratory disease in patients with suspected COVID-19. To date, 62% of patients admitted with COVID-19 confirmed by quantitative PCR (n=97; 56 men and 41 women) had baseline DTS, and the remaining 38%, who presented a worse clinical condition underwent chest X-ray. When the DTS radiological reports were classified according to the probability of COVID-19 as: 1) low; 2) intermediate; 3) high;

or 4) no radiological alterations, we found that the results of 53% of the DTS performed prior to viral testing were highly probable and only 6% were normal.

In total, 13% of PCR-positive patients were admitted after their second DTS because they did not initially meet clinical admission criteria. In all cases, progressive pulmonary opacities were observed on DTS, in addition to worsening symptoms and clinical laboratory markers. Four cases were reported as low probability in the first DTS and high probability in the second; 2 patients had normal initial DTS and high probability in the second; and another 2 cases were reported as low probability in the first DTS and intermediate probability in the second.

Our recent experience reporting DTS in patients with suspected COVID-19 suggests that this technique is more useful when pulmonary opacities are subtle and therefore more difficult to identify by X-ray. It also facilitates the detection of multiple peripheral opacities, confirming bilateral involvement in many cases; characteristics that, as already mentioned, are associated with COVID-19. In this respect, DTS is more specific than chest X-ray in this disease. By providing a series of coronal slices, pulmonary opacities that may be faint or posterior can be more accurately located than with lateral X-ray (Fig. 1) (annex, Supplementary Figs. 1 and 2). It is not a matter of opinion. It is a conclusion generated by what was experienced with these patients. The main limitation of this technique is the respiration-mediated artifacts caused by the difficulty of some patients in holding their breath during the examination.

Although more studies are needed to consolidate the utility of DTS in a scenario with high clinical suspicion for COVID-19, it seems

reasonable that a DTS positive for disease could obviate the need for CT. In this context, DTS use as primary imaging technique not only relieves the pressure on CT rooms, but also reduces the radiation dose delivered to patients. In conclusion, our preliminary results suggest that DTS may play an important role in the initial evaluation of patients with suspected COVID-19.

Appendix A. Supplementary data

Supplementary material related to this article can be found, in the online version, at doi:<https://doi.org/10.1016/j.arbr.2020.06.005>.

References

1. Culp WC. Coronavirus disease 2019. *A & A Pract.* 2020;14:14, e01218. Available from: <https://www.who.int/emergencies/diseases/novel-coronavirus-2019> [Accessed 4 May 2020].
2. Hoffmann M, Kleine-Weber H, Schroeder S, Krüger N, Herrler T, Erichsen S, et al. SARS-CoV-2 cell entry depends on ACE2 and TMPRSS2 and is blocked by a clinically proven protease inhibitor. *Cell.* 2020;181:271–80, <http://dx.doi.org/10.1016/j.cell.2020.02.052>, e8.
3. Rubin GD, Ryerson C, Haramati L, Sverzellati N, Kanne J, Raouf S, et al. The role of chest imaging in patient management during the COVID-19 pandemic: a multinational consensus statement from the Fleischner Society. *Radiology.* 2020;296:172–80, <http://dx.doi.org/10.1148/radiol.2020201365>.
4. American College of Radiology. ACR Recommendations for the use of Chest Radiography and Computed Tomography (CT) for Suspected COVID-19 Infection, 2020. Available from: <https://www.acr.org/Advocacy-and-Economics/ACR-Position-Statements/Recommendations-for-Chest-Radiography-and-CT-for-Suspected-COVID19-Infection> [Accessed 10 April 2020].
5. Inui S, Fujikawa A, Jitsu M, Kunishima N, Watanabe S, Suzuki Y, et al. Chest CT findings in cases from the cruise ship “diamond princess” with coronavirus disease 2019 (COVID-19). *Radiol Cardiothorac Imaging.* 2020;2:e200110, <http://dx.doi.org/10.1148/ryct.2020200110>.
6. Xie X, Zhong Z, Zhao W, Zheng C, Wang F, Liu J. Chest CT for typical 2019-nCoV pneumonia: relationship to negative RT-PCR testing. *Radiology.* 2020;200343, <http://dx.doi.org/10.1148/radiol.2020200343>.
7. Wong HYF, Lam HYS, Fong AHT, Leung ST, Chin T, Yen Lo CS, et al. Frequency and distribution of chest radiographic findings in COVID-19 positive patients. *Radiology.* 2019;201160, <http://dx.doi.org/10.1148/radiol.2020201160>.
8. Choi H, Qi X, Yoon SH, Park SJ, Lee KH, Kim JY, et al. Extension of coronavirus disease 2019 (COVID-19) on Chest CT and implications for chest radiograph interpretation. *Radiol Cardiothorac Imaging.* 2020;2:e200107, <http://dx.doi.org/10.1148/ryct.2020200107>.
9. Salehi S, Abedi A, Balakrishnan S, Gholamrezanezhad A. Coronavirus disease 2019 (COVID-19): a systematic review of imaging findings in 919 patients. *Am J Roentgenol.* 2020;215:87–93, <http://dx.doi.org/10.2214/AJR.20.23034>.
10. Zhou S, Wang Y, Zhu T, Xia L. CT features of coronavirus disease 2019 (COVID-19) pneumonia in 62 patients in Wuhan, China. *Am J Roentgenol.* 2020;214:1287–94, <http://dx.doi.org/10.2214/AJR.20.22975>.
11. Ferrari A, Bertolaccini L, Solli P, Di Salvia PO, Scaradozzi D. Digital chest tomosynthesis: the 2017 updated review of an emerging application. *Ann Transl Med.* 2018;6, <http://dx.doi.org/10.21037/atm.2017.08.18>, 91–91.
12. Grosso M, Prioto R, Chirardo D, Talenti A, Roberto E, Bertolaccini L, et al. Comparison of digital tomosynthesis and computed tomography for lung nodule detection in SOS screening program. *Radiol Medica.* 2017;122:568–74, <http://dx.doi.org/10.1007/s11547-017-0765-3>.
13. Choo JY, Lee KY, Yu A, Kim J-H, Lee SH, Won J, et al. A comparison of digital tomosynthesis and chest radiography in evaluating airway lesions using computed tomography as a reference. *Eur Radiol.* 2016;26:3147–54, <http://dx.doi.org/10.1007/s00330-015-4127-z>.
14. Kim EY, Bista AB, Kim T, Park SY, Park KJ, Kang DK, et al. The advantage of digital tomosynthesis for pulmonary nodule detection concerning influence of nodule location and size: a phantom study. *Clin Radiol.* 2017;72:796, <http://dx.doi.org/10.1016/j.crad.2017.03.022>, e1–796e8.
15. Dobbins JT, McAdams HP, Sabol JM, Chakraborty DP, Kazerooni EA, Reddy GP, et al. Multi-institutional evaluation of digital tomosynthesis, dual-energy radiography, and conventional chest radiography for the detection and management of pulmonary nodules. *Radiology.* 2017;282:236–50, <http://dx.doi.org/10.1148/radiol.2016150497>.

Inmaculada Calvo^{a,*}, Sara SantaCruz-Calvo^b,
María Gracia Aranzana^a, Patricia Mármol^a,
Jorge Ángel Luque^a, Inmaculada Peral^a, Eva María Quijada^a,
Cristina Gómez^a, Celia Borrego^a, Jorge Marín^c

^a Servicio de Radiología, Hospital Comarcal de la Merced, Osuna, Sevilla, Spain

^b Department of Pharmacology and Nutritional Sciences and the Barnstable Brown Diabetes and Obesity Center, University of Kentucky, Lexington, Kentucky, United States

^c Servicio de Medicina Interna, Hospital Comarcal de la Merced, Osuna, Sevilla, Spain

* Corresponding author.

E-mail address: inmaculada.calvo.sspa@juntadeandalucia.es (I. Calvo).

Received 17 May 2020

Accepted 18 June 2020