



# Perioperative circulatory support for lung transplantation

Akihiro Ohsumi<sup>1</sup> · Hiroshi Date<sup>1</sup>

Received: 4 December 2020 / Accepted: 20 February 2021 / Published online: 5 March 2021  
© The Japanese Association for Thoracic Surgery 2021

## Abstract

**Objective** Extracorporeal membrane oxygenation (ECMO) has recently replaced cardiopulmonary bypass (CPB) as the preferred option for providing circulatory support during lung transplantation. This review aimed to summarize the previous data and to address the relative use of ECMO and CPB during lung transplantation.

**Methods** The database was searched in PubMed (Medline) using the following keywords: lung transplantation, extracorporeal membrane oxygenation, and cardiopulmonary bypass, for all relevant reports which were written in English and were published between 2000 and 2020.

**Review** Several reports have revealed that intraoperative use of ECMO is associated with lower blood product transfusion requirements, shorter ventilator support, and shorter length of hospital stay. During recent years, preoperative ECMO has also been used with favorable outcomes as a bridge to lung transplantation in critically ill patients.

**Conclusions** The use of ECMO during lung transplantation seems to reduce postoperative complications and improve short-term outcomes, relative to CPB. However, additional data should be collected through large multicenter randomized controlled trials. Furthermore, preoperative ECMO as a bridge to lung transplantation appears to provide favorable outcomes, although additional data are also needed from experienced transplant centers.

**Keywords** Extracorporeal membrane oxygenation · Cardiopulmonary bypass · Lung transplantation · ECMO · CPB

## Introduction

Lung transplantation (LTx) is well-established as the last option for patients with end-stage pulmonary diseases. Extracorporeal circulation (ECC) is required during LTx, although the intraoperative support strategies, which include off-pump, extracorporeal membrane oxygenation (ECMO), and cardiopulmonary bypass (CPB), vary considerably among transplant centers. During recent years, an increasing number of transplant centers have changed their ECC strategy from CPB to ECMO during LTx. Two recent meta-analyses comparing ECMO and CPB during LTx revealed favorable outcomes for ECMO, although the results differed among centers. Furthermore, ECMO has been used

for post-transplant recovery from primary graft dysfunction (PGD) and as a pre-transplant bridge to LTx in critically ill patients.

This review aimed to summarize the previous publication and acquire the current trend about ECC before and during LTx. The database was searched in PubMed (Medline) using the following keywords: lung transplantation, extracorporeal membrane oxygenation, and cardiopulmonary bypass, for all relevant reports which were written in English and were published between 2000 and 2020.

## Intraoperative ECMO for cadaveric double LTx

### CPB versus ECMO

The set-up for CPB and ECMO involves vascular cannulation, a pump, and an oxygenator. There are several important differences between CPB and ECMO, as shown in Table 1. The CPB circuit is an open system and has a venous reservoir with cardiomy suction lines. The ECMO circuit is

Presented at the 72th Annual Scientific Meeting of The Japanese Association for Thoracic Surgery.

✉ Akihiro Ohsumi  
akohsumi@kuhp.kyoto-u.ac.jp

<sup>1</sup> Department of Thoracic Surgery, Kyoto University Hospital, 54 Shogoin Kawahara-cho, Sakyo-ku, Kyoto 606-8507, Japan

**Table 1** Comparing cardiopulmonary bypass, extracorporeal membrane oxygenation, and off-pump

## Cardiopulmonary bypass (open circuit with reservoir)

1. *Indications:* required intracardiac repair, difficult double-lumen tube intubation (e.g., pediatric cases)
2. *Advantages:* use of pump sucker, open heart anastomosis is possible, cardiac decompression with less hemodynamically instability
3. *Disadvantages:* full heparinization, greater bleeding and more blood products transfused, greater inflammation

## Extracorporeal membrane oxygenation (closed circuit without reservoir)

1. *Indications:* pulmonary hypertension, hemodynamically instability, single-lung ventilation considered unstable
2. *Advantages:* low-dose heparinization, stable oxygenation and removal of carbon dioxide, decreased pulmonary hypertension, stable hemodynamics with cardiac compression
3. *Disadvantage:* no safety margin for air embolism

## Off-pump

1. *Indications:* possible single lung ventilation of native lung, no pulmonary hypertension
2. *Advantages:* no anticoagulation, minimal bleeding, shorter operation times, minimal inflammatory cascade
3. *Disadvantages:* hemodynamically instability because of cardiac compression, poorer visualization (especially for left lung transplantation via anterolateral incision), more perfusion and ventilation for the native lung during single-lung transplantation, required single-lung ventilation in a newly implanted lung during the second lung implantation

a closed system and does not have a blood–air interface, and thus does not require full heparinization. Open-circuit CPB had been the standard modality for intraoperative cardiopulmonary support, and LTx had been performed using CPB [1–3]. However, CPB requires full heparinization and may induce inflammation via passage of blood through the circuit, which can lead to coagulopathy and bleeding that require blood transfusion [4, 5]. In addition, the use of CPB is a risk factor for PGD [6]. Improvements in ECMO technology allowed for the first reported use of ECMO during LTx in 2001 [7], and since 2008 most LTx centers have switched their intraoperative ECC strategy from CPB to ECMO [2, 3, 5, 7–9].

To the best of our knowledge, two systematic reviews and meta-analyses have compared ECMO and CPB during LTx [10, 11]. The meta-analysis by Hoechter et al. was published in 2017 [10] and the meta-analysis by Magouliotis et al. was published in 2018 [11]. Both studies used independent assessments by several investigators, who independently performed data extraction and quality assessment, and any disagreements were resolved via discussion. Hoechter et al. included 6 studies in the meta-analysis [2, 3, 5, 8, 9, 12], which evaluated intraoperative red blood cell (RBC) transfusion, intraoperative fresh frozen plasma (FFP) transfusion, intraoperative platelet transfusion, duration of postoperative ventilation support, length of intensive care unit (ICU) stay, and mortality rate. Magouliotis et al. added one report by Aigner et al. [13] and the meta-analysis included 7 studies with 785 patients [11], which evaluated total operation time, total support time, ischemic time, intraoperative transfusions, intubation time, ICU stay, mean hospital stay, postoperative forced expiratory volume in 1 s, complications, and short-, medium-, and long-term mortality rates. The meta-analysis by Magouliotis et al. revealed no significant differences between the ECMO and CPB groups in terms of

total operation time, total support time, and ischemic time for both the first and second lungs. Hoechter et al. reported that the intraoperative blood transfusion requirement seemed to be beneficial for ECMO, but the differences did not reach significance. In contrast, Magouliotis et al. reported that the CPB group had significantly greater intraoperative transfusions of RBC, FFP, and platelets. In this context, intraoperative bleeding depends on the anticoagulation level, which is unbalanced between the ECMO and CPB groups, as low-dose heparinization is generally used for ECMO patients and full-dose heparinization is used for CPB patients. Thus, the difference in the findings of Magouliotis et al. and Hoechter et al. might be related to the CPB patients receiving high-dose heparinization and the use of both low-dose and high-dose heparinization in the ECMO group. Yeo et al. have reported that ECMO using low-dose heparinization does not markedly increase the rate of thromboembolic complications [14]. Therefore, low-dose heparin may be sufficient to achieve the desired anticoagulation level during ECMO, without increasing the rate of thromboembolic complications, which would lead to a lower requirement for intraoperative blood transfusions.

Hoechter et al. reported that the ECMO group had shorter durations of ventilator support and ICU stay, with 5 of 6 studies indicating a trend toward shorter ventilation [10]. Furthermore, Magouliotis et al. reported that the CPB group had significantly longer durations for intubation, ICU stay, and hospital stay [11]. In this context, Hoechter et al. addressed the importance of protective lung ventilation with low tidal volume and early extubation, which help to reduce the risk of pulmonary infection. The strategy at our center also aims to achieve early extubation followed by non-invasive positive pressure ventilation, as described by Soluri-Martins [15]. Tracheostomy is considered in some cases when sedation reduction is favored and when mechanical

ventilation is expected to last for > 1 week. Furthermore, separation of the upper and lower respiratory tracts is desirable to prevent pulmonary infection in patients with sinusitis.

Magouliotis et al. [11] reviewed complications and reported that the CPB group had significantly higher rates of bleeding, PGD, renal failure requiring dialysis, and tracheostomy. In addition, Hoechter et al. reported that, relative to the CPB group, the ECMO group had a 54% lower mortality rate at 3 months, a 12% higher mortality rate at 6 months, and a 35% lower mortality rate at 12 months, although none of these differences were significant [10]. Magouliotis et al. also reported no significant differences in mortality rates at 1 month, 3 months, and 1 year [11]. In this setting, short-term mortality is directly affected by operative parameters and complications, while medium- and long-term mortality is mainly related to chronic lung allograft dysfunction, infection, and complications related to prolonged hospital stays. Among the studies that were included in the meta-analyses, Ius et al. reported that ECMO was associated with a significant reduction in mortality (13% versus 39%) and with a non-significantly lower rate of grade 3 PGD [2]. Biscotti et al. also reported that the CPB group was more likely to have any PGD at 24 h and 72 h after the LTx, and that the CPB group had more severe PGD, relative to the ECMO group [9]. Another prospective multicenter study by Diamond et al. (for the Lung Transplant Outcomes Group) evaluated 1,255 lung transplant recipients at 10 American transplant centers, demonstrating that CPB use was a significant risk factor for grade 3 PGD among single and bilateral transplant recipients, and that grade 3 PGD was associated with a significantly increased risk of 1-year mortality [6]. Hoetzenecker et al. [16] (for the Vienna Lung Transplant Group) reported that a newly implanted graft is most vulnerable during the reperfusion phase. In that study, which involved the routine use of intraoperative ECMO in all patients, only 7.5% of the patients had grade 3 PGD immediately after transplantation, and at 72 h after LTx, only 1.3% of the patients had grade 3 PGD and 76.7% of the patients had been extubated. In addition, the 90-day mortality rate was 3.2% and the 2-year survival rate was 86%, with the lowest reported PGD rates at that time [16]. Those findings might be related to recent improvements in ECMO use, which are related to evolving strategies regarding ECMO indication and patient selection. Although favorable results have been achieved using ECMO during transplantation, even better outcomes have been reported among the limited cases that could be performed without ECC.

### V-V versus V-A ECMO

The configuration for intraoperative ECMO varies according to institutional practice, patient characteristics, and risk factors. Venovenous (V-V) ECMO only offers gas exchange

and is applied for respiratory failure without concomitant cardiac failure or significant pulmonary hypertension, but it is not commonly used as intraoperative support during LTx. This procedure plays an important role in some cases of severe hypercapnia without hemodynamic instability; it can work effectively as extracorporeal CO<sub>2</sub> removal in a less-invasive fashion than V-A ECMO. Furthermore, it could be possible using a small caliber venous dual lumen catheter with lower flow, and is effective especially for the hypercapnic failure of chronic obstructive pulmonary disease. V-V ECMO may also be useful as a bridge to LTx, which will be discussed later in this review, although it is not suitable for patients with pulmonary hypertension or concomitant cardiac impairment. Furthermore, this configuration creates excess recirculation (i.e., oxygenated blood returns to the circuit). Venovenous (V-V) ECMO can offer both respiratory and hemodynamic support and is widely used as intraoperative ECMO, generally in patients with pulmonary hypertension and right ventricular dysfunction. While there are alternative cannulation strategies that vary according to institutional practice, V-A ECMO traditionally involves venous drainage from the femoral vein and reinfusion into the femoral artery. In this ‘peripheral’ configuration, the blood perfusing the brain, heart, and upper extremities comes from the native lungs and ECMO flow, and may contain inadequate oxygenation depending on the cardiac output and ECMO flow. From a hemodynamics point of view, peripheral V-A ECMO decreases the right ventricle preload and increases the left ventricle afterload. Additionally, ischemia of the lower limbs can occur if they are not perfused distal to the cannulation site. Ius et al. preferred peripheral cannulation and reported ECMO-related vascular complications in 36 of 311 patients (12%): leg ischemia ( $n = 18$ ), bleeding from cannulation sites ( $n = 5$ ), retrograde type B acute dissection ( $n = 1$ ), arteriovenous fistula ( $n = 3$ ), lymphatic leakage ( $n = 3$ ), deep venous thrombosis ( $n = 2$ ), post-discharge stenosis of the right external iliac and right anterior tibial arteries ( $n = 2$ ), and post-discharge arteriovenous fistula ( $n = 1$ ) [17]. Reeb et al. reported that peripheral V-A ECMO should not be used as a first-line ECMO strategy in cases of isolated lung failure [18]. Aigner et al. reported that peripheral cannulation will be especially useful for an anteroaxillary approach with smaller thoracotomy, although it produces considerable local morbidity in the groin, which involves vascular complications and lymphatic fistulas [13]. The main alternative route is central cannulation, which is beneficial in cases that involve a clamshell incision and can avoid potential complications in the groin. Nevertheless, central V-A ECMO does not involve a vent or sucker, and does not allow for cardioplegia [18]. Central and peripheral ECMO both use a closed circuit with elevated negative pressures, which creates a potential for catastrophic air embolism. During central V-A ECMO, it may be helpful

to tie an umbilical tape around the cannula and right atrial wall to prevent air suctioning around the drainage cannula [18]. Bermudez et al. used an integrated ECMO and CPB system, which recognized significant air embolisms (> 3 mm) and allowed for immediate full CPB (without a circuit change) if necessary, because it included a venous reservoir placed in parallel [8]. Thomas et al. introduced the use of a hybrid ECMO-CPB circuit, which can facilitate easy and immediate conversion to full CPB without interruption of ECC [19]. The conversion to full CPB will be considered when a significant amount of air enters the ECMO circuit, and when the anesthesiologist is unable to keep up with fluid requirements, such as during severe bleeding [19]. Among the 7 studies that were included in the meta-analysis, only 2 studies involved central arterial cannulation [3, 9]. Bermudez et al. preferred bilateral anteroaxillary thoracotomy as the surgical approach for double LTx and also favored a peripheral approach using the right femoral vein and artery if there was no femoral artery calcification or disease [8]. Nevertheless, those studies involved different periods and were published in different years, which suggests that there may have been changes during recent years.

### Heparinization strategy

The heparinization strategies for the studies included in the meta-analyses were generally high-dose heparin for CPB and low-dose heparin for ECMO, although Bittner et al. used high-dose heparin in 4 ECMO cases [12]. The heparin doses for ECMO were 5000 IU of unfractionated heparin [2], 5000 IU of unfractionated heparin plus additional heparin to achieve an activated clotting time (ACT) of 180–200 s [3], high-dose heparin (> 150 IU/kg) or low-dose heparin (0–150 IU/kg) [5], a bolus of 3000–5000 units [9], a bolus of 75 IU/kg and additional heparin to achieve an ACT of 160–180 s in prolonged cases [13], and an initial bolus of 5,000 IU to maintain an ACT of 180–250 s [8]. An additional report by Reeb et al. targeted an ACT of 180–200 s for V-A ECMO [18], while Hoetzenecker et al. used a single heparin dose of 40 units/kg and no monitoring based on the ACT [16]. To date, the ideal heparin dose for anticoagulation during ECMO is still a matter of debate. At Kyoto University Hospital, patients initially receive 1000 units of heparin with adjustment to maintain an ACT of 160–200 s. Gratz et al. reported the use of low molecular weight heparin (LMWH) compared with the use of unfractionated heparin (UFH) for preoperative and/or postoperative ECMO; there was no difference between the two groups with regard to serious bleeding, and the proportion of patients experiencing thromboembolic events was significantly higher in the UFH group than in the LMWH group [20]. LMWH might be an alternative to UFH, but further studies will be needed.

### Comparison with off-pump

The differences among ECMO, CPB, and off-pump are summarized in Table 1. Aigner et al. [13] reported that the group with no support had significantly shorter durations of intubation and ICU stay as well as significantly better survival. Bermudez et al. reported that the off-pump group had significantly better outcomes in terms of the duration of mechanical ventilation, reintubation, tracheostomy, duration of ICU and hospital stay, and survival at 30 days, 6 months, and 1 year [8]. Another study by Ius et al. reported that a group without ECMO had significantly better results in terms of postoperative ECMO, intraoperative blood product usage, repeat thoracotomy for bleeding, new dialysis, grade 2–3 PGD post-transplant, atrial fibrillation, tracheostomy, ventilation time, and duration of ICU and hospital stay [21].

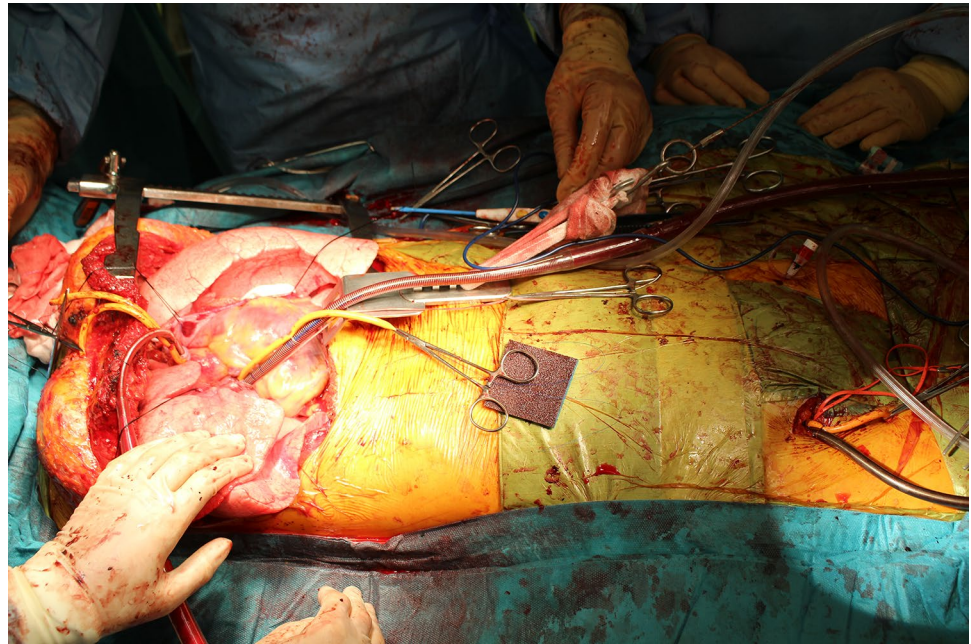
### Strategy at Kyoto University

At Kyoto University Hospital, we consider an off-pump procedure when the recipient has stable hemodynamic and respiratory statuses. However, we consider ECMO when the patient has hypercapnia or pulmonary hypertension before or after general anesthesia induction, when hemodynamic instability or pulmonary hypertension occurs after clamping of the right or left pulmonary artery, when the graft is relatively small, or when the chest cavity is small and it will be difficult to maintain a good surgical field (Fig. 1). Furthermore, CPB is mandatory in some cases, such as when the patient requires concomitant intracardiac repair, when single lung ventilation is difficult, or when it is difficult to clamp the pulmonary artery or left atrium with a sufficient cuff.

### Intraoperative ECMO for cadaveric single LTx

A registry-based study by the International Society of Heart and Lung Transplantation revealed that the outcomes of bilateral LTx are better than those of single LTx. In addition, the number of double LTx procedures has been increasing, while the global number of single LTx procedures has remained fairly stable. However, unlike in North America and Europe, the situation is markedly different in Japan, which has an extreme donor shortage. Thus, single LTx is performed unless the recipient has pulmonary hypertension or infection. The number of single LTx procedures is still increasing based on registry analysis performed by the Japanese Society of Lung and Heart–Lung Transplantation, with 56% of cadaveric LTx procedures involving single LTx in 2019. However, we could not identify any reports regarding the ECC strategy for single

**Fig. 1** Intraoperative photo of extracorporeal membrane oxygenation (ECMO) at Kyoto University. Central ECMO was established via arterial cannulation of the ascending aorta and venous cannulation from the right atrium to the superior vena cava and right femoral vein



LTx, and we hope to introduce our strategy at Kyoto University Hospital.

In our institution, patients undergoing right-side single LTx are always placed on the table in the supine position, and ECMO is established via inflow cannulation of the ascending aorta and draining cannulation from the right atrium to the superior vena cava and right femoral vein. We use two drainage cannulas to ensure stable drainage even if cardiac compression occurs during manipulations to properly expose the hilum for the anastomoses. Right-side single LTx is performed using a hemi-clamshell incision to ensure an adequate surgical field. Patients who require left-side single LTx and will not need ECMO are placed in the right recumbent position and a posterolateral incision is used. However, patients who require left-side single LTx and may need ECMO are first placed in the supine position, and the right femoral artery and vein are secured to facilitate femoro-femoral bypass if necessary. The patient is then moved to the right semi-recumbent position and a posterolateral incision is used. We believe that the anterolateral approach creates a more challenging surgical field because of the heart's position. When the ECMO flow is not sufficient, it is not difficult to change the position of the cannula after the table is turned. Heparinization is initiated using 1,000 units of heparin and adjusted to achieve an ACT of 160–200 s during the ECC.

### ECMO use as a bridge to LTx

There has been increasing use of ECMO during recent decades as a bridge to LTx in critically ill patients. The United Organ Sharing Network data registry indicates

that, among 21,927 patients who underwent LTx during 2000–2014, ECMO was used as a bridge strategy for 414 adults. There are no universally accepted guidelines regarding this strategy, which leaves the decision to each transplant center. Looer et al. [22] reported that the indications for bridging ECMO to LTx in potential candidates were refractory hypoxemia, hypercarbia, or right heart failure despite optimal medical management, and suggested that the decision to initiate ECMO should be made by a multidisciplinary team based on reasonable endpoints, cannulation strategies, management goals, and expected outcomes. Chiumello et al. performed a systematic review of 14 retrospective studies with 441 patients who went ECMO bridging to LTx [23]. All 14 studies reported the 1-year post-transplant survival rates, which were 50–70% in 5 studies, 70–90% in 4 studies, and up to 90% in 2 studies. Among these reports, Fuehner et al. applied an awake ECMO strategy to avoid intubation and general anesthesia, and reported that it provided significantly better survival than mechanical ventilation (80% versus 50%) [24]. Fuehner et al. and Crotti et al. also reported that ECMO support, as an alternative to invasive mechanical ventilation, seems to achieve better outcomes than when it was combined with invasive respiratory assistance [24, 25]. However, Chiumello et al. noted that the data were derived from very experienced centers and may not be generalizable to other centers, which led them to conclude that the current evidence does not support a firm conclusion regarding the efficacy of ECMO as a bridge to LTx [23]. The latest outcomes for ECMO as a bridge to LTx were from a high-volume transplant center in Toronto [26]. In that case series, ECMO was used in 71

adults as an intended bridge to LTx, with 11 patients (16%) who required ECMO bridging to re-transplantation. The median ECMO duration before LTx was 10 days (range: 0–95 days), and the authors concluded that the bridging provided good short-term and long-term outcomes when it was performed before the first LTx, although it was associated with significantly shorter survival in patients who underwent re-transplantation [26].

The cannulation strategy should be based on the intention of achieving early ambulation, preventing muscle weakness, and minimizing ventilator-associated complications. In addition, the treatment strategy should be based on the estimated time spent waiting to receive the donor grafts. Thus, the final strategy will be based on the specific transplant center and the patient's status. Patients with respiratory failure only require a V-V or V-A configuration. Early ambulation might be achieved using a single-lumen jugular cannula [27, 28], although recirculation might occur and experience is needed to ensure accurate positioning. Other centers will use conventional jugular-femoral or femoro-femoral ECMO. In patients with only hypercapnic respiratory failure, a small caliber double-lumen cannula will be adequate [29]. Patients with pulmonary hypertension will need V-A ECMO to protect against right ventricular dysfunction, and a new a double-lumen cannula directed to the pulmonary trunk might be beneficial. Diaz-Guzman et al. introduced the PROTEK Duo double-lumen cannula (Cardiac Assist, Inc., Pittsburgh PA), which was developed to support patients with right heart failure by allowing effective decompression of the right atrium and right ventricle while providing adequate antegrade flow into the pulmonary artery. The cannula is placed percutaneously under fluoroscopy guidance, and the right internal jugular vein is preferred in patients with severe pulmonary hypertension and right-sided heart failure. Positioning of the distal cannula within the right ventricle outflow tract is simple and allows for prolonged deployment in ambulatory patients who are awaiting LTx [30].

The next consideration is the transition from the pre-transplant bridging ECMO configuration to the intraoperative ECMO configuration. Hashimoto et al. from the Toronto group reported the transition from a pre-transplant V-V bridge to intraoperative ECMO among 34 patients with a median bridging duration of 12 days [31]. Three patients required intraoperative CPB, 20 patients continued to use V-V ECMO, and 11 patients were switched to V-A ECMO because of hemodynamic compromise. Two strategies were used to transition from bridge V-V ECMO to intraoperative V-A ECMO, and the inflow cannula was inserted into the ascending aorta in all cases. One strategy involved venovenous arterial support, and the aortic inflow cannula was connected to the existing venous inflow cannula using a Y-shape adapter. The other strategy involved two separate ECMO circuits, and the second circuit consisted of an

outflow cannula to the right atrium. No significant difference in the 1-year survival rate was observed when V-A and V-V ECMO were compared during LTx [31].

## Conclusion

Meta-analyses and other reports have identified better results in the ECMO group, although there are no prospective randomized trials to provide high-quality data regarding this relationship. Nevertheless, advances in ECMO technology may allow intraoperative ECMO to replace CPB, depending on the specific indication, the patient's status, and the institution's experience. Pre-transplant bridge ECMO has also been performed worldwide with favorable outcomes, although additional data are needed from experienced transplant centers.

## Compliance with ethical standards

**Conflicts of interest** The authors of this manuscript have no conflicts of interest to disclose.

## References

1. Marczin N, Royston D, Yacoub M. Pro: lung transplantation should be routinely performed with cardiopulmonary bypass. *J Cardiothorac Vasc Anesth.* 2000;14(6):739–45.
2. Ius F, Kuehn C, Tudorache I, Sommer W, Avsar M, Boethig D, et al. Lung transplantation on cardiopulmonary bypass support: venoarterial extracorporeal membrane oxygenation outperformed cardiopulmonary bypass. *J Thorac Cardiovasc Surg.* 2012;144(6):1510–6.
3. Machuca TN, Collaud S, Mercier O, Cheung M, Cunningham V, Kim SJ, et al. Outcomes of intraoperative extracorporeal membrane oxygenation versus cardiopulmonary bypass for lung transplantation. *J Thorac Cardiovasc Surg.* 2015;149(4):1152–7.
4. McRae K. Con: lung transplantation should not be routinely performed with cardiopulmonary bypass. *J Cardiothorac Vasc Anesth.* 2000;14(6):746–50.
5. Hoechter DJ, von Dossow V, Winter H, Müller HH, Meiser B, Neurohr C, et al. The Munich Lung Transplant Group. The Munich Lung Transplant Group: Intraoperative extracorporeal circulation in lung transplantation. *Thorac Cardiovasc Surg.* 2015;63(8):706–14.
6. Diamond JM, Lee JC, Kawut SM, Shah RJ, Localio AR, Bellamy SL, et al. Clinical risk factors for primary graft dysfunction after lung transplantation. *Am J Respir Crit Care Med.* 2013;187(5):527–34.
7. Ko WJ, Chen YS, Lee YC. Replacing cardiopulmonary bypass with extracorporeal membrane oxygenation in lung transplantation operations. *Artif Organs.* 2001;25(8):607–12.
8. Bermudez CA, Shiose A, Esper SA, Shigemura N, D'Cunha J, Bhamra JK, et al. Outcomes of intraoperative venoarterial extracorporeal membrane oxygenation versus cardiopulmonary bypass during lung transplantation. *Ann Thorac Surg.* 2014;98(6):1936–42 (**discussion 1942–3**).

9. Biscotti M, Yang J, Sonett J, Bacchetta M. Comparison of extracorporeal membrane oxygenation versus cardiopulmonary bypass for lung transplantation. *J Thorac Cardiovasc Surg.* 2014;148(5):2410–5.
10. Hoechter DJ, Shen Y-M, Kammerer T, Günther S, Weig T, Schramm R, et al. Extracorporeal circulation during lung transplantation procedures: a meta-analysis. *ASAIO J.* 2017;63(5):551–61.
11. Magouliotis DE, Tasiopoulou VS, Svokos AA, Svokos KA, Zacharoulis D. Extracorporeal membrane oxygenation versus cardiopulmonary bypass during lung transplantation: a meta-analysis. *Gen Thorac Cardiovasc Surg.* 2018;66(1):38–47.
12. Bittner HB, Binner C, Lehmann S, Kuntze T, Rastan A, Mohr FW. Replacing cardiopulmonary bypass with extracorporeal membrane oxygenation in lung transplantation operations. *Eur J Cardio Thorac Surg.* 2007;31(3):462–7 (**discussion 467**).
13. Aigner C, Wisser W, Taghavi S, Lang G, Jaksch P, Czyzewski D, et al. Institutional experience with extracorporeal membrane oxygenation in lung transplantation. *Eur J Cardio Thorac Surg.* 2007;31(3):468–73 (**discussion 473–4**).
14. Yeo HJ, Kim DH, Jeon D, Kim YS, Cho WH. Low-dose heparin during extracorporeal membrane oxygenation treatment in adults. *Intensive Care Med.* 2015;41(11):2020–1.
15. Soluri-Martins A, Sutherland Y, Silva PL, Pelosi P, Rocco PR. How to minimise ventilator-induced lung injury in transplanted lungs: the role of protective ventilation and other strategies. *Eur J Anaesthesiol.* 2015;32(12):828–36.
16. Hoetzenecker K, Benazzo A, Stork T, Sinn K, Schwarz S, Schweiger T, et al.; Vienna Lung Transplant Group. Bilateral lung transplantation on intraoperative extracorporeal membrane oxygenator: an observational study. *J Thorac Cardiovasc Surg.* 2020;160(1):320–327.e1
17. Ius F, Aburahma K, Boethig D, Salman J, Sommer W, Draeger H, et al. Long-term outcomes after intraoperative extracorporeal membrane oxygenation during lung transplantation. *J Heart Lung Transplant.* 2020;39(9):915–25.
18. Reeb J, Olland A, Renaud S, Lejay A, Santelmo N, Massard G, et al. Vascular access for extracorporeal life support: tips and tricks. *J Thorac Dis.* 2016;8(Suppl 4):S353–63.
19. Thomas M, Martin AK, Allen WL, Makey IA, Renew JR, Rodrigues ES, et al. Lung transplantation using a hybrid extracorporeal membrane oxygenation circuit. *ASAIO J.* 2020;66:e123–5.
20. Gratz J, Pausch A, Schaden E, Baierl A, Jaksch P, Erhart F, et al. Low molecular weight heparin versus unfractionated heparin for anticoagulation during perioperative extracorporeal membrane oxygenation: a single center experience in 102 lung transplant patients. *Artif Organs.* 2020;44(6):638–46.
21. Ius F, Sommer W, Tudorache I, Avsar M, Siemieni T, Salman J, et al. Five-year experience with intraoperative extracorporeal membrane oxygenation in lung transplantation: indications and midterm results. *J Heart Lung Transplant.* 2016;35(1):49–58.
22. Loor G, Simpson L, Parulekar A. Bridging to lung transplantation with extracorporeal circulatory support: when or when not? *J Thorac Dis.* 2017;9(9):3352–61.
23. Chiumello D, Coppola S, Froio S, Colombo A, Del Sorbo L. Extracorporeal life support as bridge to lung transplantation: a systematic review. *Crit Care.* 2015;19:19.
24. Fuehner T, Kuehn C, Hadem J, Wiesner O, Gottlieb J, Tudorache I, et al. Extracorporeal membrane oxygenation in awake patients as bridge to lung transplantation. *Am J Respir Crit Care Med.* 2012;185(7):763–8.
25. Crotti S, Iotti GA, Lissoni A, Belliato M, Zanierato M, Chierichetti M, et al. Organ allocation waiting time during extracorporeal bridge to lung transplant affects outcomes. *Chest.* 2013;144(3):1018–25.
26. Hoetzenecker K, Donahoe L, Yeung JC, Azad S, Fan E, Ferguson ND, et al. Extracorporeal life support as a bridge to lung transplantation—experience of a high-volume transplant center. *Thorac Cardiovasc Surg.* 2018;155(3):1316–1328.e1.
27. Rehder KJ, Turner DA, Hartwig MG, Williford WL, Bonadonna D, Walczak RJ Jr, et al. Active rehabilitation during extracorporeal membrane oxygenation as a bridge to lung transplantation. *Respir Care.* 2013;58(8):1291–8.
28. Turner DA, Cheifetz IM, Rehder KJ, Williford WL, Bonadonna D, Banuelos SJ, et al. Active rehabilitation and physical therapy during extracorporeal membrane oxygenation while awaiting lung transplantation: A practical approach. *Crit Care Med.* 2011;39(12):2593–8.
29. Abrams DC, Brenner K, Burkart KM, Agerstrand CL, Thomashow BM, Bacchetta M, et al. Pilot study of extracorporeal carbon dioxide removal to facilitate extubation and ambulation in exacerbations of chronic obstructive pulmonary disease. *Ann Am Thorac Soc.* 2013;10(4):307–14.
30. Diaz-Guzman E, Sharma NS, Wille K, Hoopes CW. Use of a novel pulmonary artery cannula to provide extracorporeal membrane oxygenation as a bridge to lung transplantation. *J Heart Lung Transplant.* 2016;35(8):1051–3.
31. Hashimoto K, Hoetzenecker K, Yeung JC, Jeagal L, Donahoe L, Pierre A, et al. Intraoperative extracorporeal support during lung transplantation in patients bridged with venovenous extracorporeal membrane oxygenation. *J Heart Lung Transplant.* 2018;37(12):1418–24.

**Publisher's Note** Springer Nature remains neutral with regard to jurisdictional claims in published maps and institutional affiliations.