



Contents lists available at [ScienceDirect](#)

Trauma Case Reports

journal homepage: <http://www.journals.elsevier.com/trauma-case-reports/>



Case Report

An unduly delayed presentation of an “isolated segment of ileum” after blunt abdominal trauma with full recovery

H.K.C. Lakmal*, D. Rupasinghe, B.L. Perera

National Hospital Sri Lanka, Colombo, Sri Lanka

ARTICLE INFO

Article history:

Accepted 7 April 2015

Available online 7 May 2015

Introduction

Small bowel injury (SBI) is a rare but significant complication after blunt abdominal trauma (BAT). Delayed presentations of bowel perforations have a high morbidity and mortality due to high faecal contamination as it leads to peritonitis. Diagnosis of an isolated SBI in trauma victims, who are otherwise healthy, is a challenging issue unless there is a high degree of suspicion. Majority of blunt abdominal trauma, associated with bowel injuries, are caused by motor vehicle accidents (MVAs). In this research study we are reporting a case of a delayed presentation of avulsion of the terminal ileum due blunt abdominal trauma after a motor vehicle accident (MVA).

Case report

A 57-year old male was admitted to the surgical casualty ward with severe lower abdominal pain and high fever of 7 days in duration. His history indicated an incident of blunt trauma to lower abdomen whilst driving a motorised trishaw. This incident had taken place 10 days prior to the admission to the hospital. His lower abdomen had been compressed by the handlebar of the trishaw and he was admitted to emergency department of the local hospital. Chest and pelvic X-rays and FAST (focused abdominal sonography for trauma) scan were done and the patient was discharged with analgesics as investigations indicated that he was clinically normal. Patient was asymptomatic for 2 days and then on the third day, he developed abdominal pain and fever. He was readmitted to the local hospital on day 4 and was investigated for abdominal pain. On the 7th

* Corresponding author at: 374, Dikhenapura, Munagama, Horana, 12400 Sri Lanka. Tel.: +94 775292757.

E-mail addresses: kasunlakmal@gmail.com (H.K.C. Lakmal), drdamindarupasinghe@yahoo.com (D. Rupasinghe), blalithp@yahoo.com (B.L. Perera).

day, he developed absolute constipation, vomiting and high fever and was transferred to the national hospital for further management and investigation.

Upon admission, the patient had fever with chills and persistent vomiting. The patient was in septic shock and abdominal examination revealed a distinctive palpable mass in right lower quadrant. Patient was resuscitated with Intravenous (IV) fluids and IV antibiotics were started. Routine blood samples were drawn, which revealed signs of infection. The blood counts during the initial investigations are given below.

- White blood cells: $33.4 \times 10^3/\text{mm}^3$
- C-reactive protein: 93.7 mg/l
- Deranged serum creatinine: 163 micromol/l
- Clotting profile: INR-1.6

Abdominal X-rays showed multiple dilated small bowel loops and contrast enhanced computed tomography (CT) of the abdomen, revealed an ileal transection proximal to the ileocaecal junction with faecal collection (Fig. 1).

An Emergency Laparotomy was performed and an isolated ileal segment of 15 cm was found adherent to peritoneal surface of anterior abdominal wall. This segment was detached from the ileum, 12 cm proximal to the ileocaecal junction. There was an omental mass covered with faeces with impending entero-cutaneous fistula formation to anterior abdominal wall. The rest of the peritoneal cavity showed minimal faecal contamination. The diseased segment removed and a double barrel ileostomy was made after thorough peritoneal lavage. The patient recovered without significant morbidity and was discharged (How many days after? Its more comprehensive if this is mentioned). He was then readmitted six weeks later for ileostomy reversal and was discharged after full recovery.

Discussion

MVAs are the commonest reason for blunt abdominal trauma, followed by interpersonal violence and falling from a height [1,2]. The small bowel is the most commonly injured hollow viscera and third commonest organ injured in BAT [3]. Increased intraluminal pressure as a result of elevated intra-abdominal pressure, tears and avulsions from fixed points of attachment, and crushing against the spine are the proposed pathophysiological causes of SBI. According to our knowledge, this is the first report of SBI in BAT after an incident of handlebar trauma in motorised trishaw accident. Secondly, this case is unique as this the first case of delayed

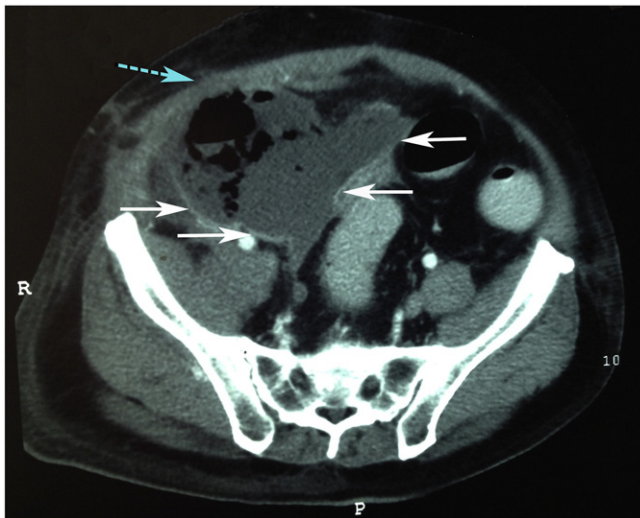


Fig. 1. CECT abdomen 10 days after initial trauma with faecal collection (arrows) with impending fistulous tract to anterior abdominal wall (dashed arrow).

presentation of isolated segment of bowel after BAT. There is only one other case report with similarity to the present case scenario [4].

SBI after BAT can be reliably diagnosed by clinical examination in only 30% of the cases [6]. Concomitant neurological trauma and usage of alcohol, causing reduced level of consciousness, further reduces the reliability of physical assessment of BAT [7]. Current evidence is that the free air under the diaphragm on erect plain chest radiographs is of poor sensitivity [8].

FAST examination of blunt abdominal trauma has a good sensitivity for the detection of free fluid but less in the detection of intestinal injuries [9,10]. Limited amount of bleeding, paralytic ileus after bowel injury, and operator factors may have been the cause for negative FAST in this case of isolated SBI. But there is evidence that delayed repeat ultrasound scans may increase the sensitivity [11].

CT abdomen is an investigation of choice with a sensitivity up to 92%, specificity up to 94% in diagnosing SBI after BAT [8,12,13]. CT evidence of contrast extravasation and/or extra luminal air are diagnostic of bowel injury and free fluid without solid organ injury, small bowel thickening and dilatation are suggestive features [8,13]. However, it should be noted that the CT has as approximately 13% false negative rate which challenges its role as gold standard [14]. Diagnostic peritoneal lavage (DPL) has also a place in detecting hollow organ perforation after BAT [15,16]. Laparoscopy can identify SBI in BAT effectively in stable patients and improve morbidity and mortality [17,18]. Our case confirms the abovementioned findings where imaging has failed the early diagnosis of SBI. This case confirms that the high degree of clinical suspicion with repeated investigations is the only option for early detection of isolated SBI in BAT.

Time elapsed until surgery has been identified as a major factor causing mortality following SBI. Peritoneal soiling and the presence of other nonintestinal lesions have all been identified as independent factors affecting the prognosis [19]. When surgery is delayed more than 24 hour mortality can rise more than 50% [19].

Conclusion

Even though our patient had a remarkable recovery, BAT related isolated bowel injury carries a significant morbidity and mortality due to diagnostic delays. Currently the available investigations still carry variable sensitivity or specificity in diagnosis of SBI in BAT. This condition is further worsened due to the variance of the availability of facilities such as CT in the Asian countries. We suggest that patients with blunt abdominal trauma with high energy handlebar injuries should have a CECT abdomen to exclude bowel injury regardless of the symptoms. If CT facilities are not available, patient should be monitored for delayed symptoms and signs at least for 24 h with a delayed ultrasound scan or DPL before discharging from the hospital.

To our knowledge, medical literature about specific injury patterns of BAT following MVAs associated with motorised trishaws is sparse. So we conclude that further studies should be conducted in this regard in order to implement better preventive strategies.

Conflict of interest

No conflicts of interest.

Acknowledgements

Dr. S.A.S. Gunawardena, Consultant Urologist, National Hospital Sri Lanka, Colombo, is thanked for reviewing the manuscript.

References

- [1] J. Smith, E. Caldwell, S. D'Amours, B. Jalaludin, M. Sugrue, Abdominal trauma: a disease in evolution, *ANZ J. Surg.* 75 (2005) 790–794.
- [2] M.A. Gad, A. Saber, S. Farrag, M.E. Shams, G.M. Ellabban, Incidence, patterns, and factors predicting mortality of abdominal injuries in trauma patients, *N. Am. J. Med. Sci.* 4 (2012) 129–134.
- [3] D.D. Watts, S.M. Fakhry, Incidence of hollow viscus injury in blunt trauma: an analysis from 275,557 trauma admissions from the East multi-institutional trial, *J. Trauma* 54 (2003) 289–294.
- [4] R. Vijayan, K. Toe, Delayed complete small-bowel and mesenteric transection following seemingly minor blunt abdominal trauma, *BMJ Case Rep.* 2013 (2013).
- [6] J. Guarino, J.M. Hassett Jr., F.A. Luchette, Small bowel injuries: mechanisms, patterns, and outcome, *J. Trauma* 39 (1995) 1076–1080.

- [7] W.S. Hoff, M. Holevar, K.K. Nagy, L. Patterson, J.S. Young, A. Arrillaga, et al., Practice management guidelines for the evaluation of blunt abdominal trauma: the EAST practice management guidelines work group, *J. Trauma Acute Care Surg.* 53 (2002) 602–615.
- [8] M. Saku, K. Yoshimitsu, J. Murakami, Y. Nakamura, S. Oguri, T. Noguchi, et al., Small bowel perforation resulting from blunt abdominal trauma: interval change of radiological characteristics, *Radiat. Med.* 24 (2006) 358–364.
- [9] M.I. Nnamonu, C.H. Ihezue, A.Z. Sule, V.M. Ramyil, S.D. Pam, Diagnostic value of abdominal ultrasonography in patients with blunt abdominal trauma, *Niger. J. Surg. Res.* 19 (2013) 73–78.
- [10] L. Hoffman, D. Pierce, S. Puumala, Clinical predictors of injuries not identified by focused abdominal sonogram for trauma (FAST) examinations, *J. Emerg. Med.* 36 (2009) 271–279.
- [11] L.H. Blackburne, D. Soffer, M. McKenney, J. Amortegui, C.I. Schulman, B. Crookes, et al., Secondary ultrasound examination increases the sensitivity of the FAST exam in blunt trauma, *J. Trauma* 57 (2004) 934–938.
- [12] J. Sherck, C. Shatney, K. Sensaki, V. Selivanov, The accuracy of computed tomography in the diagnosis of blunt small-bowel perforation, *Am. J. Surg.* 168 (1994) 670–675.
- [13] K.K. Tan, J.Z. Liu, T.S. Go, A. Vijayan, M.T. Chiu, Computed tomography has an important role in hollow viscus and mesenteric injuries after blunt abdominal trauma, *Injury* 41 (2010) 475–478.
- [14] S.M. Fakhry, D.D. Watts, F.A. Luchette, Current diagnostic approaches lack sensitivity in the diagnosis of perforated blunt small bowel injury: analysis from 275,557 trauma admissions from the EAST multi-institutional HVI trial, *J. Trauma* 54 (2003) 295–306.
- [15] K.K. Nagy, R.R. Roberts, K.T. Joseph, R.F. Smith, G.C. An, F. Bokhari, et al., Experience with over 2500 diagnostic peritoneal lavages, *Injury* 31 (2000) 479–482.
- [16] Y.C. Wang, C.H. Hsieh, C.Y. Fu, C.C. Yeh, S.C. Wu, R.J. Chen, Hollow organ perforation in blunt abdominal trauma: the role of diagnostic peritoneal lavage, *Am. J. Emerg. Med.* 30 (2012) 570–573.
- [17] M. Khubutiya, P.A. Yartsev, A.A. Guliaev, V.D. Levitsky, M.A. Tiibekova, Laparoscopy in blunt and penetrating abdominal trauma, *Surg. Laparosc. Endosc. Percutan. Tech.* 23 (2013) 507–512.
- [18] J.J. Johnson, T. Garwe, A.R. Raines, J.B. Thurman, S. Carter, J.S. Bender, et al., The use of laparoscopy in the diagnosis and treatment of blunt and penetrating abdominal injuries: 10-year experience at a level 1 trauma center, *Am. J. Surg.* 205 (2013) 317–320 discussion 21.
- [19] G.R. Faria, A.B. Almeida, H. Moreira, E. Barbosa, P. Correia-da-Silva, J. Costa-Maia, Prognostic factors for traumatic bowel injuries: killing time, *World J. Surg.* 36 (2012) 807–812.