



## Original Article

# Medium-term clinical outcomes of laminoplasty with adjunct short anterior fusion in multilevel cervical myelopathy

Tsung-Chiao Wu<sup>a,†</sup>, Kuang-Ting Yeh<sup>a,b,†</sup>, Ru-Ping Lee<sup>c</sup>, Tzai-Chiu Yu<sup>a,b</sup>, Ing-Ho Chen<sup>a,b</sup>, Cheng-Huan Peng<sup>a</sup>, Kuan-Lin Liu<sup>a</sup>, Jen-Hung Wang<sup>d</sup>, Wen-Tien Wu<sup>a,b,\*</sup>

<sup>a</sup>Department of Orthopedics, Hualien Tzu Chi Hospital, Buddhist Tzu Chi Medical Foundation, Hualien, Taiwan, <sup>b</sup>School of Medicine, Tzu Chi University, Hualien, Taiwan, <sup>c</sup>Institute of Medical Sciences, Tzu Chi University, Hualien, Taiwan, <sup>d</sup>Department of Research, Hualien Tzu Chi Hospital, Buddhist Tzu Chi Medical Foundation, Hualien, Taiwan

<sup>†</sup>Both authors contributed equally to this work.

Received : 10-Oct-2017  
Revised : 22-Nov-2017  
Accepted : 18-Dec-2017

## ABSTRACT

**Objectives:** Expansive open-door laminoplasty (EOLP) is effective for multilevel cervical spondylotic myelopathy (MCSM). When MCSM is combined with one- or two-level segmental kyphosis, instability, or major anterior foci, EOLP with short-segment anterior cervical fusion (ACF) results in good short-term neurological recovery and can preserve postoperative range of motion (ROM). The objective of this study was to evaluate the medium-term clinical outcomes of this procedure and to analyze the risk factors affecting the neurological function at the last follow-up. **Materials and Methods:** A total of 87 patients were enrolled in this retrospective study conducted from January 2007 to May 2011. These patients exhibited MCSM with combined short segmental kyphosis, instability, or major anterior pathology, and received EOLP and short-segment anterior fusion. The follow-up period lasted at least 60 months. The radiographic outcomes were collected from plain radiographs with dynamic views checked preoperatively and at the last follow-up. Neurological status and visual analog scale scores for neck pain were evaluated. Logistic regression analysis was then applied to determine the correlation between radiographic parameters and rates of neurological recovery. **Results:** The mean Japanese Orthopedics Association recovery rate at the last follow-up was 77.8%. The improvement in functional scores and reduction in neck pain were statistically significant. The most influential risk factor affecting neurologic recovery was preoperative functional status. **Conclusions:** EOLP followed by short-segment ACF is a favorable treatment for patients with MCSM with concomitant short-segment kyphosis, instability, or major anterior pathology.

**KEYWORDS:** Anterior major pathology, Expansive open door laminoplasty, Japanese Orthopedic Association recovery rate, Segmental instability or local kyphosis, Short level anterior cervical fusion

## INTRODUCTION

Expansive open-door laminoplasty (EOLP) is an effective surgical method for multilevel cervical spondylotic myelopathy (MCSM) [1,2]. Indirect decompression of the spinal cord, a posterior bony ceiling to protect the neural elements, and motion of the spinal segments can be preserved by expanding the spinal canal posteriorly. However, the posterior procedure is contraindicated in patients with segmental instability, major kyphotic alignment, or major anterior pathology [3,4]. When a patient presents with long-level stenosis combined with short-level segmental instability, local kyphosis, or major anterior pathology, long-level anterior decompression and fusion with or without posterior instrumented fusion may be indicated. We have performed EOLP with essential short-level anterior decompression and fusion for these patients, and the short-term surgical results have been

favorable [5]. This study evaluated the medium-term clinical outcomes of the patients diagnosed with MCSM who received EOLP with short-segment anterior cervical fusion (ACF) and examined the risk factors associated with poor neurological recovery.

## MATERIALS AND METHODS

This study was approved by the Institutional Review Board of Hualien Tzu Chi Hospital, Buddhist Tzu Chi Medical Foundation (IRB101-100). The study was conducted in accordance with the Declaration of Helsinki and was approved


### \*Address for correspondence:

Dr. Wen-Tien Wu,  
Department of Orthopedics, Hualien Tzu Chi Hospital, Buddhist Tzu Chi Medical Foundation, 707, Section 3, Chung-Yang Road, Hualien, Taiwan.  
E-mail: wentien2003@yahoo.com.tw

This is an open access journal, and articles are distributed under the terms of the Creative Commons Attribution-NonCommercial-ShareAlike 4.0 License, which allows others to remix, tweak, and build upon the work non-commercially, as long as appropriate credit is given and the new creations are licensed under the identical terms.

For reprints contact: reprints@medknow.com

**How to cite this article:** Wu TC, Yeh KT, Lee RP, Yu TC, Chen IH, Peng CH, et al. Medium-term clinical outcomes of laminoplasty with adjunct short anterior fusion in multilevel cervical myelopathy. Tzu Chi Med J 2019;31(1):47-51.

Access this article online	
Quick Response Code: 	Website: www.tcmjmed.com
	DOI: 10.4103/tcmj.tcmj_22_18

by the Local Ethics Committee of the institution. Informed written consent was waived because the study was a retrospective data analysis. We retrospectively collected patients' data from the electronic medical records and radiological images of Hualien Tzu Chi Hospital. The patients included in this study were diagnosed with MCSM and had received EOLP with one- or two-level ACF from January 2007 to May 2011, and were followed for at least 5 years. In total, 240 patients matched these selection criteria; 87 of the patients included in this study had the clinical and radiographic data required for a postoperative 5-year follow-up. The clinical data included Japanese Orthopedic Association (JOA) scores [6], Nurick scores, neck disability index (NDI) values [7], and visual analog scale (VAS) scores to assess neurological function and axial neck pain. Improvements to neurologic status were estimated on the basis of the recovery rate as (postoperative JOA score – preoperative JOA score)/(17 – preoperative JOA score) ×100% [8], with a score of 75%–100% considered excellent, 50%–74% good, 25%–49% fair, and 0%–24% poor.

The procedures for determining radiographic parameters from the lateral view plain films of the cervical spine were as follows. Cervical lordosis (CL) was evaluated by measuring the angle between the lower endplate of C2 and the upper endplate of C7. The C2–C7 sagittal vertical axis (SVA) was measured as the distance between the posterosuperior corner of C7 and the vertical line from the center of the C2 body. The C7 slope was measured as the angle between a horizontal line and the superior endplate of C7. The range of motion (ROM) of the neck was determined using the difference of the angles between the lower endplate of C2 and the upper endplate of C7 and was measured using dynamic views. The ACF angle was measured as the Cobb angle of the anterior fusion level.

EOLP was performed according to the methods of Hirabayashi *et al.*[9] and O'Brien *et al.*[10], followed by an anterior approach for a discectomy or corpectomy of anterior pathology. Subsequent interbody fusion was performed using artificial cages and autogenous or allogeneous strut bone grafts, which were fixed using a titanium locking plate-and-screw system (Zephir, Medtronic Sofamor Danek Inc., Memphis, TN, USA). Lateral and dynamic lateral radiographs of the cervical spine were done 3, 6, 12, 36, and 60 months' postoperatively. Computerized tomography (CT) scans were done at the 6-month follow-up to evaluate the union of the laminoplasty hinge sites as well as the stability of the anterior fusion sites. Magnetic resonance imaging (MRI) was done to evaluate the spinal cord condition at 12 and 60 months' postoperatively.

Statistical analyses were performed using SPSS, version 17.0 software (SPSS, Inc., Chicago, IL, USA). The unpaired Student's *t*-test was used to compare preoperative and postoperative parameters. The level of statistical significance was set as *P* < 0.05. Logistic regression analysis was performed to determine the risk factors for poor JOA recovery rates.

**RESULTS**

Table 1 shows the characteristics of the patients the data of 87 patients – 45 men and 42 women with a mean age of 60.5 years – were retrospectively analyzed. All patients

**Table 1: Patient data and pre-and post-operative parameters (n=87)**

	Males	Females	Total
<i>n</i>	45	42	87
Age	59.20±11.51	61.90±13.43	60.51±12.48
ACF level (%)	-	-	-
1	14 (31.1)	13 (31.0)	27 (31.0)
2	31 (68.9)	29 (69.0)	60 (69.0)
CL			
Preoperative	1.9±10.0	0.5±7.2	1.2±8.7
Postoperative	13.6±8.5	10.3±7.6	12.0±8.2
CSVA			
Preoperative	26.7±16.3	17.6±12.7	22.3±15.3
Postoperative	29.6±15.0	21.8±11.6	25.9±13.9
C7 slope			
Preoperative	21.7±10.4	16.6±7.8	19.2±9.5
Postoperative	26.5±9.4	20.2±5.9	23.4±8.5
ACF angle			
Preoperative	1.6±6.1	0.2±6.9	1.0±6.5
Postoperative	9.9±6.9	9.4±6.6	9.6±6.7
NROM			
Preoperative	34.9±13.6	41.4±15.2	38.0±14.7
Postoperative	19.1±9.4	21.0±7.0	20.0±8.3
VAS			
Preoperative	5.9±0.8	5.7±1.2	5.8±1.0
Postoperative	2.7±1.6	3.0±1.4	2.8±1.5
NDI			
Preoperative	33.7±10.5	36.3±8.8	34.9±9.7
Postoperative	15.6±9.9	18.2±8.4	16.9±9.3
JOA score			
Preoperative	8.9±2.9	8.9±2.7	8.9±2.8
Postoperative	15.1±3.2	15.2±2.8	15.2±3.0
Nurick score			
Preoperative	3.0±1.3	3.0±1.2	3.0±1.2
Postoperative	1.5±1.5	1.6±1.3	1.5±1.4
Preserved ROM (%)	54.7±20.5	59.8±26.8	57.5±27.8
JOA recovery rate (%)	77.9±14.8	77.4±12.0	77.8±13.4

Data are presented as *n* or percentage or mean±SD. ACF: Anterior cervical fusion, CL: Cervical lordosis, CSVA: Cervical sagittal vertical axis, JOA: Japanese Orthopedic Association, NDI: Neck disability index, NROM: Neck range of motion, VAS: Visual analog scale, ROM: Range of motion, SD: Standard deviation

received a C3–C6 laminoplasty and C7 partial laminectomy under a diagnosis of C3–C7 MCSM. Twenty-seven patients received adjunct one-level ACF, and the other 60 received adjunct two-level ACF. No differences were observed between men and women in the preoperative mean functional and pain scores. The mean values for the CL, C2–C7 SVA, and C7 slope were lower in females, whereas Neck ROM values were lower in males. The JOA score increased from 8.9 to 15.1 and the mean JOA recovery rate was 77.8%. NDI and Nurick scores also improved from 34.9 to 16.9 and from 3.0 to 1.5, respectively. The average CL decreased drastically from 1.2° to 12°, whereas the average C7 slope significantly increased from 19.2° to 23.4°. The ACF angle increased from 1.0° to 9.6°. The preservation of the average ROM of the neck was 57.5%. The mean VAS score for neck pain at the 5-year follow-up was 2.8. The improvement between pre- and post-operative neurologic

and radiographic parameters, except for the C2–C7 SVA, was significant [Table 2]. The functional outcomes and neck ROM did not differ significantly between those who received one-level ACF and those who received two-level ACF. The risk factors that were significantly correlated with a poor JOA recovery rate were poor preoperative JOA and Nurick scores [Table 3]. The modified  $R^2$  was 0.803. No complications such as exacerbated neurological status or aggravated neck pain were observed during the follow-up period. Similarly, the follow-up lateral view radiographs and CT scans revealed no cases of opened laminae reclosure or anterior fixation failure.

### Case report

A 52-year-old man presented with an unsteady gait, clumsiness in both hands, weakness in the four limbs, and a neck pain VAS score of 5. The preoperative JOA score was 9 and Nurick score was 3. A plain radiograph revealed C5–C6 local

kyphosis (2° kyphosis) with disc space narrowing [Figure 1a]. The preoperative ROM was 22°. A sagittal MRI view revealed C3–C7 stenosis and obvious anterior pathology over C5–C6 [Figure 1b]. C3–C7 anterior fusion with 4-segment anterior cervical discectomy or C5, 6 corpectomy was the usual choice for surgery. We performed a C3–C6 laminoplasty with a C7 partial laminectomy and adjunct C5–C6 ACDF. Five-year postoperatively, the neck pain VAS score was 2, the postoperative JOA score was 15, the Nurick score was 1, and the JOA recovery rate was 75%. The cervical curvature exhibited a 3° lordosis [Figure 1c] and a 13° ROM. Three motion segments were saved and 59.1% ROM was preserved. MRI 5-year postoperatively revealed a patent spinal cord [Figure 1d].

### DISCUSSION

Anterior long-level decompression and fusion with or without posterior long-level fixation is often indicated for patients with MCSM and short-level anterior major pathology or local kyphosis [11]. We applied an alternative surgical choice: EOLP followed by short-level ACF. This study demonstrated good medium-term clinical outcomes in 87 patients. Complications such as dysphonia, dysphagia, construction failure, and adjacent segment disease can occur after long-level ACF [12-15]. EOLP can indirectly and effectively decompress the spinal cord of multilevel cervical stenosis without sacrificing the motion segments [16]. Combined essential-level ACF could solve concomitant anterior pathology and correct cervical lordotic alignment. The ROM of the neck was preserved in more than 50% of these cases because the motion segments were protected by this procedure. Moreover, performing EOLP first can also improve the safety of the ACF procedure because of the posterior shift of the spinal cord [17]. Expansion of the spinal canal may also decrease the risk of impingement of the spinal cord.

Regression logistic analysis revealed that risk factors significantly correlated with neurological recoveries were related to the preoperative neurological status. Numerous factors, including age, duration of myelopathy symptoms, preoperative neurological condition, diabetes, smoking history, and sagittal alignment of the cervical spine, could affect the postoperative outcomes of patients with MCSM [18-20]. The selection of the appropriate surgical treatment, which is controversial among surgeons, also strongly affects the outcomes of patients with MCSM [21-23]. By employing two relatively less invasive surgical techniques, patients with MCSM and anterior short-level major foci, segmental instability, or kyphosis could obtain favorable short- and medium-term clinical results, with significant reductions in the number of complications. Securing opened laminae with titanium miniplates prevents reclosure [2], and the complication rate of C5 palsy decreases through the creation of more medical gutters [24]. Performing essential-level ACF not only removes major pathology and corrects cervical alignment but also minimizes the complications associated with long-level ACF. However, this study has some limitations regarding comparisons of the short-term surgical results of this surgical method as well as comparisons with the surgical results and complications of long-level ACF. Our future studies will address these limitations.

**Table 2: Comparison between pre- and post-operative parameters (n=87)**

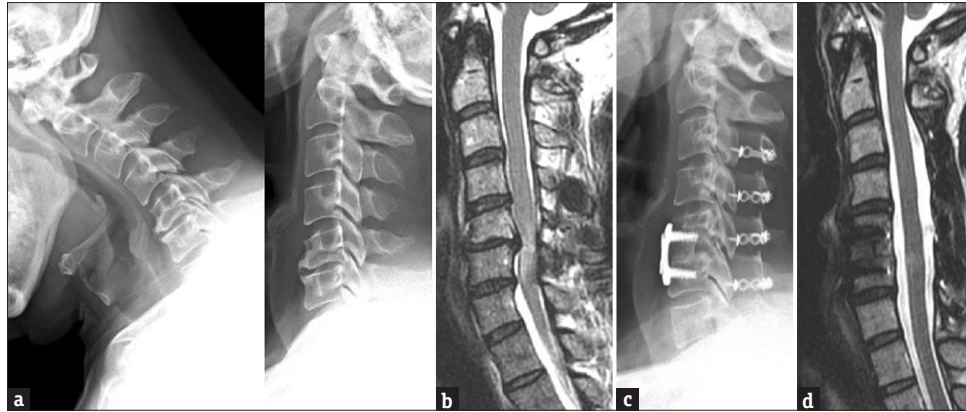Item	Preoperative	Postoperative	P
CL	1.2±8.7	12.0±8.2	<0.001*
CSVA	22.3±15.3	25.9±13.9	0.072
C7 slope	19.2±9.5	23.4±8.5	<0.001*
ACF angle	1.0±6.5	9.6±6.7	<0.001*
NROM	38.0±14.7	20.0±8.3	<0.001*
VAS	5.8±1.0	2.8±1.5	<0.001*
NDI	34.9±9.7	16.9±9.3	<0.001*
JOA score	8.9±2.8	13.8±3.0	<0.001*
Nurick score	3.0±1.2	1.5±1.4	<0.001*

Data are presented as n or mean±SD, \* $P<0.05$  is considered statistically significant. ACF: Anterior cervical fusion, CL: Cervical lordosis, CSVA: Cervical sagittal vertical axis, JOA: Japanese Orthopedic Association, NDI: Neck disability index, NROM: Neck range of motion, VAS: Visual analog scale, SD: Standard deviation

**Table 3: Factors associated with Japanese Orthopedic Association recovery rate (n=87)**

Item	JOA recovery rate		
	$\beta$	SD	P
Intercept	46.947	17.38	0.009*
Age	0.055	0.098	0.579
Gender	-	-	-
Male	2.489	2.343	0.292
Female	References		NA
Preoperative CL	0.280	0.157	0.078
Preoperative CSVA	0.117	0.134	0.385
Preoperative C7 slope	-0.240	0.201	0.236
Preoperative ACF angle	-0.183	0.189	0.338
Preoperative NROM	-0.001	0.095	0.989
Preserved NROM (%)	-0.009	0.008	0.292
Preoperative VAS	0.295	1.138	0.796
Preoperative NDI	0.114	0.138	0.409
Preoperative JOA score	4.310	0.800	<0.001*
Preoperative Nurick score	-8.817	1.843	<0.001*

Data are presented as n or mean±SD, \* $P<0.05$  is considered statistically significant. ACF: Anterior cervical fusion, CL: Cervical lordosis, CSVA: Cervical sagittal vertical axis, JOA: Japanese Orthopedic Association, NDI: Neck disability index, NROM: Neck range of motion, VAS: Visual analog scale, SD: Standard deviation, NA: Not available



**Figure 1:** Radiographic studies of a 47-year-old man. (a) Dynamic plain radiograph of the cervical spine, lateral view, showing C5–C6 fixed local kyphosis. (b) Preoperative cervical spine magnetic resonance imaging T2 sagittal view showing C3–C7 stenosis and C5–C6 local kyphosis with major disc protrusion pathology. (c) Five-year postoperative cervical spine radiograph, lateral view, showing solid fusion of C5–C6 with good fixation of the miniplates of the laminae. (d) Five-year postoperative cervical spine magnetic resonance imaging T2 sagittal view showing an uncompressed, patent spinal cord

## CONCLUSIONS

EOLP is a well-established method to treat MCSM in patients with cervical stability and lordosis, and it preserves cervical motion segments. Adjunct anterior decompression and fusion is a favorable treatment for patients with concomitant short segment kyphosis, instability, or major anterior pathology, making EOLP applicable to almost all cases of MCSM.

## Acknowledgment

This manuscript was edited by Wallace Academic Editing.

## Declaration of patient consent

The authors certify that they have obtained all appropriate patient consent forms. In the form the patient has given his consent for his images and other clinical information to be reported in the journal. The patients understand that his name and initials will not be published and due efforts will be made to conceal their identity, but anonymity cannot be guaranteed.

## Financial support and sponsorship

Nil.

## Conflicts of interest

There are no conflicts of interest.

## REFERENCES

1. Yang HL, Chen GD, Zhang HT, Wang L, Luo ZP. Open-door laminoplasty with plate fixation at alternating levels for treatment of multilevel degenerative cervical disease. *J Spinal Disord Tech* 2013;26:E13-8.
2. Yeh KT, Yu TC, Chen IH, Peng CH, Liu KL, Lee RP, et al. Expansive open-door laminoplasty secured with titanium miniplates is a good surgical method for multiple-level cervical stenosis. *J Orthop Surg Res* 2014;9:49.
3. Yeh KT, Lee RP, Chen IH, Yu TC, Peng CH, Liu KL, et al. Laminoplasty with adjunct anterior short segment fusion for multilevel cervical myelopathy associated with local kyphosis. *J Chin Med Assoc* 2015;78:364-9.
4. Tang HM, Yeh KT, Lee RP, Chen IH, Yu TC, Liu KL, et al. Combined expansive open-door laminoplasty with short-segment lateral mass instrumented fusion for multilevel cervical spondylotic myelopathy with short segment instability. *Ci Ji Yi Xue Za Zhi* 2016;28:15-9.
5. Yoon ST, Raich A, Hashimoto RE, Riew KD, Shaffrey CI, Rhee JM, et al. Predictive factors affecting outcome after cervical laminoplasty. *Spine (Phila Pa 1976)* 2013;38:S232-52.
6. Yonenobu K, Abumi K, Nagata K, Taketomi E, Ueyama K. Interobserver and intraobserver reliability of the Japanese orthopaedic association scoring system for evaluation of cervical compression myelopathy. *Spine (Phila Pa 1976)* 2001;26:1890-4.
7. Schuller W, Ostelo RW, Janssen R, de Vet HC. The influence of study population and definition of improvement on the smallest detectable change and the minimal important change of the neck disability index. *Health Qual Life Outcomes* 2014;12:53.
8. Hirai T, Kawabata S, Enomoto M, Kato T, Tomizawa S, Sakai K, et al. Presence of anterior compression of the spinal cord after laminoplasty inhibits upper extremity motor recovery in patients with cervical spondylotic myelopathy. *Spine (Phila Pa 1976)* 2012;37:377-84.
9. Hirabayashi K, Toyama Y, Chiba K. Expansive laminoplasty for myelopathy in ossification of the longitudinal ligament. *Clin Orthop Relat Res* 1999;359:35-48.
10. O'Brien MF, Peterson D, Casey AT, Crockard HA. A novel technique for laminoplasty augmentation of spinal canal area using titanium miniplate stabilization. A computerized morphometric analysis. *Spine (Phila Pa 1976)* 1996;21:474-83.
11. Williams KE, Paul R, Dewan Y. Functional outcome of corpectomy in cervical spondylotic myelopathy. *Indian J Orthop* 2009;43:205-9.
12. Sasso RC, Ruggiero RA Jr, Reilly TM, Hall PV. Early reconstruction failures after multilevel cervical corpectomy. *Spine (Phila Pa 1976)* 2003;28:140-2.
13. Joseph V, Kumar GS, Rajshekhar V. Cerebrospinal fluid leak during cervical corpectomy for ossified posterior longitudinal ligament: Incidence, management, and outcome. *Spine (Phila Pa 1976)* 2009;34:491-4.
14. Okawa A, Sakai K, Hirai T, Kato T, Tomizawa S, Enomoto M, et al. Risk factors for early reconstruction failure of multilevel cervical corpectomy with dynamic plate fixation. *Spine (Phila Pa 1976)* 2011;36:E582-7.
15. Saunders RL, Pikus HJ, Ball P. Four-level cervical corpectomy. *Spine (Phila Pa 1976)* 1998;23:2455-61.
16. Yeh KT, Yu TC, Chen IH, Peng CH, Liu KL, Wang JH, et al. Comparison of anterior cervical decompression fusion and expansive open door laminoplasty for multilevel cervical spondylotic myelopathy. *Formos J Musculoskelet Disord* 2014;5:1-8.
17. Kawaguchi Y, Nakano M, Yasuda T, Seki S, Hori T, Kimura T, et al. Anterior decompressive surgery after cervical laminoplasty in patients with ossification of the posterior longitudinal ligament. *Spine J* 2014;14:955-63.

18. Machino M, Yukawa Y, Ito K, Inoue T, Kobayakawa A, Matsumoto T, et al. Risk factors for poor outcome of cervical laminoplasty for cervical spondylotic myelopathy in patients with diabetes. *J Bone Joint Surg Am* 2014;96:2049-55.
19. Arnold PM, Fehlings MG, Kopjar B, Yoon ST, Massicotte EM, Vaccaro AR, et al. Mild diabetes is not a contraindication for surgical decompression in cervical spondylotic myelopathy: Results of the AOSpine North America multicenter prospective study (CSM). *Spine J* 2014;14:65-72.
20. Wu FL, Sun Y, Pan SF, Zhang L, Liu ZJ. Risk factors associated with upper extremity palsy after expansive open-door laminoplasty for cervical myelopathy. *Spine J* 2014;14:909-15.
21. Yuan W, Zhu Y, Liu X, Zhou X, Cui C. Laminoplasty versus skip laminectomy for the treatment of multilevel cervical spondylotic myelopathy: A systematic review. *Arch Orthop Trauma Surg* 2014;134:1-7.
22. Liu X, Wang H, Zhou Z, Jin A. Anterior decompression and fusion versus posterior laminoplasty for multilevel cervical compressive myelopathy. *Orthopedics* 2014;37:e117-22.
23. Heller JG, Raich AL, Dettori JR, Riew KD. Comparative effectiveness of different types of cervical laminoplasty. *Evid Based Spine Care J* 2013;4:105-15.
24. Yeh KT, Chen IH, Yu TC, Liu KL, Peng CH, Wang JH, et al. Modified expansive open-door laminoplasty technique improved postoperative neck pain and cervical range of motion. *J Formos Med Assoc* 2015;114:1225-32.