

# Acute Coils Migration Causing Significant M3 Branch Occlusion: A Case Report of Rescue Surgery with Superficial Temporal Artery-Middle Cerebral Artery Bypass

## Abstract

We describe an uncommon case of acute coils migration with significant occlusion of M3 branch and our management of this complication. Balloon-assisted coil placement was performed for an unruptured intracavernous internal carotid artery aneurysm in a 62-year-old woman. After coil placement and balloon deflection, we observed coils migration with significant occlusion of M3 branch. After early clinical deterioration without other neurological symptoms, we decided to perform superficial temporal artery-middle cerebral artery (STA-MCA) bypass to ensure blood flow distal to the occlusion. The patient was discharged without neurological deficit. To the best of our knowledge, this is the first case report about STA-MCA bypass to treat acute coils migration. This technique could represent a successful rescue therapy in case of acute coils migration that cannot be retrieved by endovascular tools or in case where distal and deep location of migrated coils contraindicate surgical removal.

**Keywords:** Balloon-assisted coiling, coil migration, intracranial aneurysm, STA-MCA bypass, vessel occlusion

## Introduction

Endovascular coiling has become the mainstay of treatment for both ruptured and unruptured aneurysms in the majority of centers worldwide.<sup>[1,2]</sup> Advances in endovascular techniques, including balloons-assisted coiling procedure, have been applied in intracranial aneurysms. Coil migration is a potential rare complication of this kind of procedure and may have catastrophic consequences if not adequately managed.<sup>[3]</sup> We present here a rare complication of acute coil migration after balloon-assisted coil embolization.

## Case Report

A 62-year-old woman, with maternal positive history for subarachnoid hemorrhage, presented with incidental left intracavernous internal carotid artery (ICA). During computed tomography angiography (CTA) follow-up, the aneurysm slowly increased (3.4 mm × 3.7 mm × 3.9 mm, neck 3.00 mm, aspect ratio AR 1.13), so she underwent balloon-assisted coil

placement [Figure 1a and b]. A balloon catheter (Shoryu 4 × 15) was placed in the proximal supraclinoid segment of ICA. A microcatheter (Excelsior SL-10) was then introduced into the aneurysm and the aneurysmal dome was embolized with (Axium 3 × 8, 1.5 × 2) coils [Figure 1c and d]. The aneurysm seemed to be completely embolized but, after balloon deflation, coils migrated and caused a significant occlusion of M3 branch with severe reduction of flow [Figure 1e-h]. After early clinical deterioration (Glasgow Coma Scale score 14) without other neurological deficit, considering migrated coils too deep and the occluded vessel too small to perform endovascular/surgical removal of the coils, we decided to perform bypass to restore cerebral perfusion distal to the occlusion. A left frontotemporal approach [Figure 2a] was performed, followed by a bypass between the frontal branch of the STA and M3 branch. Microdoppler confirmed the patency of the bypass. Indocyanine green 800 flow was used to evaluate the risk of cerebral hyperperfusion syndrome.<sup>[4]</sup>

This is an open access journal, and articles are distributed under the terms of the Creative Commons Attribution-NonCommercial-ShareAlike 4.0 License, which allows others to remix, tweak, and build upon the work non-commercially, as long as appropriate credit is given and the new creations are licensed under the identical terms.

For reprints contact: reprints@medknow.com

**Riccardo Stanzani<sup>1,2,3</sup>,  
Yasuhiro Yamada<sup>3</sup>,  
Tukasa Kawase<sup>3</sup>,  
Gowtham Devareddy<sup>3</sup>,  
Chandratej Kadam<sup>3</sup>,  
Firuz Shukurov<sup>3</sup>,  
Chavan Vaibhav<sup>3,4</sup>,  
Yoko Kato<sup>3</sup>**

<sup>1</sup>Department of Neurosurgery, Neurosurgery Unit AOU Policlinico di Modena – OCSAE Modena Hospital, Modena, <sup>2</sup>Department of Neurosurgery, Neurosurgical Residency Program, University of Padua, Padua, Italy, <sup>3</sup>Department of Neurosurgery, Bantane Hospital, Fujita Health University, Nagoya, Japan, <sup>4</sup>Department of Neurosurgery, Krishna Institute of Medical Sciences, Karad, Maharashtra, India

## Address for correspondence:

Dr. Riccardo Stanzani,  
Department of Neurosurgery,  
Neurosurgery Unit Aou  
Policlinico Di Modena – Ocsae  
Modena Hospital, Modena,  
Italy.  
Department of Neurosurgery,  
Neurosurgical Residency  
Program, University of Padua,  
Padua, Italy.  
Department of Neurosurgery,  
Bantane Hospital, Fujita Health  
University, Nagoya, Japan.  
E-mail: stanza.richi@gmail.com

## Access this article online

Website: www.asianjns.org

DOI: 10.4103/ajns.AJNS\_349\_19

## Quick Response Code:



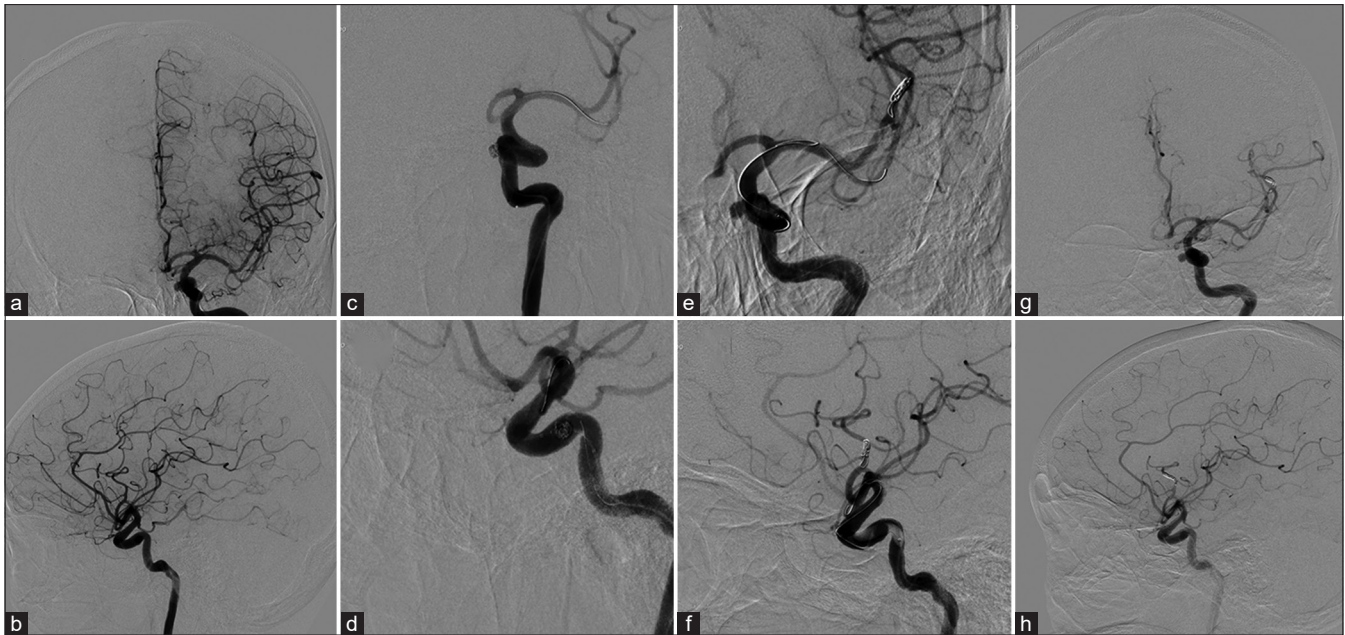
**How to cite this article:** Stanzani R, Yamada Y, Kawase T, Devareddy G, Kadam C, Shukurov F, et al. Acute coils migration causing significant M3 branch occlusion: A case report of rescue surgery with superficial temporal artery-middle cerebral artery bypass. Asian J Neurosurg 2020;15:428-30.

Submitted: 02-Dec-2019

Revised: 03-Jan-2020

Accepted: 09-Apr-2020

Published: 29-May-2020

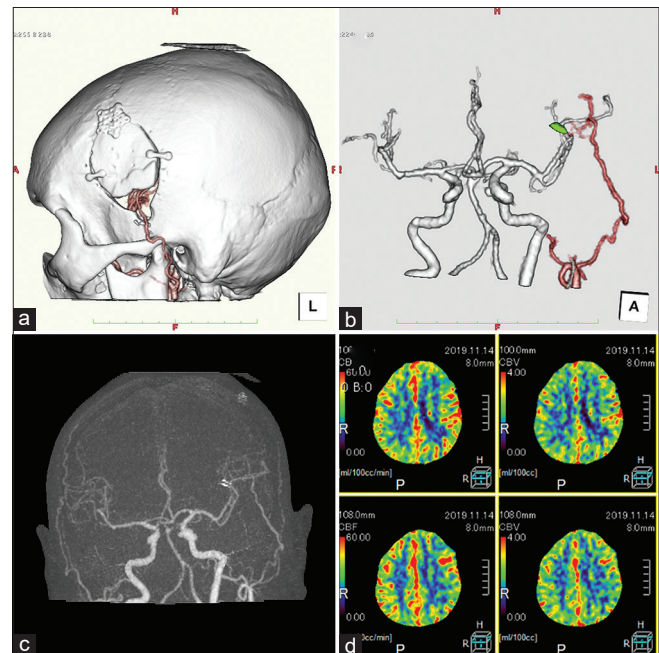


**Figure 1:** (a and b) Angiogram shows a left intracavernous internal carotid artery aneurysm. (c and d) The aneurysm filled by two coil. (e and f) Initially migration of coils to the left MCA bifurcation. (g and h) Migration and significant occlusion of M3 branch

No postoperative bleeding was detected at postoperative computed tomography (CT) scan. During the postoperative course, the patient underwent CT angiography, magnetic resonance angiography (the patient refused any other endovascular procedure to assess bypass patency) and CT angiography perfusion sequence [Figure 2b-d]. The patient was discharged after 10 days, without neurological deficit.

### Discussion

Coil migration out of their destination occurs in 0.2%–6% of procedures.<sup>[3,5-13]</sup> Acute coil migration is a rare condition and in literature no standardized methods to manage this complication are described. Kim *et al.* described six cases who underwent surgical management for parent artery occlusion linked with inadvertent coil herniation.<sup>[14]</sup> Deshmukh *et al.* described a case of acute coils migration in the angular artery treated by arteriotomy and coil mass removal.<sup>[15]</sup> Turek *et al.* described three cases of acute migration of endovascular tools treated by surgical removal through an incision of a middle cerebral artery (MCA) branch, the anterior temporal artery.<sup>[13]</sup> Abdalkader *et al.* described three cases of delayed coils migration and one case of acute coils migration, all surgically managed with coils retrieval.<sup>[3]</sup> Motegi *et al.* described a case of delayed coil migration surgically treated with removal of the coils and clip of the aneurysm with superficial temporal artery (STA-MCA) bypass to ensure blood flow to perforators of the left M1 segment during and after coil removal.<sup>[16]</sup> Yi *et al.* described a case of stent thrombosis treated with high-flow extracranial-to-intracranial bypass.<sup>[17]</sup> Abdalkader *et al.* also identify small aneurysm, aspect ratio <1.6 and small coils as significant risk factors for coil migration.<sup>[3]</sup> The aneurysm treated in this paper is small and with an AR



**Figure 2:** (a and b) computed tomography angiography three-dimensional reconstruction after bypass. (c) Magnetic resonance angiography confirming the patency of the bypass. (d) Computed tomography angiography perfusion sequence shows hypoperfused area in the frontal lobe (middle and inferior gyrus with low cerebral blood flow and high mean transit times with preserved cerebral blood volume)

of 1.13, therefore at high risk of coil migration according to Abdalkader *et al.* findings. To the best of our knowledge, this is the first case report about STA-MCA bypass to treat acute significant vessel occlusion after acute coils migration without coils removal. Considering the acute significant vessel occlusion and the clinical deterioration of the patient, we decided to perform STA-MCA bypass to restore brain

perfusion without performing CT/magnetic resonance imaging perfusion study. Surgical treatment was started immediately (within 1 h), as suggested by other authors in case of surgical removal of coils.<sup>[3,13-15]</sup> Readers may claim that the patient could recover also without performing STA-MCA bypass. No controlled study has been conducted to date. We can only speculate that a significant occlusion of M3 branch has high probability to become symptomatic. Ultraearly treatment (overall time from coil migration to successful revascularization was 2 h and a half) is more advisable for a better outcome.

## Conclusions

Acute coil migration with significant occlusion of distal branch of MCA is uncommon, but it may be devastating if not effectively managed. However, in future, a larger number of patients could develop this complication as more and more intracranial aneurysms are aggressively treated by endovascular procedure. When surgical or endovascular retrieval of acute migrated coils in MCA branch is not possible, the significant occlusion of a distal vessel can be managed performing STA-MCA bypass as rescue therapy.

## Declaration of patient consent

The authors certify that they have obtained all appropriate patient consent forms. In the form the patient(s) has/have given his/her/their consent for his/her/their images and other clinical information to be reported in the journal. The patients understand that their names and initials will not be published and due efforts will be made to conceal their identity, but anonymity cannot be guaranteed.

## Acknowledgment

The case report was done with the support from the Department of Neurosurgery, Fujita Health University, Babuntane Hospital, Nagoya, Japan.

## Financial support and sponsorship

Nil.

## Conflicts of interest

There are no conflicts of interest.

## References

- Molyneux A, Kerr R, Stratton I, Sandercock P, Clarke M, Shrimpton J, *et al.* International subarachnoid aneurysm trial (ISAT) of neurosurgical clipping versus endovascular coiling in 2143 patients with ruptured intracranial aneurysms: A randomised trial. *Lancet* 2002;360:1267-74.
- Eskey CJ, Meyers PM, Nguyen TN, Ansari SA, Jayaraman M, McDougall CG, *et al.* Indications for the performance of intracranial endovascular neurointerventional procedures: A scientific statement from the American Heart Association. *Circulation* 2018;137:e661-89.
- Abdalkader M, Pötin M, Chen M, Ortega-Gutierrez S, Samaniego E, Weill A, *et al.* Coil migration during or after endovascular coiling of cerebral aneurysms. *J Neurointerv Surg* 2019. doi: 10.1136/neurintsurg-2019-015278.
- Rennert RC, Strickland BA, Ravina K, Bakhsheshian J, Russin JJ. Assessment of hemodynamic changes and hyperperfusion risk after extracranial-to-intracranial bypass surgery using intraoperative indocyanine green-based flow analysis. *World Neurosurg* 2018;114:352-60.
- Henkes H, Fischer S, Weber W, Miloslavski E, Felber S, Brew S, *et al.* Endovascular coil occlusion of 1811 intracranial aneurysms: Early angiographic and clinical results. *Neurosurgery* 2004;54:268-80.
- Ding D, Liu KC. Management strategies for intraprocedural coil migration during endovascular treatment of intracranial aneurysms. *J Neurointerv Surg* 2014;6:428-31.
- White PM, Lewis SC, Nahser H, Sellar RJ, Goddard T, Gholkar A, *et al.* HydroCoil endovascular aneurysm occlusion and packing study (HELPS trial): Procedural safety and operator-assessed efficacy results. *AJNR Am J Neuroradiol* 2008;29:217-23.
- Guglielmi G, Viñuela F, Duckwiler G, Dion J, Lylyk P, Berenstein A, *et al.* Endovascular treatment of posterior circulation aneurysms by electrothrombosis using electrically detachable coils. *J Neurosurg* 1992;77:515-24.
- Casasco AE, Aymard A, Gobin YP, Houdart E, Rogopoulos A, George B, *et al.* Selective endovascular treatment of 71 intracranial aneurysms with platinum coils. *J Neurosurg* 1993;79:3-10.
- Phatouros CC, McConachie NS, Jaspán T. Post-procedure migration of Guglielmi detachable coils and Mechanical detachable spirals. *Neuroradiology* 1999;41:324-7.
- Leslie-Mazwi TM, Heddier M, Nordmeyer H, Stauder M, Velasco A, Mosimann PJ, *et al.* Stent retriever use for retrieval of displaced microcoils: A consecutive case series. *AJNR Am J Neuroradiol* 2013;34:1996-9.
- Viñuela F, Duckwiler G, Mawad M. Guglielmi detachable coil embolization of acute intracranial aneurysm: Perioperative anatomical and clinical outcome in 403 patients. 1997. *J Neurosurg* 2008;108:832-9.
- Turek G, Kochanowicz J, Lewszuk A, Lyson T, Zielinska-Turek J, Chwiesko J, *et al.* Early surgical removal of migrated coil/stent after failed embolization of intracranial aneurysm. *J Neurosurg* 2015;123:841-7.
- Kim YB, Lee KC, Lee JW, Huh SK, Yoon PH, Kim DI. Rescue microsurgery in coil herniation causing thromboembolic occlusion of parent artery. *Acta Neurochir (Wien)* 2009;151:1609-16.
- Deshmukh VR, Klopfenstein J, Albuquerque FC, Kim LJ, Spetzler RF. Surgical management of distal coil migration and arterial perforation after attempted coil embolization of a ruptured ophthalmic artery aneurysm: Technical case report. *Neurosurgery* 2006;58:ONS-E379.
- Motegi H, Isobe M, Isu T, Kamiyama H. A surgical case of delayed coil migration after balloon-assisted embolization of an intracranial broad-neck aneurysm: Case report. *Neurosurgery* 2010;67:516-21.
- Yi L, Zhao W, Krings T, Wang W, Chen J. High-flow extracranial-to-intracranial bypass for treatment of thrombotic parent vessel occlusion after stent-assisted aneurysm coiling as a potential rescue therapy. *World Neurosurg* 2019;127:326-9.