

## Case report

## Malignant Brenner tumor of the ovary: Review and case report

Susan M. Lang<sup>a</sup>, Anne M. Mills<sup>a,b</sup>, Leigh A. Cantrell<sup>a,c,\*</sup><sup>a</sup> University of Virginia School of Medicine, Charlottesville, VA 22903, United States<sup>b</sup> Department of Pathology, Division of Anatomic Pathology, University of Virginia School of Medicine, Charlottesville, VA 22903, United States<sup>c</sup> Department of Obstetrics and Gynecology, Division of Gynecologic Oncology, University of Virginia School of Medicine, Charlottesville, VA 22903, United States

## ARTICLE INFO

## Keywords:

Malignant Brenner tumor  
Ovarian carcinoma  
Review

## ABSTRACT

Ovarian neoplasms are a heterogeneous group of tumors with varying incidence in the general population. The most common are the surface epithelial tumors which include transitional cell tumors. Transitional cell tumors include both transitional cell carcinoma and Brenner tumor. The vast majority of Brenner tumors are benign, often incidental findings; however, malignant Brenner tumors (MBT) do occasionally occur. MBT present similarly to other ovarian neoplasms with abdominal pain and bulk symptoms. On imaging, these tumors demonstrate nonspecific findings. Microscopically, they demonstrate areas of conventional benign Brenner tumor juxtaposed with regions of frank malignancy showing marked cytologic atypia and infiltration. There is no consistent tumor marker for these tumors, but CA-125, CA 72-4 and SCC have been reported in singular instances. Tumors express several immunohistochemical markers of urothelial differentiation including uroplakin III, thrombomodulin, GATA3, p63, as well as cytokeratin 7. The primary treatment modality is surgical excision. Due to their rarity, the precise role and regimen of adjuvant chemo-radiation therapy for MBT has not been established. We herein review a case of MBT with emphasis on primary treatment and treatment of recurrent disease, including the use of adjuvant pelvic radiation, discuss the current state of the literature and standards of practice regarding this malignancy.

## 1. Introduction

Ovarian neoplasms are a heterogeneous group composed of tumors showing epithelial, germ cell, and sex cord stromal differentiation. The ovarian Brenner tumor (BT) represents a rare epithelial ovarian neoplasm and accounts for 1–2% of all ovarian neoplasms. Identified in 1907 by Fritz Brenner, BT are now subclassified into benign, borderline (proliferative) or malignant categories (Speert, 1956). Malignant BTs (MBT) are extremely rare, comprising < 5% of all BT. MBT was first reported by von Numers in 1945 (von Numers, 1945). Given the rarity of this tumor, individual case reports, small case series, or recently, retrospective population-based studies provide the only available information about how to treat these patients, and the optimal adjuvant management remains unclear (Gezginç et al., 2012; Nasioudis et al., 2016; Verma et al., 2014). Herein we describe a case of MBT and review the current literature on these tumors.

## 2. Case report

A 77-year-old G1 with a past medical history of hypertension, acquired hypothyroidism after radioiodine thyroid ablation for Grave's

disease, and hysterectomy presented for gynecologic consultation due to a pelvic mass incidentally discovered during evaluation for recurrent UTI.

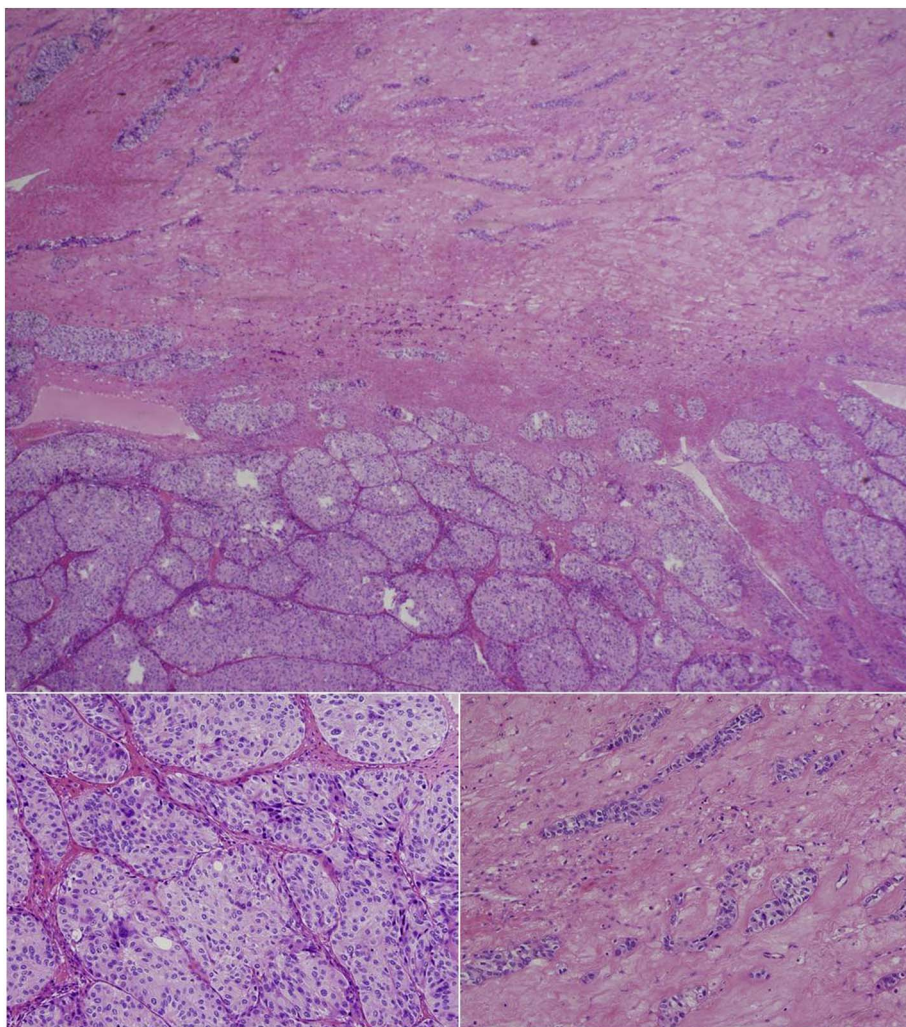
Computerized Tomography (CT) of the abdomen and pelvis showed a  $9.2 \times 9.6 \times 10.8$  cm heterogeneous mass in the right hemipelvis likely arising from the ovary. No lymphadenopathy was identified. Small solitary pulmonary nodules were seen in the bilateral lower lobes, but were not consistent with metastatic disease patterns. Tumor markers were normal (CA 125 = 14 U/mL and CEA = 2.4 ng/mL), on initial evaluation. Interval time from initial consultation to surgery was 11 days.

During surgical exploration, a > 10 cm right ovarian mass was visualized. The mass was friable, fleshy and densely adhered to the right pelvic sidewall. However, there was no evidence of other metastatic disease. Initial frozen pathology returned as sex cord stromal versus epithelial ovarian neoplasm. Bilateral pelvic and paraaortic lymph node dissection was performed for staging.

Pathologic examination revealed a biphasic proliferation of epithelial cells with areas of solid, well-formed nests immediately juxtaposed with regions of infiltrative cord-like and single cell growth (Fig. 1). Cytologically, the tumor showed only mild atypia even in the

\* Corresponding author at: PO Box 800712, Charlottesville, VA 22908, United States.

E-mail addresses: [LAC6VZ@virginia.edu](mailto:LAC6VZ@virginia.edu), [LAC6VZ@hscmail.mcc.virginia.edu](mailto:LAC6VZ@hscmail.mcc.virginia.edu) (L.A. Cantrell).



**Fig. 1.** Malignant Brenner tumor is characterized by the juxtaposition of areas of conventional Brenner tumor juxtaposed with infiltrative, frankly malignant cells. The interface between these two processes is illustrated here in the top image (Hematoxylin & eosin stain, 4 ×), which demonstrates well-demarcated nests of Brenner tumor at the bottom of the field [20 ×, bottom right image] and infiltrative cords and single cells percolating through the top portion of the field [20 ×, bottom left image].

infiltrative areas. Immunohistochemical studies showed positivity for cytokeratin 7 with focal GATA3 and p63 expression. Stains for the sex cord stromal marker inhibin, the neuroendocrine marker chromogranin, and the mesothelial marker calretinin were all negative. Based on the presence of urothelial differentiation with conventional BT morphology adjacent to frankly infiltrative malignancy, this tumor was classified as MBT and was considered low-grade on the basis of minimal cytologic atypia. The tumor was limited to the right ovary and was staged as pT2c on the basis of ascites fluid involvement and adhesions to the pelvic sidewall.

The patient desired an aggressive therapeutic strategy and was treated with carboplatin and paclitaxel every 3 week dosing for a total of 6 cycles. Disease recurrence was identified nearly 1 year later on CT with the appearance of a new right adnexal lesion measuring 2.5 × 1.9 cm and an enlarged left inguinal lymph node. Recurrence was biopsy confirmed in the lymph node. PET scan revealed multiple areas of increased uptake concerning for disease spread to the inguinal and external iliac lymph nodes and a second course of chemotherapy with carboplatin/paclitaxel was initiated. Interval CT after cycle 2 to assess efficacy showed mixed response and bevacizumab was added to the treatment regimen. Data showing increased progression free survival with Bevacizumab in epithelial ovarian tumors (GOG0218, ICON7) was extrapolated to MBT for treatment in this patient despite there being no data suggesting significant impact on overall survival (Burger et al., 2011; Oza et al., 2015). Favorable response was seen on PET after total cycle 12 and the patient continued bevacizumab for a total of 20 cycles. PET revealed local disease progression in the pelvis.

The patient elected for removal of the pelvic mass and then received adjuvant radiation of 30 Gy in 10 fractions to the tumor bed. While limited information exists on radiation therapy in this tumor type, the family of epithelial ovarian neoplasms is known to be radiosensitive, and therefore was considered next line therapy as the patient had progressed through multiple chemotherapeutic options. She has been without evidence of disease since that time (24 months). To our knowledge this is the first report of a prolonged disease-free interval after treatment with debulking and radiotherapy in the setting of recurrent MBT.

### 3. Presenting symptoms

MBT presents similarly to other ovarian cancers (abdominal distension, abdominal pain, bulk symptoms and relative vague symptomatology) (Gezginç et al., 2012; Moon et al., 2000; Nasioudis et al., 2016). Patients typically present with disease confined to the ovary or surrounding tissue with lymphatic spread being less common (Nasioudis et al., 2016). < 10% of patients with MBT present with ascites, but MBT should be considered in patients with an ovarian mass and the presence of squamous cells in the peritoneal fluid (Driss et al., 2010). One case of MBT has been reported where the presenting symptom was intracranial hypertension from dural metastasis (Baizabal-Carvalho et al., 2010). While generally not hormone secreting, estrogen secreting MBTs have been reported leading to abnormal uterine bleeding, such as menstrual irregularity or postmenopausal bleeding (Joh et al., 1995; Kühnel et al., 1987).

#### 4. Imaging

A recent retrospective analysis showed that the median tumor size for MBT was 10 cm (Nasioudis et al., 2016); however, tumor sizes vary with some sources suggesting these neoplasms are typically much smaller (< 2 cm) (Jung et al., 2002). The majority of tumors is unilateral and may have locoregional spread (Nasioudis et al., 2016).

In general, Brenner tumors have been shown on CT imaging to have nonspecific findings, most consistently reported as a mild-moderate enhancement with evidence of amorphous calcification confined to the solid component (Jung et al., 2002; Moon et al., 2000). Malignant Brenner tumors are not associated with findings consistent with hemorrhage or necrosis; however, these features, along with a thick irregular wall, thick septa and papillary projections are typical features of malignant epithelial ovarian tumors (Jung et al., 2002; Moon et al., 2000). This difference would suggest that if hemorrhage or necrosis are noted on imaging, there should be higher suspicion for a non-MBT malignant epithelial neoplasm (Moon et al., 2000).

The literature poorly differentiates the imaging characteristics between benign vs malignant BT. Solid, low intensity lesions seen on T2-weighted MRI are consistent with Brenner tumors (Jung et al., 2002; Moon et al., 2000). Higher intensity solid components can be seen on T1-weighted images (Moon et al., 2000). One case report of BT transformation described the MR imaging findings as hypointense solid tumor with dense collagenous tissue and calcification consistent with benign findings on histology and hyperintense tumor consistent with histology that was malignant (Takeuchi et al., 2008). Another report of MBT MR findings includes a multiloculated, mixed solid-cystic mass with mild enhancement (Moon et al., 2000).

*“The clinical utility of CT and MR imaging is unclear, as MBT do not have pathognomonic imaging features. Imaging more readily contributes to the assessment of tumor location, size, and burden as well as with surgical planning.”* As with other ovarian tumors, diagnosis can only be made by histologic evaluation.

#### 5. Pathogenesis

The pathogenesis of BT has not been unequivocally elucidated. Although BTs demonstrate transitional-type differentiation as is seen in bladder and ureters, most investigators favor that these tumors do not originate in the urothelial tract. Initial reports suggested origin directly from ovarian surface epithelium; however, more recent evidence indicates these tumors derive from sites of transitional cell metaplasia within the adnexa (Ali et al., 2012; Seidman et al., 2004), also known as Walthard cell nests, within normal ovaries and fallopian tubes (Seidman and Khedmati, 2008). Interestingly, Walthard cell nests are more likely to be present in women with BT or other ovarian neoplasm than in controls (Seidman and Khedmati, 2008).

#### 6. Histologic characteristics

The histologic diagnosis of MBT is principally made by using the criteria established by Hull et al. and requires the concomitant presence of both the malignant and benign/borderline BT with clear stromal invasion by the malignant epithelial components (Hull and Campbell, 1973). Furthermore, associated tumor types (most commonly mucinous cystadenoma) must either be absent or geographically distinct from the MBT (Hull and Campbell, 1973). The transitional-type differentiation necessary for the diagnosis of BT/MBT is characterized by the presence of nuclei with distinct nuclear grooves (so-called “coffee-bean” shapes) and can be aided with immunohistochemical demonstration of urothelial marker expression (such as GATA3, uroplakin III, thrombomodulin, and p63) (Cuatrecasas et al., 2009; Liao et al., 2007; Roma and Masand, 2015; Seidman and Khedmati, 2008).

#### 7. Differentiating TCC and MBT

The primary tumor on the differential diagnosis of MBT is TCC. Despite their shared transitional cell phenotype, there is considerable evidence that these two tumors represent distinct pathologic and clinical entities. On imaging and gross examination, TCC lacks the calcifications typically seen in MBT (Austin and Norris, 1987). MBT have been shown to present more often in stage I without extraovarian spread and be less aggressive than primary TCC of the ovary, irrespective of tumor stage (Austin and Norris, 1987). One study found that primary ovarian TCC represented the more aggressive tumor type when compared to MBT as 69% of TCC presented with late stage disease compared to 19% of MBT (Austin and Norris, 1987).

Microscopically, TCC fails to demonstrate a benign Brenner tumor component characterized by well-differentiated transitional cell nests and instead shows frankly malignant features throughout. The tumors also show differing immunophenotypes, with TCC showing immunohistochemical overlap with high-grade serous carcinoma through the diffuse expression of WT1, ER, and p53 (Cuatrecasas et al., 2009). In contrast, BT/MBT are typically negative (or, in the case of p53, only focally positive) for these markers (Ali et al., 2012). p16 expression also differs between TCC and MBT, with TCC more often showing diffuse overexpression and MBT showing loss of heterozygosity and silencing (Cuatrecasas et al., 2009). Brenner tumors have increased EGFR, Ras and Cyclin D1 expression with increasing degree of malignancy, while TCC do not overexpress these proteins (Cuatrecasas et al., 2009). p63 may have some utility in the distinction of MBT and TCC as some studies report this marker has high sensitivity for BT/MBT but is most often negative in TCC, although p63 expression in metastatic TCC has been reported (Kalebi and Hale, 2008; Liao et al., 2007).

Brenner tumors, both benign and malignant, have not been shown to possess the TERT promoter mutation associated with approximately 70% of urothelial carcinoma (Khani et al., 2016). While these data add further credence to the supposition BT/MT have a distinct pathogenesis from TCC, it is correlative at best (Khani et al., 2016). While no study to date has specifically analyzed TERT promoter mutation in ovarian TCC, the data favor these mutations in urinary bladder and upper urinary tract TCC (Kinde et al., 2013; Rachakonda et al., 2013; Wang et al., 2014). Direct comparison is necessary and represents a possible avenue of further exploration if sequencing for TERT mutations is to have true diagnostic utility in the future.

#### 8. Tumor markers

Reliable tumor markers for MBT have not been identified. Yamamoto et al. have published two case reports of MBT, one with elevated CA72-4 and CA125 and the other with elevated CA72-4 and squamous cell carcinoma (SCC) antigen which suggested these may be tumor markers of interest (Yamamoto et al., 1999). CA125 is elevated in some patients with MBT, with reports ranging from 30 to 70%, but was not correlative to stage or tumor burden (Han et al., 2015; Nasioudis et al., 2016). Despite the low sensitivity (50–62%) and moderate specificity (94–98.5%) of CA125, it remains the most widely used serologic marker in patients with epithelial ovarian cancer traditionally used to monitor for recurrence after treatment (Sölétormos et al., 2016). Given that MBT is a member of this neoplastic family, it remains sensible to check pre-operative CA125 in these patients and to use it as a marker of recurrence if an elevated CA125 returns to normal after treatment.

#### 9. Treatment

Surgery is accepted as the standard of care for all epithelial ovarian tumors. Nasioudis et al. have recently reported on a retrospective population based analysis of MBT showing that nearly 98% of patients with MBT have primary surgical resection (Nasioudis et al., 2016).



**Table 1**

Summary table of MBT features and comparison to the presented case. This table summarizes the findings of the review in comparison to the patient presented. The case is consistent with general characteristics in most sectors. Differences exist in molecular markers present (i.e., galectin 3). Briefly differences in treatment are outlined. UTI – urinary tract infection; BT – Brenner tumor; CA125 – cancer antigen 125; CA72-4 – cancer antigen 72-4; SCC – squamous cell cancer antigen; CT – computed tomography; MRI – magnetic resonance imaging; LND – lymph node dissection; R1 – recurrence 1; R2 – recurrence 2; PAX2 – paired box gene; PAX8 – paired box gene; WTI – Wilms tumor protein 1; ER – estrogen receptor; TERT – human telomerase reverse transcriptase; GATA 3 – GATA binding protein 3 to DNA sequence [A/T]GATA[A/G]; CTX – chemotherapy; XRT – radiation therapy.

Tumor Sx	Molecular markers	Histologic findings	Tumor markers	Imaging findings	Treatment
<b>MBT characteristics</b> Nonspecific symptoms (abdominal pain and distention) Bulk symptoms Abnormal Uterine bleeding	Positive for: uropalakin III, thrombomodulin, cytokeratin 7, p63, GATA-3 Negative for: calretinin, PAX2, PAX8, WTI, ER, p16, p53, TERT mutations	Papillary with fibrovascular core Covered by epithelium Marked nuclear atypia A benign BT component is present	Possible CA125, CA72-4 and SCC	Size – 10 cm avg CT – mild-moderate enhancement with calcification in the solid component T1 MRI – multiloculated, mixed solid-cystic mass with mild enhancement	Surgical excision of mass ± LND Adjuvant chemotherapy (taxane + platinum based CTX)
Case study patient Recurrent UTI from obstruction	Positive for: cytokeratin 7, galectin 3 Negative for: inhibin, chromogranin, cytokeratin 20, CD138, calretinin, p63, GATA-3	Confluent growth pattern Solid with areas of nesting and trabeculae formation Uniform nuclei Focal moderate nuclear pleomorphism Normal nuclear-to-cytoplasmic ratio Focal area of benign BT present	Normal CA125 Normal CEA	Size - 9 × 10 cm pelvic mass CT – mild enhancement of a heterogeneous mass	Initial - Staging surgery + Carboplatin/paclitaxel R1 - Carboplatin/paclitaxel + Bevacizumab R2 – Surgery + XRT

Another recent study evaluated the specificity and sensitivity of frozen section diagnosis for ovarian neoplasms. This work highlighted that the overall accuracy of diagnosis by frozen section is > 99% as determined by a group of senior gynecologic pathologists by comparing accuracy of frozen section (intraoperative) diagnosis to the diagnosis on final paraffin embedded samples (Hashmi et al., 2016).

Pelvic and para-aortic lymph node dissection are classical procedures undertaken for malignant ovarian neoplasm to achieve accurate staging. However, while approximately 50% of patients with surgical tumor excision had concomitant lymph node dissection, only 5% of these patients had evidence of lymphatic spread and lymph node dissection did not confer any disease-specific survival benefit to these patients (Nasioudis et al., 2016). The necessity of complete lymph node dissection in combination with the completion surgery (total abdominal hysterectomy, bilateral salpingoophorectomy, omentectomy) in this patient population has therefore not been established, but is currently recommended for accurate staging as indicated by the International Federation of Gynecology and Obstetrics (FIGO) (Heintz et al., 2006).

The role of adjuvant therapy in the treatment of MBT is poorly defined as these rare ovarian tumors are infrequently encountered in clinical practice. The effect of platinum-based chemotherapy plus paclitaxel as a post-surgical chemotherapy has showed some conferred survival advantage (Han et al., 2015). Of note, none of the patients with recurrence after chemotherapy had stage I disease (Han et al., 2015). Case reports of other regimens have been published with variable outcomes. One case report demonstrated an 8-month disease-free interval after treatment with Adriamycin, Cyclophosphamide and radiotherapy, but had much more limited success with hexamethylmelamine, cyclophosphamide, methotrexate and 5-fluorouracil (Hexa-CAF) on recurrence (Haid et al., 1983).

The current standard chemotherapy regimen for patients with epithelial ovarian neoplasms is carboplatin plus paclitaxel (Ozols et al., 2003). Evaluation of patients with epithelial ovarian cancer who receive adjuvant treatment with platinum-based chemotherapy shows they have improved overall survival in those with early stage (I/IIa) epithelial ovarian cancer (Winter-Roach et al., 2012). Additionally, a benefit of 6 cycles compared to 3 was not demonstrated in a randomized Phase 3 trial of non-serous epithelial ovarian cancers; however, the study was underpowered to detect a difference (Chan et al., 2009). While there are not, nor will there be, large clinical trials assessing efficacy of chemotherapy in patients with MBT, the data from other epithelial ovarian tumors is extrapolated and carboplatin/paclitaxel is an acceptable choice. It would be reasonable to assess chemoresponsiveness after 3 cycles of therapy with these agents in light of the data that suggest there is no advantage to a 6-cycle regimen.

Radiation therapy as primary treatment of MBT has not been studied to our knowledge; however, radiation therapy (RT) for treatment of epithelial ovarian cancers has fallen out of favor given the relative responsiveness of these tumors to chemotherapeutic regimens and the unfavorable side effect profile of whole abdominal radiation therapy (WART). In fact, a recent SEER study reported on 2.4% of patients with MBT received RT (Nasioudis et al., 2016). The most recent NCCN guidelines on epithelial ovarian cancers do not include RT as a primary treatment recommendation and instead reference palliative RT for local symptom control (Morgan et al., 2016). Recent evidence has shown, however, that advancement in RT technology is contributing to successful local control of gynecologic malignancy and is not associated with high rates of radiation toxicity. Chundury et al. showed a 2-year local control rate of 82% in women who received intensity modulated radiation therapy (IMRT, median dose - 50.4 Gy) after epithelial ovarian tumor recurrence without a high toxicity rate (acute GI toxicity rate – 6.1%) (Chundury et al., 2016). Additionally, when evaluating the effect of external beam radiation (EBRT) coupled with stereotactic body radiation (SBRT) in the non-MBT epithelial ovarian cancer subset of gynecologic cancers studied, mean time to recurrence after RT ( $\bar{x}$  = 50 Gy) was 54 mo and no grade 3 or 4 toxicities were reported

(Hasan et al., 2016). A study of involved field radiation therapy (IFRT) on local control of recurrent epithelial ovarian tumors of various stages demonstrated a 5 year in-field disease control rate of 71% (Brown et al., 2013). Given that contemporary RT allows for directed therapy to tumor beds and relative sparing of vital organs, use of this treatment modality should be reconsidered for recurrent epithelial ovarian tumors, such as in the presented case of recurrent MBT. Targeted RT of recurrent tumors would take advantage of the radiosensitive nature of epithelial ovarian tumors while concurrently reducing chemotherapy and potential chemotoxicity.

Over half of the cases of MBT are stage I at diagnosis (Han et al., 2015; Nasioudis et al., 2016). Recently, the 5-year disease specific survival of MBT confined to the ovary was quoted at 94.5% while those patients with extra-ovarian disease had survival rate of 51.3% (Nasioudis et al., 2016). Similar to other tumors, poorly differentiated tumors portend a worse prognosis than those which are well-differentiated (Roth and Czernobilsky, 1985).

A previous analysis of rare ovarian tumors, including BT of unspecified benignity, established that the generalized recurrence rate of these tumors was approximately 28% (Bilici et al., 2013). Another study showed disease recurrence in MBT with a mean time to recurrence at 11 months (Han et al., 2015). There is evidence of increased progression free survival among women with epithelial ovarian cancer who receive adjuvant chemotherapy (Winter-Roach et al., 2012). It is noteworthy, however, that data on recurrence of MBT is limited due to rarity.

## 10. Conclusions

Herein we describe a case of recurrent MBT successfully treated with cytoreductive-chemoradiation therapy, and the literature on MBT was reviewed. There are some similarities between the presented case and the literature (Table 1). Consistent with the literature, remission was achieved initially with carboplatin/paclitaxel after surgical resection. Our patient's response supports that this regimen should be considered as a first line adjuvant chemotherapy in patients with advanced disease given the robust response of the tumor to this treatment. As in other platinum sensitive epithelial cancers, repeat treatment with carboplatin/paclitaxel was attempted. It was not as effective as the primary treatment, and the patient did demonstrate favorable tumor response with combination therapy with Bevacizumab; however, she later progressed while receiving Bevacizumab maintenance therapy. Of note, in this patient, secondary excision and radiation treatment have thus far been successful in prevention of a third recurrence. This case represents a complete response to adjuvant RT after progression through chemotherapy. While no concrete evidence exists for radiation therapy in MBT, its success in other epithelial ovarian cancers and in the presented case of MBT suggest it is a useful option for refractory neoplasms. As this represents a singular case of successful treatment, generalizations about treatment protocols cannot be suggested.

## Conflict of interest statement

The authors declare they have no conflict of interest.

## References

Ali, R., Seidman, J., Luk, M., Kalloger, S., Gilks, C., 2012. Transitional cell carcinoma of the ovary is related to high-grade serous carcinoma and is distinct from malignant Brenner tumor. *Int. J. Gynecol. Pathol.* 31, 499.

Austin, R.M., Norris, H.J., 1987. Malignant Brenner tumor and transitional cell carcinoma of the ovary: a comparison. *Int. J. Gynecol. Pathol.* 6, 29–39.

Baizabal-Carvalho, J., Barragán-Campos, H., Alonso-Juárez, M., Gamboa-Domínguez, A., Gutiérrez-Manjarréz, F., Caro-Sánchez, C., García-Ramos, G., 2010. Dural metastases as a presentation of a Brenner tumor. *J. Clin. Neurosci.* 17, 524–526.

Bilici, A., Inanc, M., Ulas, A., Akman, T., Seker, M., Babacan, N., Inal, A., Bal, O., Koral, L., Sevinc, A., Tufan, G., Elkiran, E., Ustaalioglu, B., Yavuzsen, T., Alkis, N., Ozkan, M., Gumus, M., 2013. Clinical and pathologic features of patients with rare ovarian

tumors: multi-center review of 167 patients by the Anatolian Society of Medical Oncology. *Asian Pac. J. Cancer* 14, 6493–6499.

Brown, A.P., Jhingran, A., Klopp, A.H., Schmeler, K.M., Ramirez, P.T., Eifel, P.J., 2013. Involved-field radiation therapy for locoregionally recurrent ovarian cancer. *Gynecol. Oncol.* 130 (2), 300–305 (Aug).

Burger, R.A., Brady, M.F., Bookman, M.A., Fleming, G.F., Monk, B.J., Huang, H., Mannel, R.S., Homesley, H.D., Fowler, J., Greer, B.E., Boente, M., Birrer, M.J., Liang, S.X., Gynecologic Oncology Group, 2011. Incorporation of bevacizumab in the primary treatment of ovarian cancer. *N. Engl. J. Med.* 365 (26), 2473–2483 (Dec 29).

Chan, J.K., Tian, C., Fleming, G.F., Monk, B.J., Herzog, T.J., Kapp, D.S., Bell, J., 2009. The potential benefit of 6 vs. 3 cycles of chemotherapy in subsets of women with early-stage high-risk epithelial ovarian cancer: an exploratory analysis of a Gynecologic Oncology Group study. *Gynecol. Oncol.* 116, 301–306.

Chundury, A., Apicelli, A., DeWees, T., Powell, M., Mutch, D., Thaker, P., Robinson, C., Grigsby, P.W., Schwarz, J.K., 2016. Intensity modulated radiation therapy for recurrent ovarian cancer refractory to chemotherapy. *Gynecol. Oncol.* 141 (1), 134–139 (Apr).

Cuatrecasas, M., Catusus, L., Palacios, J., Prat, J., 2009. Transitional cell tumors of the ovary: a comparative clinicopathologic, immunohistochemical, and molecular genetic analysis of Brenner tumors and transitional cell carcinomas. *Am. J. Surg. Pathol.* 33, 556–567.

Driss, M., Mrad, K., Dhouib, R., Doghri, R., Abbes, I., Romdhane, K., 2010. Ascitic fluid cytology in malignant Brenner tumor: a case report. *Acta Cytol.* 54, 598–600.

Gezginç, K., Karataylı, R., Yazici, F., Acar, A., Çelik, Ç., Çapar, M., Tavli, L., 2012. Malignant Brenner tumor of the ovary: analysis of 13 cases. *Int. J. Clin. Oncol.* 17, 324–329.

Haid, M., Victor, T., Weldon-Linne, M., Danforth, D., 1983. Malignant brenner tumor of the ovary: electron microscopic study of a case responsive to radiation and chemotherapy. *Cancer* 51, 498–508.

Han, J.H., Kim, D.Y., Lee, S.W., Park, J.Y., Kim, J.H., Kim, Y.M., Kim, Y.T., Nam, J.H., 2015. Intensive systemic chemotherapy is effective against recurrent malignant Brenner tumor of the ovary: an analysis of 10 cases within a single center. *Taiwan J. Obstet. Gynecol.* 54, 178–182.

Hasan, S., Ricco, A., Jenkins, K., Lanciano, R., Hanlon, A., Lamond, J., Yang, J., Feng, J., Good, M., Noumoff, J., Brady, L., 2016. Survival and control prognosticators of recurrent gynecological malignancies of the pelvis and para-aortic region treated with stereotactic body radiation therapy. *Front. Oncol.* 22 (6), 249 (Nov).

Hashmi, A., Naz, S., Edhi, M., Faridi, N., Hussain, S., Mumtaz, S., Khan, M., 2016. Accuracy of intraoperative frozen section for the evaluation of ovarian neoplasms: an institutional experience. *World J. Surg. Oncol.* 14, 1–5.

Heintz, A.P., Odicino, F., Maisonneuve, P., Quinn, M.A., Benedet, J.L., Creasman, W.T., Ngan, H.Y., Pecorelli, S., Beller, U., 2006. Carcinoma of the ovary. FIGO 26th annual report on the results of treatment in gynecological cancer. *Int. J. Gynaecol. Obstet.* 95 (Suppl 1), S161–S192 (Nov).

Hull, M., Campbell, G., 1973. The malignant Brenner tumor. *Obstet. Gynecol.* 42, 527–534.

Joh, K., Aizawa, S., Ohkawa, K., Dohzono, H., Ohgoshi, E., 1995. Case report of a malignant Brenner tumor with hyperestrogenism. *Pathol. Int.* 45, 75–84.

Jung, S., Lee, J., Rha, S., Byun, J., Jung, J., Hahn, S., 2002. CT and MR imaging of ovarian tumors with emphasis on differential diagnosis. *Radiographics* 22, 1305–1325.

Kalebi, A., Hale, M., 2008. p63 expression in ovarian tumours: immunopositivity in metastatic transitional cell carcinoma of the ovary. *Histopathology* 53, 228.

Khani, F., Diolombi, M.L., Khattar, P., Huang, W., Fallon, J.T., Epstein, J.I., Zhong, M., 2016. Benign and malignant Brenner tumors show an absence of TERT promoter mutations that are commonly present in urothelial carcinoma. *Am. J. Surg. Pathol.* 40, 1291–1295.

Kinde, I., Munari, E., Faraj, S.F., Hruban, R.H., Schoenberg, M., Bivalacqua, T., Allaf, M., Springer, S., Wang, Y., Diaz, L.A., Kinzler, K.W., Vogelstein, B., Papadopoulos, N., Netto, G.J., 2013. TERT promoter mutations occur early in urothelial neoplasia and are biomarkers of early disease and disease recurrence in urine. *Cancer Res.* 73, 7162–7167.

Kühnel, R., Rao, B., Stolk, J., Kessel, H. van, Seldenrijk, C., Willig, A., 1987. Estrogen synthesizing rare malignant brenner tumor of the ovary with the presence of progesterone and androgen receptors in the absence of estrogen receptors. *Gynecol. Oncol.* 26, 263–269.

Liao, X., Xue, W., Shen, D., Ngan, H., Siu, M., Cheung, A., 2007. p63 expression in ovarian tumours: a marker for Brenner tumours but not transitional cell carcinomas. *Histopathology* 51, 477–483.

Moon, W.J., Koh, K., Kim, S.K., Kim, Y.S., Rhim, H.C., Cho, O.K., Chang, K., Byun, J.Y., Cho, K.S., Kim, S.H., 2000. Brenner tumor of the ovary: CT and MR findings. *J. Comput. Assist. Tomogr.* 24, 72–76.

Morgan Jr, R.J., Armstrong, D.K., Alvarez, R.D., Bakkum-Gamez, J.N., Behbakht, K., Chen, L.M., Copeland, L., Crispens, M.A., DeRosa, M., Dorigo, O., Gershenson, D.M., Gray, H.J., Hakam, A., Havrilesky, L.J., Johnston, C., Lele, S., Martin, L., Matulonis, U.A., O'Malley, D.M., Penson, R.T., Percac-Lima, S., Pineda, M., Plaxe, S.C., Powell, M.A., Ratner, E., Remmenga, S.W., Rose, P.G., Sabbatini, P., Santoso, J.T., Werner, T.L., Burns, J., Hughes, M., 2016. Ovarian cancer, Version 1.2016, NCCN clinical practice guidelines in oncology. *J. Natl. Compr. Canc. Netw.* 14 (9), 1134–1163 (Sep).

Nasioudis, D., Sisti, G., Holcomb, K., Kanninen, T., Witkin, S.S., 2016. Malignant Brenner tumors of the ovary; a population-based analysis. *Gynecol. Oncol.* 142, 44–49.

von Numers, C., 1945. A contribution to the case knowledge and histology of the Brenner tumor: do malignant forms of the Brenner tumor also occur? *Acta Obstet. Gynecol. Scand.* 25, 114–127.

Oza, A.M., Cook, A.D., Pfisterer, J., Embleton, A., Ledermann, J.A., Pujade-Lauraine, E., Kristensen, G., Carey, M.S., Beale, P., Cervantes, A., Park-Simon, T.W., Rustin, G.,

- Joly, F., Mirza, M.R., Plante, M., Quinn, M., Poveda, A., Jayson, G.C., Stark, D., Swart, A.M., Farrelly, L., Kaplan, R., Parmar, M.K., Perren, T.J., ICON7 trial investigators, 2015. Standard chemotherapy with or without bevacizumab for women with newly diagnosed ovarian cancer (ICON7): overall survival results of a phase 3 randomised trial. *Lancet Oncol.* 16 (8), 928–936 (Aug).
- Ozols, R.F., Bundy, B.N., Greer, B.E., Fowler, J.M., Clarke-Pearson, D., Burger, R.A., Mannel, R.S., DeGeest, K., Hartenbach, E.M., Baergen, R., 2003. Phase III trial of carboplatin and paclitaxel compared with cisplatin and paclitaxel in patients with optimally resected stage III ovarian cancer: a Gynecologic Oncology Group study. *J. Clin. Oncol.* 21, 3194–3200.
- Rachakonda, P.S., Hosen, I., Verdier, P.J. de, Fallah, M., Heidenreich, B., Ryk, C., Wiklund, N.P., Steineck, G., Schadendorf, D., Hemminki, K., Kumar, R., 2013. TERT promoter mutations in bladder cancer affect patient survival and disease recurrence through modification by a common polymorphism. *Proc. Natl. Acad. Sci.* 110, 17426–17431.
- Roma, A.A., Masand, R.P., 2015. Different staining patterns of ovarian Brenner tumor and the associated mucinous tumor. *Ann. Diagn. Pathol.* 19, 29–32.
- Roth, L., Czernobilsky, B., 1985. Ovarian brenner tumors. II. Malignant. *Cancer* 56, 592–601.
- Seidman, J.D., Khedmati, F., 2008. Exploring the histogenesis of ovarian mucinous and transitional cell (Brenner) neoplasms and their relationship with Walthard cell nests: a study of 120 tumors. *Arch. Pathol. Lab. Med.* 132, 1753–1760.
- Seidman, J.D., Horkayne-Szakaly, I., Haiba, M., Boice, C.R., Kurman, R.J., Ronnett, B.M., 2004. The histologic type and stage distribution of ovarian carcinomas of surface epithelial origin. *Int. J. Gynecol. Pathol.* 23, 41–44.
- Sölétormos, G., Duffy, M., Hassan, S., Verheijen, R., Tholander, B., Bast, R., Gaarenstroom, K., Sturgeon, C., Bonfrer, J., Petersen, P., Troonen, H., CarloTorre, G., Kulpa, J., Tuxen, M., Molina, R., 2016. Clinical use of cancer biomarkers in epithelial ovarian cancer: updated guidelines from the European Group on Tumor Markers. *Int. J. Gynecol. Cancer* 26, 43.
- Speert, H., 1956. Obstetrical-gynecological eponyms: Fritz Brenner and Brenner tumors of the ovary. *Cancer* 9, 217–221.
- Takeuchi, M., Matsuzaki, K., Sano, N., Furumoto, H., Nishitani, H., 2008. Malignant Brenner tumor with transition from benign to malignant components: computed tomographic and magnetic resonance imaging findings with pathological correlation. *J. Comput. Assist. Tomogr.* 32, 553–554.
- Verma, A., Chander, B., Verma, S., Soni, A., 2014. Malignant Brenner tumor of ovary. *J. Obstet. Gynecol. India* 64, 148–149.
- Wang, K., Liu, T., Ge, N., Liu, L., Yuan, X., Liu, J., Kong, F., Wang, C., Ren, H., Yan, K., Hu, S., Xu, Z., Björkholm, M., Fan, Y., Zhao, S., Liu, C., Xu, D., 2014. TERT promoter mutations are associated with distant metastases in upper tract urothelial carcinomas and serve as urinary biomarkers detected by a sensitive castPCR. *Oncotarget* 5, 12428–12439.
- Winter-Roach, B.A., Kitchener, H.C., Lawrie, T.A., 2012. Adjuvant (post-surgery) chemotherapy for early stage epithelial ovarian cancer. *Cochrane Libr* (CD004706, PMID: 19588360).
- Yamamoto, R., Fujita, M., Kuwabara, M., Sogame, M., Ebina, Y., Sakuragi, N., Kato, H., Fujimoto, S., 1999. Malignant Brenner tumors of the ovary and tumor markers: case reports. *Jpn. J. Clin. Oncol.* 29, 308–313.