

DISTAL RADIAL FRACTURES IN PATIENTS OVER 60 YEARS OLD: ORTHOGONAL PLATES VERSUS VOLAR PLATE

Edgard Novaes de França Bisneto¹, Emygdio José Leomil de Paula¹, Marcelo Rosa de Resende¹, Rames Mattar Júnior², Arnaldo Valdir Zumioti³

ABSTRACT

Objective: To compare the results from surgical treatment between volar plates with angular stability and orthogonal plates in unstable distal radius fractures, in patients aged over 60 years. **Methods:** The patients were divided into two groups that were treated with volar plates or orthogonal plates. Clinical and radiographic results were analyzed prospectively. **Results:** The study groups presented similar clinical and radio-

graphic results six months after the operation. However, three months after the surgery, the volar plate group had superior results. **Conclusion:** Both group presented good functional results. Surgical treatment enabled early rehabilitation. The orthogonal plate technique required a longer learning curve, presented more complications and worse initial results.

Keywords – Distal Radius Fractures; Volar Plates; Orthogonal Plates; Fractures in the Elderly

INTRODUCTION

Despite changes in life expectancy and quality of life among patients over the age of 60 years, fractures of the distal extremity of the radius in this population are still often neglected⁽¹⁾.

The world population has clearly been aging, with increasing average life expectancy, including in Brazil, especially in large urban centers (source: IBGE). In parallel to this, it has been observed that elderly people's quality of life has also improved over recent years, and many individuals over the age of 60 years are regularly practicing physical exercise. Therefore, among the cri-

teria adopted for therapeutic indications for these fractures, chronological age has been losing importance in relation to analysis on patients' general state and their expectations regarding functional recovery⁽¹⁾.

Despite good results from the use of external fixators, their use for specific fixation of fragments (particularly intra-articular fragments) has been questioned in comparison with the use of angular stability plates, since the latter provide an earlier functional return^(2,3).

The use of volar plates with angular stability has been advocated through the argument that they have the great advantage of providing an earlier return to activities of daily living. These plates are capable of maintaining the

1 – PhD. Attending Physician, Institute of Orthopedics and Traumatology, School of Medicine, University of São Paulo.

2 – Associate Professor, School of Medicine, University of São Paulo.

3 – Titular Professor, Department of Orthopedics and Traumatology, School of Medicine, University of São Paulo.

Work performed at LIM 41, Medical Investigation Laboratory for the Musculoskeletal System, Department of Orthopedics and Traumatology.

Correspondence: Rua Tucuna 10, apto. 41, Vila Pompéia, 05021-010 São Paulo, SP. E-mail: novaesf@terra.com.br

Work received for publication: March 17, 2010; accepted for publication: July 12, 2010.

We declare that there is no conflict of interest in this paper

reduction, even in osteoporotic bones⁽⁴⁻⁶⁾.

The use of dorsal plates has been correlated with tendon complications. Complications with extensor tendons are so frequent that authors have recommended routine removal of these plates after the fracture has consolidated⁽⁷⁾.

Biomechanical analysis on the two fixation methods has shown that their resistance is equivalent. There is a slight advantage for specific fixation of fragments using orthogonal plates⁽⁸⁾.

This prospective study had the aim of analyzing the functional and radiographic results among patients over the age of 60 years with fractures of the distal third of the radius who underwent two different surgical techniques.

MATERIAL AND METHOD

This study included 19 patients of ages ranging from 60 to 87 years, of whom 17 were female and two were male. They presented intra-articular fractures of the distal extremity of the radius of types B and C in the AO-ASIF classification. The patients were divided randomly by means of a draw (by tossing a coin) into two groups:

Group A: treated with a volar plate using a volar approach, by means of the route described by Henry, with placement of an LCP 3.5 mm plate (Synthes Ind. e Com. Ltda.) (Figures 1 and 2).

Group B: treated with two plates of 2.4 mm (Synthes Ind. e Com. Ltda.) that were arranged orthogonally by means of two surgical routes (one lateral and the other, dorsal), thereby fixing specific fragments (Figures 3 and 4).

Each patient was evaluated during the immediate postoperative period and three and six months after the surgery. The evaluation consisted of radiographic analysis, goniometry and a grip strength test (Jamar[®]).

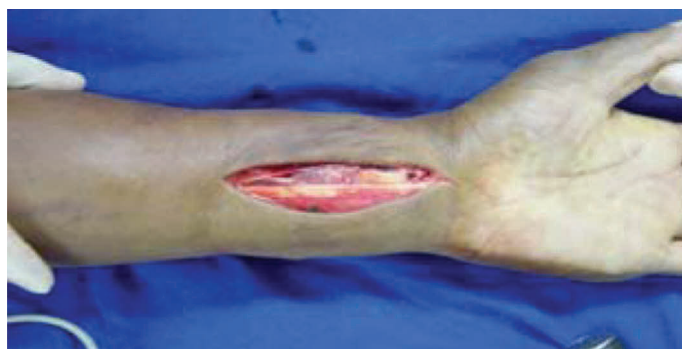

Figure 1 – Volar incision of Henry type for placement of volar plate.

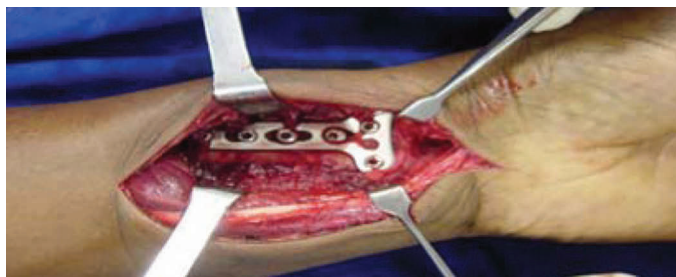

Figure 2 – Volar plate (Synthes 3.5 mm) in place.

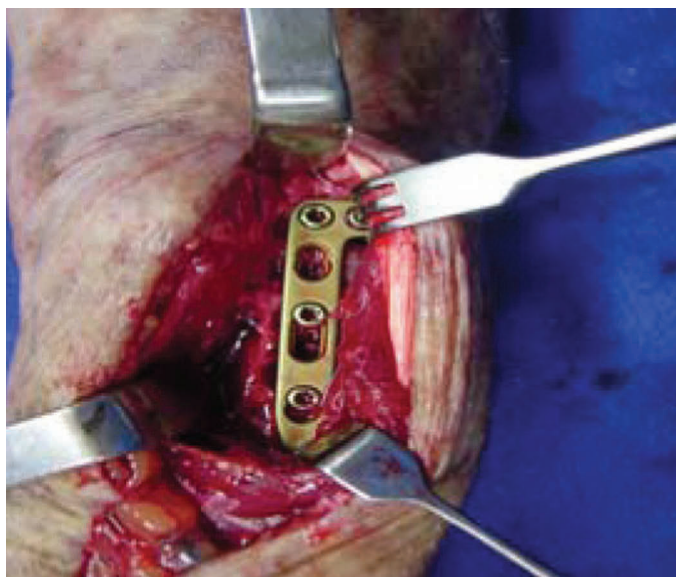


Figure 3 – Plate (Synthes 2.7 mm) placed between the fourth and fifth extensor compartments.

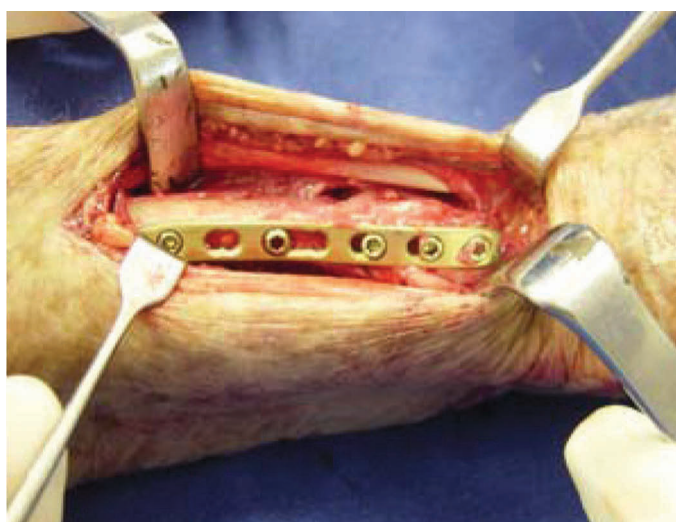


Figure 4 – Plate (Synthes 2.7 mm) placed under the first compartment.

Rehabilitation was started on the seventh to tenth day after the operation, when the plaster cast was exchanged for an orthosis of thermoplastic material. Active movement of the fingers was encouraged during the imme-

diate postoperative period. From the fourth week after the operation, the patients started to perform exercises against resistance, and the orthoses were removed after the sixth week (Figure 5).

The statistical analyses were performed using repeated-measurement models with random between-individual factors relating to the four measurements on each patient, and a fixed factor between individuals relating to the treatment with volar or orthogonal plates. The dependence between the measurements made on the same patients was incorporated with unstructured matrices of covariance, with the exception of pronation measurements, for which a compound symmetry structure was used. Descriptive levels (p) less than or equal to 5% were taken to be significant differences.

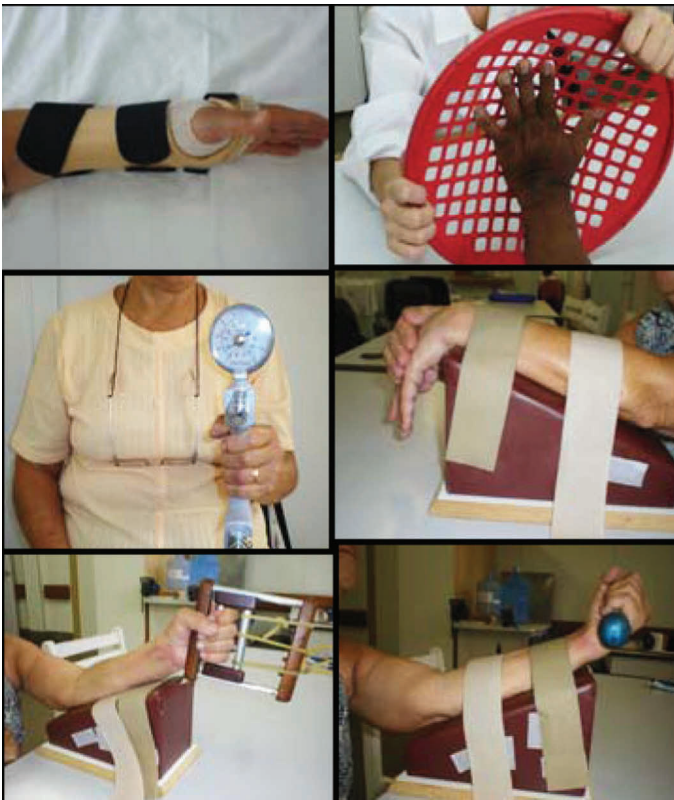

Figure 5 – Rehabilitation exercises started on the tenth day after the operation.

RESULTS

The mean ages in the groups were similar: 73.16 years in group A, which received volar plates, and 74.25 years in group B, which received orthogonal plates.

Since one of the assessment parameters was the comparison with the non-operated wrist, we compared dominance between the groups, which was also similar.

In group A, 58% ($n = 7$) of the patients suffered a fracture of the radius in the dominant arm, while in group B, the dominant arm also prevailed: 62% ($n = 5$) of the patients.

Table 1 shows the data obtained from goniometry and strength assessments among the patients in group A.

Table 1 – Functional assessment in group A.

	Volar plates			
	Contralateral side (11)	1 month (12)	3 months (11)	6 months (8)
Flexion	64.18	37.66	49.63	54.12
Extension	57.7	38.33	51.09	50.62
DU	30.36	20.3	27.9	27.62
DR	19.09	12.75	20.09	20
PRON	77.27	73.33	76.81	79.37
SUP	87.27	74.58	84.54	83.12
Strength kgF (Jamar)	21.02	6.11	10.7	13.7

Table 2 shows the data obtained from goniometry and strength assessments among the patients in group B.

Table 2 – Functional assessment of group B.

/degrees	Orthogonal plates			
	Contralateral side (8)	1 month (8)	3 months (7)	6 months (5)
Flexion	67.5	25.62	36.85	57
Extension	58.62	32.12	48.71	55
DU	28.62	14.75	21.57	26.6
DR	17	7.5	12.5	16.4
PRON	80.62	75	78.57	80
SUP	86.87	67.5	80.71	81
Strength kgF (Jamar)	16.17	4.33	7.5	12

Tables 3 and 4 show the relative evolution of the means of the data obtained from goniometry and from grip strength measurements, in comparison with the means from the non-operated side.

There were three cases of serious complications: two torn tendons (ELP in one patient and ECD in another) and one case of sympathetic reflex dystrophy. All these patients were in group B (orthogonal plates). In the cases of the first two patients, the dorsal plates were removed and the appropriate treatment was provided for

Table 3 – Comparative functional assessment between the operated and contralateral sides in group B.

	Orthogonal plates		
	Percentage evolution compared with the non-operated side		
/degrees	1 month	3 months	6 months
Flexion	38%	55%	84%*
Extension	55%	83%	94%*
DU	52%	75%	93%
DR	44%	74%	96%
PRON	93%	97%	99%
SUP	78%	93%	93%*
Strength kgF (Jamar)	27%	46%	74%*

Table 4 – Comparative functional assessment between the operated and contralateral sides in group A.

	Volar plates		
	Percentage evolution compared with the non-operated side		
/degrees	1 month	3 months	6 months
Flexion	59%	77%	84%*
Extension	66%	89%	88%*
DU	67%	92%	91%
DR	67%	105%	105%
PRON	95%	99%	103%
SUP	85%	97%	95%
Strength kgF (Jamar)	29%	51%	65%*

the tendon lesion. In the third case, the patient recovered through clinical treatment. In addition, a fourth patient, also with orthogonal plates, underwent plate removal because of the presence of a screw inside the joint. There were no cases of infection.

During the study, we observed that some patients presented what we called “accommodation” of the fracture, especially in cases in which the initial displacement of the fracture was dorsal. This “accommodation” was noted through the consequent loss of the parameters relating to the initial reduction: volar tilt, ulnar tilt and ulnar variance. These data were not subjected to statistical analysis because of the difficulties in standardizing the radiographs and because of the small number of patients, and were thus considered to be observational data.

Tables 5 and 6 show the mean values obtained in the radiographic evaluations on the 12 cases of this study, divided between groups A and B. Negative values correspond to inversion of the parameters that were taken to be normal.

Table 5 – Assessment of the cases in which there were changes in radiographic parameters in group A.

	Volar plates		
	Mean of the values found in seven cases		
	Immediate postoperative period	3 months	Mean loss
Radial angle	22°	15°	7°
Ulnar variance	2 mm	1 mm	1 mm
Volar tilt	3°	0°	3°

Table 6 – Assessment of the cases in which there were changes in radiographic parameters in group B.

	Orthogonal plates		
	Mean of the values found in five cases		
	Immediate postoperative period	3 months	Mean loss
Radial angle	21°	12°	9°
Ulnar variance	1 mm	+ 1 mm	2 mm
Volar tilt	- 3°	- 7.5°	4.5°

In the same way, we observed that the mean values obtained at the end of the study were statistically significant. The exception to this was in the values obtained for pronation, which did not show statistical significance in any of the evaluations (Table 7).

Table 7 – Functional comparison between the groups over the evolution.

	Comparative analysis of the evolution between the groups					
	1-month assessment		3-month assessment		6-month assessment	
/degrees	Volar plate	Orthogonal plate	Volar plate	Orthogonal plate	Volar plate	Orthogonal plate
Flexion	59%	38%	77%	55%	84%	84%*
Extension	66%	55%	89%	83%	88%	94%*
DU	67%	52%	92%	75%	91%	93%*
DR	67%	44%	105%	74%	105%	96%*
PRON	95%	93%	99%	97%	103%	99%
SUP	85%	78%	97%	93%	95%	93%
Strength kgF (Jamar)	29%	27%	51%	46%	65%	74%*

In relation to the losses observed over the radiographic evolution, the mean values obtained not only were similar but also did not influence the functional results (Table 8).

Table 8 – Comparative assessment of changes to radiographic parameters.

	Mean loss	
	Volar plate	Orthogonal plate
Radial angle	7°	9°
Ulnar variance	1 mm	2 mm
Volar tilt	3°	4.5°

DISCUSSION

Leibovic and Geissler(9) demonstrated that surgical treatment with adequate fixation of the distal third of the radius, in association with early rehabilitation, especially for intra-articular fractures, presented a better result than did conservative treatment.

Ring⁽¹⁾ observed that elderly people often evolved to pain and restriction of the range of motion (ROM), with loss of quality of life, as well as complications that might occur because of poor positioning of the radius, including radiocarpal arthrosis and arthrosis of the distal radial-ulnar joint.

Harness *et al*⁽¹⁰⁾ observed that even fractures that are relatively simple in young adults change their characteristics when they occur in older patients. They present greater comminution, which makes them potentially more serious, with a greater chance of evolving to arthrosis. This observation corroborates the findings of Hegeman *et al*⁽¹¹⁾, according to which 51% of the patients with fractures of the distal extremity of the radius have osteoporosis and 81% have osteopenia. Hollevoet *et al*⁽¹²⁾ classified diminution of bone mineral density as a factor showing the severity of fractures of distal third of the radius.

Fractures of the distal third of the radius in elderly people are mostly treated conservatively, despite their severity, because elderly individuals are considered to be patients with low functional demands, if chronological age alone is analyzed⁽¹⁾. Clearly, it may be erroneous to generalize in this manner, given that all patients have their own characteristics. However, one of these characteristics tends to be common to all of them: diminished bone mineral density^(11,12). This makes surgical treatment for elderly patients a challenge for surgeons, since the bone quality does not allow ideal fixation of the bone fragments⁽¹³⁾.

Conservative treatment for unstable fractures generally evolves with loss of the reduction. McQueen *et al*⁽¹⁴⁾ analyzed 120 fractures of the distal extremity of

the radius that were initially treated conservatively and evolved to loss of the reduction. These authors compared replacement of plaster after closed reduction, bone grafting with fixation by means of Kirschner wires and an external fixator maintained for three and six weeks. In none of these methods was there any improvement of the carpal alignment, especially in cases of unstable fractures.

Hegeman *et al*⁽¹⁵⁾ also used an external fixator as a means of treatment for patients over the age of 55 years who had fractures of the distal extremity of the radius. In their study, out of the 16 patients operated, 11 lost the reduction with the external fixator and five evolved with sympathetic reflex dystrophy.

Conventional plates and screws have not been shown to be appropriate for demineralized bone, since their action is based on friction between plate and bone, and screw fixation based on the bone cortex is poor in osteopenic bone.

Several studies on the use of dorsal plates have been published^(13,16-19). Reduction that is maintained with dorsal plates has been described in several studies; however, in all the large series in which this method has been used, there have been complications relating to the extensor tendons. Herron *et al*⁽¹⁸⁾ reported that out of 30 patients operated, 11 had to have the plate removed because of complications with the extensor tendons, and one patient suffered what in effect was a total rupture⁽¹⁶⁾. Beharrie *et al*⁽¹⁶⁾ described a case of extensor tendinitis precisely in association with the dorsal plate.

The use of volar plates of fixed angle, i.e. with angular stability for treating fractures of the distal radius, was popularized particularly by Orbay and Fernandez^(6,20,21). The technique of orthogonal plates, with plates of 2.4 mm, also with angular stability, was described and popularized by Peine *et al*⁽¹⁷⁾.

In the present study, we observed female predominance, since 89.5% (17 out of 19) of the patients were women. This corroborates the data in the literature, which attribute a role to fractures of the distal extremity of the radius, of providing an important sign of osteoporosis, which occurs faster and more intensely among women^(11,12).

None of the patients demonstrated any problem of elbow stiffness or shoulder pain, which are common in conservative treatments for these fractures among elderly people. There were no cases of infection. There were no important clinical interurrences.

Comparing the groups, there were 12 wrists in group A versus eight in group B. This difference was due to the randomization method chosen. Nonetheless, we observed that there was similarity in the mean ages and dominance of the limb affected: 73.1 years versus 74.2 years and 58% versus 62% of the limbs affected were the dominant limb.

From analysis on the goniometric evolution and grip strength of the patients in the two groups, we could clearly see that the evaluation was better for volar plates, reaching statistical significance, in the first and third months of evolution.

The use of orthogonal plates for specific fixation of fragments caused complications that were considered to present high morbidity, such as tearing of extensor tendons in two patients, presence of a screw inside the joint in one patient and sympathetic reflex dystrophy in one patient. On the other hand, we did not observe any complications of this nature with the use of volar plates.

The great majority of the patients said that they were satisfied with the treatment, although it has to be

borne in mind that their assessment was made before the abovementioned more serious complications appeared. We observed that, independent of the group studied, the patients already presented good function one month after the operation.

The present authors agree that the surgical technique of volar plates is simpler, with less aggression to soft tissues and shorter duration of surgery.

CONCLUSION

We believe that surgical treatment for elderly patients is the best option with regard to unstable fractures of the distal third of the radius. Between the groups studied, we consider that volar plates were safer because they presented fewer complications. Functionally, the two techniques were shown to be similar after six months, but the first and third months after the operation showed statistically significant values favoring the group with volar plates. The technique for orthogonal plates requires a longer learning curve and should, in our view, be used only for selected cases.

REFERENCES

1. Ring D. Treatment of the neglected distal radius fracture. *Clin Orthop Relat Res.* 2005;(431):85-92.
2. Ochman S, Frerichmann U, Armsen N, Raschke MJ, Meffert RH. [Is use of the fixateur externe no longer indicated for the treatment of unstable radial fracture in the elderly?]. *Unfallchirurg.* 2006;109(12):1050-7.
3. Benson LS, Minihane KP, Stern LD, Eller E, Seshadri R. The outcome of intra-articular distal radius fractures treated with fragment-specific fixation. *J Hand Surg Am.* 2006;31(8):1333-9.
4. Voigt C, Lill H. [What advantages does volar plate fixation have over K-wire fixation for distal radius extension fractures in the elderly?]. *Unfallchirurg.* 2006;109(10):845-6.
5. Gruber G, Bernhardt GA, Köhler G, Gruber K. Surgical treatment of distal radius fractures with an angle fixed bar palmar plating system: a single center study of 102 patients over a 2-year period. *Arch Orthop Trauma Surg.* 2006;126(10):680-5.
6. Orbay J, Badia A, Khoury RK, Gonzalez E, Indriago I. Volar fixed-angle fixation of distal radius fractures: the DVR plate. *Tech Hand Up Extrem Surg.* 2004;8(3):142-8.
7. Keller M, Steiger R. [Open reduction and internal fixation of distal radius extension fractures in women over 60 years of age with the dorsal radius plate (pi-plate)]. *Handchir Mikrochir Plast Chir.* 2006;38(2):82-9.
8. Taylor KF, Parks BG, Segalman KA. Biomechanical stability of a fixed-angle volar plate versus fragment-specific fixation system: cyclic testing in a C2-type distal radius cadaver fracture model. *J Hand Surg Am.* 2006;31(3):373-81.
9. Leibovic SJ, Geissler WB. Treatment of complex intra-articular distal radius fractures. *Orthop Clin North Am.* 1994;25(4):685-706.
10. Harness N, Ring D, Jupiter JB. Volar Barton's fractures with concomitant dorsal fracture in older patients. *J Hand Surg Am.* 2004;29(3):439-45.
11. Hegeman JH, Oskam J, van der Palen J, Ten Duis HJ, Vierhout PA. The distal radial fracture in elderly women and the bone mineral density of the lumbar spine and hip. *J Hand Surg Br.* 2004;29(5):473-6.
12. Hollevoet N, Verdonk R. Outcome of distal radius fractures in relation to bone mineral density. *Acta Orthop Belg.* 2003;69(6):510-4.
13. Duncan SF, Weiland AJ. Minimally invasive reduction and osteosynthesis of articular fractures of the distal radius. *Injury.* 2001;32(Suppl 1):SA14-24.
14. McQueen MM, Hajducka C, Court-Brown CM. Redispaced unstable fractures of the distal radius: a prospective randomised comparison of four methods of treatment. *J Bone Joint Surg Br.* 1996;78(3):404-9.
15. Hegeman JH, Oskam J, Vierhout PA, Ten Duis HJ. External fixation for unstable intra-articular distal radial fractures in women older than 55 years. Acceptable functional end results in the majority of the patients despite significant secondary displacement. *Injury.* 2005;36(2):339-44.
16. Beharrie AW, Beredjikian PK, Bozentka DJ. Functional outcomes after open reduction and internal fixation for treatment of displaced distal radius fractures in patients over 60 years of age. *J Orthop Trauma.* 2004;18(10):680-6.
17. Peine R, Rikli DA, Hoffmann R, Duda G, Regazzoni P. Comparison of three different plating techniques for the dorsum of the distal radius: a biomechanical study. *J Hand Surg Am.* 2000;25(1):29-33.
18. Herron M, Faraj A, Craigen MA. Dorsal plating for displaced intra-articular fractures of the distal radius. *Injury.* 2003;34(7):497-502.
19. Ring D. Intra-articular fractures of the distal-radius. *J Am Soc Surg Hand.* 2002;2:60-77.
20. Orbay JL, Fernandez DL. Volar fixation for dorsally displaced fractures of the distal radius: a preliminary report. *J Hand Surg Am.* 2002;27(2):205-15.
21. Orbay JL, Fernandez DL. Volar fixed-angle plate fixation for unstable distal radius fractures in the elderly patient. *J Hand Surg Am.* 2004;29(1):96-102.
22. Osada D, Viegas SF, Shah MA, Morris RP, Patterson RM. Comparison of different distal radius dorsal and volar fracture fixation plates: a biomechanical study. *J Hand Surg Am.* 2003;28(1):94-104.