



Case Report

# Cerebrospinal fluid leakage due to nasoseptal flap partial necrosis: A pitfall for skull base reconstruction of endoscopic endonasal surgery

Hiroki Yamada<sup>1</sup>, Masahiro Toda<sup>1</sup>, Mariko Fukumura<sup>1</sup>, Ryotaro Imai<sup>1</sup>, Hiroyuki Ozawa<sup>2</sup>, Kaoru Ogawa<sup>2</sup>, Kazunari Yoshida<sup>1</sup>

Departments of <sup>1</sup>Neurosurgery, <sup>2</sup>Otorhinolaryngology, Head and Neck Surgery, Keio University School of Medicine, 35 Shinanomachi, Shinjuku-Ku, Tokyo, Japan.

E-mail: \*Hiroki Yamada - yhiroki08@gmail.com; Masahiro Toda - todam@keio.jp; Mariko Fukumura - mariko-fukumura@live.jp; Ryotaro Imai - rimai5794@gmail.com; Hiroyuki Ozawa - ozakky123@gmail.com; Kaoru Ogawa - ogawak@a5.keio.jp; Kazunari Yoshida - kazrmky@keio.jp



\*Corresponding author:

Hiroki Yamada,  
Department of Neurosurgery,  
Keio University School of  
Medicine, 35 Shinanomachi,  
Shinjuku-Ku, Tokyo, Japan.  
yhiroki08@gmail.com

Received : 22 March 2020  
Accepted : 06 May 2020  
Published : 23 May 2020

DOI  
10.25259/SNI\_117\_2020

Quick Response Code:



## ABSTRACT

**Background:** Vascularized nasoseptal flaps allow for the reconstruction of large dural defects and have remarkably reduced the incidence of postoperative complications during endoscopic endonasal skull base surgery. Nevertheless, some complications related to nasoseptal flap have been reported. Flap necrosis is a rare, but serious issue is associated with meningitis and cerebrospinal fluid (CSF) leak.

**Case Description:** We performed endoscopic endonasal removal of the tuberculum sella meningioma in a 39-year-old woman with a history of Turner syndrome using abdominal fat, fascia, and a vascularized nasoseptal flap for dural and skull base defect reconstruction. After surgery, she developed CSF leak, and reoperation revealed partial necrosis of the septal flap that caused leakage. At this time, with a concern that removal of the necrotic part may lead to the insufficient size of the flap, we filled the gap tightly with fat pieces. However, the CSF leak recurred, and thus, we performed debridement of the necrotic region and reformed the multilayered reconstruction, following which she no longer experienced CSF leakage.

**Conclusion:** Our case suggested that partial rather than total flap necrosis could occur, possibly due to variances of vascular anatomy, leading to focal ischemia. Debridement of the necrotic region may be an important solution for recurrent cerebrospinal leakage secondary to partial necrosis of a nasoseptal flap.

**Keywords:** Cerebrospinal fluid leak, Meningioma, Nasoseptal flap, Necrosis, Skull base

## INTRODUCTION

Advances in endoscopic endonasal surgery (EES) have expanded its indications to skull base lesions and have enabled safer and less invasive surgery. Cerebrospinal fluid (CSF) leakage is a complication that requires the most attention when performing skull base lesions by EES, and it primarily occurred at a considerably high rate. As a pivotal solution, vascularized nasoseptal flap (NSF), which was introduced by Hadad *et al.*,<sup>[3]</sup> has dramatically reduced the incidence of postoperative complications.<sup>[4]</sup> It is a robust vascularized flap with a wide variety of uses, allowing the reconstruction of large dural defects as part of a multilayer reconstruction.

Recently, complications related to NSF have been studied. In a systematic review, Lavine *et al.* reported that the complications of NSF were mucocele formation, septal perforation, nasal

This is an open-access article distributed under the terms of the Creative Commons Attribution-Non Commercial-Share Alike 4.0 License, which allows others to remix, tweak, and build upon the work non-commercially, as long as the author is credited and the new creations are licensed under the identical terms.

©2020 Published by Scientific Scholar on behalf of Surgical Neurology International

dorsum collapse, effects on quality of life, olfactory loss, and flap necrosis.<sup>[5]</sup> Among them, NSF necrosis is rare, but serious complication is associated with meningitis and CSF leak,<sup>[2]</sup> although there are few detailed descriptions in the literature.

We report a case of NSF partial necrosis caused recurrent CSF leakage and subsequent meningitis. We discuss possible causes and surgical pitfalls associated with its repair.

## CASE DESCRIPTION

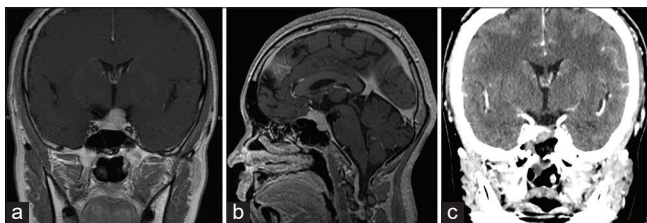
A 39-year-old woman with a clinical history of Turner syndrome (treated with estrogen and progesterone), hypercholesterolemia, and chronic thyroiditis, complained that vision in her left eye had turned whitish and hazy during desk work. Examination revealed that her visual acuity of the left eye had decreased to 20/100 vision (right eye was 20/20 vision) with a superior visual field defect of her left eye. Magnetic resonance imaging revealed a 19 mm suprasellar and sellar mass lesion with contrast enhancement [Figure 1]. The lesion pushed the optic chiasm moderately upward, particularly on the left, with extension beneath the optic canal.

We performed endoscopic endonasal removal of the tumor with a team including neurosurgeons and head-and-neck surgeons. Initially, a pedunculated full NSF was created by approaching from the right nasal cavity as our routine; with an awareness of preserving the posterior septal branch of the sphenopalatine artery, a vertical incision was initiated at the level of the sphenoid ostium and extended anteriorly until just posterior of the mucosa-skin transition. The gross total removal (Simpson Grade 2) of the tumor was achieved. For skull base defect, multilayer reconstruction was performed by inlaying the fascia collected from the abdomen, cloaking the NSF on to the dural defect, and then onlaying fat collected from the abdomen in front of it. The histopathological diagnosis of the tumor was angiomatous meningioma.

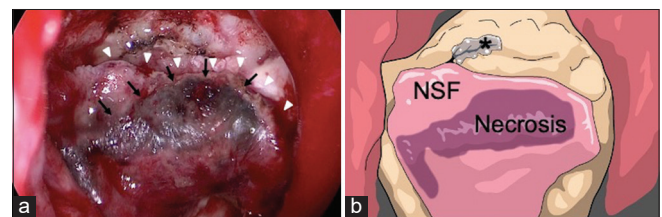
After surgery, she experienced transient deterioration of the left visual acuity; therefore, steroid pulse therapy was administered 3 times. The visual acuity slowly recovered to

preoperative level. She had steadily regained ambulation. However, on the 7<sup>th</sup> postoperative day (POD), she developed clear fluid dripping from the right nostril, which was suspected to represent CSF leakage. Conservative treatment with bed rest did not improve the symptom, so we performed EES again. During surgery, careful removal of the packing around the planum sphenoidale and sella tunica revealed that the superior half of the NSF was partially necrotic and shifted posteriorly [Figure 2]. As a result, the dural defect was exposed in front of the flap, and CSF leakage was observed thereafter. At this time, since there was a concern that the size of the flap would be insufficient for coverage of the dural defect by removing the necrotic portion, we initially filled the piece of fat collected from the abdomen to an exposed dural defect. As a result, the CSF leak resolved. The additional fat was layered thereon, and the periphery was filled. The Valsalva maneuver at the end of the procedure confirmed that there was no gross leakage.

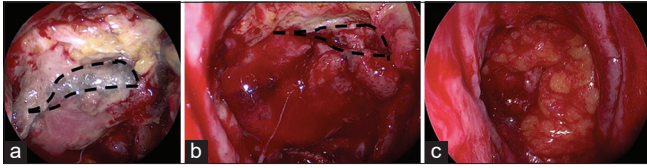
Postoperatively, she gradually regained ambulation; however, CSF leak appeared again 6 days after the reoperation. She also developed fever, headache, and increased serum inflammatory responses suggestive of meningitis. We again performed emergent EES [Figure 3]. CSF leakage was observed from the anterior edge of the dural defect in the sphenoid bone plane as before. Removal of the surrounding fat was evidence of known necrotic flap preventing engraftment with surrounding tissue. Therefore, we resected the necrotic region of the flap. The flap region maintaining blood flow was separated from the dura. The fascia newly collected from the abdomen was inlayed into the dura defect, and the fascia slightly larger than the dura defect was also onlayed. From above, we restored the defect by rotating the flap to cover the dura. We also inserted spinal drainage; CSF drainage was managed postoperatively, discharging approximately 100–140 cc per day. Intraoperative CSF tests confirmed bacterial meningitis, and we administered empiric antibiotic therapy. On POD7 from the second reoperation, observation of surgical site by nasal endoscopy demonstrated that there was no evident CSF leak nor flap necrosis. We removed the spinal drain and gradually progressed her



**Figure 1:** (a) Coronal and (b) sagittal view of preoperative gadolinium enhanced T1-weighted magnetic resonance image revealing homogeneous enhancing tumor compressing the left optic nerve. (c) Postoperative coronal contrast enhanced computed tomography showing removal of the tumor.



**Figure 2:** (a) Intraoperative view at the first reoperation showing partial necrosis (black arrows) of the nasoseptal flap (NSF) (white arrowheads) and cerebrospinal fluid (CSF) leakage from the above. (b) Schematic drawing of Figure 2a which clearly shows the NSF, flap necrosis, and CSF leak point (asterisk).



**Figure 3:** Intraoperative view at the second reoperation revealing (a) partial necrosis of the nasoseptal flap and fat pieces that were prevented from engrafting; the area within the dashed line represents the area planned for debridement; (b) after debridement of the necrotic region, the area within the dashed line represents the actual debrided region; (c) multi-reconstruction of the dural defect done with the fascia, non-necrotic flap, and fat pieces.

ambulation. The meningitis was completely cured, and she was discharged with no more CSF leakage.

## DISCUSSION

Vascularized NSF has been reliable and is the most-used method today for anterior and ventral skull base reconstruction during EES. It is reported that it has reduced the incidence of CSF leakage from 15.6% to 6.7%.<sup>[4]</sup> However, it is also associated with various complications that are only occasionally reported. Studies spotlighting anosmia and prolonged crusting are majority,<sup>[8,9]</sup> however, a few studies reported flap necrosis. Chabot *et al.* reported that the incidence of necrosis was 1.3% in all NSF cases.<sup>[2]</sup>

Various factors can be considered as risk factors for flap necrosis: patient characteristics, intracranial hypertension, flap rotation, pedicle compression, infection, and radiation therapy.<sup>[2]</sup> Although it is difficult to completely determine the causes of the flap necrosis, we suspect that it occurred for various reasons, including anatomic variance and patient background. The NSF is usually vascularized by the posterior septal artery, a branch of the sphenopalatine artery.<sup>[3]</sup> Zang *et al.* investigated anatomy to the posterior septal artery related to the NSF.<sup>[11]</sup> They observed that the septal artery had many anastomoses including the posterior ethmoid artery, anterior ethmoid artery, septal branch of the dorsal nasal artery, greater palatine artery, septal branch of the superior labial artery, and branches of the posterior septal artery itself. They also found that in some specimens, the anastomotic channels were very large, forming an arterial loop or that the postanastomotic artery was even larger than the proximal segment of the caliber. These findings suggest that a dense network of collateral pathways has formed regarding the blood supply of the nasal septum, while at the same time, in some individuals, depending on the location within the NSF, the artery other than the posterior nasal septal artery may be dominant. In our case, the necrosis existed on the apical region of the flap, which was partial and not the entire flap, appearing to be band-like and may be consistent with vasculature. It led to the discussion that blockage of

the anterior ethmoidal artery, superior labial artery, greater palatine artery, or other collateral arteries may have led to ischemia. Our findings suggest that the partial blood flow impairment of the flap might occur, and appropriate repairment could be taken to cope with this. There are other possibilities that might add to the cause of to the ischemia, administration of steroid pulse therapy and local infection.

If a flap partial necrosis caused CSF leak, it may insufficient simply to fill the gap. This is because the necrosis discourages engrafting the filling material such as fat and fascia well. In our case, at first reoperation, instead of debridement, we closed the gap with the fat onlay. This was due to concerns that debriding would reduce the size of the flap, making it impossible to cover the large dural defect at the base of the skull, and resulting in insufficient reconstruction. The gross cessation of CSF leakage and the findings of the Valsalva procedure seemed appropriate at this point. However, the fat did not firmly fix because there was no blood flow from the flap. Therefore, we believe that the pitfall in this case was the necessity of debridement of the necrotic region. In fact, past reports of septal necrosis describe aggressive debridement and redone multilayer reconstruction.<sup>[2,10]</sup> In addition, spinal drainage may have played a role in appropriate CSF control.

Turner syndrome patients have been reported to be at an increased risk for meningioma.<sup>[6,7]</sup> To date, there have been few reports that demonstrating the meningioma developed in a Turner syndrome patient.<sup>[1]</sup> Because meningioma is considered to be hormone-related tumors, female hormone replenishing preparation could contribute to this association. In this case, the patient was also taking female hormones. Although the cause is yet to be elucidated, this case is added to valuable examples of Turner syndrome with meningioma cases.

## CONCLUSION

We treated a rare case of EES complicated with recurrent CSF leakage because of NSF partial necrosis. Our case suggests that the partial, not entire, flap necrosis could occur. The cause may be an anatomical variance that led to local ischemia and steroid treatment may also have played a role. As a solution, the debridement of the necrotic region may be necessary.

## Declaration of patient consent

The authors certify that they have obtained all appropriate patient consent.

## Financial support and sponsorship

Nil.

## Conflicts of interest

There are no conflicts of interest.

## REFERENCES

1. Amelot A, Lemaistre G, Cornu P, Kalamarides M, Peyre M. Multiple meningiomas in patients with Turner syndrome. *Acta Neurochir (Wien)* 2015;157:621-3.
2. Chabot JD, Patel CR, Hughes MA, Wang EW, Snyderman CH, Gardner PA, *et al.* Nasoseptal flap necrosis: A rare complication of endoscopic endonasal surgery. *J Neurosurg* 2018;128:1463-72.
3. Hadad G, Bassagasteguy L, Carrau RL, Mataza JC, Kassam A, Snyderman CH, *et al.* A novel reconstructive technique after endoscopic expanded endonasal approaches: Vascular pedicle nasoseptal flap. *Laryngoscope* 2006;116:1882-6.
4. Harvey RJ, Parmar P, Sacks R, Zanation AM. Endoscopic skull base reconstruction of large dural defects: A systematic review of published evidence. *Laryngoscope* 2012;122:452-9.
5. Lavigne P, Faden DL, Wang EW, Snyderman CH. Complications of nasoseptal flap reconstruction: A systematic review. *J Neurol Surg B Skull Base* 2018;79:S291-9.
6. Pier DB, Nunes FP, Plotkin SR, Stemmer-Rachamimov AO, Kim JC, Shih HA, *et al.* Turner syndrome and meningioma: Support for a possible increased risk of neoplasia in Turner syndrome. *Eur J Med Genet* 2014;57:269-74.
7. Schoemaker MJ, Swerdlow AJ, Higgins CD, Wright AF, Jacobs PA. Cancer incidence in women with Turner syndrome in Great Britain: A national cohort study. *Lancet Oncol* 2008;9:239-46.
8. Soudry E, Psaltis AJ, Lee KH, Vaezafshar R, Nayak JV, Hwang PH. Complications associated with the pedicled nasoseptal flap for skull base reconstruction. *Laryngoscope* 2015;125:80-5.
9. Soyka MB, Serra C, Regli L, Meier E, Holzmann D. Long-term olfactory outcome after nasoseptal flap reconstructions in midline skull base surgery. *Am J Rhinol Allergy* 2017;31:334-7.
10. Wengier A, Ram Z, Warshavsky A, Margalit N, Fliss DM, Abergel A. Endoscopic skull base reconstruction with the nasoseptal flap: Complications and risk factors. *Eur Arch Otorhinolaryngol* 2019;276:2491-8.
11. Zang X, Wang EW, Wei H, Shi J, Snyderman CH, Gardner PA, *et al.* Anatomy of the posterior septal artery with surgical implications on the vascularized pedicled nasoseptal flap. *Head Neck* 2015;37:1470-6.

**How to cite this article:** Yamada H, Toda M, Fukumura M, Imai R, Ozawa H, Ogawa K, *et al.* Cerebrospinal fluid leakage due to nasoseptal flap partial necrosis: A pitfall for skull base reconstruction of endoscopic endonasal surgery. *Surg Neurol Int* 2020;11:121.