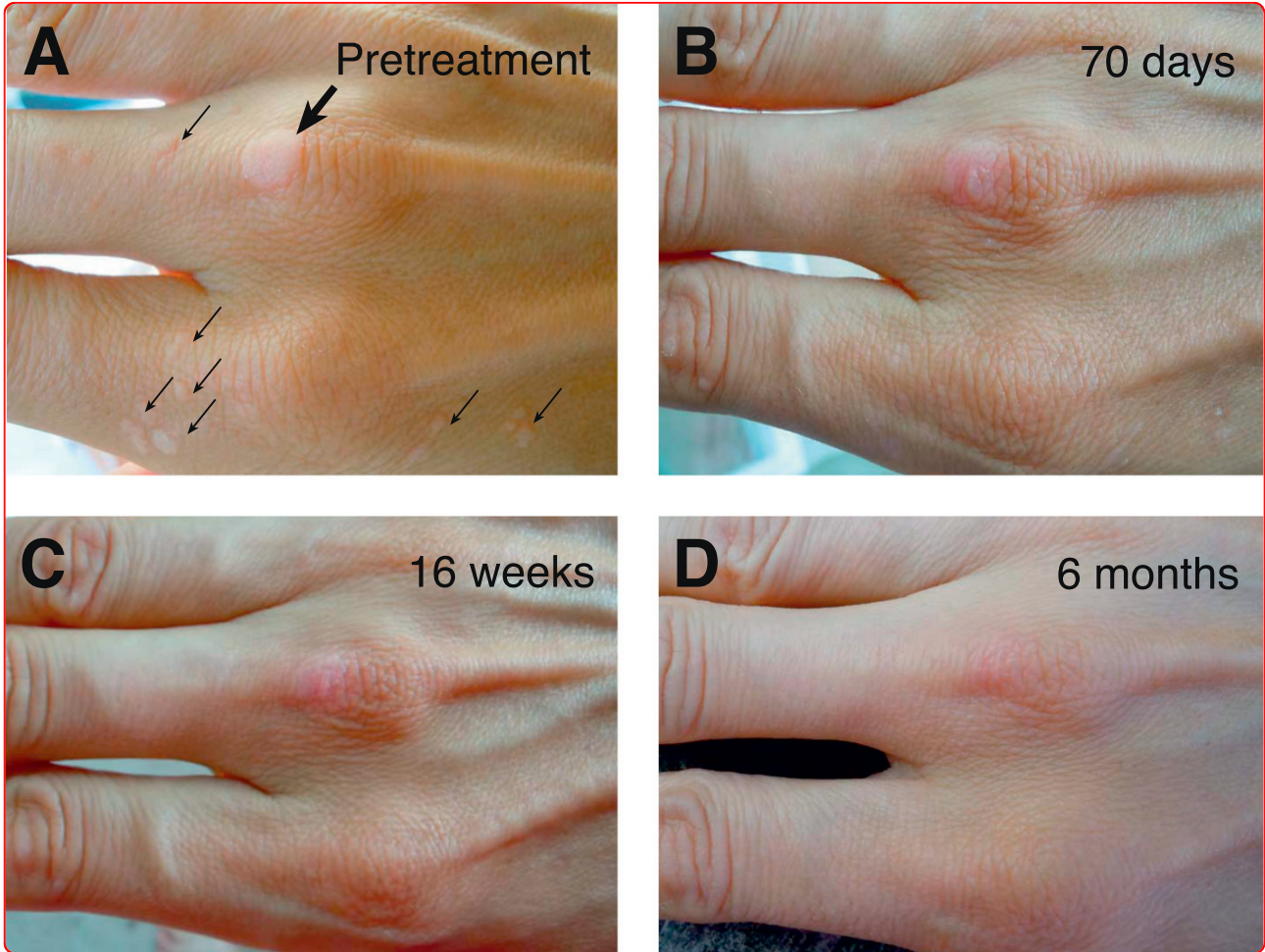

## Topical vitamin A treatment of recalcitrant common warts

Gaston and Garry

CASE REPORT

Open Access

# Topical vitamin A treatment of recalcitrant common warts

Anca Gaston<sup>1</sup> and Robert F Garry<sup>2\*</sup>

## Abstract

**Background:** Common warts (*verruca vulgaris*) are benign epithelial proliferations associated with human papillomavirus (HPV) infection. Salicylic acid and cryotherapy are the most frequent treatments for common warts, but can be painful and cause scarring, and have high failure and recrudescence rates. Topical vitamin A has been shown to be a successful treatment of common warts in prior informal studies.

**Case:** The subject is a healthy, physically-active 30 old female with a 9 year history of common warts on the back of the right hand. The warts resisted treatment with salicylic acid, apple cider vinegar and an over-the-counter blend of essential oils marketed for the treatment of warts. Daily topical application of natural vitamin A derived from fish liver oil (25,000 IU) led to replacement of all the warts with normal skin. Most of the smaller warts had been replaced by 70 days. A large wart on the middle knuckle required 6 months of vitamin A treatment to resolve completely.

**Conclusion:** Retinoids should be further investigated in controlled studies to determine their effectiveness in treating common warts and the broad range of other benign and cancerous lesions induced by HPVs.

## Background

Human papillomaviruses (HPVs) are the causative agents of a variety of benign and cancerous lesions of the skin and other epithelial surfaces. At least 189 HPV genotypes have been described [1]. Most HPV types are associated with one or a few histopathologically distinct types of lesions and may be restricted to a particular location on the body. HPV types 2, 4, 26, 29 and others are responsible for common warts (*verruca vulgaris*), which are slightly raised rough surface epithelial proliferations that occur most often on the hands, but can also grow elsewhere on the body. Other types of warts include plantar warts (*verruca plantaris*) that occur most commonly on the soles of the feet (HPV 1 and others) [2], flat warts (*verruca plana*) usually appearing on the face (HPV 3, 10, 38 and others) [3], butcher's warts of the hands and fingers (HPV 7) [4], and oral, genital/oranogenital warts (*condyloma acuminata*; HPV 6, 11, 16, 18 and many others) [5]. While common warts can affect patients' quality of life by causing adverse psychological effects or negative social perception, certain

types of HPV may induce life-threatening malignancies. HPV is associated with virtually 100% of cervical cancers, and a high portion of cancers of the penis and anus [5-7]. HPV 16 has also been strongly associated with various head and neck cancers, including head and neck squamous cell carcinoma and oropharyngeal carcinoma of the tonsils [8-10]. The incidence of HPV-induced oral cancers appears to be increasing [11].

Many different treatments have been described for HPV-induced lesions. Salicylic acid (SCA) and cryotherapy, which are intended to kill HPV-infected cells, are the most frequently employed treatments for common warts by dermatologists. Over-the-counter (OTC) versions of these treatments are also available. Numerous studies, albeit with highly variable protocols, have examined the efficacy of SCA and cryotherapy for treating HPV-induced lesions (reviewed in [12]). The efficacy of these treatments is low, and there is a high rate of recrudescence and adverse effects (such as scarring). Although well-controlled clinical trials have not been performed, retinoids are promising alternative treatments for warts [13-17]. Topical vitamin A was an effective treatment of common warts in a prior informal study [18]. Here, we present a well-

\* Correspondence: rfgarry@tulane.edu

<sup>2</sup>Department of Microbiology and Immunology, Tulane University, 1430 Tulane Avenue, New Orleans, LA 70112, USA

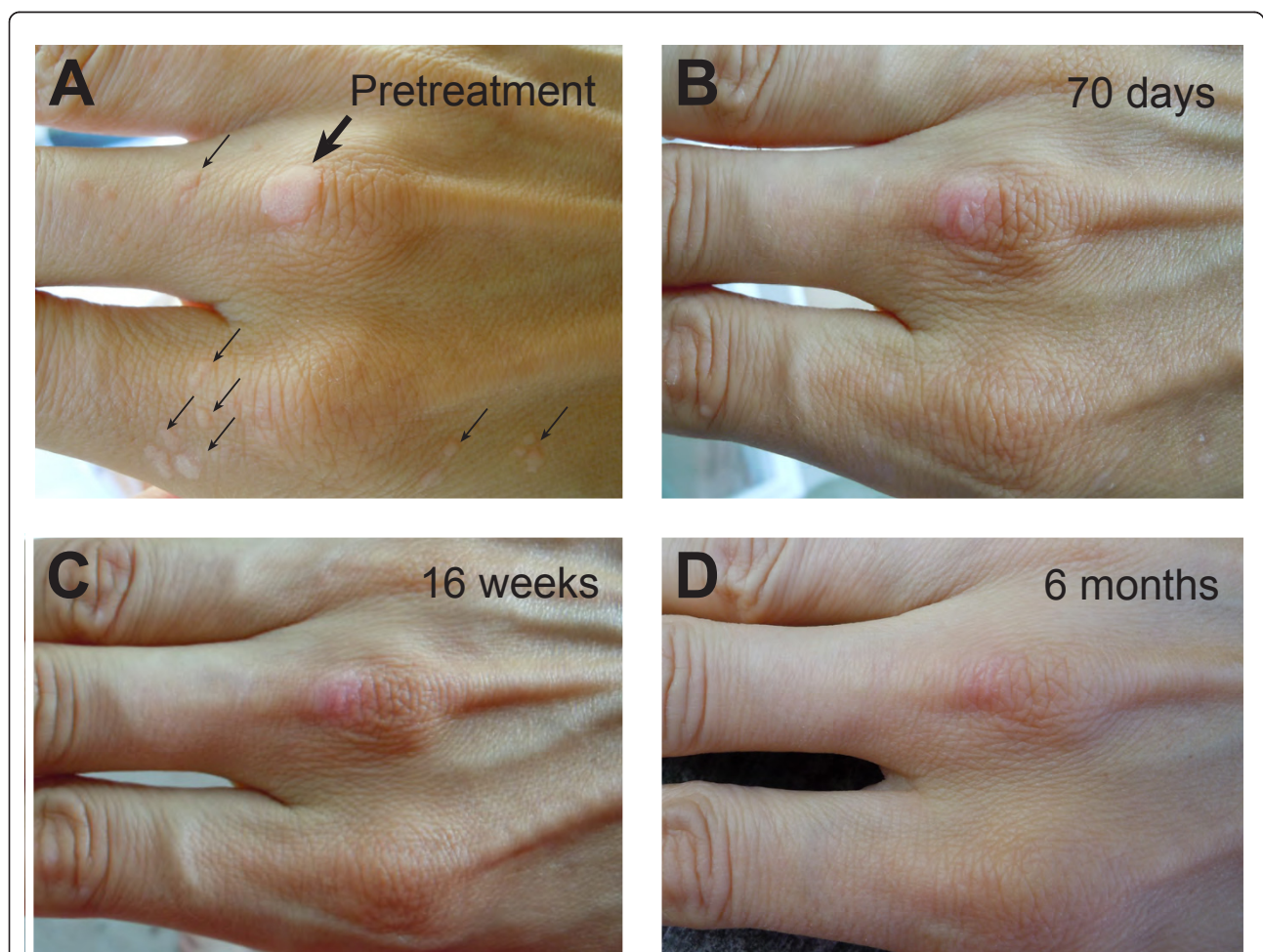
Full list of author information is available at the end of the article

documented case of topical vitamin A treatment of recalcitrant common warts.

### Case presentation

The subject is a healthy 30 year old woman of European descent with an uneventful medical history. There was a large (approximately 9 mm in diameter; large arrow Figure 1A) common wart on the middle knuckle of the right hand as well as 23 smaller warts (1 mm to 4 mm) at the base of and behind the knuckle of the index finger (small arrows, Figure 1A). The large wart was first noticed 9 years earlier. Within 1-2 years it had reached its maximum size as well as spread to multiple surrounding sites. Because of her occupation as a piano teacher, the subject reported experiencing considerable psychological distress over the visibility of the warts and the need to frequently use her hands in front of others. Over the course of the previous 2 years, several

treatments for common warts on the right hand were unsuccessful despite perfect compliance. The treatments attempted included two courses of essential oil blends which were applied to all warts three times daily as directed. The initial preparation was marketed OTC for wart treatment, guaranteed by the manufacturer to be effective within 8 weeks, and consisted of cedrus, lycea, malaleuca alternifolia, and limonium. After 3 months of perfect application resulted in no change, a second specially-formulated stronger blend was applied three times daily for an additional 2 months. This consisted of a stronger concentration of the same aforementioned essential oils plus juniper and cypress. It resulted in no change. The second unsuccessful treatment was an OTC 40% salicylic acid preparation that was applied only to the large wart for 3 months of daily application. The salicylic acid treatment resulted in very little benefit and a plateau effect after 3 weeks with no further improvement. A third



**Figure 1** Progressive clearance of *verrucae vulgaris* following daily topical application of vitamin A. Appearance of warts prior to vitamin A treatment (Panel A) and at 70 days (Panel B), 16 weeks (Panel C) and 6 months (Panel D). Large arrow indicates large wart on knuckle requiring the longest time to resolve. Small arrows indicate smaller warts cleared by 16 weeks.



unsuccessful treatment was apple cider vinegar applied to two of the smaller warts. The supradermal portion of the warts sluffed off after a few days of apple cider vinegar treatment, but promptly regrew. In addition, this treatment resulted in moderate to severe irritation of the surrounding skin.

Throughout the course of the failed attempts at treatment, the number of warts increased. All warts had returned to their original appearance prior to treatment with vitamin A. The source of vitamin A was natural fish liver oil (NOW<sup>®</sup> Foods, 25,000 IU softgels, Manufacturer SKU: 733739003409). A needle was used to puncture the softgels and the oil was applied topically to the warts every night prior to sleep. The oil was allowed to soak into the tissue before the excess oil was removed with a dry towel. Soap was not used to wash the hands until the morning. On 3-4 days of the week, the oil was applied a second time, usually around midday. The daily topical application of vitamin A led to replacement of all the warts with normal skin. Most of the smaller warts had been replaced with normal skin by 70 days (Figure 1B). The largest wart on the middle knuckle of the right hand, although replaced by mostly normal tissue after 4 months of treatment (Figure 1C), required 6 months of vitamin A treatment to completely resolve (Figure 1D). The slight discoloration of the tissue likely represents residual scar tissue from prior unsuccessful treatments. Interestingly, during the course of treatment three tiny warts on the left hand also disappeared even though vitamin A was not applied to them.

## Conclusions

The case reported here is similar to experiences in prior informal studies suggesting that topical vitamin A is an effective treatment for *verruca vulgaris*. Topical vitamin A should be further investigated as an alternative to the most frequently-utilized wart treatments, cryotherapy and SCA, which have relatively low cure rates [19-21]. In contrast to destructive or dermonecrotic treatments, topical vitamin A treatment for warts is not painful and does not lead to scarring. On the other hand, the treatment may require several months for complete resolution of the lesions, which can affect compliance. As in the current case, warts with scar tissue as a result of prior tissue destroying treatments, such as SCA, may require longer vitamin A treatment. The location and size of the wart may also affect time to resolution. Large plantar warts on the feet typically take several months to resolve with topical vitamin A. Treatments such as SCA and cryotherapy have a high rate of recrudescence that is not seen with topical vitamin A treatment. Destructive treatments that do not affect HPV replication must eliminate all virus from the deep tissue, or commonly the wart will reestablish quickly.

There are a number of plausible mechanisms by which retinoids may affect HPV-induced lesions. Warts display abnormal keratin expression [22-24]. Retinoids, such as vitamin A, regulate epithelial cell differentiation and keratin expression [25]. HPV cannot complete its replication cycle in cultured cells suggesting that differentiation of epithelia cells in tissues is important for HPV production [26]. HPV replication appears to be synchronized with epithelial cell differentiation [27,28]. Vitamin A may disrupt the interplay of HPV replication and epithelial cell differentiation, thereby allowing normal tissue to replace the warts. Previous studies have suggested that retinoids may also affect HPV transcription or replication [29,30]. Furthermore, HPV infection may alter retinoid signaling [31,32]. Immune mechanisms may also be involved in wart clearance [33]. Vitamin A treatment may increase or prolong expression of HPV T or B cell antigens allowing clearance of the warts by immune mechanisms. The observation that three small warts on the left hand of the current subject resolved simultaneously even though vitamin A was not applied directly to them, suggests the possibility that vitamin A may evoke or potentiate immune responses to warts. While it is unlikely that topical application could increase the systemic levels of vitamin A substantially (hypervitaminosis A), a modest systemic elevation of vitamin A levels by the topical treatment may have affected the small warts on the left hand.

Furthermore, warts can have psychologically devastating effects on patients' lives [34] and the emotional impact of any treatment should not be overlooked. Treatment with SCA, for example, requires carefully coating the wart with a highly noticeable white film and may not be viable for sufferers who are already self-conscious or whose warts are on their face. In contrast, vitamin A oil is colourless, easy to apply, and quickly absorbed into the tissues. In addition, it does not irritate surrounding skin or lead to drying or flaking. Because vitamin A causes the wart to slowly dissolve and disappear, it represents an inconspicuous treatment that does not attract further attention to the wart and is unlikely to cause additional psychological distress.

Because warts may "spontaneously" resolve, it is possible that clearance of the warts after treatment with vitamin A in this case was due to chance timing. However, this is unlikely given that the warts had only increased in size and number over the preceding 9 years. In addition, the case is typical of subjects in a prior informal series in which warts always began to clear within a few weeks of initiating topical vitamin A treatment [18]. Tretinoin (Retin A) and other retinoids besides vitamin A have been successfully used in limited studies for the treatment of warts [13-17]. The current case adds to the literature suggesting that retinoids should be further investigated in controlled studies to determine their effectiveness in

treating common warts and the broad range of other benign and cancerous lesions induced by HPVs.

## Consent

Informed consent was obtained from the subject for publication of this Case Report and accompanying images.

## Abbreviations

HPV: Human papillomavirus; OTC: Over-the-counter

## Acknowledgements

The authors thank Dr. Harry Prapavessis for discussions and support.

## Author details

<sup>1</sup>Faculty of Health Sciences, School of Kinesiology, The University of Western Ontario, London, ON N6A 3 K7, Canada. <sup>2</sup>Department of Microbiology and Immunology, Tulane University, 1430 Tulane Avenue, New Orleans, LA 70112, USA.

## Authors' contributions

AG performed the investigations described in this study. RFG participated in its design. AG and RFG wrote and edited the manuscript. Both authors read and approved the final manuscript.

## Competing interests

The authors declare that they have no competing interests.

Received: 29 December 2011 Accepted: 17 January 2012

Published: 17 January 2012

## References

- Bernard HU, Burk RD, Chen Z, van Doorslaer K, Hausen H, de Villiers EM: Classification of papillomaviruses (PVs) based on 189 PV types and proposal of taxonomic amendments. *Virology* 2010, **401**(1):70-79.
- Davis MD, Gostout BS, McGovern RM, Persing DH, Schut RL, Pittelkow MR: Large plantar wart caused by human papillomavirus-66 and resolution by topical cidofovir therapy. *J Am Acad Dermatol* 2000, **43**(2 Pt 2):340-343.
- Yoo H, Won SS, Choi HC, Yoon TJ, Ye SK, Park TK, Lee KH: Detection and identification of human papillomavirus types isolated from Korean patients with flat warts. *Microbiol Immunol* 2005, **49**(7):633-638.
- Oltersdorf T, Campo MS, Favre M, Dartmann K, Gissmann L: Molecular cloning and characterization of human papillomavirus type 7 DNA. *Virology* 1986, **149**(2):247-250.
- Rijkskaart DC, Berkhof J, Rozendaal L, van Kemenade FJ, Bulkman NW, Heideman DA, Kenter GG, Cuzick J, Snijders PJ, Meijer CJ: Human papillomavirus testing for the detection of high-grade cervical intraepithelial neoplasia and cancer: final results of the POBASCAM randomised controlled trial. *Lancet Oncol* 2012, **13**(1):78-88.
- Dunne EF, Friedman A, Datta SD, Markowitz LE, Workowski KA: Updates on human papillomavirus and genital warts and counseling messages from the 2010 Sexually Transmitted Diseases Treatment Guidelines. *Clin Infect Dis* 2011, **53**(Suppl 3):S143-152.
- Palefsky JM, Giuliano AR, Goldstone S, Moreira ED Jr, Aranda C, Jessen H, Hillman R, Ferris D, Coutlee F, Stoler MH, et al: HPV vaccine against anal HPV infection and anal intraepithelial neoplasia. *N Engl J Med* 2011, **365**(17):1576-1585.
- Naidu A, Wright JM: The role of the human papillomavirus in oropharyngeal cancer. *J Mich Dent Assoc* 2011, **93**(9):44-48.
- Rautava J, Kuuskoski J, Syrjanen K, Grenman R, Syrjanen S: HPV genotypes and their prognostic significance in head and neck squamous cell carcinomas. *J Clin Virol* 2012, **53**(2):116-120.
- Stokes A, Guerra E, Bible J, Halligan E, Orchard G, Odell E, Thavaraj S: Human papillomavirus detection in dysplastic and malignant oral verrucous lesions. *J Clin Pathol* 2012.
- Hocking JS, Stein A, Conway EL, Regan D, Grulich A, Law M, Brotherton JM: Head and neck cancer in Australia between 1982 and 2005 show increasing incidence of potentially HPV-associated oropharyngeal cancers. *Br J Cancer* 2011, **104**(5):886-891.
- Gibbs S, Harvey I, Sterling J, Stark R: Local treatments for cutaneous warts: systematic review. *BMJ* 2002, **325**(7362):461.
- Gelmetti C, Cerri D, Schiuma AA, Menni S: Treatment of extensive warts with etretinate: a clinical trial in 20 children. *Pediatr Dermatol* 1987, **4**(3):254-258.
- Euvrard S, Verschoore M, Touraine JL, Dureau G, Cochat P, Czernielewski J, Thivolet J: Topical retinoids for warts and keratoses in transplant recipients. *Lancet* 1992, **340**(8810):48-49.
- Al Aboosi M: Treatment of plane warts by tretinoin-induced irritant reaction. *Int J Dermatol* 1994, **33**(11):826-827.
- Tsamboas D, Georgiou S, Monastirli A, Sakkis T, Sagriotis A, Goerz G: Treatment of condylomata acuminata with oral isotretinoin. *J Urol* 1997, **158**(5):1810-1812.
- Choi YL, Lee KJ, Kim WS, Lee DY, Lee JH, Lee ES, Yang JM: Treatment of extensive and recalcitrant viral warts with acitretin. *Int J Dermatol* 2006, **45**(4):480-482.
- Garry CE, Garry JA, Garry RF: Treatment of warts. *N Engl J Med* 2004, **351**(16):1692-1693, author reply 1692-1693.
- Bruggink SC, Waagmeester SC, Gussekloo J, Assendelft WJ, Eekhof JA: Current choices in the treatment of cutaneous warts: a survey among Dutch GP. *Fam Pract* 2010, **27**(5):549-553.
- Bruggink SC, Gussekloo J, Berger MY, Zaaijer K, Assendelft WJ, de Waal MW, Bavinck JN, Koes BW, Eekhof JA: Cryotherapy with liquid nitrogen versus topical salicylic acid application for cutaneous warts in primary care: randomized controlled trial. *CMAJ* 2010, **182**(15):1624-1630.
- Cockayne S, Hewitt C, Hicks K, Jayakody S, Kang'ombe AR, Stamuli E, Turner G, Thomas K, Curran M, Denby G, et al: Cryotherapy versus salicylic acid for the treatment of plantar warts (verrucae): a randomised controlled trial. *BMJ* 2011, **342**:d3271.
- Proby CM, Churchill L, Purkis PE, Glover MT, Sexton CJ, Leigh IM: Keratin 17 expression as a marker for epithelial transformation in viral warts. *Am J Pathol* 1993, **143**(6):1667-1678.
- Barcelos AC, Sotto MN: Comparative analysis of the expression of cytokeratins (1, 10, 14, 16, 4), involucrin, filaggrin and e-cadherin in plane warts and epidermodysplasia verruciformis plane wart-type lesions. *J Cutan Pathol* 2009, **36**(6):647-654.
- Mittal KR, Demopoulos RI, Goswami S: Patterns of keratin 19 expression in normal, metaplastic, condylomatous, atrophic, dysplastic, and malignant cervical squamous epithelium. *Am J Clin Pathol* 1992, **98**(4):419-423.
- Torma H: Regulation of keratin expression by retinoids. *Dermatoendocrinol* 2011, **3**(3):136-140.
- Geimanen J, Isok-Paas H, Pipitch R, Salk K, Laos T, Orav M, Reinson T, Ustav M Jr, Ustav M, Ustav E: Development of a cellular assay system to study the genome replication of high- and low-risk mucosal and cutaneous human papillomaviruses. *J Virol* 2011, **85**(7):3315-3329.
- Mighty KK, Laimins LA: p63 is necessary for the activation of human papillomavirus late viral functions upon epithelial differentiation. *J Virol* 2011, **85**(17):8863-8869.
- Blokx WA, Smit JV, de Jong EM, Link MM, van de Kerkhof PC, Ruiter DJ: Retinoids strongly and selectively correlate with keratin 13 and not keratin 19 expression in cutaneous warts of renal transplant recipients. *Arch Dermatol* 2002, **138**(1):61-65.
- Faluhelyi Z, Rodler I, Csejtei A, Tying SK, Ember IA, Arany I: All-trans retinoic acid (ATRA) suppresses transcription of human papillomavirus type 16 (HPV16) in a dose-dependent manner. *Anticancer Res* 2004, **24**(2B):807-809.
- Myga-Nowak M, Pacholska-Bogalska J, Kwasniewski W, Kwasniewska A, Gozdzińska-Jozefiak A: Proliferation of cells and expression of RARs, RXRs and HPV viral E6 and E7 proteins in cervical cancer cell lines after treatment with ATRA. *Ann Agric Environ Med* 2011, **18**(1):145-150.
- Agarwal C, Rorke EA, Irwin JC, Eckert RL: Immortalization by human papillomavirus type 16 alters retinoid regulation of human ectocervical epithelial cell differentiation. *Cancer Res* 1991, **51**(15):3982-3989.
- Zeng M, Kumar A, Meng G, Gao Q, Dimri G, Wazer D, Band H, Band V: Human papilloma virus 16 E6 oncoprotein inhibits retinoic X receptor-mediated transactivation by targeting human ADA3 coactivator. *J Biol Chem* 2002, **277**(47):45611-45618.
- Frazer IH: Interaction of human papillomaviruses with the host immune system: a well evolved relationship. *Virology* 2009, **384**(2):410-414.

34. Micali G, Dall'Oglio F, Nasca MR, Tedeschi A: **Management of cutaneous warts: an evidence-based approach.** *Am J Clin Dermatol* 2004, **5**(5):311-317.

doi:10.1186/1743-422X-9-21

**Cite this article as:** Gaston and Garry: **Topical vitamin A treatment of recalcitrant common warts.** *Virology Journal* 2012 **9**:21.

**Submit your next manuscript to BioMed Central  
and take full advantage of:**

- Convenient online submission
- Thorough peer review
- No space constraints or color figure charges
- Immediate publication on acceptance
- Inclusion in PubMed, CAS, Scopus and Google Scholar
- Research which is freely available for redistribution

Submit your manuscript at  
[www.biomedcentral.com/submit](http://www.biomedcentral.com/submit)

