

Novel Variant c.148G>T of GJB2 Gene in a 5-Year-Old Child with KID Syndrome

Dear Editor,

We read with great interest the article “KID Syndrome: a rare genodermatosis” by Vivek Kumar Dey *et al.* published in January 2020 on Indian Dermatology Online Journal.^[1]

KID syndrome is a very rare ectodermal congenital disorder due to missense mutations in the gap junction beta-2 protein (GJB2) gene, which encodes for connexin 26 protein.^[1]

Recently, a 5-year-old child was referred to our Pediatric Dermatology Unit with several clinical manifestations involving skin, tooth, eyes, and ears.

The child showed recurrent cutaneous infections, bilateral cheilitis, and diffuse irritative dermatitis. Dermatological examination showed nail dystrophies, palmo-plantar hyperkeratosis with desquamation, and erythematous hyperkeratotic plaques on extremities and trunk. The patient showed a loss of eyebrows and eyelashes, deep periorcular furrows, brittle blond hair, and tooth abnormalities (hypodontia and conoid form) [Figures 1 and 2]. Psychomotor development was normal. The patient was also affected by profound bilateral congenital neurosensorial hearing loss, confirmed by audiometry, and, from 1 year of age, showed mild keratitis with photophobia.

Genetic analysis of genomic DNA extracted from peripheral blood leukocytes confirmed diagnosis of KID syndrome.

A mutation analysis based on Sanger sequencing of the coding exon of the GJB2 gene was performed, identifying a heterozygous variant NM_004004.6(GJB2):c.148G>T (p.Asp50Tyr). To date, the c.148G>T variant was never described before in patients with KID syndrome^[2] and is absent in the general population (gnomAD).

Familial history of genetic diseases was negative and the parents have not been tested.

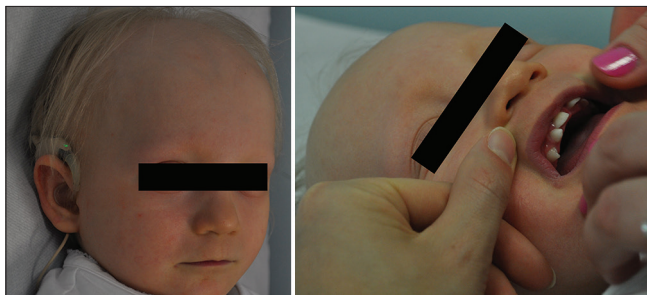


Figure 1: Clinical manifestations of the face: deep furrows around mouth and eyes, partial loss of eyebrows, total loss of eyelashes, brittle blond hair, and tooth abnormalities (hypodontia and conoid form)

From birth, the patient used topical treatments with emollients, urea, other keratolytic products or topical antibiotics.

She is regularly followed by a multispeciality team, including dermatologists, otorhinolaryngologists, ophthalmologists, and speech therapists.

The three markers of KID syndrome are keratitis, deafness, and ichthyosis. KID syndrome is clinically characterized by neurosensorial hearing loss, hyperkeratosis of the palms, soles, and skin folds, widespread alopecia of the scalp, partial loss of the eyebrows, nail dystrophy, and dentition anomalies.^[3,4] The etiopathogenesis of KID syndrome is due to missense mutation of the GJB2 gene, which encodes for the connexin 26 protein, involved in the development of intercellular channels of ectodermal-derived several epithelia.^[2,5] This mutation leads to dysregulation in the epidermal calcium homeostasis, increasing proliferation, and aberrant cell differentiation. The consequence is the abnormal lipid composition of the stratum corneum, with a lack of ceramides and barrier defect, compensated by hyperproliferation of stratum basale, determining the typical hyperkeratosis.^[5]

In patients with suspected KID syndrome, clinicians should perform, if possible, molecular genetic testing in order to achieve the correct diagnosis and to identify the specific syndrome among the heterogeneous group of ectodermal dysplasias with possible correlations genotype-phenotype.

Financial support and sponsorship

Nil.

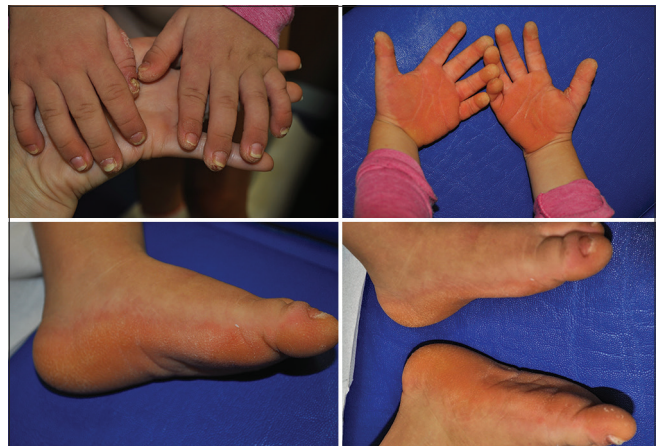

Figure 2: Nail dystrophies and palmo-plantar hyperkeratosis with desquamation

Conflicts of interest

There are no conflicts of interest.

Francesca Caroppo, Serena Szekely, Anna B. Fortina

*Pediatric Dermatology Unit – Department of Medicine DIMED,
University of Padova, Padova, Italy*

Address for correspondence:


*Dr. Francesca Caroppo,
Pediatric Dermatology Unit, Department of Medicine, DIMED,
University of Padova, Padova, Italy.
E-mail: francesca.caroppo@outlook.it*

References

1. Dey VK, Saxena A, Parikh S. KID syndrome: A rare genodermatosis. *Indian Dermatol Online J* 2020;11:116-8.
2. Mazereeuw-Hautier J, Bitoun E, Chevrant-Breton J, Man SY, Bodemer C, Prins C, *et al.* Keratitis-ichthyosisdeafness syndrome: Disease expression and spectrum of connexin 26 (GJB2) mutations in 14 patients. *Br J Dermatol* 2007;156:1015-9.
3. Enei ML, Cassettari A, Córdova S, Torres O, Paschoal F. Do you know this syndrome? *An Bras Dermatol* 2011;86:819-21.
4. Messmer EM, Kenyon KR, Rittinger O, Janecke AR, Kampik A. Ocular manifestations of keratitis-ichthyosis-deafness (KID) syndrome. *Ophthalmology* 2005;112:e1-6.
5. Elias P, Ahn S, Brown B, Crumrine D, Feingold KR. Origin

of the epidermal calcium gradient: Regulation by barrier status and role of active vs passive mechanisms. *J Invest Dermatol* 2002;119:1269-74.

This is an open access journal, and articles are distributed under the terms of the Creative Commons Attribution-NonCommercial-ShareAlike 4.0 License, which allows others to remix, tweak, and build upon the work non-commercially, as long as appropriate credit is given and the new creations are licensed under the identical terms.

Access this article online	
Website: www.idoj.in	Quick Response Code 
DOI: 10.4103/idoj.IDOJ_603_20	

How to cite this article: Caroppo F, Szekely S, Fortina AB. Novel variant c.148 G>T of GJB2 gene in a 5-year-old child with KID syndrome. *Indian Dermatol Online J* 2020;11:1014-5.

Received: 28-Jul-2020. **Revised:** 15-Sep-2020.

Accepted: 13-Oct-2020. **Published:** 08-Nov-2020.

© 2020 Indian Dermatology Online Journal | Published by Wolters Kluwer - Medknow