

HOSTED BY




ELSEVIER

Available online at www.sciencedirect.com

ScienceDirect

journal homepage: <http://www.elsevier.com/locate/ijpam>



ORIGINAL RESEARCH ARTICLE

Radiologic and clinical evaluation of children with first febrile urinary tract infection



A. Nickavar^a, B. Safaeian^{b,*}, M. Biglari abhari^c

^a Department of Pediatric Nephrology, Iran University of Medical Sciences, Tehran, Iran

^b Department of Pediatrics, Gorgan University of Medical Sciences, Gorgan, Iran

^c Resident of Community Medicine, Iran University of Medical Sciences, Tehran, Iran

Received 16 December 2014; received in revised form 27 February 2015; accepted 6 March 2015

Available online 1 April 2015

KEYWORDS

Acute pyelonephritis;
Vesicoureteral reflux;
Ultrasonography;
DMSA scan;
Cystoureterography

Abstract *Background and objectives:* Accurate diagnosis of acute pyelonephritis (APN) is clinically challenging in young children. The evaluation methods for APN and its major risk factor, vesicoureteral reflux (VUR), have been revised in recent years. The aim of this study was to evaluate the value of different radiologic investigations in children experiencing the first episode of APN.

Materials and methods: This study included 425 children of 2–12 months of age (17.5% male, 82.5% female) with APN. APN was defined as a positive urine culture associated with focal or diffuse decreased cortical uptake and preservation of renal contour indicated by DMSA renal scan.

Results: The mean age at diagnosis was 39.2 ± 1.56 months. The following signs were observed in the patients: fever ≥ 38.5 °C, 66.8%; positive CRP, 85.4%; ESR > 25 , 78.6%; and leukocytosis $> 13,000/\text{mm}^3$, 53.4%.

Pyelocalyceal fullness and increased parenchymal echogenicity were the most common renal ultrasonography findings, and ultrasonography had 34% sensitivity and 53% specificity for these two findings. DMSA scan and ultrasound findings of APN were not significantly correlated ($P = .112$).

VUR was found in 42.2% of patients. DMSA scanning was not reliable for the diagnosis of VUR ($P = .956$), with 42% sensitivity and specificity.

VUR was identified in 42.7% of patients by ultrasound ($P = .001$), and the diagnostic rate was related to the VUR severity. Ultrasound had 42.7% sensitivity and 27% specificity for the diagnosis of VUR.

* Corresponding author. Taleghani Childrens Hospital, Gorgan University of Medical Sciences, Gorgan, Iran. Tel.: +98 01732234364.

E-mail address: safaeian26@gmail.com (B. Safaeian).

Peer review under responsibility of King Faisal Specialist Hospital & Research Centre (General Organization), Saudi Arabia.

Conclusion: Determination of inflammatory markers is recommended for the evaluation of children with APN. In addition, normal ultrasound is a valuable imaging tool for excluding high grade VUR.

Copyright © 2015, King Faisal Specialist Hospital & Research Centre (General Organization), Saudi Arabia. Production and hosting by Elsevier B.V. This is an open access article under the CC BY-NC-ND license (<http://creativecommons.org/licenses/by-nc-nd/4.0/>).

1. Introduction

Acute pyelonephritis (APN) is one of the most common serious bacterial infections that occurs in febrile infants and young children. The most significant complication of acute pyelonephritis (APN) is permanent renal damage, characterized by proteinuria, hypertension and chronic renal failure [1–3].

The assessment and follow-up of children with UTI have been revised in recent years. The American Academy of Pediatrics recommended US for the initial evaluation of the first febrile UTI in children 2–24 months of age and recommends VCUG in children with evidence of obstructive hydronephrosis, renal cortical scarring, evidence of severe VUR, recurrent febrile UTI and atypical conditions [4,5].

The NICE guidelines suggest renal US for the first febrile UTI in children younger than 6 months of age and in those with atypical serious UTI, increased serum creatinine concentration and septicaemia. A DMSA scan has been suggested for follow up of atypical or recurrent UTI at 4–6 months after resolution [6,7].

According to the limitations of invasive procedures in the current guidelines, we performed this study to compare the accuracy of different radiologic imaging techniques for the diagnosis of APN and VUR in children experiencing the first episode of APN to determine the least invasive approaches that are accurate for the evaluation of APN in children.

2. Materials and methods

This is a retrospective study of children experiencing the first episode of APN admitted to two children's medical centres between 2006 and 2013. The study was approved by the institutional review committee.

A total of 425 children (17.5% males, 82.5% females) were included in this study. APN was defined as a UTI associated with a positive DMSA scan. UTI was defined as growth of more than 10^5 CFU/ml in a mid-stream urine sample, more than 10^4 CFU/ml in urine obtained by bladder catheterization, or any growth observed in suprapubic aspirate.

Patients with congenital and acquired urologic abnormalities, voiding dysfunction, neurogenic bladder, nephrolithiasis, recurrent UTI, extra-renal infections, inflammatory conditions, hypertension, renal insufficiency, incomplete radiologic procedures, mixed bacterial growth, lower UTI, and incomplete follow-up were excluded from the study.

Inflammatory markers, such as positive CRP, ESR > 25 , and WBC $> 13,000/\text{mm}^3$, were identified. A Tc 99 DMSA scan was performed during the first week of admission by injection of 2 MBq/kg Tc 99 DMSA. A positive DMSA scan was defined as focal or diffuse decreased cortical uptake with preservation of renal contour.

Renal US was performed within the first 72 h of admission by 2 expert paediatric radiologists. US findings of APN included altered parenchymal echogenicity, pelvicalyceal dilatation or fullness, undifferentiated corticomedullary junction, and renal enlargement.

VUR was identified by conventional or radioisotope cystography and classified as mild (grades 1–2), moderate (grade 3) and severe (grades 4–5). US findings of VUR included a renal pelvic diameter greater than 5 mm or variable caliectasis during voiding.

The validity of the tests was determined by generating receiver operating characteristic (ROC) curves using SPSS software version 19. A *P* value $< .05$ was considered statistically significant.

3. Results

The mean age at diagnosis was 39.2 ± 1.56 (range 2–120) months. The clinical manifestations and laboratory findings are summarized in Table 1. The most frequently isolated organisms were Ecoli, klebsiella, Pseudomonas, Proteus and Enterococcus species. More than 3/4 of patients were sensitive to nitrofurantoin, third generation cephalosporins, aminoglycosides, and ciprofloxacin and resistant to cotrimoxazole and ampicillin.

VUR was found in 42.2% of patients, and it was bilateral in 44.1% of those patients. Of the patients with VUR, 44.8%

Table 1 Clinical manifestations and laboratory findings of the patient groups.

Variables	Frequency %
<i>Clinical manifestations</i>	
Fever ≥ 38.5	66.8
Flank pain	42.6
Urinary tract complaints (dysuria, frequency, urinary incontinence)	32.7
Systemic manifestations	24.8
<i>Laboratory findings</i>	
Positive CRP	85.4
Increased ESR	78.6
Leukocytosis $> 13,000$	53.4

Table 2 Value of different radiologic studies in children experiencing first APN.

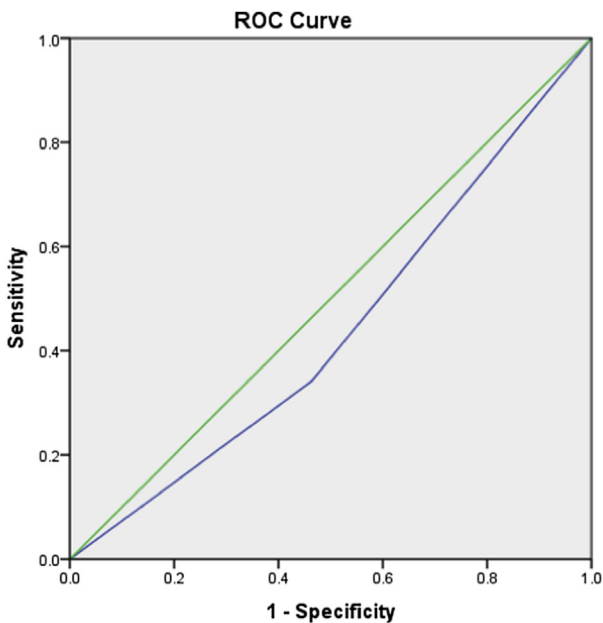
Variables	Sensitivity	Specificity	PPV	NPV	PLR	NLR
USG in APN	34	53	87	8	0.72	0.8
USG in VUR	42.7	27	53.5	63.5	0.58	0.47
DMSA in VUR	42	42	91.5	8	0.72	0.72

had severe reflux, followed by 30.8% with moderate reflux and 24.4% with mild reflux.

The most common sonographic findings of APN were pyelocaliceal fullness (76%) and increased parenchymal echogenicity (21%). US and DMSA scan findings of APN were not significantly correlated ($P = .112$). US had 34% sensitivity and 53% specificity for diagnosis of APN (Table 2). US was not accurate for the diagnosis of APN ($P = .188$) (Figure 1).

VUR was detected in 35.7% of patients with a positive DMSA scan ($P = .948$), with 42% sensitivity and specificity (Table 2). DMSA scan was not accurate for VUR diagnosis ($P = .956$) (Figure 2).

US findings of VUR were detected in 42.7% of patients, with a significant correlation to cystography ($P = .001$), and the rate of VUR detection by US was related to VUR severity (30% diagnosed with mild, 40% diagnosed with moderate and 51% diagnosed with severe VUR).



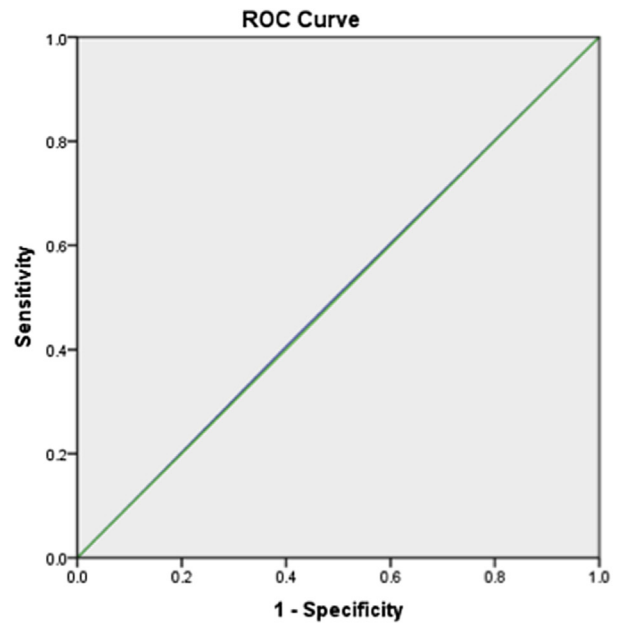
Diagonal segments are produced by ties.

Area Under the Curve

Test Result Variable(s): sonoAPN

Area	Std. Error ^a	Asymptotic Sig. ^b	Asymptotic 95% Confidence Interval	
			Lower Bound	Upper Bound
.439	.047	.188	.347	.531

Figure 1 ROC curve of USG in APN.



Diagonal segments are produced by ties.

Area Under the Curve

Test Result Variable(s): DMSA

Area	Std. Error ^a	Asymptotic Sig. ^b	Asymptotic 95% Confidence Interval	
			Lower Bound	Upper Bound
.503	.050	.956	.404	.601

Figure 2 ROC curve of DMSA scan in VUR.

US had low sensitivity (42.7%) and specificity (27%) for VUR diagnosis (Table 2); however, according to the ROC analysis, US was accurate for VUR diagnosis ($P = .006$) (Figure 3).

4. Discussion

US, Tc 99 DMSA scan and cystography were introduced as the standard screening procedures for APN in previous reports [8,9]. However, the evaluation and management procedures for children with APN have been revised in recent guidelines. We performed this study to identify the reliability of these radiologic approaches for the diagnosis and evaluation of children experiencing the first episode of APN.

In 30–50% of patients with an abnormal DMSA scan, APN has been detected by US [10,11], and US is not considered accurate as a single test for APN diagnosis [12]. However, B mode high resolution ultrasound was shown to be as sensitive as DMSA scan for the diagnosis of non-obstructive APN in a study by Morin et al. [13]. The accuracy of US depends to the age of the children with APN and is lower in children younger than 1 year old [11]. DMSA scan has not been recommended in children older than 5 years at the presentation of the first UTI in patients with a normal ultrasound [14]. Accordingly, US findings of APN was detected in 1/3 of our patients, with low sensitivity, specificity and accuracy. Normal US did not exclude APN, but the results of

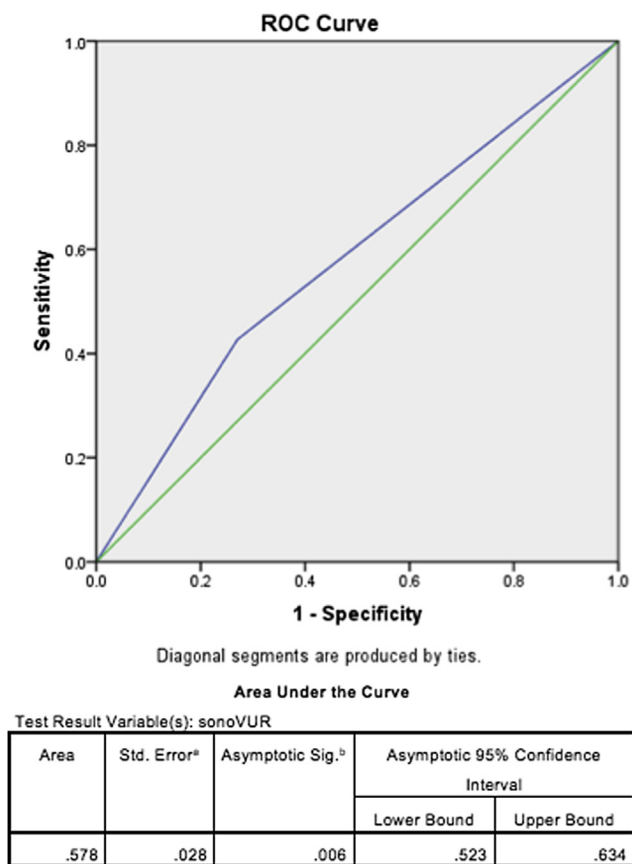


Figure 3 ROC curve of USG in VUR.

our study suggest that it can be used for the screening of urinary tract abnormalities.

VUR has been reported in 27–70% of patients with an abnormal DMSA scan [12,14]. DMSA scan has low sensitivity and limited VUR diagnosis ability [15], and it is not considered an absolute substitution for cystography, missed 30% of patients [3,9,16]. However, the possibility of VUR (especially high grade VUR) has been low in both normal DMSA scan and US in children older than 1 year, excluding VCUG in some studies [17,18]. In our study, VUR was detected in 35.7% of patients with a positive DMSA scan, with low sensitivity, specificity and accuracy. The accuracy of DMSA scan was related to age and severity of VUR, with 9% of mild and 33% of high grade VUR cases being identified by DMSA scan.

US findings of VUR have been reported in 10–45% of patients with VUR [19]. With US, 74% of VUR cases were not identified, and 25% of the cases were severe VUR. US is not considered an accurate substitution for VCUG in VUR diagnosis due to its low sensitivity and specificity, especially in children younger than 2 years. The accuracy of US depends on VUR grade [20–22], and a study by Massanyi showed a 0.16 sensitivity for grade 1–V VUR and a 0.5 sensitivity in grade V VUR [22]. However, US has been suggested for initial VUR investigation, especially for high grade cases [8,21]. US was abnormal in 42.7% of our patients with VUR, with low sensitivity and specificity but acceptable accuracy for predicting high grade VUR. In addition, VGUG was abnormal in all patients with sonographic evidence of VUR.

In conclusion, the determination of inflammatory markers, such as fever, CRP and ESR are recommended for the evaluation of children with APN. US is not a valuable imaging technique for the diagnosis of APN, but is suggested for the exclusion urinary tract abnormalities. In addition, normal US is valuable for excluding high grade VUR and administration of prophylactic antibiotics. Furthermore, cystography cannot be excluded as a valuable diagnostic tool for VUR.

There are some limitations to our study. First, the study was retrospective, which generates possible selection bias. However, we attempted to enrol all patients with APN during the study period. Second, the accuracies of US and DMSA scanning may have been influenced by the two different operators. Third, some of the patients may have had previous unrecognized UTIs, and VUR may have been missed due to the inaccuracy of VCUG in 35% of patients.

Conflicts of Interest

The authors have no conflicts of interest to disclose.

Acknowledgement

This study was supported by the Childrens and Neonatal Health Center of Gorgan Medical University.

References

- [1] Nickavar A, Sotoudeh K. Treatment and prophylaxis in pediatric urinary tract infection. *Int J Prev Med* 2011;2:4–9.
- [2] Jaksic E, Bogdanovic R, Artiko V, Saranovic DS, Petrasinovic Z, Petrovic M, et al. Diagnostic role of initial renal cortical scintigraphy in children with the first episode of acute pyelonephritis. *Ann Nucl Med* 2011;251:37–43.
- [3] Sheu JN, Wu KH, Chen SM, Tsai JD, Chao YH, Lue KH. Acute 99mTc DMSA scan predicts dilating vesicoureteral reflux in young children with a first febrile urinary tract infection: a population-based cohort study. *Clin Nucl Med* 2013;38:163–8.
- [4] Practice parameter: the diagnosis, treatment, and evaluation of the initial urinary tract infection in febrile infants and young children. American Academy of Pediatrics. Committee on Quality Improvement. Subcommittee on Urinary Tract Infection. Subcommittee on Urinary Tract Infection. *Pediatrics* 1999;103(4 Pt 1):843–52.
- [5] Urinary tract infection: clinical practice guideline for the diagnosis and management of the initial UTI in febrile infants and children 2 to 24 months. *Pediatrics* 2011;128:595–610.
- [6] Mori R, Lakhanpaul M, Verrier-Jones K. Diagnosis and management of urinary tract infection in children: summary of NICE guidance. *BMJ* 2007;25:395–7.
- [7] Supavekin S, Surapaitoolkorn W, Pravisithikul N, Kqtanavanishapong S, Chiewvit S. The role of DMSA renal scintigraphy in the first episode of urinary tract infection in childhood. *Ann Nucl Med* 2013;27:170–6.
- [8] Ismaili K, Wissing KM, Lotin K, Le PQ, Christophe C, Lepage P, et al. Characteristics of first urinary tract infection with fever in children: a prospective clinical and imaging study. *Pediatr Infect Dis J* 2011;30:371–4.
- [9] Nammalwar BR, Vijayakumar M, Sankar J, Ramnath B, Prahlad N. Evaluation of the use of DMSA in culture positive UTI and culture negative acute pyelonephritis. *Indian Pediatr* 2005;42:691–6.

- [10] Björngvinsson E, Majd M, Eggl KD. Diagnosis of acute pyelonephritis in children: comparison of sonography and ^{99m}Tc-DMSA scintigraphy. *Am J Roentgenol* 1991;157:539–43.
- [11] MacKenzie JR, Fowler K, Hollman AS, Tappin D, Murphy AV, Beattie TJ. The value of ultrasound in the child with an acute urinary tract infection. *Br J Urol* 1994;74:240–4.
- [12] Morin D, Veyrac C, Kotzki PO, Lopez C, Dalla Vale F, Durand MF, et al. Comparison of ultrasound and dimercaptosuccinic acid scintigraphy changes in acute pyelonephritis. *Pediatr Nephrol* 1999;13:219–22.
- [13] Ataei N, Madani A, Habibi R, Khorasani. Evaluation of acute pyelonephritis with DMSA scans in children presenting after the age of 5 years. *Pediatr Nephrol* 2005;20:1439–44.
- [14] Sorkhi H, Nooreddini HG, Amiri M, Osia S, Farhadi-Niakee S. Prediction of vesicoureteral reflux in children with first urinary tract infection by dimercaptosuccinic acid and ultrasonography. *Iran J Pediatr* 2012;22:57–62.
- [15] Mantadakis E, Vouloumanou EK, Georgantzi GG, Tsalkidis A, Chatzimichael A, Falagas ME. Acute Tc-99m DMSA scan for identifying dilating vesicoureteral reflux in children: a meta-analysis. *Pediatrics* 2011;128:e169–79.
- [16] Preda I, Jodal U, Sixt R, Stokland E, Hansson S. Normal dimercaptosuccinic acid scintigraphy makes voiding cystourethrography unnecessary after urinary tract infection. *Pediatrics* 2007;151:581–4.
- [17] Zhang X, Xu H, Zhou L, Cao Q, Shen Q, Sun L, et al. Accuracy of early DMSA scan for VUR in young children with febrile UTI. *Pediatrics* 2014;133:e30–8.
- [18] Lee MD, Lin CC, Huang FY, Tsai TC, Huang CT, Tsai JD. Screening young children with a first febrile urinary tract infection for high-grade vesicoureteral reflux with renal ultrasound scanning and technetium-99m-labeled dimercaptosuccinic acid scanning. *J Pediatr* 2009;154:797–802.
- [19] Lee HY, Soh BH, Hong CH, Kim MJ, Han SW. The efficacy of ultrasound and dimercaptosuccinic acid scan in predicting vesicoureteral reflux in children below the age of 2 years with their first febrile urinary tract infection. *Pediatr Nephrol* 2009;24:2009–13.
- [20] Adibi A, Gheysari A, Azhir A, Merikhi A, Khani S, Tayari N. Value of sonography in the diagnosis of mild, moderate and severe vesicoureteral reflux in children. *Saudi J Kidney Dis Transpl* 2013;24:297–302.
- [21] Massanyi EZ, Preece J, Gupta A, Lin SM, Wang MH. Utility of screening ultrasound after first febrile UTI among patients with clinically significant vesicoureteral reflux. *Urology* 2013;82:905–9.
- [22] Juliano TM, Stephany HA, Clayton DB, Thomas JC, Pope 4th JC, Adams MC, et al. Incidence of abnormal imaging and recurrent pyelonephritis after first febrile urinary tract infection in children 2 to 24 months old. *J Urol* 2013;190(Suppl. 4):1505–10.