



Office-Based Surgical Intervention for Hidradenitis Suppurativa (HS): A Focused Review for Dermatologists

Drew K. Saylor · Nicholas D. Brownstone · Haley B. Naik

Received: March 2, 2020 / Published online: May 20, 2020
© The Author(s) 2020

ABSTRACT

Easily accessible office-based procedures that require minimal resources may facilitate timely surgical management of hidradenitis suppurativa (HS). This review focuses on excision and unroofing as two surgical HS treatments that can be tailored to the outpatient setting. Fifty-five articles were included in our review, representing 3914 patients. The majority were retrospective studies (58%, $n = 32$), and the studies reported data both across patients and by number of treated lesions. Recurrence rates for unroofing (14.5%) were found to be half that of excision (30%) across patients ($p = 0.015$) and slightly lower across lesions [20% recurrence vs 26% for excision ($p = 0.023$)]. Complication rates at the lesion level were also significantly associated with procedure, with rates after excision more than double those after roofing (26% vs. 12%, $p < 0.001$). The complication rate

after combined medical and surgical therapy did not differ between procedures. Studies also suggest that continuing medical therapy in the perioperative period may be associated with improved recurrence rates, although delayed wound healing with biologic therapy has been reported. The existing data are limited by low-quality uncontrolled studies with small sample sizes, variable reporting of outcomes, and lack of uniform definitions for recurrence and remission. Further systematic prospective studies are needed to better compare complication and recurrence rates across these procedures in HS, especially in the context of concomitant medical therapy.

Keywords: Complication rate; Deroofing; Excision; Hidradenitis suppurativa; Hurley; Recurrence rate; Unroofing

Digital Features To view digital features for this article go to <https://doi.org/10.6084/m9.figshare.12229442>.

D. K. Saylor (✉) · N. D. Brownstone · H. B. Naik
Department of Dermatology, University of
California, San Francisco, CA, USA
e-mail: drew.saylor@ucsf.edu

Key Summary Points

Early accessible office-based procedures that require minimal resources such as local excision and unroofing may facilitate timely surgical management of hidradenitis suppurativa

This review compared local excision and unroofing across 55 included articles based on a number of variables, including recurrence and complication rates

Recurrence rates for unroofing (14.5%) were found to be half those of excision (30%) across patients

Complication rates for unroofed lesions (12.5%) were found to be lower than for excised lesions (26%)

However, existing data are limited by low-quality uncontrolled studies with small sample sizes, variable reporting of outcomes, and lack of uniform definitions for recurrence and remission

INTRODUCTION

Hidradenitis suppurativa (HS) is a chronic inflammatory skin disorder centered around the hair follicle that appears to be the end result of a complex interplay of genetics, microbes, immune dysregulation, and environmental factors [3]. The hallmark of progressive disease is the creation of suppurative and connected dermal tunnels, tracts, bridging nodules, sinuses, and fistulas. This structural alteration of the skin has historically contributed to the belief that HS is a surgical disease, with wide or radical excisions performed to remove abnormal areas. However, such an approach is associated with significant morbidity, including nerve damage, thrombosis, bleeding, infection, dehiscence, and scar contracture [30]. With the introduction of improved medical therapies including broad-spectrum antibiotics, hormonal

therapies, and biologic therapies, the role for surgery is shifting though it is still essential to current management.

HS is now considered both a medical and surgical disease, recognizing that the fundamental physical alteration of the skin in later stages of disease needs to be addressed alongside the other known mechanisms of the inflammatory component of the disease in all stages. There are numerous procedural modalities for HS, all with the common goal of altering or removing areas of abnormal skin that are typically not responsive to existing medical therapies alone. Simple procedures that can be performed in an outpatient office-based setting include incision and drainage (an incision made over suppurative nodules to facilitate drainage), unroofing (insertion of a probe into abscesses and sinuses of HS followed by a systematic removal of all involved tissue down to the base of the tracts), and limited or wide excision (removal of diseased skin with a margin of normal skin). Other procedures that require additional equipment include CO₂ laser (laser excision, marsupialization, and destruction of tracts, usually with second intention healing), neodymium-yttrium aluminum garnet laser (Nd:YAG) (laser destruction of hair follicles), and electrosurgery (loop electrode removal of diseased skin down to the subcutaneous layer). Surgical approaches that typically require an operating room setting and surgical specialist include radical excision (removal of skin even beyond the clinically evident areas in an effort to capture hidden disease). These treatments vary markedly in their technique, level of invasiveness, and morbidity.

This review focuses on excision and unroofing for several reasons. First, excision in its various forms (limited/local, wide, and radical) is traditionally the most common procedure for HS and is considered a surgical mainstay, especially for Hurley III patients. Of note, it is rare for authors to uniformly define the diameter or exact width of an excision in the literature, making it difficult to discriminate among limited (removal of diseased area with < 1 cm margin), wide (removal of diseased area with several centimeters of normal skin), and radical (removal of entire anatomic subunits) excision.

The size of excision determines whether this can be a realistic in-office procedure for dermatologists, with limited excision typically performed under local anesthesia and radical excision reserved for an operating room setting with surgical specialists. In contrast, unroofing has a much smaller literature base and is almost always performed in the outpatient setting. Unroofing generally involves insertion of a probe into tunnels of HS followed by a systematic removal of all involved tissue down to the base of the tracts [58]. Although these two procedures are very different, they can be used on overlapping types of HS lesions, including inflammatory nodules, tunneling sinus tracts, abscesses, and scarring. They are perhaps the more accessible of the many surgical options, requiring no additional office equipment or specialists in many cases. Incision and drainage is also a simple in office procedure, but was not reviewed because it carries a 100% recurrence rate and is best reserved for relief of pain secondary to acute inflammatory nodules or abscesses [16, 36].

Dermatologists can play a crucial role in the timing and type of procedures utilized for HS because they often serve as the medical home for patients with HS, optimizing medical management while coordinating referrals for surgical and other specialists. This review intentionally focuses on two office-based procedures that can be performed by dermatologists: excision and unroofing. This review summarizes data on recurrence and complication rates for excisions and unroofing to better assist physicians attempting to navigate these surgical treatment decisions.

This article is based on previously conducted studies and does not contain any studies with human participants or animals performed by any of the authors.

METHODS

A literature search for articles was conducted using the PubMed database from 1 January 1985 to 31 December 2019 (Fig. 1) using the search terms (“hidradenitis suppurativa OR acne inversa”) AND (“surgery”), AND (“procedure”),

AND (“excision”), AND (“unroofing” OR “deroofting”). A filter was used for this search to include only English language articles and full-text articles. The titles and abstracts were reviewed, and articles were included if they discussed surgical management of HS and excluded if they did not discuss surgery, focused mainly on reconstructive technique or wound healing, focused only on other procedural modalities (e.g., CO₂ laser), were short communications (such as letters to the editor or viewpoints), were reviews or meta-analyses, did not have HS as the primary focus or only focused on management of HS sequelae (e.g., lymphedema), or focused only on description of surgical technique. Duplicate articles were then removed. Patient demographics, clinical characteristics, HS characteristics, HS medical and surgical intervention, and postoperative complications were collected for each study using a pre-determined standardized data form. Descriptive statistics were calculated, and recurrence and complication data were first totaled across the included studies at both the patient and the lesion level. These data were stratified by procedure (excision versus medical therapy) and summarized using counts and frequencies. Rates of recurrence and complication were compared between the two procedural groups using chi-square tests or Fischer’s exact tests where appropriate.

RESULTS

A total of 1621 potentially relevant unique articles were identified from the initial literature search. Of these, 594 articles were excluded because they did not discuss surgery, 207 articles were excluded because of having the sole focus on reconstruction and/or wound healing, 76 articles were excluded because of having a focus only on other procedural treatments (e.g., CO₂ laser), 48 articles were excluded because they were short communications (e.g., letters to the editor), 187 articles were excluded because they were reviews or meta-analyses, 192 articles were excluded because HS was not the primary focus or only discussed management of sequelae of HS (e.g., lymphedema), and 92 articles

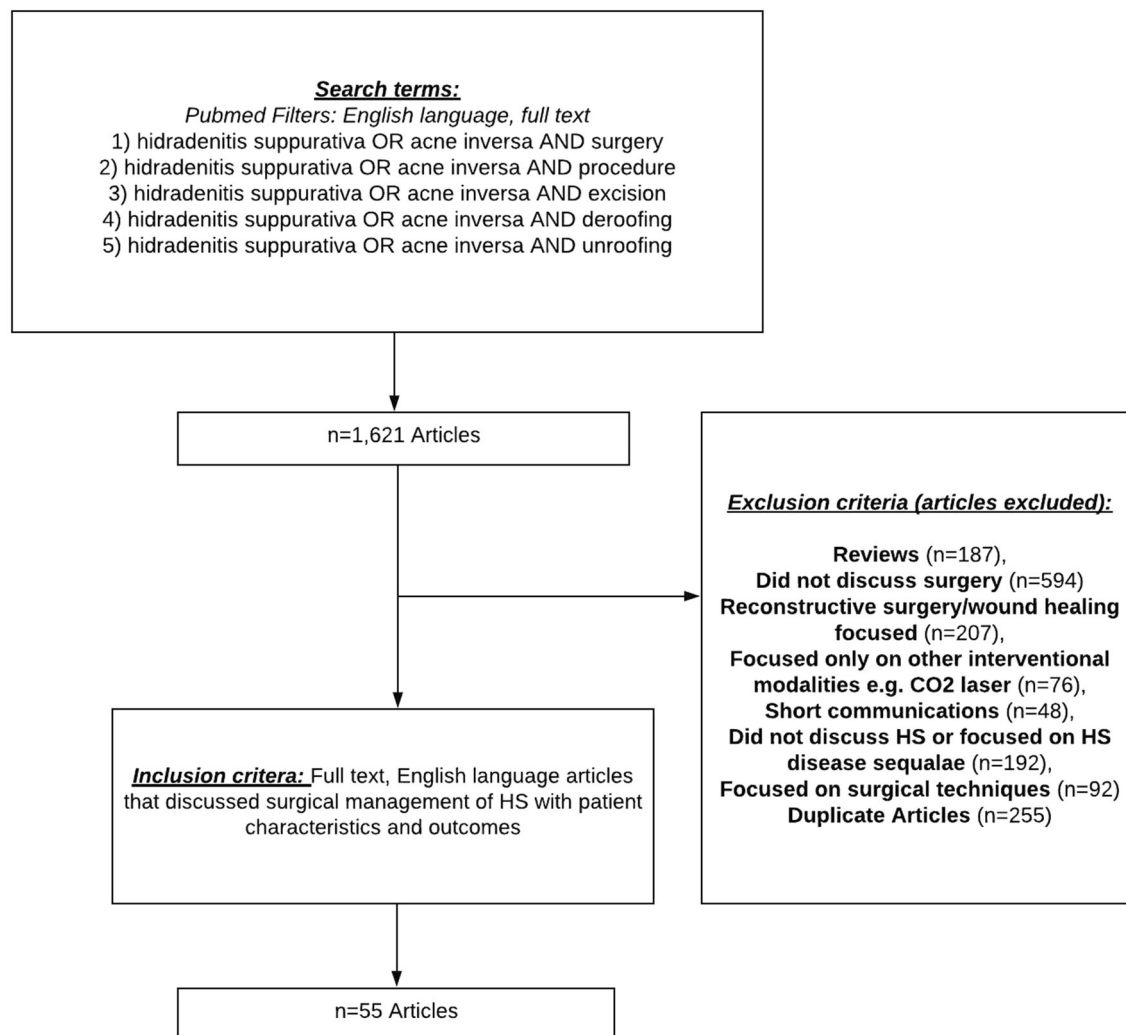


Fig. 1 Diagram of literature review

were excluded because they focused only on descriptions of surgical technique (Fig. 1). Fifty-five unique articles were ultimately selected based on inclusion/exclusion criteria, including 32 retrospective studies (58%), 12 case series/case reports (22%), and 11 prospective studies (20%). Across all studies, 3914 patients were included for analysis. A summary of all articles is included in Table 1.

Excision

Forty-five articles (81%) comprising 2816 patients discussed excision in the treatment of HS: 60% of these articles were retrospective

studies ($n = 27$), 22% were case series/case reports ($n = 10$), and 18% were prospective studies ($n = 8$). See Table 2 for a summary of excision data. Hurley staging was provided in 34.7% ($n = 976$) of these patients (Hurley stage 1: 5.2%, $n = 51$; Hurley stage 2: 31.3%, $n = 305$; Hurley stage 3: 63.1%, $n = 616$). Excision studies that reported an average duration of disease ($n = 15$) had a mean duration of 19.7 years. Seven excision studies reported an average time from disease onset to excision, with a mean of 7.6 years. Follow-up periods were reported differently across all the excision studies (Table 1). Of the studies that provided a mean follow-up,

Table 1 Summary of articles

Study	Study design	Treatment method	No. of patients, surgical site	Hurley stage	Recurrence rate (timeline)	Top 3 complications (patients with complication), timeline	Follow-up	Adjuvant medical therapy (timeline)
Local excision								
Prens et al. [45]	Prospective	Local excision	39, Multiple	1, 2, 3	9/39 (NR)	10/39: Postoperative bleeding hypergranulation tissue (combined 90%), NR	12 mos (mean)	Yes—biologics (pre- and post-surgical)
Posch et al. [44]	Prospective	Local excision	74, Multiple	3	14/74 (4.7 years)	35/74: Postoperative pain ($n = 30$), hypertrophic scarring ($n = 22$), mobility restriction ($n = 7$), NR	4.72 years (median)	No
Yamashita et al. [65]	Prospective	Local excision	18, Buttocks and perineum	2, 3	1/18 (NR)	11/18: Surgical site infection (55%), skin graft loss (5%), NR	8–36 mos (mean 12.3 mos)	No
Büyükaşık et al. [13]	Prospective	Local excision	15, Multiple	1, 2, 3	2/36 lesions (NR)	9/36 Lesions: surgical site infection (33%), wound dehiscence (22%), contracture (22%), NR	10–84 mos (mean 44 mos)	No
Bieniek et al. [6]	Prospective	Local excision	57, Multiple	1, 2, 3	NR	33/57: Pain (33%), surgical site infection (10%), contracture (7%), NR	24 mos	No
Buimer et al. [11]	Prospective	Local excision	200, NR	NR	84/200 (3 mos)	104/200: Dehiscence and infection (15%), infection (8%), 0–3 mos	72 mos (mean)	Yes—antibiotics (intraoperative gentamicin)

Table 1 continued

Study	Study design	Treatment method	No. of patients, surgical site	Hurley stage	Recurrence rate (timeline)	Top 3 complications (patients with complication), timeline	Follow-up	Adjuvant medical therapy (timeline)
Puri et al. [47]	Prospective	Local excision	30, Multiple	NR	6/30 (NR)	NR	NR	Yes–retinoid (NR)
Shanmugam et al. [54]	Prospective	Local excision	68, NR	1, 2, 3	NR	NR	NR	Yes–biologics (NR)
Ngaage et al. [42]	Retrospective	Local excision	79, Multiple	1, 2, 3	56/220 Lesions (5–23 mos)	76/200 Lesions: wound dehiscence (29%), contracture (3.5%), infection (2.5%), 90 days	33 mos (median)	No
Walter et al. [61]	Retrospective	Local excision	48, Multiple	3	26/48 (3 wk–5 yrs)	NR	Mean 3.81 yrs (1.08–6.25 yrs)	No
Nweze et al. [43]	Retrospective	Local excision	214, axilla	NR	22/214 (48 mos)	NR	6.5 yrs (mean)	No
Kofler et al. [34]	Retrospective	Local excision	255, Multiple	3	173/255 (0–57 mos)	70/255: Postoperative bleeding (NR), surgical site infection (NR), limited mobility (NR), NR	Mean 57 mos (19–127 mos)	No
Deckers et al. [17]	Retrospective	Local excision	86, Multiple	1, 2, 3	95/253 Lesions (6 mos)	NR	Mean 26.2 mos (6–79 mos)	No
Burney et al. [12]	Retrospective	Local excision	122, Multiple	NR	NR	NR	5.6 years	No
Romanowski et al. [49]	Retrospective	Local excision	98, Multiple	1, 2, 3	NR	NR	12 mos	No

Table 1 continued

Study	Study design	Treatment method	No. of patients, surgical site	Hurley stage	Recurrence rate (timeline)	Top 3 complications (patients with complication), timeline	Follow-up	Adjuvant medical therapy (timeline)
Wollina et al. [62]	Retrospective	Local excision	117, Anogenital	3	6/117 (NR)	7/117: Postoperative bleeding (13%), surgical site infection (13%), wound dehiscence (13%)	NR	Yes – biologics, antibiotics, retinoids (pre-surgical)
Humphries et al. [28]	Retrospective	Local excision	17, Multiple	NR	2/17 (NR)	NR	Mean 1.02 yrs (1.2 mos–5.25 yrs)	No
DeFazio et al. [18]	Retrospective	Local excision	21, Multiple	3	4/21 (NR)	5/21: Surgical site infection (10%), delayed wound healing (10%), wound dehiscence (5%), NR	Mean 18 mos (6–31 mos)	Yes—biologics (post-surgical)
Chen et al. [14]	Retrospective	Local excision	6, Inguinal	3	1/6 (NR)	NR	Mean 4.3 mos (2.7–6.1 mos)	No
Nesmith et al. [41]	Retrospective	Local excision	11, axilla	NR	0/11 (NR)	0/11, NR	Mean 4.3 yrs	Yes—antibiotics (pre-and post-surgical)
Van Rappard et al. [60]	Retrospective	Local excision	57, Multiple	NR	21/57 (NR)	17/57: Wound dehiscence (NR), postoperative bleeding (NR), surgical site infection (NR), NR	Mean 14 mos (3–84 mos)	No
Kagan et al. [33]	Retrospective	Local excision	57, Multiple	NR	0/57, NR	NR	Mean 8.5 mos	No

Table 1 continued

Study	Study design	Treatment method	No. of patients, surgical site	Hurley stage	Recurrence rate (timeline)	Top 3 complications (patients with complication), timeline	Follow-up	Adjuvant medical therapy (timeline)
Bocchini et al. [8]	Retrospective	Local excision	56, Buttock and perineum	NR	1/56 (17 mos)	16/56 Partial graft loss (16%), persistent disease (9%), anal stenosis (2%), NR	Mean 12 mos (4 mos–6 yrs)	No
Bohn et al. [9]	Retrospective	Local excision	138, Multiple	NR	38/138	NR	8 yrs (0–21 yrs)	No
Rompel et al. [50]	Retrospective	Local excision	106, Multiple	NR	43/106 (NR)	43/106: Wound dehiscence (12%), postoperative bleeding (11%), surgical site infection (8%), 6–36 mos	Median 36 mos	No
Soldin et al. [55]	Retrospective	Limited local excision, wide local excision, radical excision	59, Axilla	NR	NR	11/59: Wound dehiscence (12%), incomplete graft take (10%), contracture (8%), NR	Mean 16 (4–122 mos)	No
Jemec et al. [31]	Retrospective	Local excision	84, Multiple	NR	NR	NR	Mean 4.5 years (1–11 yrs)	No
Harrison et al. [27]	Retrospective	Local excision	95, Multiple	NR	19/95 (3–72 mos)	14/95 Skin graft failure (9%), anemia (4%), edema (2%), NR	Mean 47 mos (6–89)	No
Jafari et al. [29]	Retrospective	Local excision	68, Multiple	1, 2, 3	NR	NR	NR	No
Wollina et al. [63]	Retrospective	Local excision	67, Peri-anal and genital	3	6/67 (6–6065 days)	7/67: Bleeding (2%), fever (2%), infection (2%), 30 days	56	Yes–biologics (pre-surgical)

Table 1 continued

Study	Study design	Treatment method	No. of patients, surgical site	Hurley stage	Recurrence rate (timeline)	Top 3 complications (patients with complication), timeline	Follow-up	Adjuvant medical therapy (timeline)
Balik et al. [5]	Retrospective	Local excision	15, Gluteal and genital	3	0/15 (0–5 years)	0/15 (0–5 years)	Mean 5 years	No
Alharbi et al. [2]	Retrospective	Local excision	32, Multiple	2, 3	6/32 (NR)	4/32 (NR)	Mean 24 mos	No
Fertitta et al. [21]	Retrospective	Limited local excision, wide local excision	75, Multiple	1, 2, 3	40/115 lesions (NR), 24% wide excision, 50% limited excision	11/115 Lesions: scar retraction (36%), lymphedema (36%), surgical site infection (27%) (NR)	Mean 449 days (0–2061 days)	No
Ge et al. [23]	Case series	Local excision	4, Multiple	3	0/4	0/4, NR	4 years	No
Garék et al. [22]	Case series	Local excision	2, Axilla and inguinal	3	0/2	1/2 Wound dehiscence (50%)	NR	No
Menderes et al. [40]	Case series	Local excision	27, Multiple	1, 2, 3	2/27	NR	Mean 19.7 mos (6–48 mos)	No
Endo et al. [20]	Case series	Local excision	12, Peri-anal	NR	2/12 (4 years)	NR	NR	No
Ather et al. [4]	Case series	Local excision	3, Multiple	3	0/3 (NR)	2/3 Axillary contracture (66%)	NR	No
Lim et al. [37]	Case report	Local excision	1, Multiple	3	0/1	0/1	12 mos	Yes—biologics (pre-surgical)
Tchernev et al. [56]	Case report	Local excision	1, Axilla and groin	1, 2	NR	0/1	NR	Yes—antibiotics (pre surgery)
Samuel et al. [52]	Case report	Local excision	1, Breast	NR	0/1 (12 months)	0/1, NR	12 mos	No

Table 1 continued

Study	Study design	Treatment method	No. of patients, surgical site	Hurley stage	Recurrence rate (timeline)	Top 3 complications (patients with complication), timeline	Follow-up (months)	Adjuvant medical therapy (timeline)
Lozev et al. [39]	Case report	Local excision	1, Multiple	3	NR	NR	NR	Yes—antibiotics (pre-surgical)
Gibas et al. [24]	Case report	Local excision	1, Genital	3	0/1 (NR)	NR	2 yrs	No
Ritz et al. [48]	Retrospective	Wide local excision, incision and drainage, limited local excision	31, Multiple	NR	8/31 (15–35 months)	2/31: Postoperative bleeding (3%), deep vein thrombosis (3%), NR	Mean 72 mos (3–238 mos)	No
Worden et al. [64]	Retrospective	Local excision, incision and drainage	248, Multiple	1,2,3	NR	NR	Means 28 mos	Yes—biologics (pre- and post-surgical)
Source	Study design	Treatment method	No. of patients, surgical site	Hurley stage	Recurrence rate (timeline)	Complications (timeline)	Follow-up (months)	Adjuvant medical therapy (timeline)
Unroofing								
Haixiang et al. [26]	Prospective	Unroofing	8, Multiple	2, 3	0/8 (NR)	NR	3 mos	Yes—antibiotics (pre- and post-surgical)
Van Der Zee et al. [58]	Prospective	Unroofing	44, Multiple	1, 2	15/88 lesions (1.2–6.2 mos)	1/88: Postoperative bleeding (NR)	Median 34 mos	No

Table 1 continued

Source	Study design	Treatment method	No. of patients, surgical site	Hurley stage	Recurrence rate (timeline)	Complications (timeline)	Follow-up (months)	Adjuvant medical therapy (timeline)
Brown et al. [10]	Case series	Unroofing	4, Multiple	NR	NR	NR	NR	No
Lin et al. [38]	Case report	Unroofing	1, Gluteal	3	0/1 (NR)	0/1 (NR)	3 mos	No
Blok et al. [7]	Retrospective	Unroofing, STEEP	113, Multiple	1, 2, 3	106/482 Lesions (NR)	8/482 Lesions:		
hypergranulation tissue, wound infection, bleeding 14 – 87.5 mos	Median 43 mos	No						
Dahmen et al. [15]	Prospective	Unroofing and sinus tract excision	52, Multiple	2, 3	12/87 Lesions, 8/45 patients (median of 2.3 mos to recurrence)	7/96 Lesions: Postoperative bleeding, NR	Median 28 mos	No
Local excision and unroofing								
Kohorst et al. [35]	Retrospective	Local excision (n = 88), unroofing (n = 23)	111, Multiple	1, 2, 3	43/111 (1–2 yrs)	Overall rate NR: tightness of skin (40%),burning/numbness (34.5%), infection (23.4), NR	Median 21.7 yrs (4 mos–38 years)	No

Table 1 continued

Source	Study design	Treatment method	No. of patients, surgical site	Hurley stage	Recurrence rate (timeline)	Complications (timeline)	Follow-up (months)	Adjuvant medical therapy (timeline)
Kohorst et al. [36]	Retrospective	Local excision ($n = 405$), unroofing ($n = 168$), incision and drainage ($n = 17$)	590, Multiple	1, 2, 3	144/590 (NR)	15/590: Cellulitis (60%), skin graft loss (13%), wound dehiscence (6%), 30 days	Mean 632.9 days	
(1–6961 days)	No							
Vankeviciute et al. [59]	Retrospective	Local excision, unroofing, incision and drainage	26, NR	1, 2, 3	NR	9/26: Contracture (23%), anemia (9%),		
hypoalbuminemia (4%), NR	NR	No						
Grimstad et al. [25]	Retrospective	Unroofing, local excision, CO2 laser	149, Multiple	1, 2, 3	NR	57/149: Postoperative bleeding (29%), delayed wound healing (28%), stricture (14%), NR	4–9 mos	Yes–antibiotics (not specified)

NR not reported, Yrs years, Mos months

Table 2 Summary of recurrence and complication data across excision and unroofing studies

	Local excision	Unroofing
Number of studies	45	6
Recurrence rate (patients)	30% (554/1840)	14.5% (8/54)
Recurrence rate (lesions)	26% (98/371)	20% (133/657)
Complication rate (patients)	31% (409/1311)	0% (1 case study)
Complication rate (lesions)	26% (96/367)	12.5% (83/666)
Combined medical and surgical therapy		
Recurrence rate	13% (114/863)	0% (1 case study)
Complication rate	32% (150/457)	28.5% (8/28)

the mean follow-up period was an average of 40 months (median 21.2, IQR = 45.9, $n = 26$).

Excision: Recurrence

Eighty-two percent of studies reported the recurrence rate ($n = 37$). Seventeen percent of studies had defined criteria for recurrence of HS lesions ($n = 8$), such as “recurrence of a lesion within 5 mm of the operated area” or “an inflammatory boil immediately within the scar or within less than 0.5 cm from the scar.” None of the studies had identical recurrence criteria. Of the 37 articles that reported recurrence data after excision (representing 1840 patients), the recurrence rate was 30% ($n = 554$ patients). Three studies reported recurrence by lesion number, with 98 of 371 lesions recurring across these studies (26.4%) [21, 42, 13]. One study reported recurrence by Hurley stage as follows: 3 lesions recurred in Hurley 1 patients (8.1%), 12 lesions recurred in Hurley 2 patients (32.4%), and 22 lesions recurred in Hurley 3 patients (59.5%) [21]. Hurley stage was not found to be a significant risk for recurrence based on this data. Seven excision studies reported on recurrence by specific site on the body. Of the 62 patients who had recurrence reported by site, 25 (40%) were in the inguinal area, 17 (27%) axillary, 15 (24%) genital, 4 (6%) perineal, and 1 (1%) in the submammary area. Of the 311 lesions that had recurrence, 139 (45%) recurred in the axillary area, 62 (20%) inguinal, 36 (12%)

perineal, 10 (3%) submammary, and 3 (1%) genital.

Excision: Complications

Sixty percent of excision studies had specific data on the complication rate and type ($n = 27$). The complication rate calculated across studies was 31.2% (409 complications/1311 patients). The top three reported complications were infection ($n = 13$), postoperative bleeding ($n = 10$), and dehiscence ($n = 7$), and other reported complications included pain and contracture/stricture of scar, delayed wound healing, hypergranulation, decreased mobility, and hypertrophic scar. Three studies reported the complication rate by lesion number, with a 26.1% complication rate across lesions (96 of 367 lesions had a complication; 4 lesions were excluded from the complication analysis by one author [21]). The top three complications among these three studies included wound dehiscence ($n = 58$ lesions), infection ($n = 8$ lesions), and contracture ($n = 7$ lesions), and other reported complications included lymphedema and scar retraction. No excision studies reported on complication rate by anatomic site.

Excision Combined with Medical Therapy

Medical therapy alongside excision was reported in 12 studies (804 patients), with variable timing of perioperative administration of medical therapy. Thirty-three percent ($n = 4$) of

these articles were prospective studies, 42% ($n = 5$) were retrospective studies, and 25% ($n = 3$) were case series/case reports; 66% ($n = 8$) of these articles also reported data on postoperative complications, with a combined complication rate of 32% (150/457 patients). Of the studies that reported the postoperative recurrence rate in the setting of adjuvant medical therapy, the mean recurrence rate was 13% (114/863 patients). The majority ($n = 11$) of these studies reported on the use of antibiotics and biologic medications, with only two mentioning retinoids [47, 62]. Of these, one study discussed post-surgical use of biologics [18], four studies detailed use of biologics and antibiotics in the weeks or months preceding surgery [37, 39, 56, 63], three detailed antibiotic and/or biologic use both pre- and post-surgical intervention [41, 46, 64], one detailed intraoperative use of a gentamicin sponge [11], and two studies did not specify exact timing [47, 54]. Prens et al. [46] reported significantly longer healing times with the use of adalimumab (five patients) and infliximab (one patient) started several months before surgery, held for 1–2 weeks perioperatively, and then re-instated postoperatively within 1–2 weeks. Worden et al. [64] performed a multivariate logistic regression analysis to analyze factors that negatively impacted healing and found a significant negative impact on healing if immune modulating therapy (infliximab, adalimumab, prednisone) was not held at least 2 weeks before surgery. Only one study detailed the use of adjuvant biologic therapies, including infliximab (eight patients) and ustekinumab (three patients) initiated 2–3 weeks after closure and continued for an average of 10.5 months [18]. This did result in a significantly lower rate of local recurrence, time to recurrence, disease progression, and time to progression in the combined therapy group compared with the surgery only group [18]. There was no significant difference in wound healing between the combined therapy and surgery only group.

Unroofing

Six articles (11%) comprising 222 patients discussed unroofing in the treatment of HS: one was a retrospective study, three were prospective studies, and two were case series/case reports. See Table 2 for a summary of unroofing data. Hurley staging was provided in four studies ($n = 174$) (Hurley stage 1: 7.5%, $n = 13$; Hurley stage 2: 77.6%, $n = 135$; Hurley stage 3: 14.9%, $n = 26$). Only one unroofing study reported an average duration of disease, which was 14.9 ± 9.4 years (range 4–30) [26]. Two unroofing studies reported on the timing of unroofing following disease onset, reporting a mean of 18.3 years [26] and median of 12 years [7]. The mean follow-up period for the unroofing studies was 240 days (SD = 207, $n = 6$).

Unroofing: Recurrence

Five of the six unroofing studies reported recurrence rates [7, 15, 26, 38, 58]. Only two studies reported recurrence criteria, such as “an inflammatory nodule or abscess located within 2 cm of the scar” or self-reported “newly described disease adjacent to or within the previously operated area.” Recurrence across patients was reported as 14.5% in 3 studies (8 recurrences/54 patients) [15, 26, 38] and recurrence across lesions was reported in 3 studies at a rate of 20% (133 recurrences/657 lesions) [7, 15, 58]. Time to recurrence was reported by only one study and ranged from 14 months to 87.5 months from the operative date [7]. No unroofing studies reported on recurrence by anatomic site.

Unroofing: Complications

Four unroofing studies reported complication data; one was a case report [38], and three reported complication rate across lesions [7, 15, 58]. A case report of one patient reported no complications [38]. There was a 12.5% complication rate across unroofed lesions (83 complications/666 lesions). The top three reported complications included postoperative bleeding ($n = 3$), hypergranulation tissue

($n = 1$), and wound infection ($n = 1$). No unroofing studies reported on complication by anatomic site.

Unroofing Combined with Medical Therapy

Data on the use of medical therapy alongside unroofing were reported in only one study including 8 patients with 28 lesions [26]. Intravenous azithromycin and oral metronidazole were used for 5–7 days prior to unroofing, sinuses were washed daily with saline that contained gentamicin, and intravenous azithromycin, oral metronidazole, and levofloxacin were used for 5–7 days postoperatively; 82.1% (24/28 lesions) showed improvement, and there were no recurrences within the 3-month follow-up period; 28.5% of lesions had complications (8 complications/28 lesions), and the three most common were pain ($n = 4$), oozing ($n = 3$), and fever ($n = 2$).

Excision and Unroofing (Combined Data)

Four studies reported data on excision and unroofing collectively in retrospective studies, representing 876 patients [25, 35, 36, 59]. Two studies reported grouped recurrence rates across multiple procedures (e.g., excision, unroofing) and did not specify intervention [35, 36]. Kohorst et al. [36] reported a grouped recurrence rate of 24.4% for a group of 590 patients who underwent excision, unroofing, and incision and drainage, whereas Kohorst et al. [35] had a patient-reported recurrence rate of 40.2% for a group of 111 patients who underwent excision, unroofing, or curettage. For the group of 111 patients, unroofing and excision had similar recurrence risks, and neither Hurley II nor III patients had an increased risk of postoperative recurrence compared with Hurley I patients.

Three of these studies specified postoperative complications, with an overall rate of 4% (81 complications/765 patients) [25, 36, 59]. The top complication was infection ($n = 2$). Each additional complication was reported once and included wound dehiscence, bleeding,

contracture, skin graft loss, delayed wound healing, anemia, stricture, tightness of skin, burning/numbness of skin, and hypoalbuminemia.

Overall Recurrence and Complication Rate Results

Recurrence rates at both the patient and lesion level were both significantly associated with type of procedure. Thirty percent of patients treated with excision had a recurrence compared with 15% of those treated with unroofing ($p = 0.015$). Similarly, 26% of lesions recurred after excision, compared with 20% after unroofing ($p = 0.02$). Complication rates at the lesion level were also significantly associated with procedure, with rates after excision more than double those after roofing (26% vs. 12%, $p < 0.001$). The complication rate after combined medical and surgical therapy did not differ between procedures. Because no patients were either reported to have complications after unroofing or recurrences after unroofing combined with medical therapy, comparisons were not possible in these categories.

DISCUSSION

This review demonstrates that excision and unroofing significantly differ in recurrence and complication rates when examined by both patients and lesions. The recurrence rate of unroofing was found to be half that of excision across patients and slightly lower across unroofed lesions. Unroofing also has a significantly lower complication rate than excision. Unroofed lesions have half the complication rate of excised lesions, though complications such as bleeding and pain are similar across the two modalities.

The existing data also suggest that recurrence rates may be lower in surgical intervention when used alongside medical therapy. The recurrence rate when excision was combined with medical treatments such as antibiotics and biologics was less than half that of surgery alone and was the lowest recurrence rate found in this review. Because only one unroofing study

described a combined medical and surgical approach with antibiotics, a comparison of excision and unroofing was not possible. Despite the lower recurrence rate for excision combined with medical therapy, studies reported concerns about poor wound healing with immunomodulating interventions such as biologics or systemic steroids. The complication rate for the excision with the medical therapy group was equivalent to the rate of excision alone, but significantly longer healing time was noted with the use of biologic therapy including adalimumab and infliximab. The exception was one study [18] that used only adjuvant biologic therapy initiated several weeks after closure, where no difference in wound healing was found.

This review highlights that both excision and unroofing may play important roles in the current management of HS. The existing data suggest that either approach can be successfully employed based on factors such as disease severity, extent of involvement, clinical setting, provider comfort, and available resources. The lower recurrence and complication rates for unroofing may be particularly relevant to any practitioner looking for an effective and fast technique, as unroofing has been noted for its tissue-saving approach, suitability as an office procedure that rarely requires general anesthesia, and high patient satisfaction rate [58]. These data also begin to suggest that combining medical therapies with surgical intervention may improve surgical outcomes, although the ideal timing of these medical therapies and balancing them with wound healing concerns remain unclear.

The North American HS guidelines [3] and HS ALLIANCE Zouboulis et al. [66] make recommendations for surgical intervention based on lesion type and Hurley stage. The Hurley staging system is a widely used clinical tool that was developed to help guide surgical management by classifying patients according to physical signs of HS. Hurley I has traditionally been characterized as a non-surgical state that is medically managed, with single or multiple isolated nodules or abscesses without dermal tunnels or scarring. Hurley II denotes recurrent abscesses and single or multiple widely

separated lesions with tunnel formation and scarring. Hurley III has diffuse involvement across a regional area and multiple extensive interconnected tunnels, abscesses, and scarring. A traditional treatment model dictates medical therapy only for Hurley I, with surgical intervention reserved for Hurley II and III for disease that is uncontrolled by medical therapy. This review found that Hurley staging was inconsistently reported in existing studies both pre- and postoperatively, making it impossible to compare outcomes across Hurley stage for each type of procedure. Moving forward, specifying the stage of HS in studies of surgical intervention for HS both pre- and postoperatively may provide important context for results and will be instrumental in determining the efficacy of specific interventions for defined types of HS lesions and optimizing surgical intervention for HS.

There is a growing body of literature on combination therapy with medical treatments and surgical intervention. In our review of the limited existing data, we found a lower recurrence rate for excision combined with medical therapy compared with the recurrence rate for excision alone, and the complication rate was comparable. Comparison of recurrence for unroofing with and without medical therapy was limited by the limited number of combination therapy unroofing studies (only one study of eight patients). A higher complication rate was seen in this study compared with unroofing without medical therapy, but this comparison is highly limited given this is a small number of patients in a single study. Antibiotics and biologic therapy were the two most common adjuvant therapies in this review. Our findings align with other reports in the literature of using medical therapy alongside surgery, which the North American HS guidelines deemed generally beneficial with minimal risk of increased postoperative complications [3]. The Safety and Efficacy of Humira (Adalimumab) for HS Peri-Surgically study (SHARPS study), which assessed the role of adalimumab in combination with HS surgery by randomizing participants to receive placebo or adalimumab before and after surgery, will be a helpful addition to understanding the extent to

which biologic therapy might affect surgical outcomes in the setting of severe HS [51]. [“Safety and Efficacy of Humira (Adalimumab) for Hidradenitis Suppurativa (HS) Peri-Surgically (SHARPS Study)—Full Text View—ClinicalTrials.gov,” n.d.]. Similar trials and prospective controlled studies are needed to definitively compare recurrence and complication rates between surgery alone versus combination therapy and to determine optimal medical intervention alongside surgery.

Several reviewed studies and other published reviews also comment on the promising nature of early intervention based on small prospective and larger retrospective studies, with a potentially higher cure rate for surgical intervention at an early Hurley stage compared with later Hurley stages [1, 32, 50, 53]. Based on these studies, excision and unroofing may be particularly useful for focal areas of disease. Meaningful comparison of disease duration prior to excision versus unroofing was limited by the very small number of unroofing studies that reported this information. The potential impact of early surgical intervention with medical therapy is not definitively known, but our increasing comprehension of HS pathophysiology reinforces the idea that structural alteration of the skin occurs quickly and often aggressively. Thus, this review provides data on two surgical interventions that can play an early role for practitioners interested in this approach.

This review is limited by low-quality studies with small sample size, uncontrolled retrospective and prospective studies, and case reports that did not control for confounding variables. Data on duration of follow-up, medical comorbidities, specific anatomic region, size of excision, and type of reconstruction were not uniformly collected across studies, and outcome rates are variably reported, with some studies reporting data based on number of patients and others reporting data based on number of lesions. Recurrence and complication data by specific site on the body were scarce, reported in only a small number of excision studies and no unroofing studies. The number of studies included in this review is limited, particularly for the topic of unroofing. As a result, it is difficult to provide a true definitive comparison

between unroofing and excision to guide treatment choices. Finally, although recurrence is used as a primary outcome, uniform definitions for recurrence and remission in HS do not exist, making it difficult to compare efficacy across studies [57]. Defining fundamental outcomes terminology and outcome measures for HS is currently ongoing through the International Dermatology Outcome Measures (IDEOM) initiative [19].

CONCLUSIONS

HS is a disease that has marked variability in its presentation and progression, requiring both medical and surgical management that is tailored to the type of HS lesion. Definitive conclusions about recurrence and complication rates for excision and unroofing are limited by the quality of the current literature. However, based on available data, recurrence and complication rates for unroofing appear to be lower than for excision. Though preliminary, it also appears that continuing medical therapy in the perioperative period may be helpful in terms of limiting recurrence, though concerns about delayed wound healing with biologic therapy have been reported. Further systematic prospective studies are needed to better compare complication and recurrence rates across these procedures in HS, especially in the context of concomitant medical therapy.

ACKNOWLEDGEMENTS

Funding. No funding or sponsorship was received for this study or publication of this article.

Authorship. All named authors meet the International Committee of Medical Journal Editors (ICMJE) criteria for authorship for this article, take responsibility for the integrity of the work as a whole, and have given their approval for this version to be published.

Disclosures. Drew K. Saylor and Nicholas D. Brownstone have nothing to disclose. Haley B. Naik has received grant support from AbbVie, consulting fees from 23andme and Janssen, and is a board member of the Hidradenitis Suppurativa Foundation (HSF); however, there is nothing to disclose with the present study.

Compliance with Ethics Guidelines. This article is based on previously conducted studies and does not contain any studies with human participants or animals performed by any of the authors.

Data Availability. The datasets during and/or analyzed during the current study are available from the corresponding author on reasonable request.

Open Access. This article is licensed under a Creative Commons Attribution-NonCommercial 4.0 International License, which permits any non-commercial use, sharing, adaptation, distribution and reproduction in any medium or format, as long as you give appropriate credit to the original author(s) and the source, provide a link to the Creative Commons licence, and indicate if changes were made. The images or other third party material in this article are included in the article's Creative Commons licence, unless indicated otherwise in a credit line to the material. If material is not included in the article's Creative Commons licence and your intended use is not permitted by statutory regulation or exceeds the permitted use, you will need to obtain permission directly from the copyright holder. To view a copy of this licence, visit <http://creativecommons.org/licenses/by-nc/4.0/>.

REFERENCES

- Aksakal AB, Adışen E. Hidradenitis suppurativa: importance of early treatment; efficient treatment with electrosurgery. *Dermatol Surg.* 2008;34(2): 228–31. <https://doi.org/10.1111/j.1524-4725.2007.34042.x>.
- Alharbi Z, Kauczok J, Pallua N. A review of wide surgical excision of hidradenitis suppurativa. *BMC Dermatol.* 2012;12:9. <https://doi.org/10.1186/1471-5945-12-9>.
- Alikhan A, Sayed C, Alavi A, Alhusayen R, Brassard A, Burkhart C, Poulin Y. North American clinical management guidelines for hidradenitis suppurativa: A publication from the United States and Canadian Hidradenitis Suppurativa Foundations: Part I: diagnosis, evaluation, and the use of complementary and procedural management. *J Am Acad Dermatol.* 2019;81(1):76–90. <https://doi.org/10.1016/j.jaad.2019.02.067>.
- Ather S, Chan DSY, Leaper DJ, Harding KG. Surgical treatment of hidradenitis suppurativa: Case series and review of the literature. *Int Wound J.* 2006;3(3): 159–69. <https://doi.org/10.1111/j.1742-481X.2006.00235.x>.
- Balik E, Eren T, Bulut T, Büyükuncu Y, Bugra D, Yamaner S. Surgical approach to extensive hidradenitis suppurativa in the perineal/perianal and gluteal regions. *World J Surg.* 2009;33(3): 481–7. <https://doi.org/10.1007/s00268-008-9845-9>.
- Bieniek A, Matusiak L, Okulewicz-Gojlik D, Szepietowski JC. Surgical treatment of hidradenitis suppurativa: Experiences and recommendations. *Dermatol Surg Off Publ Am Soc Dermatol Surg.* 2010;36(12), 1998–2004. <https://doi.org/10.1111/j.1524-4725.2010.01763.x>.
- Blok JL, Boersma M, Terra JB, Spoo JR, Leeman FWJ, van den Heuvel ER, Horváth B. Surgery under general anaesthesia in severe hidradenitis suppurativa: a study of 363 primary operations in 113 patients. *J Eur Acad Dermatol Venereol.* 2015;29(8):1590–7. <https://doi.org/10.1111/jdv.12952>.
- Bocchini SF, Habr-Gama A, Kiss DR, Imperiale AR, Araujo SEA. Gluteal and perianal hidradenitis suppurativa: Surgical treatment by wide excision. *Dis Colon Rectum.* 2003;46(7):944–9. <https://doi.org/10.1007/s10350-004-6691-1>.
- Bohn J, Svensson H. Surgical treatment of hidradenitis suppurativa. *Scand J Plast Reconstr Surg Hand Surg.* 2001;35(3):305–9. <https://doi.org/10.1080/028443101750523230>.
- Brown SC, Kazzazi N, Lord PH. Surgical treatment of perineal hidradenitis suppurativa with special reference to recognition of the perianal form. *Br J Surg.* 1986;73(12):978–80. <https://doi.org/10.1002/bjs.1800731210>.
- Buimer MG, Ankersmit MFP, Wobbes T, Klinkenbijl JHG. Surgical treatment of hidradenitis suppurativa with gentamicin sulfate: a prospective randomized

- study. *Dermatol Surg*. 2008;34(2):224–7. <https://doi.org/10.1111/j.1524-4725.2007.34041.x>.
12. Burney RE. 35-Year experience with surgical treatment of hidradenitis suppurativa. *World J Surg*. 2017;41(11):2723–30. <https://doi.org/10.1007/s00268-017-4091-7>.
 13. Büyükaşık O, Hasdemir AO, Kahramansoy N, Çöl C, Erkol H. Surgical approach to extensive hidradenitis suppurativa. *Dermatol Surg Off Publ Am Soc Dermatol Surg*. 2011;37(6):835–42. <https://doi.org/10.1111/j.1524-4725.2011.01961.x>.
 14. Chen ML, Odom B, Santucci RA. Surgical management of genitoperineal hidradenitis suppurativa in men. *Urology*. 2014;83(6):1412–7. <https://doi.org/10.1016/j.urology.2014.01.011>.
 15. Dahmen RA, Gkalpakiotis S, Mardesicova L, Arenberger P, Arenbergerova M. Deroofing followed by thorough sinus tract excision: A modified surgical approach for hidradenitis suppurativa. *J Der Deutschen Dermatologischen Gesellschaft*. 2019;17(7):698–702. <https://doi.org/10.1111/ddg.13875>.
 16. Danby FW, Hazen PG, Boer J. New and traditional surgical approaches to hidradenitis suppurativa. *J Am Acad Dermatol*. 2015;73(5 Suppl 1):S62–65. <https://doi.org/10.1016/j.jaad.2015.07.043>.
 17. Deckers IE, Dahi Y, van der Zee HH, Prens EP. Hidradenitis suppurativa treated with wide excision and second intention healing: A meaningful local cure rate after 253 procedures. *J Eur Acad of Dermatol Venereol JEADV*. 2018;32(3):459–62. <https://doi.org/10.1111/jdv.14770>.
 18. DeFazio MV, Economides JM, King KS, Han KD, Shanmugam VK, Attinger CE, Evans KK. Outcomes after combined radical resection and targeted biologic therapy for the management of recalcitrant hidradenitis suppurativa. *Ann Plast Surg*. 2016;77(2):217–22. <https://doi.org/10.1097/SAP.0000000000000584>.
 19. Elman SA, Merola JF, Armstrong AW, Duffin KC, Latella J, Garg A, Gottlieb AB. The International Dermatology Outcome Measures (IDEOM) initiative: a review and update. *J Drugs Dermatol*. 2017;16(2):119–24.
 20. Endo Y, Tamura A, Ishikawa O, Miyachi Y. Perianal hidradenitis suppurativa: Early surgical treatment gives good results in chronic or recurrent cases. *Br J Dermatol*. 1998;139(5):906–10. <https://doi.org/10.1046/j.1365-2133.1998.02524.x>.
 21. Fertitta L, Hotz C, Wolkenstein P, Méningaud JP, Sawan D, Hersant B, Sbidian E. Efficacy and satisfaction of surgical treatment for hidradenitis suppurativa. *J Eur Acad Dermatol Venereol*. 2019. <https://doi.org/10.1111/jdv.16135>.
 22. Gatěk J, Dudesek B, Krátká A, Vrána D, Duben J. Severe hidradenitis suppurativa. *Rozhl V Chir Mesci Ceskoslov Chirurגיעke Spol*. 2014;93(9):468–71.
 23. Ge S, Orbay H, Silverman RP, Rasko YM. Negative pressure wound therapy with instillation and dwell time in the surgical management of severe hidradenitis suppurativa. *Cureus*. 2018;10(9):e3319. <https://doi.org/10.7759/cureus.3319>.
 24. Gibas A, Matuszewski M, Michajłowski I, Krajka K. Acne inversa of the scrotum and penis – aggressive urological treatment. *Cent Eur J Urol*. 2012;65(3):167–9. <https://doi.org/10.5173/cej.2012.03.art15>.
 25. Grimstad Ø, Tzellos T, Dufour DN, Bremnes Ø, Skoie IM, Snekvik I, Ingvarsson G. Evaluation of medical and surgical treatments for hidradenitis suppurativa using real-life data from the Scandinavian registry (HISREG). *J Eur Acad Dermatol Venereol*. 2019;33(6):1164–71. <https://doi.org/10.1111/jdv.15353>.
 26. Haoxiang X, Chengrang L, Baoxi W, Xinfeng W. Modified Abscess Drainage in Treatment of Eight Cases with Hidradenitis Suppurativa in China. *Dermatol Surg*. 2013;39(5):779–83. <https://doi.org/10.1111/dsu.12110>.
 27. Harrison BJ, Mudge M, Hughes LE. Recurrence after surgical treatment of hidradenitis suppurativa. *Br Med J (Clin Res Ed)*. 1987;294(6570):487–9. <https://doi.org/10.1136/bmj.294.6570.487>.
 28. Humphries LS, Kueberuwa E, Beederman M, Gottlieb LJ. Wide excision and healing by secondary intent for the surgical treatment of hidradenitis suppurativa: A single-center experience. *J Plast, Reconstr Aesthet Surg JPRAS*. 2016;69(4):554–66. <https://doi.org/10.1016/j.bjps.2015.12.004>.
 29. Jafari SM, Knüsel E, Cazzaniga S, Hunger RE. A retrospective cohort study on patients with hidradenitis suppurativa. *Dermatology*. 2018;234(1–2):71–8. <https://doi.org/10.1159/000488344>.
 30. Janse I, Bieniek A, Horváth B, Matusiak Ł. Surgical procedures in hidradenitis suppurativa. *Dermatol Clin*. 2016;34(1):97–109. <https://doi.org/10.1016/j.det.2015.08.007>.
 31. Jemec GB. Effect of localized surgical excisions in hidradenitis suppurativa. *J Am Acad Dermatol*. 1988;18(5 Pt 1):1103–7. [https://doi.org/10.1016/s0190-9622\(88\)70113-9](https://doi.org/10.1016/s0190-9622(88)70113-9).

32. Jemec GBE. Hidradenitis suppurativa. *J Cutan Med Surg.* 2003;7(1):47–56. <https://doi.org/10.1007/s10227-002-2104-z>.
33. Kagan RJ, Yakuboff KP, Warner P, Warden GD. Surgical treatment of hidradenitis suppurativa: A 10-year experience. *Surgery.* 2005;138(4):734–40. <https://doi.org/10.1016/j.surg.2005.06.053>.
34. Kofler L, Schweinzer K, Heister M, Kohler M, Breuninger H, Häfner H-M. Surgical treatment of hidradenitis suppurativa: An analysis of postoperative outcome, cosmetic results and quality of life in 255 patients. *J Eur Acad of Dermatol Venereol JEADV.* 2018;32(9):1570–4. <https://doi.org/10.1111/jdv.14892>.
35. Kohorst JJ, Baum CL, Otley CC, Roenigk RK, Pemberton JH, Dozois EJ, Davis MDP. Patient satisfaction and quality of life following surgery for hidradenitis suppurativa. *Dermatol Surg.* 2017;43(1):125–33. <https://doi.org/10.1097/DSS.0000000000000942>.
36. Kohorst JJ, Baum CL, Otley CC, Roenigk RK, Schenck LA, Pemberton JH, Davis MDP. Surgical management of hidradenitis suppurativa: outcomes of 590 consecutive patients. *Dermatol Surg.* 2016;42(9):1030–40. <https://doi.org/10.1097/DSS.0000000000000806>.
37. Lim SYD, Cheong EC, Oon HH. Management of severe hidradenitis suppurativa with biologic therapy and wide excision. *Arch Plast Surg.* 2019;46(3):272–6. <https://doi.org/10.5999/aps.2018.00339>.
38. Lin C-H, Chang K-P, Huang S-H. Deroofing: an effective method for treating chronic diffuse hidradenitis suppurativa. *Dermatol Surg.* 2016;42(2):273–5. <https://doi.org/10.1097/DSS.0000000000000609>.
39. Lozev I, Pidakev I, Lotti T, Wollina U, Gianfaldoni S, Lotti J, Tchernev G. Severe acne inversa—dermatological approach in a bulgarian patient. *Open Access Maced J Med Sci.* 2017;5(4):561–3. <https://doi.org/10.3889/oamjms.2017.144>.
40. Menderes A, Sunay O, Vayvada H, Yilmaz M. Surgical management of hidradenitis suppurativa. *Int J Med Sci.* 2010;7(4):240–7.
41. Nesmith RB, Merkel KL, Mast BA. Radical surgical resection combined with lymphadenectomy-directed antimicrobial therapy yielding cure of severe axillary hidradenitis. *Ann Plast Surg.* 2013;70(5):538–41. <https://doi.org/10.1097/SAP.0b013e31828ea7cb>.
42. Ngaage LM, Wu Y, Ge S, Gebran S, Liang F, Rada EM, Rasko YM. Factors influencing the local cure rate of hidradenitis suppurativa following wide local excision. *Int Wound J.* 2020;17(1):117–23. <https://doi.org/10.1111/iwj.13241>.
43. Nweze N, Parsikia A, Ahuja R, Joshi ART. Axillary hidradenitis: Risk factors for recurrence after surgical excision in 214 patients. *Am Surg.* 2018;84(3):422–7.
44. Posch C, Monshi B, Quint T, Vujic I, Lilgenau N, Rappersberger K. The role of wide local excision for the treatment of severe hidradenitis suppurativa (Hurley grade III): Retrospective analysis of 74 patients. *J Am Acad Dermatol.* 2017;77(1):123–9.e5. <https://doi.org/10.1016/j.jaad.2017.01.055>.
45. Prens E, Deckers I. Pathophysiology of hidradenitis suppurativa: An update. *J Am Acad Dermatol.* 2015;73(5 Suppl 1):S8–11. <https://doi.org/10.1016/j.jaad.2015.07.045>.
46. Prens LM, Huizinga J, Janse IC, Horváth B. Surgical outcomes and the impact of major surgery on quality of life, activity impairment and sexual health in hidradenitis suppurativa patients: A prospective single centre study. *J Eur Acad Dermatol Venereol.* 2019;33(10):1941–6. <https://doi.org/10.1111/jdv.15706>.
47. Puri N, Talwar A. A study on the management of hidradenitis suppurativa with retinoids and surgical excision. *Indian J Dermatol.* 2011;56(6):650–1. <https://doi.org/10.4103/0019-5154.91821>.
48. Ritz JP, Runkel N, Haier J, Buhr HJ. Extent of surgery and recurrence rate of hidradenitis suppurativa. *Int J Colorectal Disase.* 1998;13(4):164–8. <https://doi.org/10.1007/s003840050159>.
49. Romanowski KS, Fagin A, Werling B, Kass G, Liao J, Granchi T, Kealey GP, Wibbenmeyer L. Surgical management of hidradenitis suppurativa: A 14-Year retrospective review of 98 consecutive patients. *J Burn Care Res Off Publ Am Burn Assoc.* 2017;38(6):365–70. <https://doi.org/10.1097/BCR.0000000000000531>.
50. Rompel R, Petres J. Long-term results of wide surgical excision in 106 patients with hidradenitis suppurativa. *Dermatol Surg.* 2000;26(7):638–43. <https://doi.org/10.1046/j.1524-4725.2000.00043.x>.
51. Safety and Efficacy of Humira (Adalimumab) for Hidradenitis Suppurativa (HS) Peri-Surgically (SHARPS Study)—Full Text View—ClinicalTrials.gov. (n.d.). <https://clinicaltrials.gov/ct2/show/NCT02808975>. Accessed 9 Feb 2020.
52. Samuel S, Tremelling A, Murray M. Presentation and surgical management of hidradenitis suppurativa of the breast during pregnancy: A case report. *Int J Surg Case Rep.* 2018;51:21–4. <https://doi.org/10.1016/j.ijscr.2018.08.013>.

53. Shah N. Hidradenitis suppurativa: a treatment challenge. *Am Fam Physician*. 2005;72(8):1547–52.
54. Shanmugam VK, Mulani S, McNish S, Harris S, Buescher T, Amdur R. Longitudinal observational study of hidradenitis suppurativa: Impact of surgical intervention with adjunctive biologic therapy. *Int J Dermatol*. 2018;57(1):62–9. <https://doi.org/10.1111/ijd.13798>.
55. Soldin MG, Tulley P, Kaplan H, Hudson DA, Grobbelaar AO. Chronic axillary hidradenitis—The efficacy of wide excision and flap coverage. *Br J Plast Surg*. 2000;53(5):434–6. <https://doi.org/10.1054/bjps.1999.3285>.
56. Tchernev G, Temelkova I. Hidradenitis Suppurativa (Hurley I/II): serial excisions with primary wound closure under local anesthesia as most adequate treatment approach. *Open Access Maced J Med Sci*. 2019;7(3):400–2. <https://doi.org/10.3889/oamjms.2019.148>.
57. Thorlacius L, Garg A, Ingram JR, Villumsen B, Theut Riis P, Gottlieb AB, Jemec GBE. Towards global consensus on core outcomes for hidradenitis suppurativa research: an update from the HISTORIC consensus meetings I and II. *Br J Dermatol*. 2018;178(3):715–21. <https://doi.org/10.1111/bjd.16093>.
58. van der Zee HH, Prens EP, Boer J. Deroofing: A tissue-saving surgical technique for the treatment of mild to moderate hidradenitis suppurativa lesions. *J Am Acad Dermatol*. 2010;63(3):475–80. <https://doi.org/10.1016/j.jaad.2009.12.018>.
59. Vankeviciute RA, Polozovaite B, Trapikas J, Raudonis T, Grigaitiene J, Bylaite-Bucinskiene M. A 12-year experience of hidradenitis suppurativa management. *Adv Skin Wound Care*. 2019;32(1):1–7. <https://doi.org/10.1097/01.ASW.0000549611.06727.52>.
60. van Rappard DC, Mooij JE, Mekkes JR. Mild to moderate hidradenitis suppurativa treated with local excision and primary closure. *J Eur Acad of Dermatol Venereol JEADV*. 2012;26(7):898–902. <https://doi.org/10.1111/j.1468-3083.2011.04203.x>.
61. Walter A-C, Meissner M, Kaufmann R, Valesky E, Pinter A. Hidradenitis suppurativa after radical surgery-long-term follow-up for recurrences and associated factors. *Dermatol Surg Off Publ Am Soc Dermatol Surg*. 2018;44(10):1323–31. <https://doi.org/10.1097/DSS.0000000000001668>.
62. Wollina U, Langner D, Heinig B, Nowak A. Comorbidities, treatment, and outcome in severe anogenital inverse acne (hidradenitis suppurativa): A 15-year single center report. *Int J Dermatol*. 2017;56(1):109–15. <https://doi.org/10.1111/ijd.13393>.
63. Wollina U, Tilp M, Meseg A, Schönlebe J, Heinig B, Nowak A. Management of severe anogenital acne inversa (hidradenitis suppurativa). *Dermatol Surg*. 2012;38(1):110–7. <https://doi.org/10.1111/j.1524-4725.2011.02157.x>.
64. Worden A, Yoho DJ, Houin H, Moquin K, Hamzavi I, Saab I, Siddiqui A. Factors Affecting Healing in the Treatment of Hidradenitis Suppurativa. *Ann Plast Surg*. 2019. <https://doi.org/10.1097/SAP.0000000000002105>.
65. Yamashita Y, Hashimoto I, Matsuo S, Abe Y, Ishida S, Nakanishi H. Two-stage surgery for hidradenitis suppurativa: Staged artificial dermis and skin grafting. *Dermatol Surg Off Publ Am Soc Dermatol Surg*. 2014;40(2):110–5. <https://doi.org/10.1111/dsu.12400>.
66. Zouboulis CC, Bechara FG, Dickinson-Blok JL, Gulliver W, Horváth B, Hughes R, Kimball AB, Kirby B, Martorell A, Podda M, Prens EP, Ring HC, Tzellos T, van der Zee HH, van Straalen KR, Vossen ARJV, Jemec GBE. Hidradenitis suppurativa/acne inversa: A practical framework for treatment optimization - systematic review and recommendations from the HS ALLIANCE working group. *J Eur Acad of Dermatol Venereol JEADV*. 2019;33(1):19–31. <https://doi.org/10.1111/jdv.15233>.