

Available online at www.sciencedirect.com

ScienceDirect

journal homepage: www.elsevier.com/locate/radcr

Case Report

Transplant uretero-inguinal hernia resulting in urosepsis

Moustafa Abou Areda, Christopher R. Bailey*, Daniel O'Mara, Clifford R. Weiss

Division of Vascular and Interventional Radiology, The Johns Hopkins Hospital, Baltimore, MD, USA

ARTICLE INFO

Article history:

Received 2 August 2018

Revised 3 September 2018

Accepted 4 September 2018

Available online 3 October 2018

Keywords:

Uretero-inguinal hernia

Hydroureteronephrosis

Nephrostomy

Nonvascular intervention

ABSTRACT

Uretero-inguinal hernias are rare and can be difficult to diagnose. We present a case of a rare transplant kidney uretero-inguinal hernia. An 81-year-old male presented with urosepsis and was found to have an obstructed transplanted kidney secondary to herniation of the ureter into an inguinal hernia. The patient required interventional radiology decompression of the urinary system with a percutaneous nephrostomy tube. In this case, the patient's uretero-inguinal hernia was the extraperitoneal subtype allowing the diagnosis to be made easily on computed tomography imaging of the abdomen and pelvis which facilitated rapid treatment.

© 2018 The Authors. Published by Elsevier Inc. on behalf of University of Washington.

This is an open access article under the CC BY-NC-ND license.

(<http://creativecommons.org/licenses/by-nc-nd/4.0/>)

Introduction

Inguinal hernias are common in the United States; with an approximated 800,000 inguinal hernia repairs performed each year [1]. Inguinal hernias make up 75% of all abdominal wall hernias with two-thirds being indirect [1,2]. About 90% of all inguinal hernias occur in men with a broad age distribution [1-3]. Barring strangulated hernias, patients typically choose to wait and have an elective repair performed at a time of convenience [1-4]. Uretero-inguinal hernias are rare and are especially uncommon in patients with nontransplanted kidneys [5].

Diagnosis of the condition is particularly difficult outside of the operating room (OR), with the vast majority of cases be-

ing discovered incidentally during surgical repair of the hernia [1]. This often-unrecognized complication puts patients at high risk for ureteral damage during hernia repair [1]. We present a case of an obstructed transplanted kidney secondary to herniation of the ureter into an inguinal hernia resulting in urosepsis.

Case report

This case report is Institutional Review Board exempt.

An 81-year-old male with a history of end-stage renal disease status post kidney transplant presented with weakness, decreased urine output, and fever. Vital signs were significant for a temperature of 38.9°C, tachycardia to the 130 sec-

Acknowledgments: Dr. Weiss has received research grants from Siemens Healthcare, Merit Medical, and BTG, and he is a consultant for BTG and Medtronic.

Competing Interests: The authors have declared that no competing interests exist.

* Corresponding author.

E-mail address: cbaile19@jhmi.edu (C.R. Bailey).

<https://doi.org/10.1016/j.radcr.2018.09.002>

1930-0433/© 2018 The Authors. Published by Elsevier Inc. on behalf of University of Washington. This is an open access article under the CC BY-NC-ND license. (<http://creativecommons.org/licenses/by-nc-nd/4.0/>)

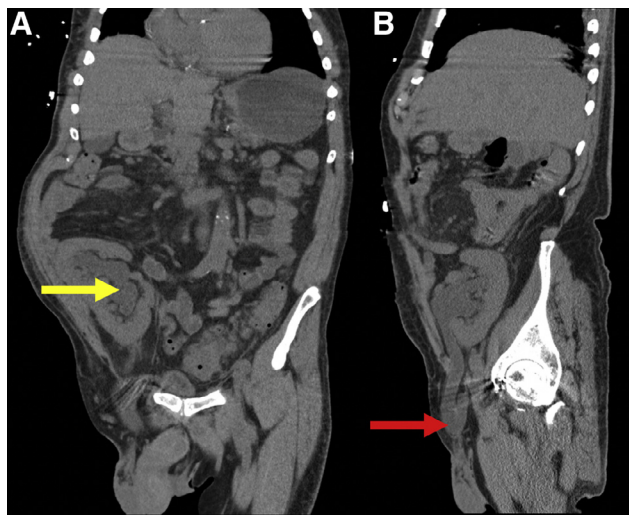


Fig. 1 – Coronal (A) and sagittal (B) CT without contrast demonstrating moderate to marked hydroureteronephrosis of the right lower quadrant transplant kidney secondary to herniation of ureter into a right inguinal hernia. The yellow arrow points to the dilated renal collecting system. The red arrow points to the dilated transplant ureter within the right inguinal hernia.

onds, and blood pressures in the 90s/60s. His initial laboratory workup revealed a white blood cell count of 14,000 cell/mm³, a creatinine of 3 mg/dL (baseline 1.4), and urinalysis findings compatible with a urinary tract infection. Blood cultures grew *Streptococcus viridans*, and urine culture grew *Acinetobacter anitrat*. Empiric broad-spectrum antibiotics and fluid resuscitation were initiated. Physical examination revealed a small, nontender, right-sided inguinal hernia. The hernia was palpable on exam, and easily reducible without evidence of incarceration. As such, no surgical intervention was indicated at the time.

A contrast enhanced computed tomography (CT) scan of the abdomen and pelvis revealed hydroureteronephrosis of the right lower quadrant transplant kidney secondary to obstruction of the right ureter within a right inguinal hernia (Fig. 1A and B). No bowel was found to be associated with the herniated ureter. Interventional radiology was consulted for urgent nephrostomy tube placement. Decompression was performed with nephrostomy tube placement (Fig. 2A and C). The procedure was performed successfully without complication.

Upon time of discharge, the patient's creatinine had returned to baseline with the patient making adequate urine. The patient was ultimately discharged a week later, in good condition with plans for definitive surgical management.

Discussion

Ureteral herniation into an inguinal hernia is very rare, with only 140 documented cases worldwide up to the year 2004 [6–12]. Ureteric hernias can be classified as inguinal, femoral, thoracic, and parailiac [13–16]. Previous studies have

demonstrated that 42% of cases are inguinoscrotal in nature [13,15]. Ureteric hernias can also be cited as spontaneous, postoperative, or as a complication of renal transplant surgery [13,14]. There are 2 anatomic presentations of ureteral herniation that have been reported in the literature: paraperitoneal and extraperitoneal herniations [5,6,14,17–19]. The vast majority of cases are of the paraperitoneal type which accounts for 80% of them [5,6]. This anatomic variant is defined by a ureter that is posteriorly attached to an indirect peritoneal hernia sac resulting in it sliding beside it [5]. This type of hernia is most commonly associated with the herniation of other organs, often the colon [5,6].

Extraperitoneal hernias are much less common, accounting for 20% of the cases, and are characterized by ureteral herniation without an associated peritoneal hernia sac [5,10,20–23]. In this type, the ureter either herniates alone or alongside retroperitoneal fat [6,10]. It is important to note that while paraperitoneal hernias are believed to be acquired, extraperitoneal hernias are thought to be secondary to congenital defects [6,10,20–23]. More specifically, extraperitoneal hernias are believed to arise from abnormal development of the ureter [5,10]. It is hypothesized that inability of the ureteric bud to detach from the mesonephric duct results in the ureter migrating inferiorly as the duct descends into the scrotum [5,10].

In our case, the patient exhibited the less common extraperitoneal anatomic variant. Unlike paraperitoneal hernias, which are more difficult to identify preoperatively, extraperitoneal hernias are more easily diagnosed as they typically present with urinary symptoms [5,24]. Our patient presented with urosepsis and evidence of hernia on physical exam. The CT scan ordered, readily identified the herniated ureter prompting decompression with a nephrostomy tube. However, it is important to note that CT scans of the abdomen and pelvis do not always show the course of the ureters making diagnosis of ureteral herniation challenging in many cases. Previous studies have shown that in cases where clinical suspicion is high and the CT scan does not clearly show ureteral herniation, obtaining urography or a retrograde pyelogram CT urogram may aid in making the diagnosis [5,25].

Ureteric hernias should ultimately be repaired surgically in order to prevent complications such as decreased renal function of the affected kidney, hydronephrosis, and urosepsis, all of which were represented in our case [5]. It is important for clinicians to be aware of this rare type of hernia as it can prevent iatrogenic damage of the ureter during surgical repair. As our case highlights, surgery can be deferred to a later time, assuming there is no evidence of strangulation or incarceration, by decompressing the renal system with a nephrostomy tube, which will alleviate symptomatic complications from the herniated ureter.

Conclusion

Uretero-inguinal hernias are rare and can lead to many complications which include loss of renal function, hydronephrosis, and urosepsis. However, surgery maybe deferred to a later time with the placement of a nephrostomy tube. Moreover,

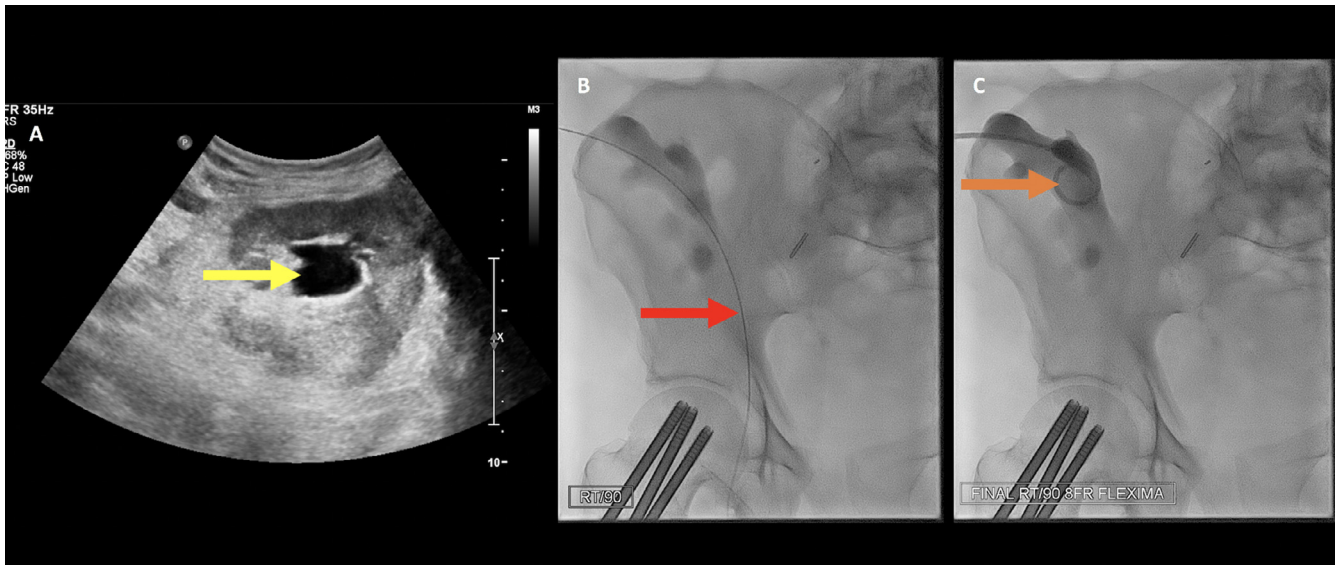


Fig. 2 – (A) Initial sonographic evaluation of the right lower quadrant transplant kidney demonstrating moderate hydronephrosis. (B, C) Intraprocedural fluoroscopic images of 8 Fr nephrostomy tube placement into hydronephrotic transplant kidney. The yellow arrow points to the dilated renal collecting system. The red arrow points to the guidewire that is within the transplant ureter. The orange arrow points to the final position of the nephrostomy tube.

failure to diagnose the presence of a herniated ureter prior to surgery puts patients at great risk for iatrogenic ureteral injury. Clinicians with a high index of suspicion may consider obtaining CT urograms, or IV and retrograde pyelograms when conventional CT scans of the abdomen and pelvis fail to identify the herniated ureter [5,25]. Given that injury to the ureters is a serious complication that requires additional surgical repair, it is important for clinicians to be aware of this rare type of hernia.

Supplementary materials

Supplementary material associated with this article can be found, in the online version, at doi:[10.1016/j.radcr.2018.09.002](https://doi.org/10.1016/j.radcr.2018.09.002).

REFERENCES

- [1] Hammoud M, Gerken J. Hernia, Inguinal. StatPearls [Updated 2018 Jul 16], Treasure Island (FL): StatPearls Publishing; 2018. Available from <https://www.ncbi.nlm.nih.gov/books/NBK513332/>.
- [2] Reistrup H, Zetner DB, Andersen K, Rosenberg J. A watchful waiting strategy in ventral and inguinal hernias. *Ugeskr Laeg* 2018;180(May (22)).
- [3] Berndsen MR, Gudbjartsson T, Berndsen FH. Is a technically challenging procedure more likely to fail? A prospective single-center study on the short- and long-term outcomes of inguinal hernia repair. *Surg Res Pract* 2018;2018:7850671.
- [4] Bouchot O, Branchereau J, Perrouin-Verbe MA. Influence of inguinal hernia repair on male fertility. *J Visc Surg Jun* 2018;155(Suppl. 1):S37–40.
- [5] Prete FP, Pezzolla A, De Leo V, Di Palma G, Prete F. Inguino-scrotal herniation of the ureter containing stones. *Hernia* 2016;20(6):887–90. <https://doi.org/10.1007/s10029-015-1400-7>.
- [6] Won ACM, Testa G. Chronic obstructive uropathy due to uretero-inguinal hernia: a case report. *Int J Surg Case Rep* 2012;3(8):379–81.
- [7] Ballard JL, Dobbs RM, Malone JM. Ureteroinguinal hernia: a rare complication of sliding inguinal hernia. *Am Surg* 1991;57:720.
- [8] Mallouh C, Pellman CM. Scrotal herniation of the ureter. *J Urologie* 1971;106:38–41.
- [9] Rocklin MS, Apelgren KN, Slomski CA, Kandzari SJ. Scrotal incarceration of the ureter with crossed renal ectopia: case report and literature review. *J Urologie* 1989;142:366.
- [10] Zmora O, Schachter PP. Sliding inguinal hernia containing the ureter: a case report. *J Urologie* 1996;155:1387.
- [11] Wagner AA, Arcand P, Bamberger MH. Acute renal failure resulting from huge inguinal bladder hernia. *Urology* 2004;64:156–7.
- [12] Loffroy R, Bry J, Guiu B, Dubruille T, Michel F, Cercueil JP, Krausé D. Ureterosciatic hernia: a rare cause of ureteral obstruction visualized by multislice helical computed tomography. *Urology* 2007;69(2):385 e1-3.
- [13] Evangelos F, Stavros G, George V, Elena E, Konstantinos V, Constantinos V. Asymptomatic extraperitoneal inguinoscrotal hernia involving ureter: a case presentation and review of the literature. *J Nat Sci Biol Med* 2015;6(3):153–5.
- [14] Giglio M, Medica M, Germinale F, Raggio M, Campodonico F, Stubinski R, et al. Scrotal extraperitoneal hernia of the ureter: case report and literature review. *Urol Int* 2001;66:166–8.
- [15] Hwang CM, Miller FH, Dalton DP, Hartz WH. Accidental ureteral ligation during an inguinal hernia repair of patient with crossed fused renal ectopia. *Clin Imaging* 2002;26:306–8.

-
- [16] Odisho AY, Freise CE, Tomlanovich SJ, Vagefi PA. Inguinal herniation of a transplant ureter. *Kidney Int* 2010;78:115.
- [17] Bertolaccini L, Giacomelli G, Bozzo RE, Gastaldi L, Moroni M. Inguino-scrotal hernia of a double district ureter: case report and literature review. *Hernia* 2005;9:291–3.
- [18] Giuly J, Francois G, Giuly D, Leroux C, Nguyen CR. Intrascrotal herniation of the urether. *Ann Chir* 2002;127:218–20.
- [19] Zarraonandia AA, Rios RA, Casas NJ, Ponce DRJ, Martinez BS, Gonzalez DJ, et al. Inguinal ureteral hernia: a clinical case. *Arch Esp Urol* 2009;62:755–7.
- [20] Kumar SR, Murari K, Kumar V, Kumar JV. Inguinoscrotal extraperitoneal herniation. *Can J Surg* 2009;52:29–30.
- [21] Massoud WA, Eschwege P, Haji P, Awad A, Iaaza LA, Chabenne J. Hydronephrosis secondary to sliding inguinal hernia containing the urether. *Urol J* 2011;8:333–334.
- [22] Alvarez Mugica M, Bulnes Vazquez V, Jalon Monzon A, Gonzalez Alvarez RC, Rodriguez Robles L, Martin Benito JL. Ureter derecho en hernia inguino-escrotal derecha. *Arch Esp Urol* 2007;60:1223.
- [23] Roach SC, Moulding F, Handbidge A. Inguinal herniation of the ureter. *Am J Roentgenol* 2005;185:283.
- [24] Sripathi S, Rajacopal KV, Kakkar A, Polnaya A. Case report—inguinoscrotal urethral hernia diagnosed on micturating cystoureterography. *Indian J Radiol Imaging* 2011;21:199–201.
- [25] McTavish JD, Jinzaki M, Zou KH, Nawfel RD, Silverman SG. Multi-detector row CT urography: comparison of strategies for depicting the normal urinary collecting system. *Radiology* 2002;225(3):783–90.