

CASE REPORT

**OPEN ACCESS**

Full open access to this and thousands of other papers at <http://www.la-press.com>.

## Neonatal Systemic Juvenile Xanthogranuloma with an Ominous Presentation and Successful Treatment

Rong Fan and Jihong Sun

Riley Hospital for Children at Indiana University Health Department of Pathology 702 Barnhill Drive, Room 2536 Indianapolis, Indiana, USA. Corresponding author email: [fanr@iupui.edu](mailto:fanr@iupui.edu)

---

**Abstract:** This case report originated from a case of neonatal multisystemic juvenile xanthogranuloma (JXG). The patient presented with blue muffin rash, cervical mass, bone destruction, lung nodule, hepatosplenomegaly, and coagulopathy and was successfully treated with Langerhans cell histiocytosis (LCH) based chemotherapy treatment. Similar cases in literature were reviewed and it seems that JXG, a relatively benign entity, when presented in its systemic form with liver involvement, could have an aggressive course and portend quite poor prognosis. Challenges and special consideration of the diagnosis, treatment, and future case observation are discussed.

**Keywords:** Juvenile xanthogranuloma, liver, neonatal, histiocytic disorder

---

*Clinical Medicine Insights: Oncology* 2011;5 157–161

doi: [10.4137/CMO.S6686](https://doi.org/10.4137/CMO.S6686)

This article is available from <http://www.la-press.com>.

© the author(s), publisher and licensee Libertas Academica Ltd.

This is an open access article. Unrestricted non-commercial use is permitted provided the original work is properly cited.



## Introduction

Juvenile xanthogranuloma (JXG) is a histiocytic disorder most commonly present in the first two decades of life, especially in the neonatal period and first year of life. It is principally a solitary cutaneous lesion with occasional multifocal or multisystemic involvement. It has a male predominance. Prognosis, generally speaking, is good except when there is deep or multi-systemic involvement. Three large clinicopathologic studies are available.<sup>1-3</sup>

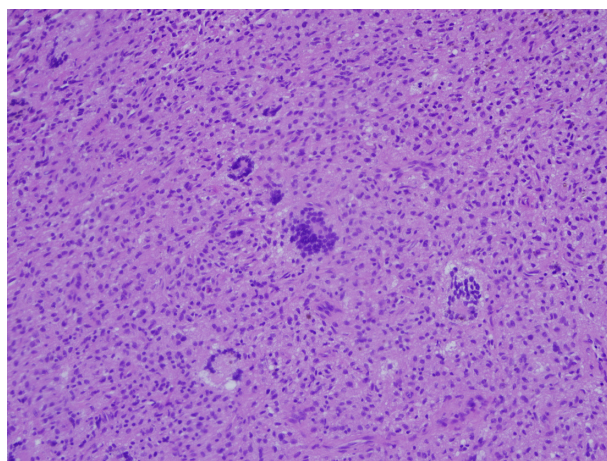
The spectrum of histological subtypes are nicely summarized by Janssen et al.<sup>2</sup> Early JXG typically presents within compact sheet-like histiocytic infiltrate, with or without scattered eosinophils, sometimes mimicking Langerhans cell histiocytosis (LCH). Touton-type giant cells are generally absent but can be detected occasionally. Classic JXG, on the other hand, typically has foamy histiocytes with abundant cytoplasm and fine cytoplasmic vacuolation; spectrum of fully developed Touton giant cells is present, but giant cells of Langerhans type or foreign body type are also possible. The late or transitional subtype typically shows predominance of single sheets of cells reminiscent of benign fibrous histiocytoma with the addition of foamy histiocytes and giant cells. Combinations of these subtypes are possible.

A distinctive immunohistochemistry staining pattern includes: positive CD68, alpha-1 antitrypsin, factor XIIIa, and lysozyme; S100 and CD1a are typically negative, in contrast to its cousin Langerhans cell histiocytosis. In electron microscopy studies, JXG shows no Birbeck granules as in LCH. Forms of systemic disease are rare and they have significant clinical implications, as summarized by Freyer and Dehner.<sup>4</sup> The case reported here is a newborn with multisystemic JXG involvement, illustrating the difficulties and challenges encountered diagnostically and therapeutically.

## Case Report

The patient is a 5-week-old, former 35-week infant who was admitted for evaluation of pancytopenia, transfusion dependence, and massive hepatosplenomegaly. He was born from normal spontaneous vaginal delivery with no maternal complications. It was noted that he had a blueberry muffin rash at birth.

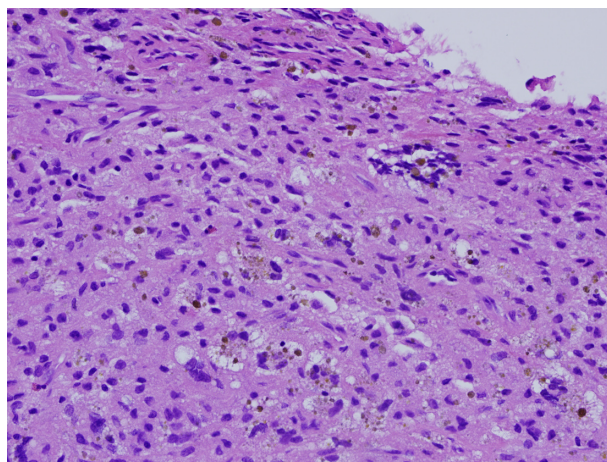
During his first month stay at nursery (NICU for prematurity), he was doing well and was eating and thriving.



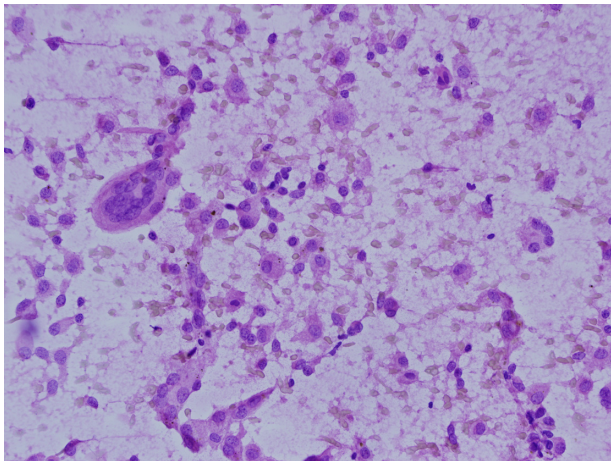
**Figure 1.** Juvenile xanthogranuloma. Foamy histiocytes aggregates with classic Touton giant cells embedded.

Physical examination was remarkable for left posterior cervical mass (suboccipital region) that was firm and diffuse, not discrete like a lymph node. The abdomen was soft, nontender, distended with marked hepatosplenomegaly down to the level of the umbilicus for the liver and spleen. There was an easily reducible umbilical hernia present. The rest of physical examination was within normal limits.

Diagnostic workup with abdominal ultrasound initially showed hepatomegaly with multiple hypoechoic lesions in the liver along with splenomegaly and ascites (Figure 5). Several CT scans confirmed these findings and found no other masses in the abdomen. Evaluation of the chest revealed a single right middle lobe nodule. Evaluation of the lymph node showed a mass adjacent to the left posterior cervical

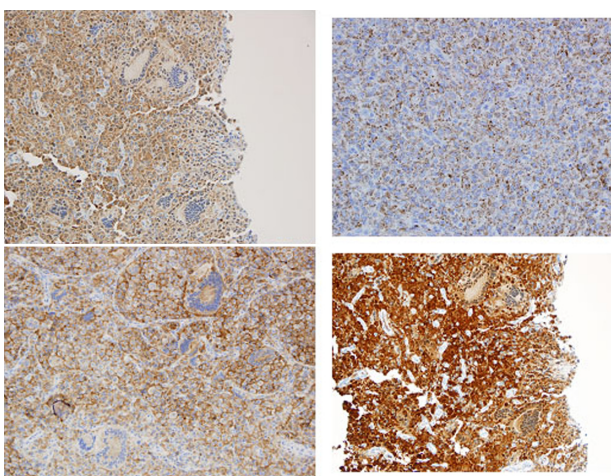


**Figure 2.** Note focally prominent hemosiderin deposit and presence of rare eosinophils.

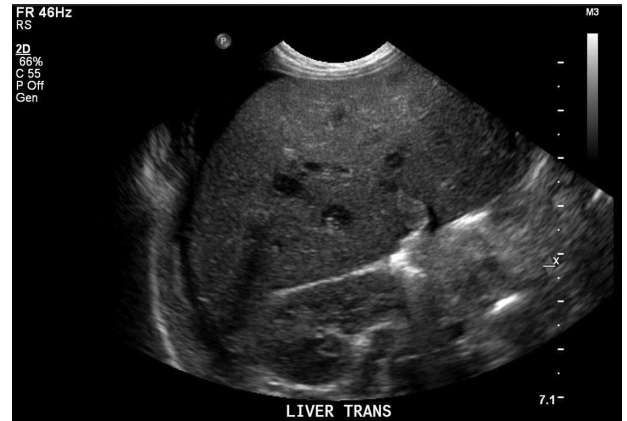

**Figure 3.** Teuton giant cell morphology is best appreciated on touch prep slides.

musculature and there was suggestion of destruction of the adjacent occipital bone and possible intracranial extension. MRI of the brain showed destruction of the left occiput with likely lesion of the left sigmoid sinus and abutment of the left internal carotid artery with encroachment of the spinal foramen without loss of flow in the artery or extension into the spinal cord. The bone marrow biopsy revealed a normocellular marrow with a decreased left shift. Other tests performed for these masses, including HVA and VMA, were all normal. The TORCH workup was negative. The differential for these various lesions, including the blueberry muffin spots, which were thought to be either in situ extramedullary hematopoiesis or superficial tumor metastases, included neuroblastoma and congenital leukemia.



**Figure 4.** The immunohistochemistry staining pattern: (A) Fascin upper left (B) CD68 upper right (C) CD4 lower left (D) Factor XIIIa lower right.



**Figure 5.** The liver ultrasound image showed multiple hypoechoic lesions.

Biopsy of the neck mass revealed a histiocytic lesion; the lesional cells were mostly polygonal (some with quite visible vacuolation) with indistinct borders, plus abundant classic Touton giant cells. Scattered inflammatory cells, mostly lymphocytes, were observed as well. Focal areas showed significant hemosiderin deposits (Figure 1–3). Entrapped nerve bundles and large caliber blood vessels were noted. The staining pattern of lesion cells was as follows: S100 negative, CD1a negative; CD68 positive, cytoplasmic, alpha-1 antitrypsin positive, cytoplasmic, lysozyme positive (strong, patchy, and cytoplasmic). Additional stains included: CD34, CD35, CD21, and CD20 negative; CD4 positive membranous; factor XIIIa strong positive; fascin positive; and cytoplasmic (Figure 4). The diagnosis of juvenile xanthogranuloma was established.

The patient was put on protocol LCH-III for the treatment of JXG, following the arm for high risk group. The chemotherapy agents included prednisone, Vinblastine, 6-MP, and Methotrexate. Coagulopathy and pancytopenia was managed symptomatically. The patient was relatively stable but had an episode of line infection. As this brief report was written, he has been off therapy for twenty months. At this point, he is doing well without any concerns and has begun walking and on regular followup. On physical examination, he was alert and well appearing; head and neck exam was remarkable only for a small bruise on his cheek; no mass was palpable in the left occipital region any longer. There was no lymphadenopathy. Lungs were clear throughout. Heart showed regular rate and rhythm without murmur. Abdomen examination demonstrated the liver was down 4 cm and spleen



tip was palpable 3 to 4 cm. His gait was considered wide based but age appropriate and the remainder of his exam was unremarkable. Pancytopenia had recovered and complete blood count (CBC) results were within normal ranges.

Radiology followup showed decrease in size of the left occipital soft tissue mass abutting the skull base; lung lesion and low density foci distributed throughout the liver were stable; hepatomegaly and splenomegaly were also stable.

## Discussion

Similar cases have been documented in medical literature and many of them behaved aggressively. It is fair to state that when JXG has liver involvement, it is a relatively benign disease in its worst form. In 1996, Dehner reported eight out of 34 patient with systemic JXG had liver involvement, two neonates died with systemic JXG, among which one had liver/spleen involvement (patient number 19).<sup>4</sup> In Dehner's 2003 survey, liver involvement claimed two out of only three deaths in 174 cases (patients number 2 and 7).<sup>1</sup> The Kiel study reported 129 patients with five cases of systemic JXG, in which the only one death (with disease) was the one with liver and spleen involvement (patient number 5).<sup>2</sup> In 2008, Haughton reported a case of "blueberry muffin baby" that proved to be a systemic JXG with skin and liver involvement, and who ended up needing liver transplant.<sup>5</sup> But successfully treated cases are available, summarized by Stover in 2008<sup>6</sup> So the pattern appears to be that the systemic JXG with liver involvement carries the worst prognosis implications, even though, as a whole, the systemic JXG group generally still tends to be prognostically optimistic.

It has been observed that extracutaneous JXG tends to have less or absent multinucleated giant cells, but our case is certainly the opposite. This case has florid classic Touton giant cells. So the lesson still is, the microscopic appearance of this entity is varied greatly and entertain the high suspicion with any histiocytes-rich lesion is essential.

From a cytogenesis point of view, JXG is related to LCH but has always been considered as a distinctive entity. The evolution of the hypotheses of its cellular origin is such an interesting topic that almost every study, major or small, paid some attention to it. Briefly, the earliest speculation in 1912 was that it has

an endothelial origin;<sup>7</sup> in 1954, its histiocytic nature was recognized and the consensus was to place this entity under non-Langerhans histiocytosis group as archetype of non-Langerhans histiocytosis,<sup>8-10</sup> with factor XIIIa+ dermal dendrocytes as the strongest candidate originating cells;<sup>11</sup> however, this concept has been challenged recently and plasmacytoid monocyte has been proposed as the putative origin of JXG.<sup>12</sup>

Due to the rarity of the systemic JXG, treatment protocols have followed that use for LCH. Histiocyte Society has a clinical stratification of LCH based on the extent of the disease. For patients with multiorgan involvement, LCH-III protocol is currently the most common treatment strategy, which was first suggested by Nakatani et al.<sup>13</sup> Experience with treating systemic JXG is available through a recent review by Stover, in which a LCH based regimen seems to have been justified.<sup>6</sup>

Clinical trials can be found on the website: H-9926-LCH III: Treatment Protocol of the Third International Study for Langerhans Cell Histiocytosis: <http://clinicaltrials.gov/ct2/show/NCT00488605>. The treatment does not always go well even though JXG generally carries a favorable prognosis even for its systemic forms. Patients sometime did not response, some died from the disease. Cladribine appears to be a reasonable second line option. In one report, an infant with systemic JXG with CNS involvement who first could not tolerate prednisolone and later failed vinblastine was treated successfully with Cladribine.<sup>14</sup> The similar positive responses have been reported in recurrent LCH treatments.<sup>15,16</sup>

Disease activity monitoring is also part of the Histiocyte Society's recommendation.<sup>17</sup>

## Conclusion

Because of the rarity and wide spectrum of manifestation, systemic JXG is often not considered in the initial differential diagnosis as happened in this case. Therefore, high degree of clinical suspicion and open mindedness is warranted when patients present with multisystemic symptoms suggestive of malignancy, especially with cases of similar presentation in the neonatal age group. Besides the consideration of neuroblastoma, so called "blueberry muffin rash" may also hint to the possible existence of systemic JXG.

Visceral multisystemic presentation with liver/spleen involvement and coagulopathy is perhaps the



worst form of systemic JXG with a more aggressive behavior and worse prognosis than other similar cases in the same category; intensified treatment, close monitoring, and followup is warranted. A LCH III based regimen is currently recommended and worked well in our case; if no satisfactory response is generated, an alternative treatment such as Cladribine may be tried.

Overall, our knowledge of systemic JXG is still very limited; more experience with its diagnosis and treatment is necessary and expected. More individual cases reports and multicenter coordination should be encouraged.

## Disclosure

This manuscript has been read and approved by all authors. This paper is unique and is not under consideration by any other publication and has not been published elsewhere. The authors and peer reviewers of this paper report no conflicts of interest. The authors confirm that they have permission to reproduce any copyrighted material.

## References

1. Dehner LP. Juvenile xanthogranulomas in the first two decades of life: a clinicopathologic study of 174 cases with cutaneous and extracutaneous manifestations. *Am J Surg Pathol.* 2003;27(5):579–93.
2. Janssen D, Harms D. Juvenile xanthogranuloma in childhood and adolescence: a clinicopathologic study of 129 patients from the kiel pediatric tumor registry. *Am J Surg Pathol.* 2005;29(1):21–8.
3. Marrogi AJ, et al. Benign cutaneous histiocytic tumors in childhood and adolescence, excluding Langerhans' cell proliferations. A clinicopathologic and immunohistochemical analysis. *Am J Dermatopathol.* 1992;14(1):8–18.
4. Freyer DR, et al. Juvenile xanthogranuloma: forms of systemic disease and their clinical implications. *J Pediatr.* 1996;129(2):227–37.
5. Houghton AM, et al. Disseminated juvenile xanthogranulomatosis in a newborn resulting in liver transplantation. *J Am Acad Dermatol.* 2008; 58(2 Suppl):S12–5.

6. Stover DG, et al. Treatment of juvenile xanthogranuloma. *Pediatr Blood Cancer.* 2008;51(1):130–3.
7. McDonagh J. Spontaneous disappearance of an endothelioma (nevo-xanthoma). *Br J Dermatol.* 1909;17:254–6.
8. Dehner LP. Reawakening to the existence of juvenile xanthogranuloma. *Am J Surg Pathol.* 2005;29(1):119–20.
9. Favara BE, et al. Contemporary classification of histiocytic disorders. The WHO committee on histiocytic/reticulum cell proliferations. Reclassification Working Group of the Histiocyte Society. *Med Pediatr Oncol.* 1997;29(3): 157–66.
10. Zelger BW, Cerio R. Xanthogranuloma is the archetype of non-Langerhans cell histiocytoses. *Br J Dermatol.* 2001;145(2):369–71.
11. Misery L, Boucheron S, Claudy AL. Factor XIIIa expression in juvenile xanthogranuloma. *Acta Derm Venereol.* 1994;74(1):43–4.
12. Kraus MD, et al. "Juvenile" xanthogranuloma: an immunophenotypic study with a reappraisal of histogenesis. *Am J Dermatopathol.* 2001;23(2): 104–11.
13. Nakatani T, et al. Successful treatment of congenital systemic juvenile xanthogranuloma with Langerhans cell histiocytosis-based chemotherapy. *J Pediatr Hematol Oncol.* 2004;26(6):371–4.
14. Rajendra B, et al. Successful treatment of central nervous system juvenile xanthogranulomatosis with cladribine. *Pediatr Blood Cancer.* 2009;52(3): 413–5.
15. Stine KC, et al. Efficacy of continuous infusion 2-CDA (cladribine) in pediatric patients with Langerhans cell histiocytosis. *Pediatr Blood Cancer.* 2004;43(1):81–4.
16. Rodriguez-Galindo C, et al. Treatment of children with Langerhans cell histiocytosis with 2-chlorodeoxyadenosine. *Am J Hematol.* 2002;69(3):179–84.
17. Satter EK, High WA. Langerhans cell histiocytosis: a review of the current recommendations of the Histiocyte Society. *Pediatr Dermatol.* 2008;25(3): 291–5.

**Publish with Libertas Academica and every scientist working in your field can read your article**

*"I would like to say that this is the most author-friendly editing process I have experienced in over 150 publications. Thank you most sincerely."*

*"The communication between your staff and me has been terrific. Whenever progress is made with the manuscript, I receive notice. Quite honestly, I've never had such complete communication with a journal."*

*"LA is different, and hopefully represents a kind of scientific publication machinery that removes the hurdles from free flow of scientific thought."*

### Your paper will be:

- Available to your entire community free of charge
- Fairly and quickly peer reviewed
- Yours! You retain copyright

<http://www.la-press.com>