

A woman with dyspnea and recurrent pneumothorax: when dyspnea is not asthma

Anusha Chidharla^a, Matthew Sehring^b, Marisa Ayari Ascencio^c and Subramanyam Chittivelu^{d,e}

^aDepartment of Internal Medicine, University of Illinois College of Medicine, Peoria, IL, USA; ^bDepartment of Pulmonary Critical Care, University of Illinois College of Medicine, Peoria, IL, USA; ^cUniversity of Illinois College of Medicine, Peoria, IL, USA; ^dMedicine and Program Director, Pulmonary and Critical Care Medicine, University of Illinois College of Medicine, Peoria, IL, USA; ^eDepartment of Internal Medicine and Pulmonary Critical Care, Peoria OSF Medical Center and Illinois Lung Institute, Peoria, USA

ABSTRACT

Lymphangioleiomyomatosis (LAM) is a rare disease characterized by cystic lung lesions, lymphatic abnormalities, and angiomyolipomas. It can take a significant amount of time to diagnose LAM due to the vague symptoms of fatigue, progressive dyspnea, pneumothorax, and pleural effusion. We present a case of a 29-year-old woman with recurrent spontaneous pneumothorax and progressive dyspnea who was initially misdiagnosed with asthma and was later found to have LAM. As with all rare diagnoses, there needs to be a suspicion of the disease in order for a further workup to be initiated. In patients with a compatible High-resolution CT scan of the chest, a high vascular endothelial growth factor-D (VEGF-D) value is diagnostic for LAM, and no other confirmatory test is needed.

ARTICLE HISTORY

Received 12 March 2020
Accepted 15 May 2020

KEYWORDS

Lymphangioleiomyomatosis; high-resolution CT; pneumothorax; vascular endothelial growth factor-D

1. Background

Lymphangioleiomyomatosis (LAM) is a rare disease characterized by cystic lung lesions, lymphatic abnormalities, and angiomyolipomas. A hallmark of the disease is the proliferation of the smooth muscle-like cells leading to the formation of lung cysts and fluid-filled cystic structures. Lymphangiomas in the thorax can be found in mediastinum, heart, thoracic duct, lung, and pleura. They can also be present in either a single or multiple organs. LAM can occur sporadically in patients with no evidence of genetic disease or be associated with tuberous sclerosis. Sporadic LAM is an uncommon disease with a prevalence that has been estimated at 2.6 per 1 million women[1].

2. Objective

To increase physicians' awareness of LAM for timely diagnosis and treatment.



3. Case presentation

We report a case of a 29-year-old female with a past medical history of spontaneous pneumothorax post-blebectomy and pleurodesis who was admitted for sudden onset shortness of breath and chest pain. Patient had progressive dyspnea on minimal exertion for the past year, which was most notable after climbing stairs. She saw her general

practitioner three times in the past year for similar symptoms. Laboratory workup and X-ray were unremarkable as an outpatient. Of note, patient did not appear to have a CT scan of her chest or pulmonary function testing done for her prior pneumothorax. She was ultimately diagnosed with depression and bronchial asthma. This was treated with an anti-depressant and albuterol inhaler with minimal improvement.

She presented to the ED for acute worsening of dyspnea and was found to have a pneumothorax. She denied recent trauma, travel, hiking, high altitude exposure, or scuba diving. She had no history of recurrent infections, seizures, rashes, joint pains, muscle weakness, and exposure to lung irritants. She is a non-smoker with no recreational drug use. She works as a laboratory technician. Her medications included oral contraceptive pill, albuterol inhaler, fluticasone, spray, and sertraline. Family history was only significant for lung cancer in her maternal grandfather, who was a smoker. Her pneumothorax resolved after placement of a chest tube, which was removed without complications after 3 days.

She continued to have exertional shortness of breath and hypoxia, despite the resolution of her pneumothorax. Upon further review, a chest x-ray showed diffuse basilar reticular opacities which were not present 6 months ago. Due to the new opacities, CT angiography was ordered and revealed diffuse cysts in the lungs consistent with LAM (Figure 2) as well as multiple nodular and

CONTACT Anusha Chidharla  anushaedma@gmail.com  Department of Internal Medicine, University of Illinois College of Medicine, Peoria, IL, USA

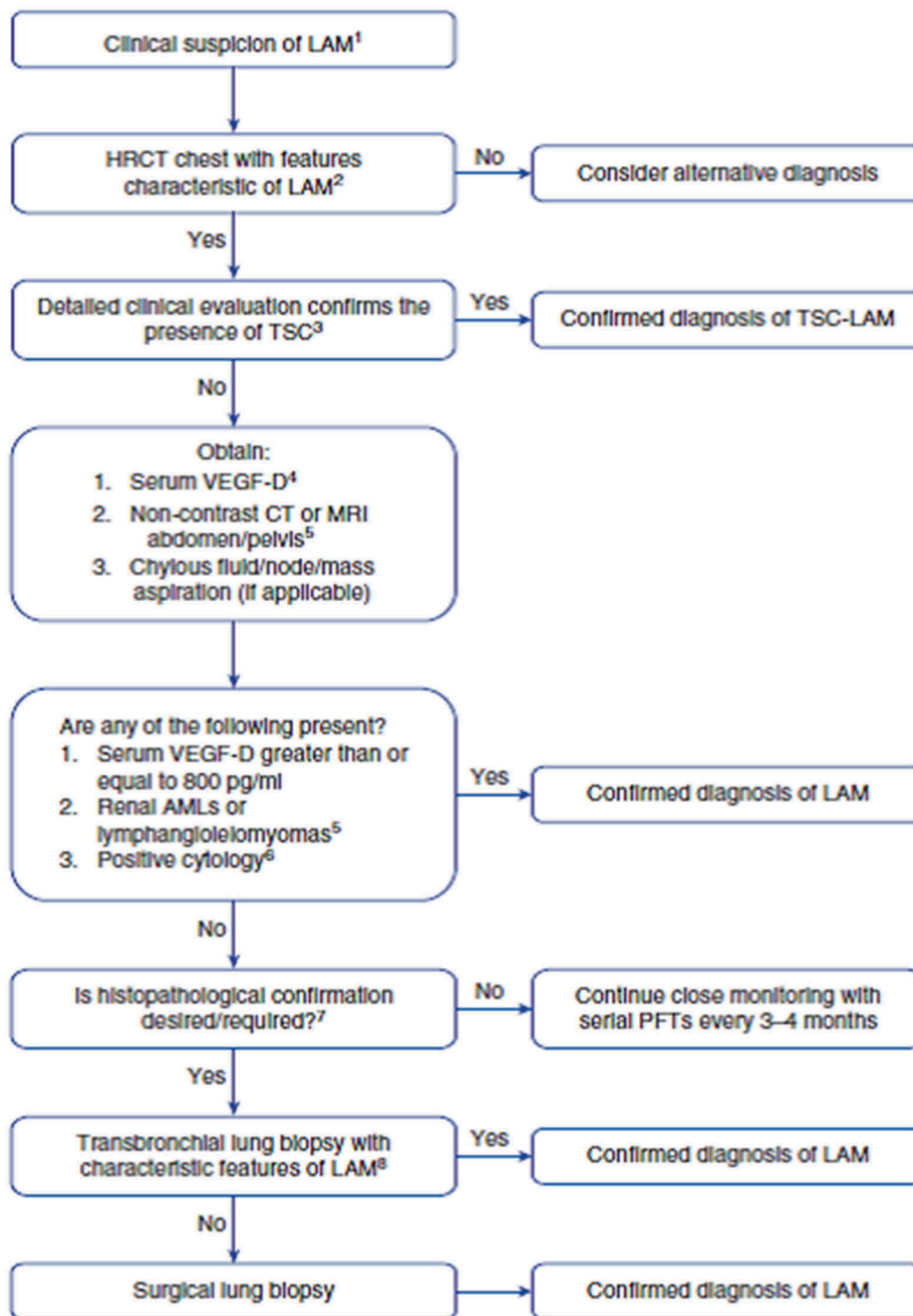


Figure 1. Clinical algorithm for diagnosis of LAM.[2]

confluent mass-like lesions in the retroperitoneum and left upper abdomen. Alpha-1-antitrypsin, rheumatoid factor, and autoimmune nuclear antibodies were unremarkable, which ruled out other causes of cystic lung diseases. Further evaluation of the abdominal lesions was done with a dedicated abdominal CT scan, which confirmed lesions consistent with retroperitoneal cystic lymphangiomyoma. Vascular endothelial growth factor-D (VEGF-D) was 3748 pg/ml and she was referred to a LAM excellence center. She was advised to stop using estrogen contraceptive pills

and try intrauterine device for contraception. Baseline pulmonary function tests were done which showed FEV1 (forced expiratory volume in 1 second) 59% predicted suggestive of moderate obstruction and severe decrease in DLCO (diffusion capacity of carbon monoxide) to 39%. She was started on a bronchodilator. She was also started on Sirolimus, a mechanistic target of Rapamycin (mTOR) inhibitor with Rapamycin trough levels with a goal of 5–15 ng/ml. She was advised to follow up for pulmonary function tests every 6 months and VEGF-D levels every 3 months. Her

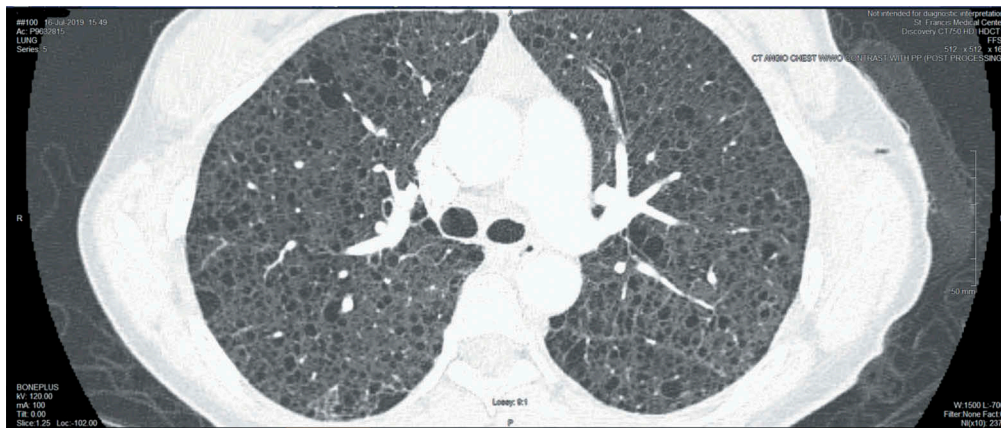

Figure 2. Axial chest CT of patient.

VEGF-D level 3 months after initiation of treatment was 2336 pg/ml. Patient reported no progression of symptoms at her 3 months follow-up and is being managed by a local pulmonologist.

4. Discussion

It can take a significant amount of time to diagnose LAM due to the vague symptoms of fatigue, progressive dyspnea, pneumothorax, and pleural effusion. Women with LAM typically have symptoms for 3 to 5 years and suffer an average of 2.2 pneumothoraxes before the diagnosis of LAM is made. As with all rare diagnoses, there needs to be a suspicion of the disease in order for a further workup to be initiated. High-resolution CT (HRCT)(Figure 1)scan is the most accurate imaging test for diagnosing LAM, providing a correct diagnosis more than 80% of the time. HCRT is recommended for all non-smoking women who present with spontaneous pneumothorax, more than one spontaneous pneumothorax regardless of smoking status, and for women with angiomyolipoma, lymphangiomyoma, or chylous effusion.

Vascular endothelial growth factor-D (VEGF-D), a blood-based diagnostic test, can distinguish LAM from other cystic lung diseases that present with similar HRCT scan appearances. In patients with a compatible HRCT chest, a high VEGF-D value is diagnostic for LAM, and no other confirmatory test is needed. LAM is a rare disease to be considered in the differential diagnosis for cystic lung diseases. The recurrence rate of pneumothorax is high if the patient is not treated surgically.

General management of LAM includes baseline pulmonary function tests, follow-up pulmonary function tests every 6 months, VEGF-D levels every 3 months, pulmonary rehabilitation, avoidance of estrogen-containing medications, vaccinations against influenza and pneumococcus, and

advice about pregnancy if appropriate [3]. It is important to provide patients with an early referral to a LAM excellence center to coordinate care between LAM experts and local pulmonologists. Ipsilateral pleurodesis is recommended for patients who present with their initial pneumothorax, to decrease the likelihood of recurrent pneumothorax. Drug treatment can include bronchodilators, Sirolimus, and Everolimus. Sirolimus, an mTOR inhibitor, is used in patients with moderate to severe lung function impairment, which is defined by an FEV1 < 70% predicted. Sirolimus is known to stabilize lung function, decrease VEGF-D levels, decrease symptoms, and improve quality of life by slowing disease progression [4]. However, it is not a curative treatment. For patients who do not tolerate or respond to Sirolimus, an alternative mTOR inhibitor, such as Everolimus can be used. There is a lot of potential for research as several other agents that can slow the progression of LAM are under investigation. Unfortunately, many patients with LAM may require lung transplantation eventually due to progressive respiratory failure. The estimated median transplant-free survival time for pulmonary LAM is 29 years from symptom onset and 23 years from diagnosis. Early recognition of the disease is important in order to start treatment to prevent progression and further complications from the disease.

Disclosure statement

No potential conflict of interest was reported by the authors.

References

- [1] Taveira-DaSilva AM, Steagall WK, Moss J. Lymphangioliomyomatosis. *Cancer Control*. 2006;13:4.

- [2] Gupta N, Finlay GA, Kotloff RM, et al. Lymphangiomyomatosis diagnosis and management: high-resolution chest computed tomography, transbronchial lung biopsy, and pleural disease management. An official American thoracic society/Japanese respiratory society clinical practice guideline. *Am J Respir Crit Care Med.* 2017;196(10):1337–1348.
- [3] Johnson SR, Taveira-DaSilva AM, Moss J, et al. Lymphangiomyomatosis. *Clin Chest Med.* 2016;37(3):389–403.
- [4] Inoue Y, Moss J, Singer LG, et al. Efficacy and safety of sirolimus in lymphangiomyomatosis. *N Engl J Med.* 2011;365(3):271–272.