


# Diagnostic Value of Artificial Intelligence in Minimal Breast Lesions Based on Real-Time Dynamic Ultrasound Imaging

Chen Qu<sup>1,\*</sup>, Fei Xia<sup>2,\*</sup>, Ling Chen<sup>1</sup>, Hong-Jian Li<sup>2</sup>, Wei-Min Li<sup>1</sup> 

<sup>1</sup>Department of Ultrasonography, Affiliated Hospital of Jiangnan University, Wuxi, Jiangsu, People's Republic of China; <sup>2</sup>Department of Ultrasonography, Huai'an Cancer Hospital, Huai'an, Jiangsu, People's Republic of China

\*These authors contributed equally to this work

Correspondence: Hong-Jian Li, Department of Ultrasonography, Huai'an Cancer Hospital, Huai'an, Jiangsu, 223232, People's Republic of China, Tel +8613511507565, Email 492938595@qq.com; Wei-Min Li, Department of Ultrasonography, Affiliated Hospital of Jiangnan University, Wuxi, Jiangsu, 214000, People's Republic of China, Tel +8613912362309, Email 1005342597@qq.com

**Purpose:** To explore the diagnostic value of artificial intelligence (AI)-based on real-time dynamic ultrasound imaging system for minimal breast lesions.

**Patients and Methods:** Minimal breast lesions with a maximum diameter of  $\leq 10$ mm were selected in this prospective study. The ultrasound equipment and AI system were activated Simultaneously. The ultrasound imaging video is connected to the server of AI system to achieve simultaneous output of AI and ultrasound scanning. Dynamic observation of breast lesions was conducted via ultrasound. And these lesions were evaluated and graded according to the Breast Imaging Reporting and Data System (BI-RADS) classification system through deep learning (DL) algorithms in AI. Surgical pathology was taken as the gold standard, and ROC curves were drawn to determine the area under the curve (AUC) and the optimal threshold values of BI-RADS. The diagnostic efficacy was compared with the use of a BI-RADS category  $>3$  as the threshold for clinically intervening in diagnosing minimal breast cancers.

**Results:** 291 minimal breast lesions were enrolled in the study, of which 228 were benign (78.35%) and 63 were malignant (21.65%). The AUC of the ROC curve was 0.833, with the best threshold value  $>4A$ . When using  $>BI-RADS 3$  and  $>BI-RADS 4A$  as threshold values, the sensitivity and negative predictive value for minimal breast cancers were higher for  $>BI-RADS 3$  than  $>BI-RADS 4A$  (100% vs 65.08%, 100% vs 89.91%, P values  $<0.001$ ). However, the corresponding specificity, positive predictive value, and accuracy were lower than those for  $>BI-RADS 4A$  (42.11% vs 85.96%, 32.31% vs 56.16%, and 54.64% vs 81.44%, P values  $<0.001$ ).

**Conclusion:** The AI-based real-time dynamic ultrasound imaging system shows good capacity in diagnosing minimal breast lesions, which is helpful for early diagnosis and treatment of breast cancer, and improves the prognosis of patients. However, it still results in some missed diagnoses and misdiagnoses of minimal breast cancers.

**Keywords:** Breast cancer, ultrasound, artificial intelligence, diagnostic

Breast cancer ranks as one of the primary causes of mortality among women globally. According to the latest global cancer statistics, breast cancer has now surpassed lung cancer as the most commonly diagnosed form of cancer, constituting 11.7% of new cases in 2020.<sup>1</sup> Despite substantial progress in the treatment of breast cancer, it continues to be a major global health challenge. Even with notable advancements in its diagnosis and treatment, both the incidence and mortality rates of breast cancer still rise annually in many regions of the world.<sup>2</sup> The early detection, diagnosis, and treatment of minimal breast lesions, referring to breast lesions with a diameter of less than 10 mm and malignant lesions are called minimal breast cancer among them, can significantly enhance patient prognosis.<sup>3,4</sup>

Ultrasound, as one of the two most prevalent diagnostic methods for breast cancer, has the benefits of simplicity, speed, and the absence of radiation. Moreover, with ongoing innovations in ultrasound technology, the accuracy of diagnosing breast cancer through this method has progressively improved.<sup>5</sup> However, breast ultrasound is highly

operator-dependent, requiring a high level of operator skill and experience for reliable and good-quality imaging. Moreover, subjective factors also play a role in the diagnostic process, which may lead to misdiagnosis in some patients, resulting in a worse prognosis. Therefore, improving the accuracy of ultrasound diagnosis and eliminating the influence of subjective factors has become a clinical challenge. In recent years, the integration of artificial intelligence (AI) in ultrasound has revolutionized the field, transitioning diagnosis from a subjective, skill-dependent practice to an objective, efficient, and reproducible analytical process. Research indicates that AI can aid ultrasound physicians in assessing breast images, markedly decreasing human error and approaching the expertise of highly experienced doctors.<sup>6-8</sup> Unlike imaging methods such as CT and MR, ultrasound scanning operates as a real-time dynamic process. Assessing breast lesions based on static ultrasound images can lead to significant errors, necessitating a comprehensive dynamic evaluation of breast tumors. Studies have shown that compared to traditional static AI diagnostic models, AI systems based on real-time dynamic ultrasound imaging can identify more detailed spatial and temporal information, enabling more accurate classification of breast lesions and thereby enhancing breast cancer diagnosis.<sup>9</sup>

As early indicators of breast cancer, minimal breast lesions evaluated via ultrasound inherently involve a high degree of subjectivity, potentially resulting in numerous missed and misdiagnosed cases. In clinical practice, we found that artificial intelligence system based on real-time dynamic ultrasound imaging could help improve the accuracy of assessment for minimal breast lesions to some extent. Our study aims to explore the diagnostic value of an AI-based real-time dynamic ultrasound imaging system for minimal breast lesions to determine whether AI technology can more objectively and accurately differentiate between benign and malignant minimal breast lesions.

## Materials and Methods

### General Information

All procedures involving human participants were performed in accordance with the Declaration of Helsinki (2013). The Ethics Committee of the Affiliated Hospital of Jiangnan University approved this study. Written informed consent was obtained from all participants before inclusion in the study. In this study, we prospectively analyzed 291 patients with minimal breast lesions who underwent ultrasound examinations at Affiliated Hospital of Jiangnan University from March 2022 to April 2024. The inclusion criteria were as follows: (1) Both artificial intelligence and ultrasound physicians assessed the nodules as BI-RADS 4; (2) The maximum diameter of the nodules was  $\leq 10$ mm; (3) Confirmed by surgical pathology with clear histopathological results; (4) In cases where 2 or more lesions were found in one breast, the lesion with the highest BI-RADS classification was selected. The exclusion criteria were as follows: (1) Nodules that had been biopsied before ultrasound examination; (2) Patients receiving neoadjuvant chemotherapy or radiotherapy; (3) Incomplete ultrasound or histopathological data; (4) Maximum diameter of breast nodules  $>10$ mm.

### Apparatus and Methods

Siemens 3000 Color Doppler ultrasound imaging was used, equipped with a linear array probe with a frequency range of 7.5–12MHz. During the scanning, the patient was placed in a supine position with both breasts and armpits fully exposed. The nipples are centered, and a sector scanning method is used to scan the breasts. Multifaceted and combined longitudinal and transverse scanning methods are employed for minimal breast lesions. All examinations were performed by an ultrasound physician with over ten years of experience.

### Artificial Intelligence Evaluation

During the breast scanning, the Yizhun AI server (Beijing Yizhun Intelligent Technology Co., Ltd., Registration No. 20212210021) is activated as well. The AI server displays the location of lesions at a speed of 64 frames per second, and convolutional neural network feature fusion simulates the restoration of 3D lesions, extracting features of benign and malignant lesions that cannot be recognized by the naked eye. Besides, AI server is directly connected to the ultrasound machine's video output and uses deep learning (DL) algorithms to automatically analyze all attributes based on the DL and ACR BI-RADS guidelines to generate an intelligent ultrasound BI-RADS report (categories 3, 4A, 4B, 4C, 5) and describe histological features, including shape (round, oval, lobulated, less regular, irregular), orientation

(parallel, non-parallel), edges (clear, fairly clear, less clear, unclear), internal echoes (high, equal, low, anechoic, heterogeneous, complex cystic-solid), posterior echoes (enhanced, shadow, unchanged, mixed changes), and calcifications within the lesion (none, coarse, micro, mixed, other).

## BI-RADS Classification Standards and Diagnostic Methods

The ACR-BI-RADS guidelines are used to evaluate minimal breast lesions.<sup>9</sup> Category 0: Assessment is incomplete; further examination is needed. Category 1: No obvious abnormalities observed. Category 2: Benign lesions; regular follow-up recommended. Category 3: Probably benign (<2% likelihood of malignancy). Category 4A: Low suspicion of malignancy (2%-<10% likelihood of malignancy). Category 4B: Moderate suspicion of malignancy (10%-50% likelihood of malignancy). Category 4C: High suspicion of malignancy (50%-<95% likelihood of malignancy). Category 5: Highly suggestive of malignancy ( $\geq$ 95% likelihood of malignancy).

## Statistical Analysis

Statistical analyses were conducted using SPSS 26.0 and MedCalc 19.3.1 software. Quantitative data are expressed as mean  $\pm$  standard deviation, and categorical data are expressed as percentages. Comparisons of quantitative data were made using the independent samples *t*-test, while rates were compared using the  $\chi^2$  test and Fisher's exact test. Pathological results were used as the gold standard. Receiver operating characteristic curves (ROC) for the BI-RADS classification of minimal breast lesions were plotted, and the area under the curve (AUC) and Youden index were calculated. An AUC of 0.50–0.69 indicates poor diagnostic performance, 0.70–0.79 indicates moderate diagnostic performance, 0.80–0.89 indicates good diagnostic performance, and  $AUC \geq 0.90$  indicates excellent diagnostic performance. The score corresponding to the maximum Youden index represents the optimal threshold for each group. A P-value <0.05 is considered statistically significant.

## Results

### Pathological Results

In this study, a total of 291 minimal breast lesions were included. According to the 5th edition of the WHO histological classification of breast tumors (2019).<sup>10,11</sup> There were 228 benign cases (78.35%) and 63 malignant cases (21.65%). Specific pathological types are detailed in Table 1.

### Ultrasound Features of Minimal Breast Lesions

The analysis of the ultrasound features of benign and malignant minimal breast lesions revealed significant statistical differences in shape and edges ( $\chi^2$  values were 53.830 and 88.997, respectively, both  $P < 0.001$ ). No significant differences

**Table 1** Distribution of Pathological Results (n)

Pathological Result	n
Benign Lesions	228
Adenosis	91
Fibroadenoma	76
Intraductal papilloma	37
Adenomatosis	22
Sclerosing adenosis	2
Malignant Lesions	63
Invasive ductal carcinoma	39
Ductal carcinoma in situ	8
Invasive lobular carcinoma	6
Papillary ductal carcinoma in situ	4
Solid papillary carcinoma	4

were found in orientation, internal echoes, posterior echoes, and calcifications within the lesion ( $\chi^2$  values were 2.540, 0.901, 4.130, and 3.292, respectively; P values were 0.111, 0.924, 0.248, and 0.349, respectively) (Table 2). Images of ultrasound features of benign and malignant minimal breast lesions are shown below (Figure 1).

## BI-RADS Classification and Distribution of Malignant in Minimal Breast Lesions

According to the 2013 ACR BI-RADS standards, the 291 minimal breast lesions were classified as BI-RADS 3, 4A, 4B, and 4C in 96, 122, 69, and 4 cases, respectively. The malignancy rate for BI-RADS 3 minimal breast lesions was within the reference range of the 2013 ACR BI-RADS standards, while the malignancy rates for BI-RADS 4A, 4B, and 4C minimal breast lesions were higher than the reference range of the 2013 ACR BI-RADS standards (Table 3).

## ROC Curves and Diagnostic Performance of BI-RADS Classification for Minimal Breast Lesions

The ROC curve for the benign and malignant classification of minimal breast lesions and their BI-RADS categorization (Figure 2) indicates an AUC of 0.833 (95% CI: 0.785 to 0.874). At the point of maximum Youden Index, the optimal threshold for the BI-RADS classification system corresponds to BI-RADS > 4A.

When using >BI-RADS 3 and >BI-RADS 4A as threshold values, the sensitivity and negative predictive value (NPV) for >BI-RADS 3 were higher than for >BI-RADS 4A (100% vs 65.08%, and 100% vs 89.91%, respectively; P values <0.001). However, the corresponding specificity, positive predictive value (PPV), and accuracy were less than those for >BI-RADS 4A (42.11% vs 85.96%, 32.31% vs 56.16%, and 54.64% vs 81.44%, respectively; P values <0.001) (Table 4).

## Discussion

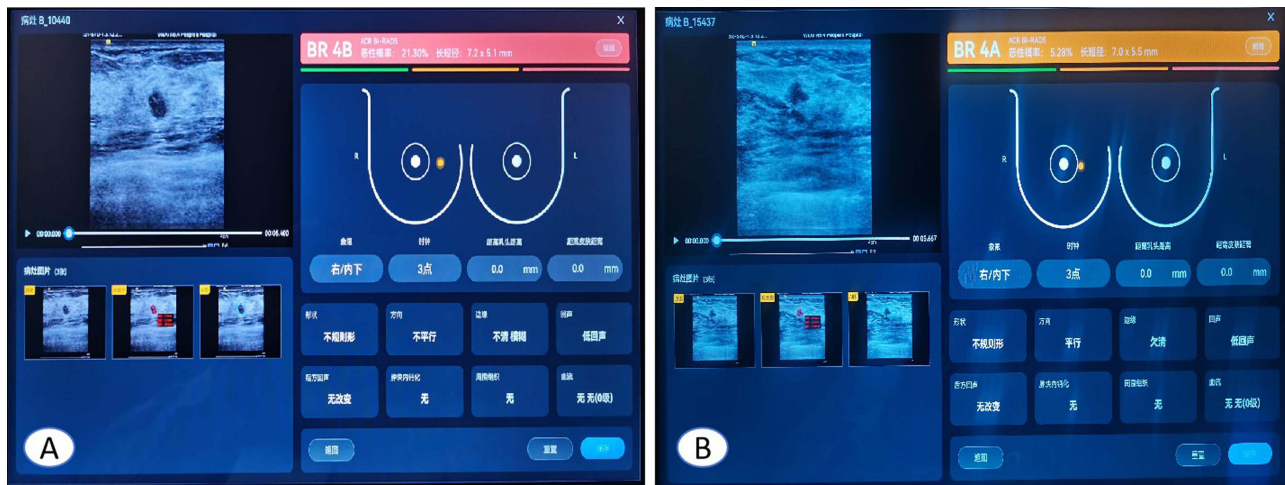
Evaluating minimal breast lesions is both a clinical priority and a significant challenge due to the high subjectivity in ultrasound physicians' assessments. At present, there are many researches on AI in breast cancer and the results are good as well. However, given the small size and atypical symptoms of minimal breast lesions, no relevant research was found in minimal breast lesions about AI. Our study used surgical pathology as the gold standard and analyzed 291 minimal breast lesions of  $\leq 10$ mm using an AI-based real-time dynamic ultrasound imaging system. The BI-RADS classification system showed low diagnostic efficiency for minimal breast cancers with an AUC of 0.833, and when the Youden index was at its maximum, the optimal threshold value was >BI-RADS 4A, with sensitivity, specificity, PPV, NPV, and overall accuracy respectively at 65.08%, 85.96%, 56.16%, 89.91%, and 81.44%.

Our analysis of the pathological results of the 291 minimal breast lesions showed that the malignancy rates for BI-RADS 4A, 4B, and 4C nodules were 18.03%, 53.62%, and 100%, respectively, all higher than the possible malignancy levels indicated by the 2013 ACR BI-RADS standards. This may be due to atypical ultrasound features of some malignant minimal breast lesions and a significant overlap between benign and malignant features. The analysis revealed that only the shape and edges of benign and malignant minimal breast lesions showed statistical differences in ultrasound features, whereas orientation, internal echoes, posterior echoes, and calcifications within the lesion showed no significant differences. The findings may differ from previous studies, indicating that malignant breast lesions often have irregular shapes, uneven edges, non-parallel orientations, attenuated posterior echoes, and microcalcifications.<sup>12–14</sup> However, in this study, the minimal size of the lesions increased the difficulty of differentiation. Although fibroadenomas and intraductal papillomas typically have characteristic ultrasound features, adenosis—the most common benign minimal breast lesion observed in this study—displayed ultrasound characteristics that significantly overlapped with those of minimal breast cancers, thereby complicating accurate assessment.

This study shows that the 2013 ACR BI-RADS classification guidelines have an AUC of 0.833 for diagnosing minimal breast cancers, indicating high clinical value in classifying minimal breast lesions. When the Youden index is at its maximum, the optimal threshold for the BI-RADS classification system is >BI-RADS 4A, consistent with the threshold values for breast tumors commonly employed by researchers.<sup>15,16</sup> At this threshold, the specificity is high, at 85.96%, meaning that the AI-based real-time dynamic ultrasound imaging system has a low misdiagnosis rate in diagnosing minimal breast lesions, which helps in accurately assessing patients with benign minimal breast lesions

**Table 2** Comparison of Ultrasonographic Characteristics in Benign and Malignant Minimal Breast Lesions (n)

Group	Shape					Orientation		Edges							
	Round	Oval	Lobulated	Less regular	Irregular	Parallel	Non-parallel	Clear	Fairly clear	Less clear	Unclear				
Benign	2	139	13	18	56	202	26	45	75	53	55				
Malignant	1	7	3	15	37	51	12	0	2	5	56				
$\chi^2$ value	53.830					2.540		88.997							
P value	<0.001					0.111		<0.001							
Group	Internal echoes						Posterior echoes				Calcifications				
	High	Equal	Low	Anechoic	Heterogeneous	Complex cystic-solid	Enhanced	Shadow	Unchanged	Mixed changes	None	Coarse	Micro	Mixed	Other
Benign	2	2	212	0	3	9	3	14	210	1	184	16	25	0	3
Malignant	1	0	59	0	1	2	1	8	53	1	47	3	11	0	2
$\chi^2$ value	0.901						4.130				3.292				
P value	0.924						0.248				0.349				



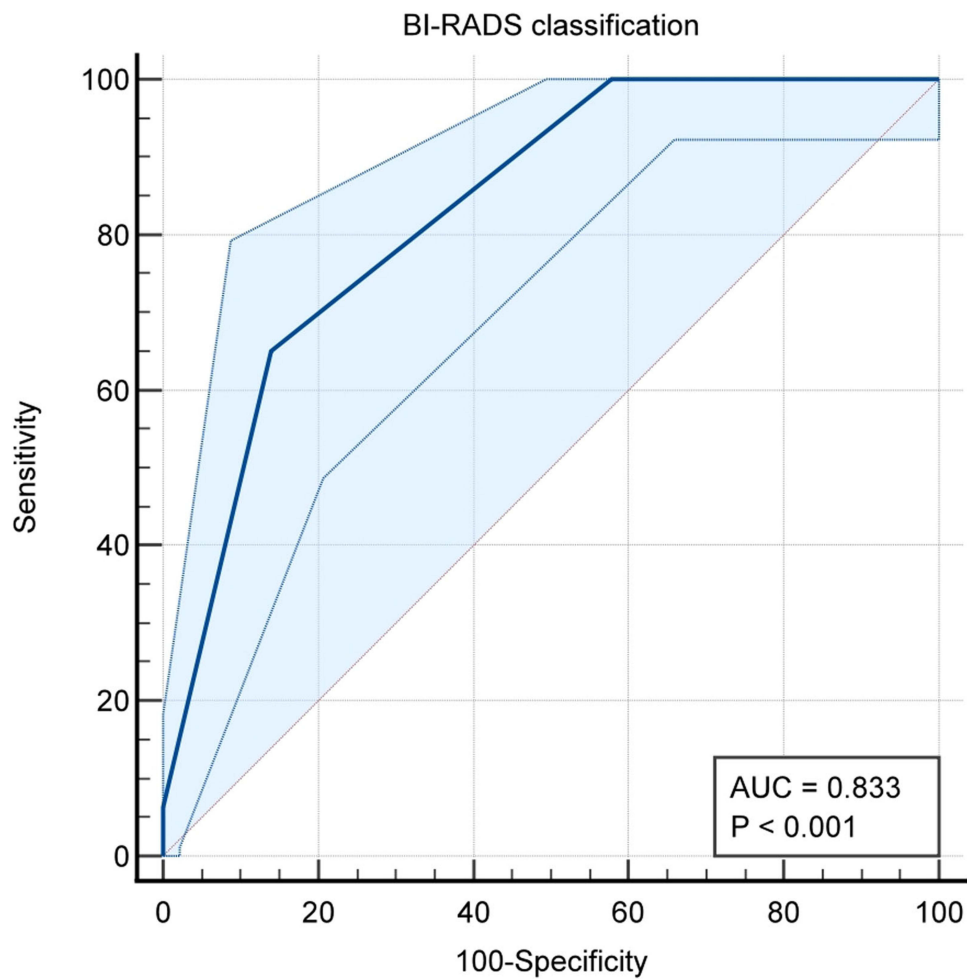
**Figure 1** Representative malignant and benign minimal breast lesions (A) Malignant minimal breast lesions, AI shows BI-RADS 4B. Pathologically confirmed as invasive ductal carcinoma (B) Benign minimal breast lesions, AI shows BI-RADS 4A. Pathologically confirmed as adenosis.

and avoiding unnecessary surgery. However, the sensitivity at this point is not very satisfactory, only 65.08%, which can lead to a significant number of missed diagnoses of minimal breast cancers, potentially missing the optimal treatment window. This is somewhat consistent with the relevant research results, Guldogan N et al suggest that the sensitivity and specificity of AI were 98.51% and 65.40%, respectively.<sup>17</sup> The author believes that the low sensitivity may be related to the fact that artificial intelligence systems can only evaluate the ultrasound characteristics of minimal breast cancers. In the process of clinical practice, the evaluation of breast cancer needs to combine the imaging and clinical characteristics, including the patient’s age, family history of breast cancer, fertility history, etc. The failure of integrating clinical information with ultrasound information of breast lesions may be the main reason for missed diagnosis of minimal breast cancers for AI system. Besides, the small sample size can also affect the accuracy of AI to some extent. Moreover, this study further explored the use of >BI-RADS 3 and >BI-RADS 4A respectively as threshold values to predict the diagnostic efficacy for minimal breast cancers. The results show that using >BI-RADS 3 as a threshold achieves a sensitivity of 100%, which can prevent missed diagnoses to the greatest extent. However, the specificity at this point is only 42.11%, leading to a high rate of misdiagnoses. Therefore, using >BI-RADS 3 and >BI-RADS 4A as threshold values may not be the best approach for managing minimal breast lesions. The evaluation of minimal breast lesion features by an AI-based real-time dynamic ultrasound imaging system requires further optimization.

Our study has several limitations. First, the ultrasound scans were performed concurrently with the AI analysis, without a double-blinded assessment. Second, the evaluation of minimal breast lesion features by the AI-based system may present minor discrepancies with the BI-RADS classification system, particularly for less typical features such as lobulated shapes, irregular contours, and unclear margins, which are not explicitly detailed in the BI-RADS guidelines. Thirdly, the sample size of our study is relatively small. Lastly, due to the confidentiality requirements of the Beijing Yizhun Intelligent Technology Co., Ltd., the technical details of the artificial intelligence system used in this study cannot be disclosed to the public, including algorithms, training data, and validation methods. Therefore, unless using the same

**Table 3** BI-RADS Category of Minimal Breast Lesions and Incidence of Malignant Lesions

BI-RADS Category	Number of nodules	Benign number	Malignant number	Malignant Rate
Category 3	96	96	0	0
Category 4A	122	100	22	18.03
Category 4B	69	32	37	53.62
Category 4C	4	0	4	100



**Figure 2** ROC Curves for diagnosing minimal breast lesions.

product, it may be difficult to assess the robustness of the AI system or to replicate the study’s results for other companies or scholars.

### Conclusion

The AI-based real-time dynamic ultrasound imaging system shows good effectiveness in diagnosing minimal breast nodules, which is helpful for early diagnosis and treatment of breast cancer, and improves the prognosis of patients. However, it still results in some missed diagnoses and misdiagnoses of minimal breast cancers. Expanding the sample size for training may improve the accuracy of diagnosis minimal breast nodules further.

**Table 4** Diagnostic Performance for Minimal Breast Lesions When Threshold Values Were >BI-RADS 3 and >BI-RADS 4A

	<b>Sensitivity</b>	<b>Specificity</b>	<b>PPV</b>	<b>NPV</b>	<b>Accuracy</b>
>3	100.00 (63/63)	42.11 (96/228)	32.31 (63/195)	100 (96/96)	54.64 (159/291)
>4A	65.08 (41/63)	85.96 (196/228)	56.16 (41/73)	89.91 (196/218)	81.44 (237/291)
$\chi^2$ Value		95.222	12.730		48.073
P value	<0.001	<0.001	<0.001	<0.001	<0.001

## Ethical Statement

The authors are accountable for all aspects of this work, ensuring that questions related to the accuracy or integrity of any part of the work are appropriately investigated and resolved. All procedures involving human participants were performed in accordance with the Declaration of Helsinki (revised 2013). This study was approved by the ethics committee of the Affiliated Hospital of Jiangnan University. Written informed consent was obtained from all participants before inclusion in the study. Patient information, such as name, age, sex, occupation, address, ID card, related diseases, and treatment plan, was provided by the Affiliated Hospital of Jiangnan University during the treatment period. Owing to the privacy of patients, the Affiliated Hospital of Jiangnan University kept the above information confidential.

## Funding

Wuxi Maternal and Child Health Promotion Project (FYTG202203).

## Disclosure

The authors declare that they have no conflicts of interest.

## References

1. Sung H, Ferlay J, Siegel RL, et al. Global Cancer Statistics 2020: GLOBOCAN Estimates of Incidence and Mortality Worldwide for 36 Cancers in 185 Countries. *CA Cancer J Clin.* 2021;71:209–249. doi:10.3322/caac.21660
2. Kashyap D, Pal D, Sharma R, et al. Global Increase in Breast Cancer Incidence: Risk Factors and Preventive Measures. *Biomed Res Int.* 2022;18:960–968. doi:10.1155/2022/9605439
3. Li SY. Radiomics based on ultrasound images for diagnosis of minimal breast cancer. *J Clin Ultrasound.* 2023;51:1544–1545. doi:10.1002/jcu.23576
4. Ross DS, Liu YF, Pipa J, et al. The diagnostic utility of the minimal carcinoma triple stain in breast carcinomas. *Am J Clin Pathol.* 2013;139:62–70. doi:10.1309/AJCPF400ADKFMGRJ
5. Guo R, Lu G, Qin B, et al. Ultrasound Imaging Technologies for Breast Cancer Detection and Management: a Review. *Ultrasound Med Biol.* 2018;44:37–70. doi:10.1016/j.ultrasmedbio.2017.09.012
6. Jabeen K, Khan MA, Alhaisoni M, et al. Breast Cancer Classification from Ultrasound Images Using Probability-Based Optimal Deep Learning Feature Fusion. *Sensors.* 2022;22:807–815. doi:10.3390/s22030807
7. Din NMU, Dar RA, Rasool M, et al. Breast cancer detection using deep learning: datasets, methods, and challenges ahead. *Comput Biol Med.* 2022;149:106–122. doi:10.1016/j.compbiomed.2022.106073
8. Shen YT, Chen L, Yue WW, et al. Artificial intelligence in ultrasound. *Eur J Radiol.* 2021;139:109717. doi:10.1016/j.ejrad.2021.109717
9. Zhao G, Kong D, Xu X, et al. Deep learning-based classification of breast lesions using dynamic ultrasound video. *Eur J Radiol.* 2023;165:110885. doi:10.1016/j.ejrad.2023.110885
10. Tan PH, Ellis I, Allison K, et al. WHO Classification of Tumours Editorial Board. The 2019 World Health Organization classification of tumours of the breast. *Histopathology.* 2020;77(2):181–185. doi:10.1111/his.14091
11. Lebeau A, Denkert C. Aktualisierte WHO-Klassifikation der Tumoren der Mamma: die wichtigsten Änderungen [Updated WHO classification of tumors of the breast: the most important changes]. *Pathologe.* 2021;42:270–280. doi:10.1007/s00292-021-00934-9
12. Wang Y, Li Y, Song Y, et al. Comparison of ultrasound and mammography for early diagnosis of breast cancer among Chinese women with suspected breast lesions: a prospective trial. *Thorac Cancer.* 2022;13:3145–3151. doi:10.1111/1759-7714.14666
13. Tadesse GF, Tegaw EM, Abdisa EK. Diagnostic performance of mammography and ultrasound in breast cancer: a systematic review and meta-analysis. *J Ultrasound.* 2023;26:355–367. doi:10.1007/s40477-022-00755-3
14. Monticciolo DL, Newell MS, Moy L, et al. Breast Cancer Screening for Women at Higher-Than-Average Risk: updated Recommendations From the ACR. *J Am Coll Radiol.* 2023;20(9):902–914. doi:10.1016/j.jacr.2023.04.002
15. Luo WQ, Huang QX, Huang XW, et al. Predicting Breast Cancer in Breast Imaging Reporting and Data System (BI-RADS) Ultrasound Category 4 or 5 Lesions: a Nomogram Combining Radiomics and BI-RADS. *Sci Rep.* 2019;9:119–127. doi:10.1038/s41598-019-48488-4
16. Hamyoon H, Yee Chan W, Mohammadi A, et al. Artificial intelligence, BI-RADS evaluation and morphometry: a novel combination to diagnose breast cancer using ultrasonography, results from multi-center cohorts. *Eur J Radiol.* 2022;157:110591. doi:10.1016/j.ejrad.2022.110591
17. Guldogan N, Taskin F, Icten GE, et al. Artificial Intelligence in BI-RADS Categorization of Breast Lesions on Ultrasound: can We Omit Excessive Follow-ups and Biopsies? *Acad Radiol.* 2024;31:2194–2202. doi:10.1016/j.acra.2023.11.031



International Journal of General Medicine

Dovepress

### Publish your work in this journal

The International Journal of General Medicine is an international, peer-reviewed open-access journal that focuses on general and internal medicine, pathogenesis, epidemiology, diagnosis, monitoring and treatment protocols. The journal is characterized by the rapid reporting of reviews, original research and clinical studies across all disease areas. The manuscript management system is completely online and includes a very quick and fair peer-review system, which is all easy to use. Visit <http://www.dovepress.com/testimonials.php> to read real quotes from published authors.

Submit your manuscript here: <https://www.dovepress.com/international-journal-of-general-medicine-journal>