

# THE MINUS® SYSTEM MINIMALLY INVASIVE TECHNIQUE FOR THE TREATMENT OF TRANSTROCHANTERIC FRACTURES

Rogério Naim Sawaia<sup>1</sup>, William Dias Belangero<sup>2</sup>

## ABSTRACT

The MINUS system was developed as a minimally invasive procedure that uses a diaphyseal cephalic extramedullary implant for the treatment of transtrochanteral fractures of the femur in elderly patients. The implant consists of a sliding screw coupled to a plate adapted to the minimally invasive technique. The surgical access is approximately three centimeters in length located on the lateral surface of the hip, below the projection of the small trochanter. A perfectly adapted instrument was used for the procedure, which also requires the use of an image

intensifier, reducing surgery time and rate of bleeding. The objective of this study is to present a new instrument and implant, developed specifically for treatment with the minimally invasive technique, reducing the length of the conventional surgical access from 10 to three centimetres. This new implant was given the commercial name of MINUS System.

**Keywords** - Surgical Procedures, Minimally Invasive; Hip Fractures; Femoral Fractures; Bone Screws

## INTRODUCTION

The advent of minimally invasive techniques has provided better results from treating complex fractures produced by high-energy trauma, generally associated with severe soft-tissue lesions<sup>(1)</sup>. This treatment methodology has also been shown to be advantageous for intertrochanteric fractures of the femur, thereby reducing the bleeding and pain and providing earlier rehabilitation for these patients, who are mostly elderly<sup>(1-7)</sup>.

Today, the principle used is one of relative stability through intra and extramedullary implants, represented by sliding pin plates and intramedullary nails<sup>(7-11)</sup>. Among sliding screw systems, the biggest representative is the implant known as the dynamic hip screw (DHS)®, which is considered to be the gold standard<sup>(4,5,9)</sup> for treatment of these fractures. The technique uses a wide access route, with bleeding levels proportional to the size of the incision<sup>(12)</sup>.

## METHOD

The MINUS system is composed of a sliding pin coupled to a plate with three holes and instruments that were developed specifically for introducing this implant<sup>(13)</sup>. Below, the instruments and implant are described:

### Instruments

One depth measurement device for sliding pins: aluminum B221M;  
 One plate guide: aluminum B221M;  
 Two bits (ø 3.2 x 250 mm): stainless steel AISI 420;  
 One external jacket: stainless steel AISI 420;  
 One external jacket: stainless steel AISI 420;  
 One plate guide screw (M6 x 1): stainless steel AISI 420;  
 One bit protector: stainless steel AISI 420;  
 One 135° guide: stainless steel AISI 420; One T key: stainless steel AISI 420;

1- Orthopedic Physician, Hospital Samaritano in São Paulo, SP and Hospital Antonio Giglio in Osasco - São Paulo, SP, Brazil.

2- Doctor and Professor of the Department of Orthopedics and Traumatology of the Faculty of Medical Sciences, UNICAMP – Campinas, SP, Brazil.

Work carried out at the Orthopedics and Traumatology Service (SOT) of the Hospital Samaritano of São Paulo (HS-SP) – Hip Group.

Correspondence: Rua Capote Valente, 154, ap.61 – CEP 05409-000 – São Paulo, SP. E-mail: rsawaia@superig.com.br

Received for publication: 11/15/2010, accepted for publication: 05/25/2011.

The authors declare that there was no conflict of interest in conducting this work

This article is available online in Portuguese and English at the websites: [www.rbo.org.br](http://www.rbo.org.br) and [www.scielo.br/rbort](http://www.scielo.br/rbort)

One rotation forceps: stainless steel AISI 420;  
 One rotation key: stainless steel AISI 420;  
 One male ( $\varnothing$  13 mm): stainless steel AISI 420;  
 One screw depth measurement device: stainless steel AISI 420;  
 One impacting device: stainless steel AISI 420;  
 One external key for sliding pins: stainless steel AISI 420;  
 One internal key for sliding pins: stainless steel AISI 420;  
 One key for cortical screws: stainless steel AISI 420;  
 Four calibrated guidewires ( $\varnothing$  2.5 x 230 mm): stainless steel ASTM F138;  
 Four calibrated guidewires ( $\varnothing$  2.5 x 300 mm): stainless steel ASTM F138;  
 Note: All the instruments are milled, except for the forceps and rotation keys, which are forged.

### Implant

Self-tapping cortical screw ( $\varnothing$  4.5 mm), of lengths 28 mm to 54 mm, in 2-mm steps: stainless steel ASTM F138 or titanium alloy ASTM F136;  
 Sliding pin with hexagonal head, of lengths 60 mm

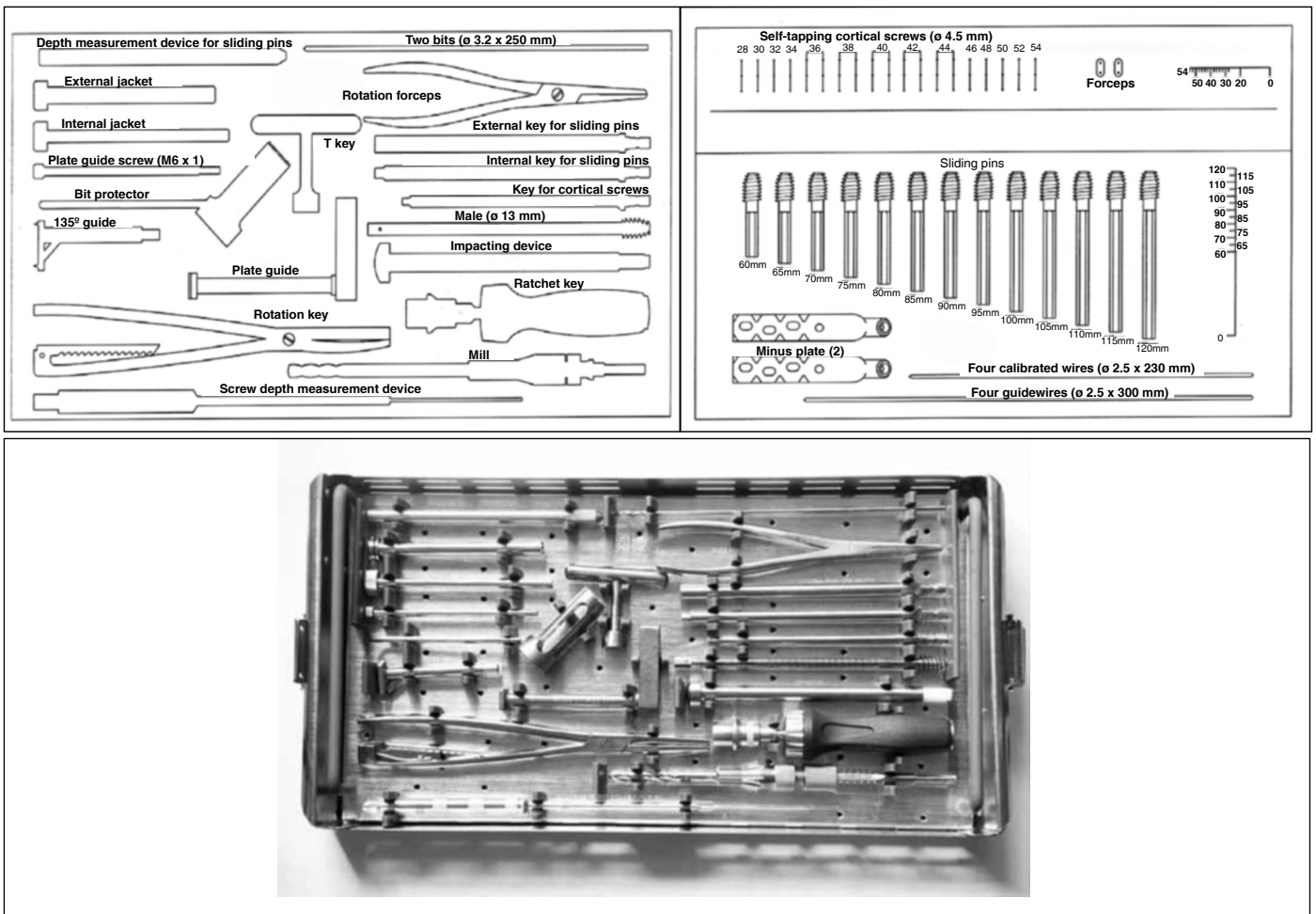
to 120 mm, in 5 mm steps): stainless steel ASTM F138 or titanium ASTM F136;

MINUS plate with three holes: forged titanium ASTM F136 / ASTM F620; plate thickness: 6.5 mm

Note: All the implants are milled, with the exception of the plate, which is forged (Figure 1).

### SURGICAL TECHNIQUE:

The patient is positioned in horizontal dorsal decubitus on a radiotransparent table. A pad of 5 cm in thickness is placed under the buttock on the same side as the fracture, to diminish the effect of anteversion of the femoral neck and to facilitate access to the proximal diaphysis of the femur, especially in obese patients (Figure 2). From the image intensifier, the quality of the reduction, i.e. the first step in the surgical procedure, can be seen. In cases of both stable and unstable fractures, functional reduction is sought, and deformity in varus and in retroversion of the femoral neck is avoided.



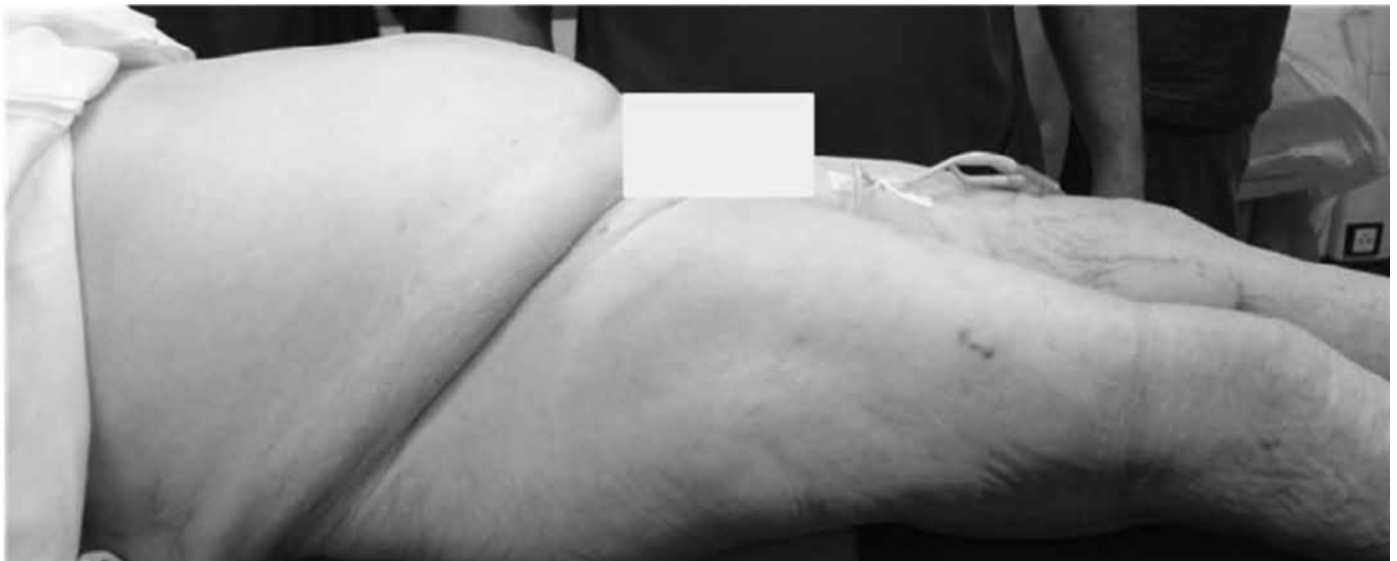**Figure 1** – Box containing instruments and implants. Schematic drawing and photograph.

After the reduction, the fracture is provisionally fixed using two Kirschner wires, of diameter 2.0 mm, which are inserted into the lateral face of the greater trochanter and go through the upper part of the femoral neck towards the femoral head (Figure 3).

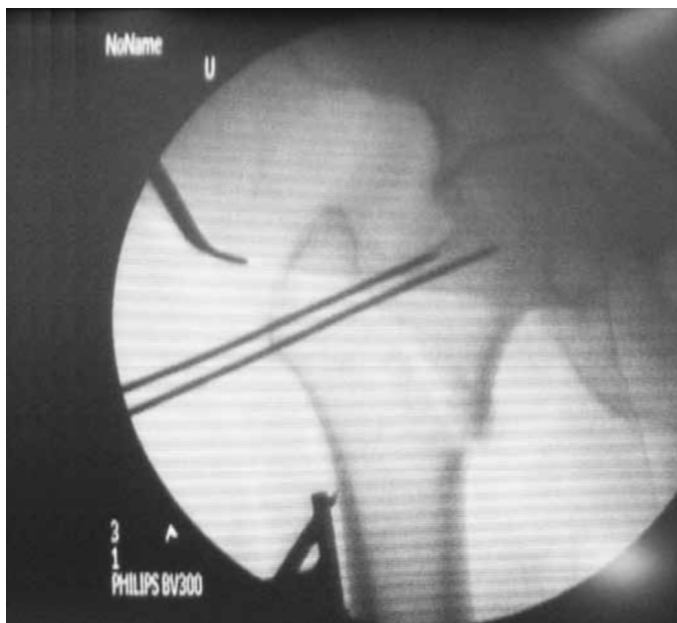
The incision is made 2 cm below the base of the lesser trochanter, at the intersection point with the femoral diaphysis. When this reference point is fractured or avulsed, the incision is started 2 cm distally to the end of the projection of the calcar, and is 3 cm in length (Figure 4).

After opening the skin, subcutaneous cellular tissue and fascia lata, the vastus lateralis muscle is di-

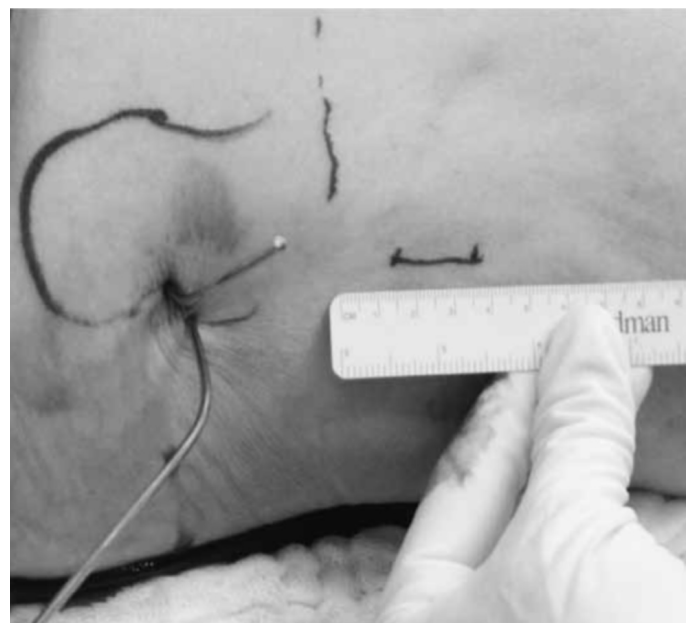
vulsed along its fibers as far as the bone plane, using Kelly forceps. With a 135° guide, the guidewire is introduced into the center of the femoral neck and head, guided by the image intensifier in AP and lateral views, while taking care to avoid interposition of the vastus lateralis between the guide and the femoral diaphysis, using the image intensifier (Figure 5). Using the measuring device, the pin size is determined. Drilling and milling of the femoral neck are performed with the three-level mill, and the size is measured based on the previous measurement made from the guidewire. The soft-tissue protector is used to avoid laceration of the vastus lateralis and fascia



**Figure 2** – Positional of the patient on the conventional table.



**Figure 3** – Reduced fracture, provisionally fixed with two percutaneous Kirchner wires.



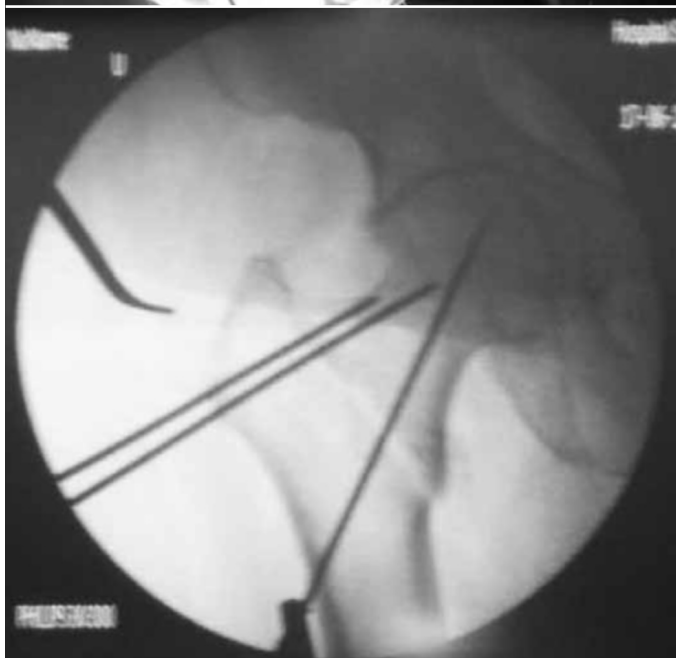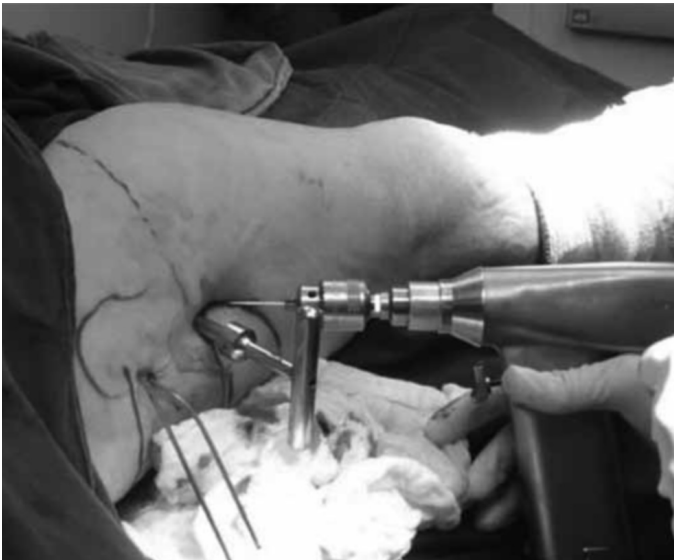**Figure 4** – Determination of starting point for the access route.

lata. The sliding pin chosen should be 5.0 mm longer than the measurement, so that it remains protruding on the lateral face of the lateral cortical bone of the femur, thus making it easier to fit the plate on the screw. The plate should be slid close in to the bone, below the musculature, with the tube turned towards the surgeon, using the plate forceps. As soon as it has been introduced, it is turned through 180° on its axis, so that the tube is introduced over the screw (Figure 6). Since these are elderly patients with flaccid musculature, this part of the procedure is carried out without great difficulty. Using the external guide, the plate holes are located and drilling for the distal screw is started, in order to position the plate at the

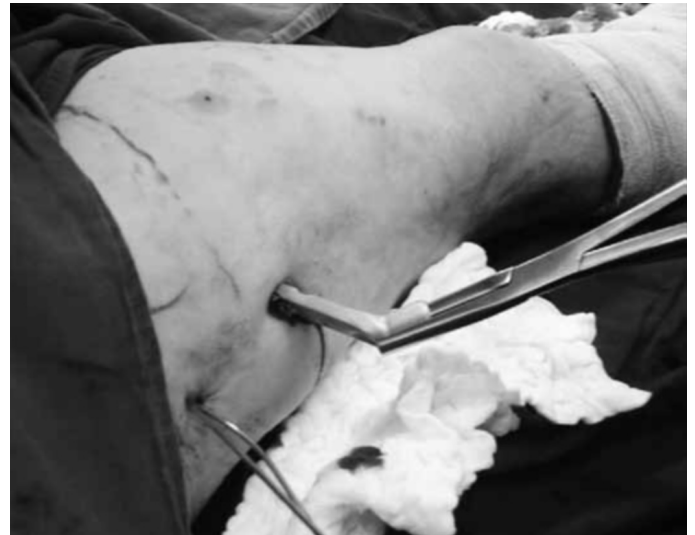center of the diaphysis (Figure 7). The two distal screws are introduced percutaneously by means of a 0.5 cm accessory route, and the proximal screw through the main route. After this, the final closure is performed (Figure 8).

## FINAL REMARKS

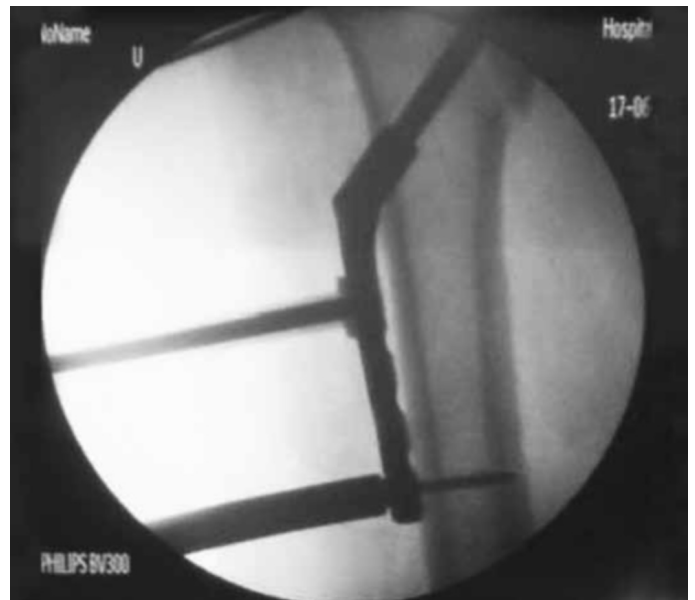
The treatment that is best for transtrochanteric fractures of the femur, taking into account unstable fractures in particular, is still a matter for debate in the literature. The choice between extra and intramedullary systems is based not only on the stability factor but also on the biological advantage<sup>(5,13-16)</sup> and the final cost of the procedure<sup>(16-18)</sup>.



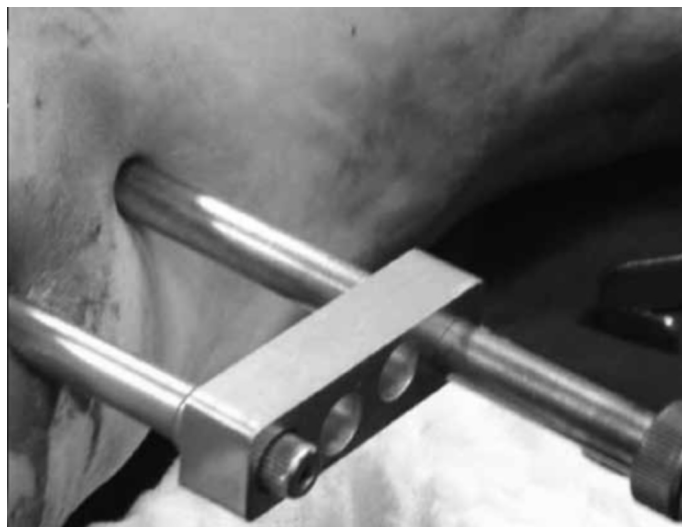**Figure 5** – Positioning of the guidewire using the 135° guide.



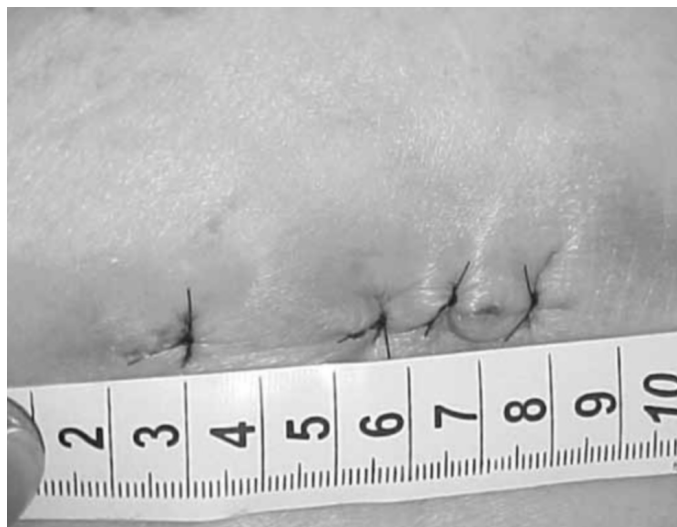
**Figure 6** – Introduction of the MINUS plate.



**Figure 7** – Plate in position and stabilized with a distal screw using the extramedullary guide.



**Figure 7B** – Plate in position and stabilized with a distal screw using the extramedullary guide.



**Figure 8** – Final appearance of skin closure.

Several studies have compared the two systems and have not found significant differences in relation to length of the surgery, blood loss, consolidation and postoperative mortality<sup>(18-20)</sup>.

Other types of minimally invasive implants can also be used, such as external fixators and, most recently, percutaneous compression plating (PCCP)<sup>(1)</sup>, which has not yet been tested on a large scale.

Without doubt, minimally invasive surgery is a path from which there is no return, but without losing quality of reduction and stabilization of the fracture. The MINUS system fulfills all these requisites, with the advantage of coming from a system that has already been used, which significantly reduces the learning curve that is always necessary for new techniques and implants.

## REFERENCES

1. Kuzyk PR, Guy P, Kreder HJ, Zdero R, McKee MD, Schemitsch EH. Minimally invasive hip fracture surgery: are outcomes better? *J Orthop Trauma*. 2009;23(6):447-53.
2. Janzing HM, Houben BJ, Brandt SE, Chhoeurn V, Lefever S, Broos P, et al. The Gotfried PerCutaneous Compression Plate versus the Dynamic Hip Screw in the treatment of pertrochanteric hip fractures: minimal invasive treatment reduces operative time and postoperative pain. *J Trauma*. 2002;52(2):293-8.
3. Sawaia RN, Belangero WD. Estudo comparativo entre a técnica de miniincisão e a via de acesso a foco aberto para o tratamento das fraturas transtrochantéricas. *Rev Bras Ortop*. 2005;40(3):106-18.
4. Lee YS, Huang HL, Lo TY, Huang CR. Dynamic hip screw in the treatment of intertrochanteric fractures: a comparison of two fixation methods. *Int Orthop*. 2007;31(5):683-8.
5. Alobaid A, Harvey EJ, Elder GM, Lander P, Guy P, Reindl R. Minimally invasive dynamic hip screw: prospective randomized trial of two techniques of insertion of a standard dynamic fixation device. *J Orthop Trauma*. 2004;18(4):207-12.
6. Chong KW, Wong MK, Rikhraj IS, Howe TS. The use of computer navigation in performing minimally invasive surgery for intertrochanteric hip fractures—The experience in Singapore. *Injury*. 2006;37(8):755-62.
7. Baumgaertel, F. Placas em ponte. “Princípios AO do tratamento de fratura”. In.: Ruedi TP, Murphy W M. Porto Alegre: ArtMed; 2002. p. 221-9.
8. Rush LV. Dynamic intramedullary fracture-fixation of the femur. Reflections on the use of the round rod after 30 years. *Clin Orthop Relat Res*. 1968;60:21-7.
9. Bridle SH, Patel AD, Bircher M, Calvert PT. Fixation of intertrochanteric fractures of the femur. A randomised prospective comparison of the gamma nail and the dynamic hip screw. *J Bone Joint Surg Br*. 1991;73(2):330-4.
10. Goldman L, Lee T, Rudd P. Ten commandments for effective consultations. *Arch Intern Med*. 1983;143(9):1753-5.
11. Curtis MJ, Jinnah RH, Wilson V, Cunningham BW. Proximal femoral fractures: a biomechanical study to compare intramedullary and extramedullary fixation. *Injury*. 1994; 25(2):99-104.
12. Muller ME, Allgower M, Schneider R, Willenegger H. Manual de osteossintese 3a. edição. São Paulo: Manole; 1993. p. 270-6.
13. Al-yassari G, Langstaff RJ, Jones JW, Al-Lami M. The AO/ASIF proximal femoral nail (PFN) for the treatment of unstable trochanteric femoral fracture. *Injury*. 2002;33(5):395-9.
14. Park SR, Kang JS, Kim HS, Lee WH, Kim YH. Treatment of intertrochanteric fracture with the Gamma AP locking nail or by a compression hip screw—a randomised prospective trial. *Int Orthop*. 1998;22(3):157-60.
15. Bridle S, Patel A, Bircher M, Calvert PT. Fixation of intertrochanteric fractures of the femur. *J Bone Joint Surg Br*. 1991;73(2):330-4.
16. Sawaia RN, Belangero WD. The treatment of transtrochanteric fractures of the femur with a minimally invasive technique using an extramedullary implant MINUS System. *Int Orthop*. 2008;32(2):159-65.
17. Zethraeus N, Strömberg L, Jönsson B, Svensson O, Ohlén G. The cost of a hip fracture. Estimates for 1,709 patients in Sweden. *Acta Orthop Scand*. 1997;68(1):13-7.
18. Johnell O. The socioeconomic burden of fractures: today and in the 21<sup>st</sup> century. *Am J Med*. 1997;103(2A):20S-25S.
19. Radford PJ, Needoff M, Webb JK. A prospective randomised comparison of the dynamic hip screw and the gamma locking nail. *J Bone Joint Surg Br*. 1993;75(5):789-93.
20. Harrington P, Nihal A, Singhania AK, Howell FR. Intramedullary hip screw versus sliding hip screw for unstable intertrochanteric femoral fractures in the elderly. *Injury*. 2002;33(1):23-8.