



## Case Report

# Periodic electroclinical seizures following an ischemic stroke revealed by continuous-EEG

Ayşe Deniz Elmali\*, Esme Ekizoglu, Irem Ciftci, Nilufer Yesilot, Oguzhan Coban, Betül Baykan

Istanbul University, Istanbul Faculty of Medicine, Department of Neurology, Istanbul, Turkey

## ARTICLE INFO

## Article history:

Received 12 September 2020

Revised 15 December 2020

Accepted 17 December 2020

Available online 20 January 2021

## Keywords:

Continuous EEG monitoring

Cortical spreading depression

Periodic seizures

Post-stroke epilepsy

## ABSTRACT

**Background:** Periodic EEG patterns are mostly associated with critical illnesses and acute disruptions of the central nervous system. Periodic or cyclic seizures are extremely rare phenomena, most of which are nonconvulsive, only reported in critically ill patients. Here we report a patient with periodic focal impaired awareness seizures following a minor stroke and address possible pathophysiological mechanisms.

**Case:** A 49 years old male patient presented with periodic seizures, associated with an acute stroke in the left occipital and parietal regions. These focal seizures, recorded during long-term video-EEG monitoring in the scalp EEG, appeared every 9–11 min, and responded to iv valproic acid treatment but not to iv treatments of diazepam, phenytoin, and levetiracetam.

**Discussion:** We believe that the blood–brain barrier disruption due to stroke, in conjunction with hyperglycemia and antiphospholipid antibodies have led to an imbalance of the surrounding tissue and sustained hyperexcitability to a point of pacemaker potentials. It is tempting to speculate that repetitive cycles of cortical spreading depression due to tissue injury have aided the periodicity of the seizures.

**Conclusion:** Continuous EEG monitoring is crucial, not only to diagnose and appropriately treat accompanying subtle seizures but also to further understand the underlying intriguing pathophysiological processes like periodicity.

© 2021 The Authors. Published by Elsevier Inc. This is an open access article under the CC BY-NC-ND license (<http://creativecommons.org/licenses/by-nc-nd/4.0/>).

Periodicity in the EEG terminology is defined as “repetition of a discharge or pattern with relatively uniform morphology and duration with a quantifiable interdischarge interval between consecutive waveforms and recurrence of the waveform at nearly regular intervals” by Hirsch et al. [1] Periodic EEG patterns are almost never “benign” in nature, mostly observed in critically ill patients with acute disruptions of the integrity of the central nervous system. Periodic or cyclic focal seizures, on the other hand, are extremely uncommon encounters. They are first reported by Blume in 1997 as “periodic seizures” and later called “cyclic” by Friedman in 2008. They are only reported in critically ill patients and almost all of them are nonconvulsive, lacking clinical correlates [2–4].

Here we report a 49 years old male patient with sudden onset of strictly periodic, frequent focal impaired awareness seizures following a minor stroke and address the possible pathophysiological mechanisms.

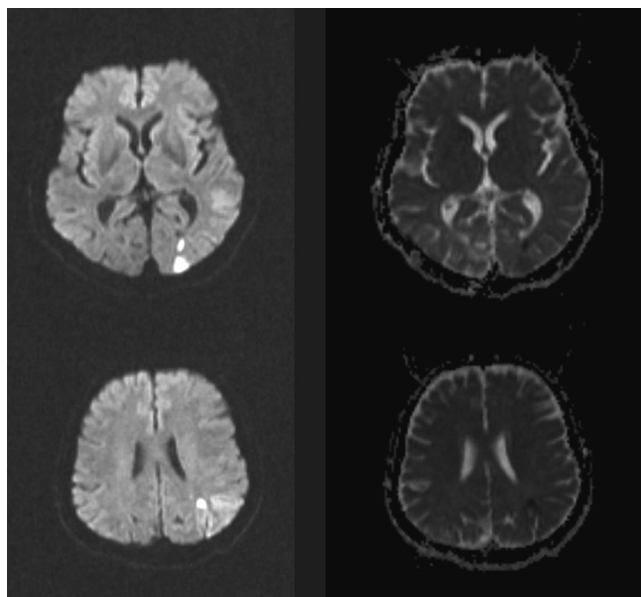
## 1. Case report

Forty-nine years old male patient with a history of poorly controlled diabetes mellitus has presented to our emergency room with right-sided mild paresis, right homonymous hemianopia and confusion. Brain MR imaging revealed scattered small diffusion restriction area and low signal on the ADC map in the left occipital and parietal regions compatible with an acute ischemic stroke (Fig. 1). His cranial MRI also showed a former silent ischemic infarction in the right occipital region. Vascular and cardiac investigations did not reveal any pathological findings. There were no other biochemical abnormalities except elevated glucose levels of 237 mg/dl (concomitant bicarbonate levels were 25.1 mmol/L) on admission with an HbA1C level of 12.7%. He had a history of peripheral artery disease treated surgically two years ago and family history disclosed that one of his sons was diagnosed with systemic lupus erythematosus.

Episodes of fluctuating confusion suggestive of seizures were noted and his emergency EEG showed 2 focal seizures starting from the left occipitoparietal region, spreading rapidly throughout the hemisphere with a limited extension to the posterior regions of the right hemisphere. These seizures lasted approximately 90–

\* Corresponding author at: Istanbul University, Istanbul Faculty of Medicine, Department of Neurology, 34390, Millet Street, Capa Istanbul, Turkey.

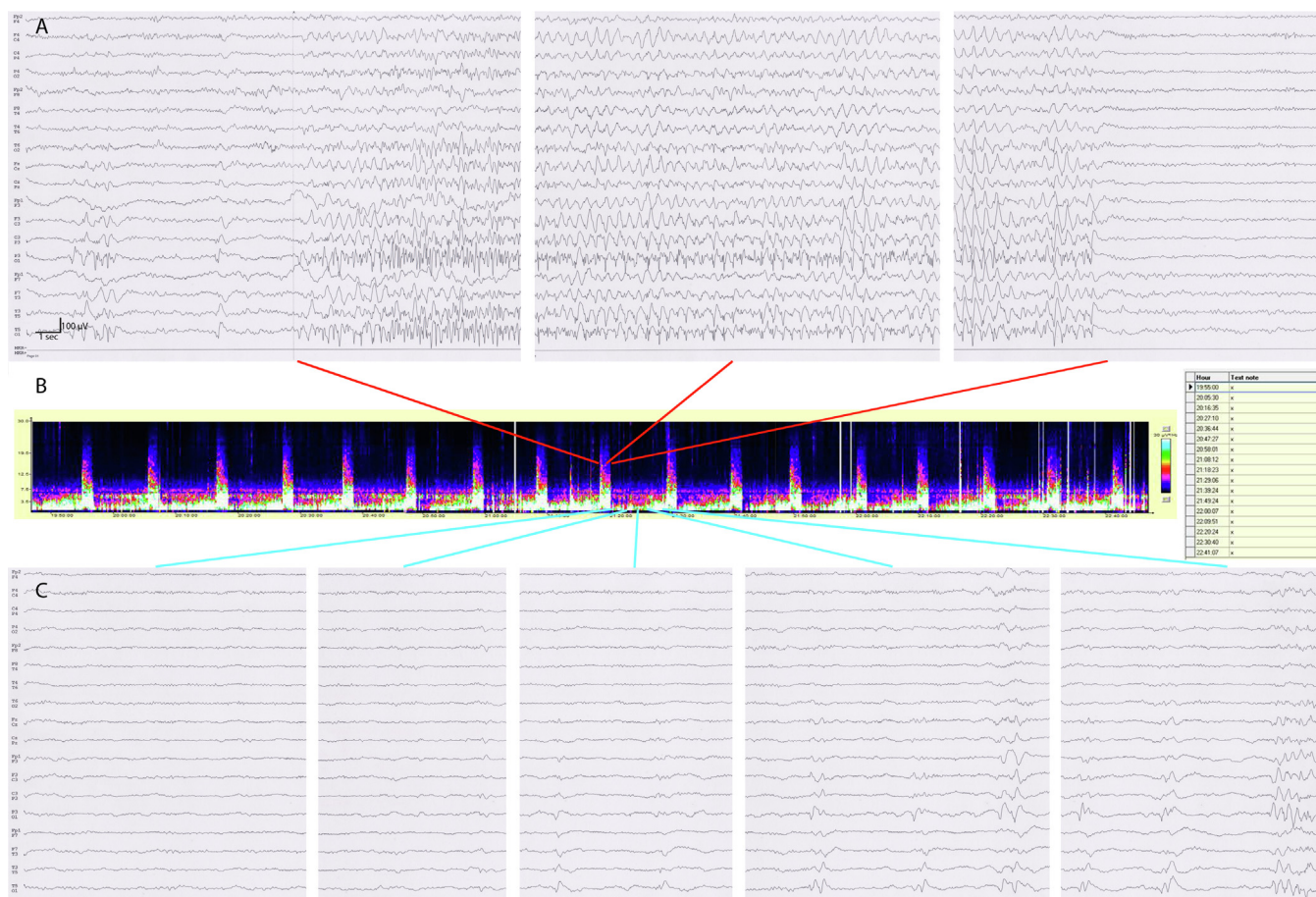
E-mail address: [denizelmali@yahoo.com](mailto:denizelmali@yahoo.com) (A.D. Elmali).



**Fig. 1.** Axial diffusion-weighted MR imaging showing scattered small diffusion restriction areas in the left occipital and parietal regions (a), confirmed on ADC map (b) in accordance with an acute ischemic stroke.

120 s before ending abruptly on both hemispheres. During these seizures, the patient became non-responsive, kept uttering his last sentence immediately before the seizure onset (ictal speech), and left upper manual automatisms starting after 60 s were observed. In the continuous video-EEG monitoring lasting 48 h, we observed that these uniform seizures repeated every 9–11 min (range 505–665 seconds, mean  $607.4 \pm 37.1$ ) in a strictly periodic manner (Fig. 2). Early postictal EEG following the seizure was significant other than mild background slowing on the left hemisphere, lateralized periodic discharges emerged later on. Neuropsychological evaluation demonstrated fluctuating frontal dysfunction.

The periodicity and seizure frequency did not change despite iv diazepam (10 mg), iv phenytoin (18 mg/kg), and iv levetiracetam (20 mg/kg) treatments as monitored closely by continuous-EEG. Only after an iv valproic acid (20 mg/kg) treatment, the intervals between seizures became longer (90 min) and the duration of the seizures lengthened (30 min), and diminished altogether under 2000 mg valproic acid, 200 mg lacosamide and 400 mg carbamazepine treatments, after 3 days following admission. (Please see Supp Table 1 for the treatment trials) Lumbar puncture did not reveal any remarkable abnormalities. Viral panels, serologic studies and paraneoplastic antibody screening were all negative. However, he had ANA positivity (homogenous, 1/2560) and antiphospholipid antibodies (beta2 glycoprotein IgM: 36.9 U/ml, beta2 glycoprotein IgG: 19.4 U/ml and anticardiolipin IgG: 19.8



**Fig. 2.** Low pass filter: 70 Hz, High pass filter: 0.5 Hz, Notch filter: 50 Hz. (a). Ictal EEG findings: seizure activity starting from the left occipitoparietal region, spreading rapidly throughout the hemisphere with a limited extension to the posterior regions of the right hemisphere. Seizures lasted approximately 90–120 s before ending abruptly on both hemispheres. (b). Periodicity of the seizures can be observed in the bar and table. (c). Interictal findings: Within seconds after the seizure, periodic lateralized discharges emerged in the left hemisphere. They became more prominent and showed generalization and multiplication immediately before the impending seizure. This interictal pattern also emerged periodically.

U/ml) but did not fulfill the criteria for systemic lupus erythematosus or primary antiphospholipid syndrome yet. The patient was discharged without any disability and he was seizure-free, his control EEG exam after one month was unremarkable other than scant generalized slow wave paroxysms.

## 2. Discussion

Our patient showed acute symptomatic, focal impaired awareness seizures emerging in a remarkable periodic manner. We believe calling these seizures “periodic” is more appropriate than cyclic, based on the definition of periodicity in the ACNS guideline [1]. These seizures are most likely to occur in older patients with acute or progressive brain injury and more likely to be associated with poor outcomes [4]. This report presents a rather pleasing contrast; our case is a younger gentleman with a comparatively minor stroke and his prognosis has been excellent.

There has been a long-standing controversy on whether periodic lateralized epileptiform discharges (PLED) represent an ictal finding or an interictal phenomenon [5]. We believe this patient might represent an example of the extreme end of a spectrum in interictal to ictal lateralized periodic discharges continuum. Seizures are common consequences of stroke and stroke-related seizures are divided into two groups according to seizure onset; seizures occurring in the first seven days are classified as early seizures [6]. In early seizures, disruption of the blood brain barrier and ischemic insult of the neurons may result in ion channel dysfunctions and disturbed homeostasis of the neurotransmitters, in addition to biochemical dysfunctions leading to irritability of the offended tissue [7].

The association of auto-antibodies with seizures is also a well-known but complicated issue; the present autoantibodies might have contributed to the seizure generation in our case. Moreover, PLEDs were reported in patients with SLE and seizures [8]. Although multiple recurrent seizures are well described in autoimmune epilepsies, (e.g. frequent facio-brachial dystonic seizures in LGI1 antibody encephalitis) they are not periodic in nature [9]. Furthermore, hyperglycemia, as observed in our patient is also a known contributor to the blood-brain barrier disruption and generation of periodic patterns like PLEDs and also involved in seizure generation [10]. Glucose is also an important mediator in the regulation of potassium metabolism, higher glucose and insulin levels increase the cellular uptake of potassium. Malfunctions in the ion channels due to neuronal damage and such mediators might give rise to leaky Na or Ca and K channels leading to spontaneous rhythmic depolarizations similar to a pacemaker potential.

The lobar origin of these periodic seizures also needs further attention. The damage to the cortex in stroke may lead to cortical spreading depression (CSD), which relates to a loss of ion homeostasis leading to a widespread depolarization of the neurons and astrocytes with altered metabolism and blood flow [11]. Accumulating evidence indicated that CSD is the pathophysiological hallmark of the migraine aura, starting in the occipital cortex, specifically. Infarct of the posterior cerebral artery caused by atherothrombosis may be the key factor in our case, as previous ICU series also report a tendency of posterior onset for cyclic seizures [3,4]. It has been shown that focal seizures involving primarily the consciousness may originate from any lobe including parietooccipital regions, however rare it may be [12]. Thus the parieto-occipital origin of the periodic seizures may support the involvement of CSD by this minor stroke.

CSD and CSD-like events can be triggered by injury of the tissue due to trauma, hemorrhage, ischemia etc. [13]. CSD has been reported to co-occur or even cause seizure by means of synchronizing the affected tissue [14]. The opposite has also been demonstrated, epileptiform activity initiated waves of CSD. In a rat

model, spike triggered spreading depression was seen to repeat in cycles lasting a mean of 6 min and up to 20 cycles [15]. Repetitive cycles of CSD have also been reported in a patient with increased intracranial pressure due to traumatic contusion [16]. The common point of these important but anecdotal observations is the use of intracranial electrodes. It is tempting to speculate that this periodic pattern might be a common phenomenon after tissue injury (in conjunction with biochemical abnormalities as a double hit) that is greatly missed via routine scalp EEG. We think that the same cyclic interplay between focal seizure activity and CSD might be the underlying explanation for the intriguing periodicity of our patient's seizures. The lack of any effect of the standard iv antiepileptic drug treatments other than valproic acid, which is also effective against CSD in migraine patients, further strengthens this hypothesis [17]. There is a synergistic pharmacodynamic interaction between PHT and VPA in vivo. We think that this might have been helpful in the limitation of the cycling seizures [18].

A very recent study has also suggested that cyclic seizures may point out to a more favorable outcome in younger patients compared to noncyclic ones. [19] The peculiar build-up phenomenon has also been reported in the literature and may constitute a clue for the ongoing cyclic seizures, which may be missed in short routine EEG recordings. [3]

## 3. Conclusion

In conclusion; an important point raised from this case is the indispensability of continuous EEG monitoring for such patients since peculiar patterns like periodicity would be missed on routine EEGs. Although previous studies reported that cyclic seizures are a negative prognostic factor, this particular case had an excellent prognosis. Further clinical and experimental studies are needed to explore this seemingly vicious cycle of periodic seizures and develop neuroprotective treatment strategies.

## Conflict of interest

On behalf of all authors, the corresponding author states that there is no conflict of interest.

## Disclosure

ADE, EE, IC, NY, OC, BB: no relevant financial or nonfinancial relationships to disclose.

## 6. Compliance with ethical standards

There was no funding for this study.

All of the authors declare that they have no conflict of interest.

All procedures performed were in accordance with the ethical standards of the institutional and national research committee and with the 1964 Helsinki declaration and its later amendments or comparable ethical standards.

Informed consent was obtained from the person hereby reported.

## CRedit authorship contribution statement

**Ayse Deniz Elmali:** Conceptualization, Data curation, Formal analysis, Investigation, Resources, Software, Visualization, Writing - original draft, Writing - review & editing. **Esme Ekizoglu:** Data curation, Supervision, Validation, Writing - review & editing. **Irem Ciftci:** Data curation, Writing - original draft. **Nilufer Yesilot:** Data curation, Supervision, Validation, Writing - review & editing. **Oguzhan Coban:** Conceptualization, Supervision, Validation, Writing -



review & editing. **Betul Baykan:** Conceptualization, Data curation, Formal analysis, Investigation, Resources, Software, Supervision, Validation, Visualization, Writing - original draft, Writing - review & editing.

## References:

- [1] Hirsch LJ, LaRoche SM, Gaspard N, et al. American Clinical Neurophysiology Society's standardized critical care EEG terminology: 2012 version. *J Clin Neurophysiol* 2013;30:1–27.
- [2] Blume WT, Wiebe S. Periodic seizures. *Epilepsia* 1997;38:1355–8.
- [3] Friedman DE, Schevon C, Emerson RG, Hirsch LJ. Cyclic electrographic seizures in critically ill patients. *Epilepsia* 2008;49:281–7.
- [4] Pinto LF, Gilmore EJ, Petroff OA, Sivaraju A, Rampal N, Hirsch LJ, Gaspard N. Cyclic seizures in critically ill patients: clinical correlates, DC recordings and outcomes. *Clin Neurophysiol* 2017;128:1083–90.
- [5] Newey CR, Sahota P, Hantus S. Electrographic features of lateralized periodic discharges stratify risk in the interictal-ictal continuum. *J Clin Neurophysiol* 2017;34:365–9.
- [6] Feyissa AM, Hasan TF, Meschia JF. Stroke-related epilepsy. *Eur J Neurol* 2018. <https://doi.org/10.1111/ene.13813> [Epub ahead of print].
- [7] Marchi N, Granata T, Ghosh C, et al. Blood-brain barrier dysfunction and epilepsy: pathophysiologic role and therapeutic approaches. *Epilepsia* 2012;53:1877–86.
- [8] Lim K-S, Cheong K-L, Tan C-T. Periodic lateralized epileptiform discharges in neuropsychiatric lupus: association with cerebritis in magnetic resonance imaging and resolution after intravenous immunoglobulin. *Lupus* 2010;19:748–52.
- [9] Irani SR, Michell AW, Lang B, et al. Faciobrachial dystonic seizures precede Lgi1 antibody limbic encephalitis. *Ann Neurol* 2011;69:892–900.
- [10] Kim DW, Moon Y, Gee Noh H, et al. Blood-brain barrier Disruption is involved in seizure and hemianopsia in nonketotic hyperglycemia. *Neurologist* 2011;17:164–6.
- [11] Sugaya E, Takato M, Noda Y. Neuronal and glial activity during spreading depression in cerebral cortex of cat. *J Neurophysiol* 1975;38:822–41.
- [12] Baykan B, Altindag E, Feddersen B, Ozel S, Noachtar S. Does semiology tell us the origin of seizures consisting mainly of an alteration in consciousness? *Epilepsia* 2011;52:1459–66.
- [13] Dreier JP, Woitzik J, Fabricius M, et al. Delayed ischaemic neurological deficits after subarachnoid haemorrhage are associated with clusters of spreading depolarizations. *Brain* 2006;129:3224–37.
- [14] Fabricius M, Fuhr S, Willumsen L, et al. Association of seizures with cortical spreading depression and peri-infarct depolarisations in the acutely injured human brain. *Clin Neurophysiol* 2008;119:1973–84.
- [15] Koroleva VI, Bureš J. Cortical penicillin focus as a generator of repetitive spike-triggered waves of spreading depression in rats. *Exp Brain Res* 1983;51:291–7.
- [16] Lauritzen M, Dreier JP, Fabricius M, et al. Clinical relevance of cortical spreading depression in neurological disorders: migraine, malignant stroke, subarachnoid and intracranial hemorrhage, and traumatic brain injury. *J Cereb Blood Flow Metab* 2011;31:17–35.
- [17] Ayata C, Jin H, Kudo C, et al. Suppression of cortical spreading depression in migraine prophylaxis. *Ann Neurol* 2006;59:652–61.
- [18] Paschoa OED, Voskuyl RA, Danhof M. Modelling of the pharmacodynamic interaction between phenytoin and sodium valproate. *Br J Pharmacol* 1998;125:1610–6.
- [19] Zorlu MM, Chuang DT, Buyukozan M, et al. Prognostic significance of cyclic seizures in status epilepticus. *J Clin Neurophysiol* 2020. <https://doi.org/10.1097/WNP.00000000000007>. Advance online publication.